

CASE REPORT

Pituitary apoplexy causing spontaneous remission of acromegaly following long-acting octreotide therapy: a rare drug side effect or just a coincidence

Sunil Kumar^{1,*} and Shruti Sharma²

¹Department of Neurology, Shri Ram Murti Smarak Institute of Medical Sciences (SRMS IMS), Bareilly, Uttar Pradesh, India, and ²Department of Endocrinology, Shri Ram Murti Smarak Institute of Medical Sciences (SRMS IMS), Bareilly, Uttar Pradesh, India

*Correspondence address. Department of Neurology, Shri Ram Murti Smarak Institute of Medical Sciences (SRMS IMS), Bareilly, Uttar Pradesh 243202, India. Tel: +91-8755067373; Fax: +91-8755607373; E-mail: doc.kumarsunil@hotmail.com

Abstract

Pituitary apoplexy is characterized by abrupt onset of haemorrhage or non-haemorrhagic infarction of a pituitary adenoma. The clinical features include acute onset severe headache, visual field defects, meningeal irritation, ophthalmoplegia and hypopituitarism. The pituitary apoplexy may be clinically silent in ~25% of patients. We report a case of acromegaly due to pituitary macroadenoma. The patient was started on long-acting octreotide therapy. On 3-month follow-up, the patient showed clinical and biochemical remission and the magnetic resonance imaging (MRI) of the brain showed subclinical haemorrhage and resolution of tumour. The octreotide therapy was stopped. On 6-month follow-up, the patient was still in remission and the MRI of brain revealed non-enhancing mixed intensities haemorrhagic and cystic areas of the pituitary gland. In our patient, whether spontaneous remission of acromegaly due to subclinical pituitary haemorrhage was coincidental or due to long-acting octreotide therapy is still a dilemma. We report this case because of rarity and clinical importance of this unusual occurrence.

INTRODUCTION

Pituitary apoplexy is a life-threatening complication of pituitary adenoma. Risk factors for pituitary apoplexy are hypertension, diabetes mellitus, acute hypovolemic shock, major surgery, pregnancy, dynamic hormone testing, anticoagulant use and dopamine agonist therapy for prolactinoma [1]. The octreotide therapy in growth hormone (GH)-secreting adenoma is currently indicated for postoperative hormone hypersecretion or refusal of surgery. The use of somatostatin receptor ligand octreotide can cause tumour shrinkage and biochemical remission in patients with acromegaly. Pituitary apoplexy may be a rare complication

of long-acting octreotide therapy. Our case highlights the rarity and clinical importance of this unusual occurrence.

CASE REPORT

An 18-year-old boy had a history of coarse facies, enlargement of hands and feet for 1 year. He presented with severe headache, recurrent vomiting and blurring of vision for 5 days in the emergency department. The blood pressure was 126/54 mmHg. The general physical examination showed prominent frontal ridges, large fleshy lips, large hands and feet. The fundus examination

Received: December 21, 2015. Revised: February 2, 2016. Accepted: February 3, 2016

© The Author 2016. Published by Oxford University Press.

This is an Open Access article distributed under the terms of the Creative Commons Attribution Non-Commercial License (<http://creativecommons.org/licenses/by-nc/4.0/>), which permits non-commercial re-use, distribution, and reproduction in any medium, provided the original work is properly cited. For commercial re-use, please contact journals.permissions@oup.com

showed bilateral papilledema. Perimetry examination revealed visual field constriction in both eyes suggestive of bitemporal hemianopia. Rest of the examinations were normal.

Haemogram and biochemical parameters including electrolytes were normal. The hormone profile study showed hypersomatotropism with secondary hypopituitarism (Table 1). The magnetic resonance imaging (MRI) of brain showed sellar mass (3.2 × 3.0 × 3.2 cm) which extended to suprasellar area and compressed bilateral optic nerve and optic chiasma (Fig. 1). The patient was diagnosed as acromegaly due to pituitary macroadenoma. He was started on levothyroxine, steroid and subcutaneous octreotide (100 µg thrice a day). Within a week, the patient had significant improvement in headache and visual blurring. Transsphenoidal surgical removal of the macroadenoma was planned but unfortunately the patient did not give consent for surgery. Predicted response to somatostatin analogue therapy was expected to be small due to the patient's age, gender and invasive character of the large macroadenoma. However, the patient showed remarkable improvements in symptoms following subcutaneous octreotide injections and was therefore started on intramuscular long-acting octreotide 20 mg once monthly.

After 3 months of octreotide [long-acting release (LAR) depot] therapy, the patient had normal visual field and complete resolution of soft tissue changes. Insulin-like growth factor-1 (IGF-1) and GH were 140 and 0.06 ng/ml after glucose load, respectively. The MRI of the brain revealed non-enhancing mixed intensities haemorrhagic and cystic areas of the pituitary gland, which was suggested to be subclinical pituitary apoplexy (Fig. 2). The octreotide LAR injection was stopped. On 6-month follow-up, after 3 months of stopping octreotide therapy, his hormone profile showed normal IGF-1 level and suppressed GH level after glucose load suggestive of biochemical remission (Table 1). The MRI of the brain shows non-enhancing mixed intensities cystic areas in the pituitary gland. On 2-year follow-up, the patient is symptoms free on levothyroxine (75 µg) and prednisolone (5 mg) once daily.

DISCUSSION

Pituitary apoplexy is characterized by abrupt onset of haemorrhage or non-haemorrhagic infarction of a pituitary adenoma [1, 2]. It may cause life-threatening pituitary dysfunction. The other clinical features include severe headache, visual field defects, meningeal irritation and ophthalmoplegia though it can be clinically silent too. Risk factors for pituitary apoplexy

are hypertension, diabetes mellitus, acute hypovolemic shock, major surgery, pregnancy, dynamic hormone testing, anticoagulant use and dopamine agonist therapy. The spontaneous remission of acromegaly following pituitary apoplexy has been previously reported, but incidence of apoplexy following octreotide therapy is very rare [3, 4]. Three cases of pituitary apoplexy with long-acting octreotide therapy in pituitary acromegaly have been reported. However, contrary to our case, all those three patients had predisposing risk factors for apoplexy [5–7]. One patient was on bromocriptine therapy, which was a risk factor for apoplexy in prolactinoma. Another patient had severe hypertension and presented with pituitary apoplexy after a single injection of long-acting octreotide. The third case was mentioned in series of acromegaly, but no details were available. Bakiri et al. [8] reported four cases of pituitary apoplexy associated with lanreotide autogel preparation. Also, in their case series, all four patients had associated risk factors for apoplexy. Two patients had severe hypertension, one was on anticoagulant and one had deep venous thrombosis before the initiation of lanreotide autogel therapy.

The hypotheses regarding the pathophysiology of pituitary apoplexy may be explained by various mechanisms. The rapidly growing pituitary adenoma can outstrip its blood supply and lead to vascular compromise and infarction. Another theory suggests that growing tumour may cause angiogenesis and formation of fragile blood vessels, which leads to haemorrhage. The expanding tumour mass may compress the pituitary infundibulum and compromise the blood flow from the portal vessels, resulting in necrosis of the entire gland with haemorrhage as a consequence. The dopamine agonist therapy has been postulated to

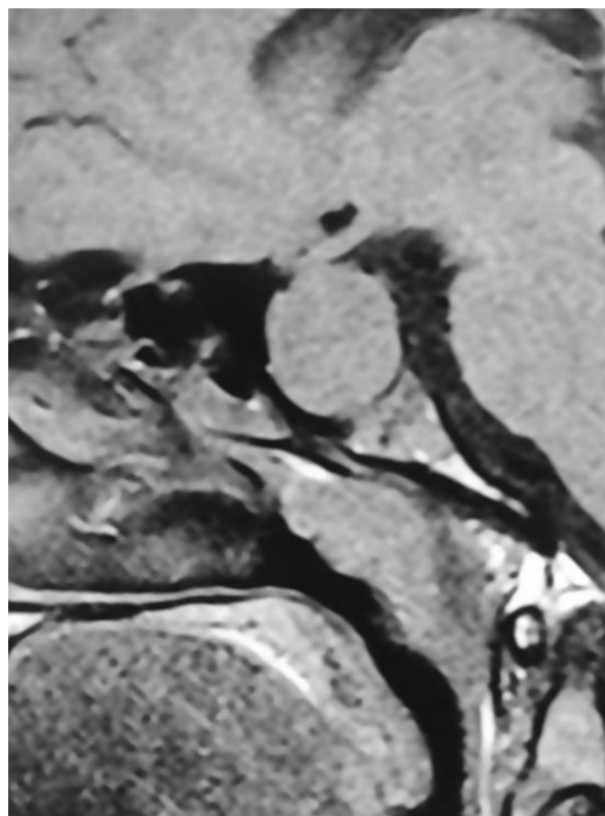


Figure 1: MRI of the brain shows 3.2 × 3.0 × 3.2 cm sellar mass (pituitary macroadenoma) with suprasellar extension, compression of the bilateral optic nerve and optic chiasma.

Table 1: Hormonal profile at start and stopping of octreotide therapy

Hormone profile	At the time of therapy	After stopping therapy
T3 (ng/dl)	115	104
T4 (µg/dl)	3.54	9.36
Thyroid stimulating hormone (µIU/ml)	0.19	0.242
Basal cortisol (µg/dl)	3.64	
Prolactin (ng/ml)	30	15.5
Luteinizing hormone (mIU/ml)	1.2	4.2
Testosterone (ng/dl)	389	620
IGF-1 (ng/ml)	1890	138
Basal GH (ng/ml)	31.6	
GH suppression test (ng/ml)	8.8	<0.05

TSH: Thyroid stimulating hormone, LH: Luteinizing hormone, IGF-1: Insulin-like growth factor-1, GH: Growth hormone.

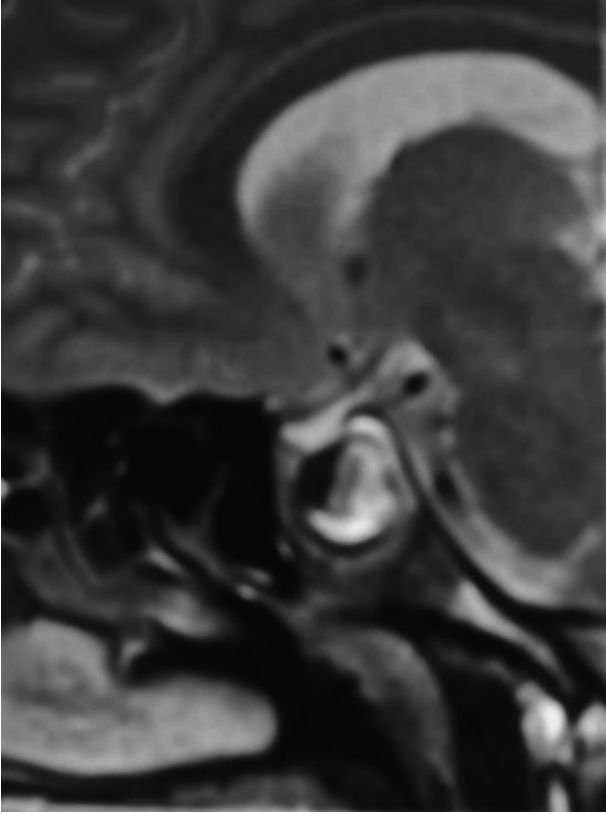


Figure 2: MRI of the brain shows non-enhancing mixed intensities haemorrhagic and cystic areas in the pituitary gland.

cause pituitary apoplexy by a rapid decrease in tumour size and inhibition of angiogenesis, which results in necrosis and haemorrhagic transformation of prolactinoma in patients who are already at risk for haemorrhagic transformation. Our patient did not have any associated risk factors for pituitary apoplexy. He developed subclinical apoplexy following octreotide therapy, which may point towards a role of octreotide in the sequence of events. In our patient, rapid normalization of IGF-1 level and marked decrease in tumour size may have led to the development of pituitary apoplexy though large retrospective cohort studies are needed to support this assumption. Whether pituitary apoplexy was purely coincidental or result of long-acting octreotide therapy leading to rapid tumour shrinkage and decreased angiogenesis is a subject of debate. But, from the clinical correlation of events in our patient, it seems that apoplexy and remission of the hypersomatotropic state were a result of octreotide therapy. This may probably be a rare side effect of somatostatin analogue therapy. About 5–7% of patients on lanreotide treatment have had pituitary apoplexy and the incidence of the same on octreotide therapy is not known. Hence, patients on octreotide therapy need close clinical, biochemical and radiological monitoring, especially those with risk factors.

To conclude, somatostatin receptor ligand (octreotide) can cause tumour shrinkage, clinical and biochemical remission in patients with acromegaly. One of the rare complications of octreotide therapy can be pituitary apoplexy. Rapid normalization of IGF-1 and marked reduction in tumour size are postulated to be cause of pituitary apoplexy in our case. Our case highlights

the importance of this rare side effect of octreotide therapy in acromegalic patients.

AUTHORS' CONTRIBUTIONS

All the authors contributed to prepare this study.

CONFLICT OF INTEREST STATEMENT

None declared.

FUNDING

No funding to report.

ETHICAL APPROVAL

We have followed the ethical norms and have taken proper informed consent from the patient and relatives. Our patient participated voluntarily and did not suffer any harm. We confirm that all the research meets the ethical guidelines, including adherence to the legal requirements of the study country.

CONSENT

We have obtained written, informed patient consent for publication of the report and any accompanying images.

GUARANTOR

S.K. is a guarantor of this study.

REFERENCES

1. Nawar RN, Abdel-Mannan D, Selma WR, Arafah BM. Pituitary tumor apoplexy: a review. *J Intensive Care Med* 2008;23:75–89.
2. Carija R, Vucina D. Frequency of pituitary tumor apoplexy during treatment of prolactinomas with dopamine agonists: a systematic review. *CNS Neurol Disord Drug Targets* 2012; 11:1012–4.
3. Fraser LA, Lee D, Cooper P, Van Uum S. Remission of acromegaly after pituitary apoplexy: case report and review of literature. *Endocr Pract* 2009;15:725–31.
4. Roerink SH, van Lindert EJ, van de Ven AC. Spontaneous remission of acromegaly and Cushing's disease following pituitary apoplexy: two case reports. *Neth J Med* 2015;73:242–6.
5. Abe T, Ludecke DK. Effects of preoperative octreotide treatment on different subtypes of 90 GH-secreting pituitary adenomas and outcome in one surgical centre. *Eur J Endocrinol* 2001;145:137–45.
6. Boulis NM, Noordmans AJ, Barkan A, Hassing J, Chandler WF. Somatotropinoma infarction during octreotide therapy leading to bilateral cavernous sinus syndrome. *Pituitary* 2000;3:185–8.
7. Chang CV, Felicio AC, Nunes VDS, Da Cunha-Neto MBC, De Castro AVB. Pituitary apoplexy after a single dose of long-acting octreotide. *Endocrinologist* 2010;20:15–6.
8. Bakiri F, Herrera J, Riestra M, Perrichot O, Pertierra J, Bruno OD, et al. Pituitary apoplexy after somatostatin analogue administration: coincidental or causative? *Clin Endocrinol (Oxf)* 2014;81:471–3.