



Original Article

Different anatomical sites of the foreign body injury with 2999 children during 2012–2016

Shan He ^a, Ze-Lan Zuo ^{b, c, *}^a Chongqing Medical University, Chongqing, 400014, China^b Department of PICU, Children's Hospital of Chongqing Medical University, Ministry of Education Key Laboratory of Child Development and Disorders, Chongqing, 400014, China^c China International Science and Technology Cooperation Base of Child Development and Critical Disorders, Chongqing Key Laboratory of Pediatrics, Chongqing, 400014, China

ARTICLE INFO

Article history:

Received 2 May 2018

Received in revised form

2 June 2018

Accepted 31 July 2018

Available online 12 December 2018

Keywords:

Children

Clinical characteristics

Different types

Foreign body injury

ABSTRACT

Purpose: This study aimed to analyze the clinical characteristic of different foreign body injuries in children and offer the preventions.**Methods:** A retrospective study and the demographic information, injury causes, foreign body injury types and other clinical factors were recorded and analyzed.**Results:** Of the 2999 patients, 1877 (62.6%) were boys and 1122 (37.4%) were girls. The majority (72.8%, $n = 2184$) of the injuries were found in 1–3 years old children. The most common anatomical site was the respiratory tract (73.4%, $n = 2201$) followed by the digestive tract (18.6%, $n = 558$), the genitourinary tract (1.93%, $n = 58$) and other sites (6.07%, $n = 182$). There were 60.4% of the in-patients from rural areas and 53.2% of the patients without medical insurance, the rate of cost by medical insurance increased with age. The medians of length of hospital stay and hospitalization cost were four days and 4767.3 CNY respectively. Most of the patients had surgical treatment (90.6%, $n = 2717$) and 64.9% of them had the complications ($n = 1946$). The cure rates of the all foreign body injuries types were above 90%, especially in genitourinary tract (98.3%). **Conclusion:** Different types of the foreign body injuries had dissimilar clinical characteristics. The effective prevention and control measures should be taken according to the variety of high-risk population, incidence season and foreign body injury types.

© 2018 Daping Hospital and the Research Institute of Surgery of the Third Military Medical University.

Production and hosting by Elsevier B.V. This is an open access article under the CC BY-NC-ND license (<http://creativecommons.org/licenses/by-nc-nd/4.0/>).

Introduction

Childhood injury is a major public health problem that requires urgent attention, responsible for about 950,000 deaths in children and young people under the age of 18 years each year, unintentional injuries account for almost 90% of these cases.^{1,2} The Chinese health yearbook statistic show that unintentional injuries are the capital cause of death for 1–15 years old children, foreign body injury is an indispensable part of unintentional injury.³

There is no wide understanding about the epidemiology of foreign body injuries in children.⁴ A six-year study show that the incidence of foreign body injuries up to 29.2 per 100,000.⁵ Foreign object varies a lot and the clinical characteristics also vary among

the different foreign body injuries. It is frequently happening in children and easily ignored by the child's keeper.⁶ In most of the cases, foreign body injuries often lack of obviously symptoms at the beginning, with the related symptoms gradually appear, the best treatment time is missing, which increased the difficulty of diagnosis, caused the complications and even fatal.

The aim of this study was to analyze the epidemiology of foreign bodies entering through natural orifices and trend analyses of the foreign body injury in children and provide basic information for the decision-making processes of relevant state departments to facilitate the timely development of effective preventive measures.

Methods

The study was performed in Children's Hospital of Chongqing Medical University (CQMU). Data was collected during 1 January 2012 to 31 December 2016. All cases of the foreign body injury were diagnosed according to the International Classification of Diseases, 10th Revision, Clinical Modification (ICD-10-CM). The diagnoses

* Corresponding author. Department of PICU, Children's Hospital of Chongqing Medical University, Ministry of Education Key Laboratory of Child Development and Disorders, Chongqing, 400014, China.

E-mail address: zuozelan@126.com (Z.-L. Zuo).

Peer review under responsibility of Daping Hospital and the Research Institute of Surgery of the Third Military Medical University.

including all foreign bodies entering through natural orifices were included. Medications taken improperly, and ingested liquid chemicals were not included. The study center ranked No.3 in China and located best pediatric medical level in the south-western of China, almost half of patients came from adjacent provinces: Sichuan, Guizhou, Yunnan, Hu'nan, Hubei, Fujian, An'hui.

There were in total 2999 patients <16 years of age identified during the 5-year study period, who were admitted to the hospital for foreign body injury. All patients' data were collected from the hospital information system (HIS) and include ID number, name, age, gender, place of residence, keeper, happened date, cost and duration of hospitalization, cause, type of foreign objects and site, clinical treatment, complication and outcome.

Statistical collection was performed with the Microsoft Excel chart from the HIS by seven people, who have been accepted the centralized train. IBM SPSS Statistics software, version 23.0, was used for the analysis. Background characteristics are presented as frequencies and mean values with the standard deviation (SD) for normally distributed variables and as medians for non-normally distributed variables. Patient age was classified into four groups: <1, 1–3, 4–6, and >6 years. Different sites of foreign body injuries were classified into four groups: respiratory tract, digestive tract, genitourinary tract and other sites. Frequency analyses were performed using Pearson's chi-squared test. Subgroups were compared by using non-parametric tests (Kruskal-Wallis H test and Pearson's chi-squared test). *p*-value of <0.05 was taken to be statistically significant.

Results

Demographics

A total of 2999 patients were hospitalized with foreign body injuries from 1 January 2012 to 31 December 2016. Among them, 1877 (62.6%) were male and 1122 (37.4%) were female, a male-to-female ratio is 1.67:1. The median age was 1 years, ranging from 19 days to 15 years. The majority (72.8%, *n* = 2184) of the injuries were found in 1–3 years old children. There were 60.4% of the in-patients from

rural areas. In different age groups, main keepers were the parents. Among 89 cases of grandparents as the keeper, children 1–3 years accounted for 91.01%, living in rural (76.40%). Almost a half (53.2%, *n* = 1596) of cases paid the hospitalization cost with no medical insurance, the rate of all medical insurance was gradually increased with the age group from 36.9% to 60.7%. The highest proportion (80.37%, *n* = 2010) of foreign objects in the young children (0–3 years) were edible, especially was all kinds of nuts (71.21%, *n* = 1781); most (66.47%, *n* = 331) of foreign objects were inedible in the 4 years and elder children (Table 1). The number of patient from Chongqing and other provinces with foreign body injury admitted in Children's Hospital of CQMU during 2012–2016 (Fig. 1)

Anatomical site

According to the anatomical site, all foreign bodies entering through natural orifices were divided into four types: respiratory tract (73.4%, *n* = 2201), digestive tract (18.6%, *n* = 558), genitourinary tract (1.93%, *n* = 58) and other sites (6.07%, *n* = 182). Other sites included nose (0.93%, *n* = 28), ear (1.77%, *n* = 53), eye (0.60%, *n* = 18), throat (0.80%, *n* = 24) and soft tissue (1.97%, *n* = 59). There were different consist of age group among different sites of the foreign body injury, the most common anatomical site of foreign part was soft tissue (32.30%, *n* = 19) in children 6 years old, ear (54.72%, *n* = 29) in children 4–6 years old respectively, other sites were 1–3 years old. There was a statistically significant difference in the different anatomical site of foreign bodies between the genders (*p* < 0.01). Boys were over-represented (62.6%) in total but the girls took 93.10% of foreign body injuries to genitourinary tract. Foreign body injuries happened at respiratory tract were high-occurrence in winter and caused by edible objects, the digestive tract was more often occurred in summer and caused by inedible objects, the genitourinary tract was more often occurred in autumn and caused by inedible objects (Table 2). Edible objects consisted of nuts, meat spur, rice, hard fruit; inedible objects included small toy or plastic parts of toy, coins, button battery, stone and unspecific metallic particle of various home appliances or metallic waste. The month trend of different anatomical site of the foreign body injury (Fig. 2).

Table 1
Different age group foreign body injury cases analysis, *n* (%).

Variable	Age group (year)				Total	χ^2/H value	<i>P</i> value
	< 1	1–3	4–6	> 6			
Gender						5.303	0.151
Boy	201 (63.4)	1367 (62.6)	171 (58.0)	138 (68.0)	1877 (62.6)		
Girl	116 (36.6)	817 (37.4)	124 (42.0)	65 (32.0)	1122 (37.4)		
Residence						9.792	0.02
Urban	103 (32.5)	885 (40.5)	126 (42.7)	73 (36.0)	1187 (39.6)		
Rural	214 (67.5)	1299 (59.5)	169 (57.3)	130 (64.0)	1812 (60.4)		
Keeper						3.035	0.219
Parents	314 (99.1)	2096 (96.0)	291 (98.7)	199 (98.0)	2900 (96.7)		
Grandparents	3 (0.9)	81 (3.7)	3 (1.0)	2 (1.0)	89 (3.0)		
Others	0 (0)	7 (0.03)	1 (0.03)	2 (1.0)	10 (0.3)		
Payment ^a						33.45	< 0.01
1	83 (26.2)	698 (32.0)	111 (37.6)	88 (43.4)	980 (32.7)		
2	32 (10.1)	280 (12.8)	42 (14.3)	31 (15.3)	385 (12.8)		
3	200 (63.1)	1179 (54.0)	137 (46.4)	80 (39.3)	1596 (53.2)		
4	2 (0.6)	27 (1.2)	5 (1.7)	4 (2.0)	38 (1.3)		
Foreign object						501.857	< 0.01
Nut	177 (55.8)	1604 (73.4)	88 (29.8)	19 (9.4)	1888 (63.0)		
Meat spur	34 (10.7)	61 (2.8)	6 (2.0)	19 (9.4)	120 (4.0)		
Other edible	31 (9.8)	103 (4.7)	7 (2.4)	6 (3.0)	147 (4.9)		
Plastic	5 (1.6)	35 (1.6)	47 (15.9)	61 (30.0)	148 (4.9)		
Metallic	52 (16.4)	309 (14.2)	100 (33.9)	54 (26.6)	515 (17.2)		
Undefined	5 (1.6)	37 (1.7)	35 (11.9)	34 (16.7)	111 (3.7)		
Self cough/discharge	13 (4.1)	35 (1.6)	12 (4.1)	10 (4.9)	70 (2.3)		

^a Payment: 1 Medical insurance in cities and towns; 2 rural cooperative medical insurance; 3 own expense; 4 others.

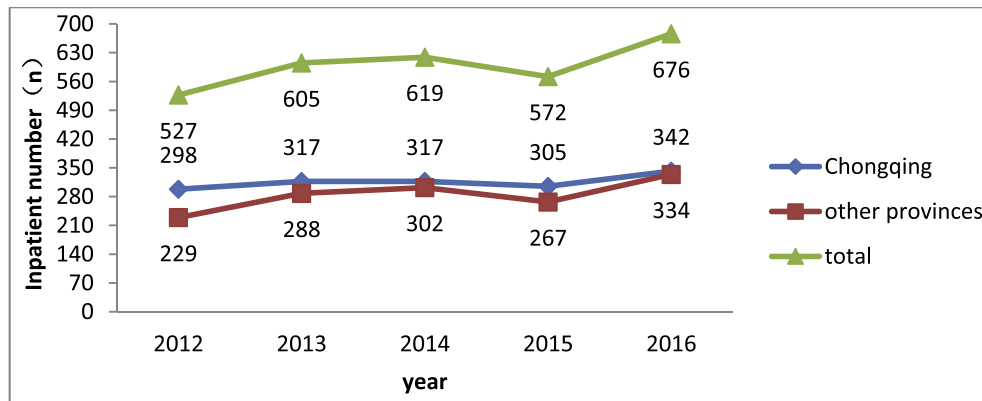


Fig. 1. Inpatient number of foreign body injury in Children's Hospital of CQMU during 2012–2016.

Clinical outcome

There was no statistically significant difference in curing rate among the four types of foreign bodies ($p = 0.101$). The cure rates of different types were all above 90%, especially in genitourinary tract up to (98.3%). In total, 90.60% ($n = 2717$) of all patients with a foreign body required surgical intervention, there were 21 patients out of 2717 patients (0.77%) required re-operation, 85.71% ($n = 18$) in respiratory tract injury, 9.52% ($n = 2$) in digestive tract, 4.76% ($n = 1$) in genitourinary tract injury. Only the complication rate of respiratory tract foreign body injury was over the half (79.33%, $n = 1746$). The data composition in surgical operation and complication of the foreign body injuries (Fig. 3). Five children died due to foreign body injuries in this study, 4 children died for the respiratory tract foreign body injury, one child died for the digestive tract foreign body injury. The medians of length of hospital stay and hospitalization cost were four days and 4767.3 CNY respectively (Table 2).

Discussion

Boys are more likely to present with foreign bodies in mostly body sites, this result was consistent with the other studies from Beijing, Shanghai, Hunan provinces,^{6–8} it may because boys are more active and have a wide range of activities compare with girls, which made them more prone to injuries.⁹ In addition, we find that the highest proportion (93.1%) of genitourinary tract foreign body injury occurred in girls, and children are curious about the body structure of themselves,¹⁰ because of the anatomical difference in genitourinary tract between boy and girl, which make girls are easier exposing to foreign objects. The rate of the foreign body injury in patients with age range 1–3 years old was higher than other age groups. The most common injury sites were respiratory tract and followed by digestive tract. The quantity of foreign body injuries decreased with the aging, while the variety increased. Foreign objects in the young children (0–3 years) mainly are edible food, like all kinds of nuts and their shells, while small toys

Table 2

Different anatomical site of foreign body injury clinical characteristics, n (%).

Variable	Sites				Total	χ^2/H value	P value
	Respiratory tract	Digestive tract	Genitourinary tract	Other sites			
Age group (year)						401.045	< 0.01
< 1	248 (11.3)	54 (9.7)	0 (0)	15 (8.3)	317 (10.6)		
1–3	1758 (79.9)	336 (60.2)	21 (36.2)	69 (37.9)	2184 (72.8)		
4–6	120 (5.4)	100 (17.9)	18 (31.0)	57 (31.3)	295 (9.8)		
> 6	75 (3.4)	68 (12.2)	19 (32.8)	41 (22.5)	203 (6.8)		
Gender						88.949	< 0.01
Boy	1419 (64.5)	326 (58.4)	4 (6.9)	128 (70.3)	1877 (62.6)		
Girl	782 (35.5)	232 (41.6)	54 (93.1)	54 (29.7)	1122 (37.4)		
Season						145.249	< 0.01
Spring	567 (25.8)	135 (24.2)	13 (22.4)	28 (15.4)	743 (24.8)		
Summer	339 (15.4)	182 (32.6)	16 (27.6)	55 (30.2)	592 (19.7)		
Autumn	540 (24.5)	144 (25.8)	21 (36.2)	58 (31.9)	763 (25.4)		
Winter	755 (34.3)	97 (17.4)	8 (13.8)	41 (22.5)	901 (30.0)		
Foreign object						1952.25	< 0.01
Edible	2049 (93.1)	52 (9.3)	17 (29.3)	37 (20.3)	2155 (71.9)		
Inedible	109 (5.0)	497 (89.1)	38 (65.5)	130 (71.4)	774 (25.8)		
Other	43 (2.0)	9 (1.6)	3 (5.2)	15 (8.2)	70 (2.3)		
Clinical outcome						4.307	0.101
Cure	2134 (97.0)	535 (95.9)	57 (98.3)	171 (94.0)	2897 (96.6)		
Incomplete-cure	63 (2.8)	22 (3.9)	1 (1.7)	11 (6.0)	97 (3.2)		
Death	4 (0.2)	1 (0.2)	0 (0)	0 (0)	5 (0.2)		
Day (day) ^a	4 (3–5)	2 (1–3)	3 (2–5)	3 (2–5)	4 (3–5)	545.719	< 0.01
Cost (CNY) ^a	4972.4 (4366.2–5961.0)	3194.5 (2689.6–4060.1)	4495.1 (3745.9–5724.2)	4420.4 (3043.1–6435.7)	4767.3 (3841.7–5733.0)	546.22	< 0.01

^a Data are expressed as mean (range).

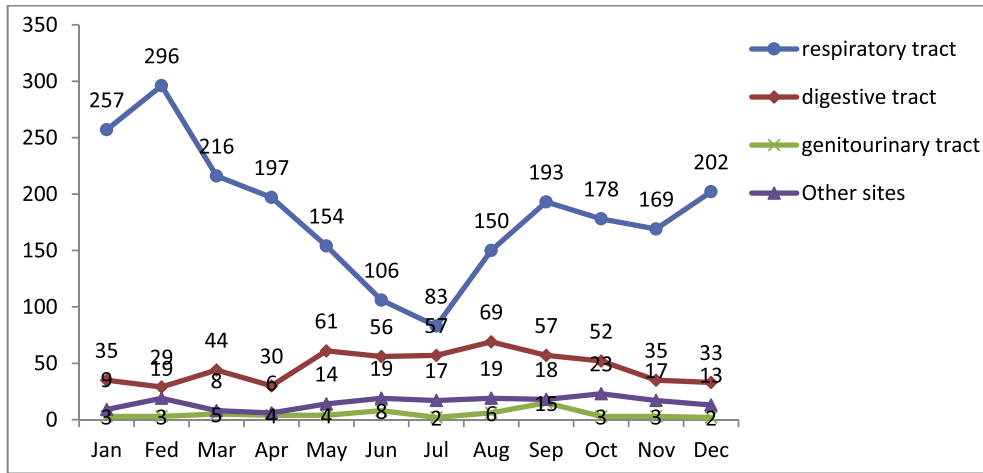


Fig. 2. The month trend of different anatomical site of foreign body injury.

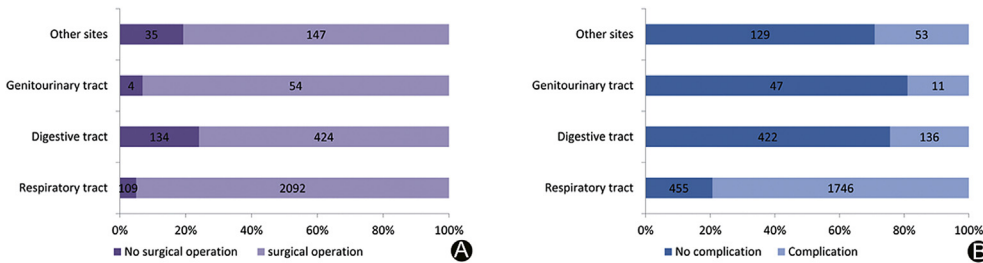


Fig. 3. A: Composition of surgical operation in different anatomical sites of foreign body injury. B: Composition of complication in different anatomical sites of foreign body injury.

or plastic parts of toy, coins, and button batteries take the main reason in the 4 years and elder children. Children always like to pick up things and feed themselves, they can't distinguish the danger.

The foreign body injury of respiratory tract is a common severe and critical disease in department of ear, nose and throat (ENT) and most of the cases' symptoms are not specific to notice. The condition is easy to change, and the complications are various and complex. It is the main reason for the death of young children due to unintentional injury.¹¹ Our study shows the mortality of foreign body injury happened in respiration tract is 0.18% ($n = 4$), rate of complications is 79.33% ($n = 1746$). The main complications are pneumonia and bronchitis. 55%–95% of respiratory foreign body events occurred in children under 3 years old.^{12–14} Foreign objects for children usually are different kinds of food, especially nuts. Eating nut is easy to cause choke, however, a simple cough was easily ignored by the keepers, when the children spit out a part of the foreign body with coughing which made an illusion that foreign body has been completely coughing out.¹⁵

The foreign body injury of the digestive tract includes the esophagus and gastrointestinal tract injuries. The children's narrow esophagus are more likely to be blocked with foreign body when there is esophagospasm caused by irritating.¹⁶ The main foreign objects are coins and button batteries. Intaking button battery can develop other perilous complications through different mechanisms: electrical discharge and the creation of hydroxide ions can cause mucosal burn, direct pressure can cause necrosis, leakage of alkalis can cause burns, and minor risk of mercury toxicity.¹⁷ Most of the gastrointestinal foreign bodies can be self-discharged without special treatment, some of the upper gastrointestinal foreign bodies can be removed by gastroscopy, but a few foreign bodies can cause serious

complications such as gastrointestinal perforation.¹⁸ If children swallowed button battery or sharp foreign body, the objects should be taken out with endoscope immediately.¹⁹ The result shows the mortality of the foreign body injury happened in digestive tract is 0.18% ($n = 1$), the rate of complications is 24.37% ($n = 136$).

The foreign body injury of genitourinary tract only happened to girls, which often occurs in autumn, while the incidence of complications was the lowest among other types of the foreign body injury (18.67%, $n = 11$). The main foreign objects are grain, plastic toys and stationery components. Its symptoms are usually bleeding, pain and observed foreign objects, which are different from the respiratory and digestive tract foreign body injury. Common symptoms, like symptoms of upper respiratory tract infection and general gastrointestinal, are difficult to diagnose with foreign body injury history in unknown children, result in the difficult diagnosis and complex treatment.

Early prevention is very important to reduce the foreign body injury in children. Therefore, safety awareness must be cultivated. Education on the dangers of small objects which children can touch in a variety of ways might help reduce the foreign body injury. Toys, food, coins and other miscellaneous objects at home, all of them are the risk items for causing the foreign body accidents, should be stored out of young children's reach. Parents or keepers should help children to develop a good eating habits that no playing and talking on the table. Moreover, the keepers should also strengthen their supervision consciousness. When injury happened, the keeper has to send the injured child to hospital as soon as possible. Reasonable treatment can avoid further damage. Integration of simple guidelines for parents into existing primary prevention programs, such as the previously mentioned or simply in the primary care setting, might be a good step forward.

Overall, there are dissimilar clinical characteristics among foreign body injury in different sites, prevention is the key to reduce the incidence of the foreign body injury. The point should be focused on the people, season, types and foreign object.

Fund

This research did not receive any specific grant from funding agencies in the public, commercial, or not-for-profit sectors.

Acknowledgements

We thank doctors Xing Deng, Li Yan, Dong Li, Qiaoying Zhang, Ting Xu, Yaru Li for data collection.

References

1. WHO. *The Global Burden of Disease*; 2004. http://202.202.224.38:9999/www.who.int/healthinfo/global_burden_disease/GBD_report_2004update_full.pdf?ua=1.
2. Peden M, Oyegbite K, Ozanne-Smith J, et al. *World Report on Child Injury Prevention*. Geneva: World Health Organization; 2008.
3. National Health and Family Planning Commission. *China Health and Family Planning Statistical Yearbook*. Beijing: Peking Union Medical College press; 2014.
4. Timmers M, Snoek KG, Gregori D, et al. Foreign bodies in a pediatric emergency department in South Africa. *Pediatr Emerg Care*. 2012;28:1348–1352. <https://doi.org/10.1097/PEC.0b013e318276c20e>.
5. Sinikumpu JJ, Serlo W. Confirmed and suspected foreign body injuries in children during 2008–2013: a hospital-based single center study in Oulu university hospital. *Scand J Surg*. 2017;106:350–355. <https://doi.org/10.1177/1457496916688139>.
6. Tu J, Chen h, Wu ZM, et al. Characteristics of hospitalized cases of foreign body injuries in a children's hospital in Hunan province in 2010–2014 years. *Chin J Dis Control Prev*. 2016;20:387–391. <https://doi.org/10.16462/j.cnki.zhjbkz.2016.04.016>.
7. Wang WC, Zhang YX. Clinical investigation and analysis of child accidental injuries in some parts of Shanghai. *Chin J Child Heal Care*. 2014;22:865–868. <https://doi.org/10.11852/zgetbjzz2014-22-08-26>.
8. Han K, Xiang X, Wang S, et al. 7334 cases of hospitalized children injury epidemiological characteristics analysis in Beijing of China. *Chin J Dis Control Prev*. 2015;19:431–434. <https://doi.org/10.16462/j.cnki.zhjbkz.2015.05.001>.
9. Gyedu A, Nakua EK, Otupiri E, et al. Incidence, characteristics and risk factors for household and neighborhood injury among young children in semiurban Ghana: a population-based household survey. *Inj Prev*. 2015;21:e71–e79. <https://doi.org/10.1136/injuryprev-2013-040950>.
10. Surya M, Sharma C, Sood D, et al. Neglected vaginal foreign body leading to vaginolith, vesicovaginal fistula and vesical calculus formation in an adolescent girl. *BJR Case Rep*. 2016;2. <https://doi.org/10.1259/bjrcr.20150474>, 20150474.
11. Kuang YT, Zhao SJ, Huang M. Diagnosis and treatment of special types of respiratory foreign bodies in children. *J Clin Pediatr Surg*. 2015;14:528–530. <https://doi.org/10.3969/j.issn.1671-6353.2015.06.020>, 536.
12. Jaswal A, Jana U, Maiti PK. Tracheo-bronchial foreign bodies: a retrospective study and review of literature. *Indian J Otolaryngol Head Neck Surg*. 2014;66:156–160. <https://doi.org/10.1007/s12070-011-0386-4>.
13. Sidell DR, Kim IA, Coker TR, et al. Food choking hazards in children. *Int J Pediatr Otorhinolaryngol*. 2013;77:1940–1946. <https://doi.org/10.1016/j.ijporl.2013.09.005>.
14. Mallick MS. Tracheobronchial foreign body aspiration in children: a continuing diagnostic challenge. *Afr J Paediatr Surg*. 2014;11:225–228. <https://doi.org/10.4103/0189-6725.137330>.
15. Tian YQ. *Otolaryngology Head and Neck Surgery*. Beijing: People's Health Press; 2010:258–261.
16. Zhang YM, Zhang TY. *Practical Science of Otolaryngology for Children*. Beijing: People's Health Press; 2011:424.
17. Liu J, Jiang Y, Han M, et al. Clinical diagnosis and treatment of children's esophageal foreign body button cell. *J Clin Otorhinolaryngol Head Neck Surg*. 2017;31:1521–1523. <https://doi.org/10.13201/j.issn.1001-1781.2017.19.014>.
18. Zhu ZC, Yan XQ, Yang J, et al. Clinical analysis of 12 cases with digestive tract perforation caused by foreign body ingestion in children. *J Peking Univ (Heal Sci)*. 2017;5:924–926. <https://doi.org/10.3969/j.issn.1671-167X.2017.05.033>.
19. Jayachandra S, Eslick GD. A systematic review of paediatric foreign body ingestion: presentation, complications, and management. *Int J Pediatr Otorhinolaryngol*. 2013;77:311–317. <https://doi.org/10.1016/j.ijporl.2012.11.025>.