

# The effect of vitamin A and vitamin C on postoperative adhesion formation: A rat model study

Behrouz Keleidari, Mohsen Mahmoudieh, Faranak Bahrami, Pejman Mortazavi<sup>2</sup>, Reza Sari Aslani<sup>1</sup>, Seyed Alireza Toliyat<sup>1</sup>

Departments of Surgery, Faculty Member of General Surgery, Isfahan University of Medical Sciences, Isfahan, <sup>1</sup>Departments of Surgery, Resident of General Surgery, Isfahan University of Medical Sciences, Isfahan, <sup>2</sup>Departments of Pathobiology, Veterinary, Sciences, Science and Research Branch, Faculty Member of Islamic Azad University, Tehran, Iran

**Background:** The aim of this study is to investigate the effect of vitamin A and C, as the agents that improve wound healing, on the adhesion formation process. **Materials and Methods:** Sixty male Wistar rats were used. They underwent midline laparotomy, for repair of a peritoneal injury, and were then assigned to four groups. Group 1 (Vitamin A) received 2000 units/kg intramuscular injection of vitamin A daily, post surgery, for two weeks; Group 2 (Vitamin C) received 100 mg/kg oral vitamin C daily, after laparotomy, for two weeks; Group 3 (vitamins A and C) received 2000 units/kg intramuscular injection of vitamin A and 100 mg/kg oral vitamin C daily, after laparotomy, for two weeks, and Group four (Sham) rats did not receive any drugs. The adhesion, inflammation, fibrosis scores, and wound integrity were evaluated after two weeks. **Results:** Rats in the vitamin C group had the lowest mean adhesion formation score ( $1 \pm 0.27$ ) and the values of  $p$  were  $< 0.0001$  for the vitamin A group and vitamin A and C groups and  $0.003$  for the sham group. Vitamin C also had the lowest fibrosis score ( $0.50 \pm 0.17$ ) among the study groups and the values of  $p$  were  $< 0.0001$  for the vitamin A group and vitamin A and C groups and  $0.002$  for the sham group. The mean inflammation score did not differ significantly among the study groups. The wound disruption strength was the highest in the vitamin C group and the difference was statistically significant in the sham group ( $1188.69 \pm 281.92$  vs.  $893.04 \pm 187.46$ ,  $p : 0.003$ ). **Conclusion:** Administration of oral vitamin C reduces adhesion formation and improves wound healing

**Key words:** Adhesion formation, vitamin A, vitamin C

**How to cite this article:** Keleidari B, Mahmoudieh M, Bahrami F, Mortazavi P, Sari Aslani R, Toliyat SA. The effect of vitamin A and vitamin C on postoperative adhesion formation: A rat model study. *J Res Med Sci* 2014;19:28-32.

## INTRODUCTION

Nowadays, postsurgical adhesion formation has become an important challenge in surgery and occurs in almost 97% of all abdominal surgeries.<sup>[1]</sup> Development of adhesion after any surgical process is influenced by various factors, such as, complexity of operation, extent of peritoneal trauma, previous illness, and poor nutritional status.<sup>[2]</sup>

The definite pathogenesis of adhesion formation is not yet clear; however, there are some theories about the role of the immune system, which reveals that severe immune system reaction in response to peritoneal damage is the pathophysiology of adhesion formation.<sup>[3,4]</sup> Another theory in this field deduces that adhesion formation is a pathological part of healing.<sup>[3]</sup>

During abdominal surgery, for prevention of adhesion formation, damage to the peritoneum

and use of foreign body should be decreased and careful hemostasis and repeated irrigation should be performed.<sup>[4]</sup> There are some agents that are used before and after surgery for the purpose of adhesion formation. Attempted drug treatments are antibiotics and immune system inhibitors, such as, corticosteroids, histamine receptor antagonists, vitamins, and hormones.<sup>[4-8]</sup> Although several researches have been performed in this field, an ideal strategy for its prevention is still unknown.

Among the drugs that are mentioned above, recent researches have mainly focused on the inhibition of the inflammatory system.<sup>[4,5,7,9,10]</sup> Although they have mentioned their role in adhesion reduction, the balance between systemic side effects and reduction of adhesion formation is still a major concern.<sup>[3,11-13]</sup>

On the other hand agents that change the healing process may influence adhesion formation; few studies have evaluated this matter.

**Address for correspondence:** Dr. Seyed Alireza Toliyat, Shohadaye Soffeh St, Al Zahra Hospital, Department of Surgery. Isfahan, Iran.  
Email: seyedalirezatoliyat@gmail.com

**Received:** 08-07-2013; **Revised:** 29-07-2013; **Accepted:** 07-09-2013

Vitamin A is an agent known to be required for epithelial tissue development, and it also facilitates normal wound repair.<sup>[14]</sup> Vitamin C is an essential cofactor of collagen synthesis and other components of connective tissues and plays an important role in the wound healing process.<sup>[15]</sup> There is only one study on the role of vitamin A in adhesion formation and there is no data available about the role of vitamin C.<sup>[16]</sup>

Our purpose, in this study, is to evaluate the effect of the optimal healing process (by using Vitamin C and Vitamin A) on post surgery abdominal adhesions and wound integrity.

## MATERIALS AND METHODS

A total of 60 male Wistar rats weighing between 250 to 350 g were used in this study. The rats were housed at a temperature of  $26 \pm 1^\circ\text{C}$  and relative humidity of 40%. All the rats were fed a standard diet and had free access to food and water. The rats were acclimatized to this diet one week before the experiment. Ethical approval for this study was obtained from the Ethics Committee of the Isfahan University of Medical Sciences.

### Experiments

The anesthesia procedure was performed using 0.02 mg/kg intramuscular Acepromazine (Woerden-The Netherlands) and 50 mg/kg Ketamine (Woerden-The Netherlands). The abdomens were shaved and prepared with betadine solution and to remove the powder particles, the gloves were washed with normal saline (Razi-Iran). All the surgical procedures were carried out under sterile conditions. The adhesion formation procedure was performed using the method described by Whang *et al.*<sup>[17]</sup> The rats underwent laparotomy via a 4 cm midline incision. A  $2 \times 2$  cm part of the peritoneum, with the underlying muscle layer, was resected. The cecum was identified and exposed, and an area of serosa measuring  $2 \times 2$  cm was abraded using a gauze until bleeding was observed.<sup>[18]</sup> Then the cecum was returned to its anatomical position and the abdominal cavity was closed in two layers with simple continuous sutures of nylon 3-0 (SUPA-Iran). The rats were randomly assigned to four groups (15 in each group). In group 1 (vitamin A), the rats received 2000 units/kg intramuscular injection of vitamin A (Osveh-Iran) daily, for two weeks, after surgery; in Group 2 (vitamin C), they received 100 mg/kg oral vitamin C (Osveh-Iran) daily, for two weeks, after laparotomy; in the third group (vitamin A and C), the rats received 2000 units/kg intramuscular injection of vitamin A and 100 mg/kg oral vitamin C daily, for two weeks, after laparotomy. In Group 4 (Sham), the rats did not receive any drugs. The doses of drugs that had been used in this study were determined according to those used previously in this field.<sup>[19,20]</sup>

After two weeks, the rats were sacrificed and a U-shaped incision was made under the anesthesia that was described above. Photographs were taken and used for the grading of adhesion by a second surgeon, who was blinded about the drugs that had been used in each rat. The scoring systems that were used in this research project [Table 1] were used in several studies with the same purpose and have been validated within the literature.<sup>[21-23]</sup> In this scoring system [Table 1]: Score 0: No adhesion, score 1: Thin filmy adhesion; score 2: More than one thin adhesion; score 3: Thick adhesion with focal point; score 4: Thick adhesion with planar attachment score 5: Very thick vascularized adhesions or more than one planar adhesion.

### Histopathological examination

Histopathological examinations were performed using light microscopy. The resected tissues, including the adhesion site, adhesion band, and cecal wall were fixed in 10% formalin and embedded in paraffin. The paraffin-embedded tissues were cut into  $5 \mu\text{m}$  slices and sustained with Hematoxylin and eosin and Masson's trichrome dyes and reviewed by a single expert pathologist, who was blinded about the study groups. Fibrosis and inflammation were graded using a semi-quantitative system.<sup>[24]</sup> With regard to the scoring of the inflammation scoring system [Table 1], Score 0: No inflammation; Score 1: Mild inflammation (only a few scattered inflammatory cells were found); Score 2: Moderate inflammation (small groups of inflammatory cells in many high power fields.); Score 3: Severe inflammation (many inflammatory cells in diffuse pattern or in large groups).

Fibrosis was evaluated using the Masson's trichrome sustained sections of the Fibrosis scoring system [Table 1].

**Table 1: Adhesion, fibrosis, and inflammation scoring systems**

	Score	Definition	
Adhesion score	0	No adhesion	
	1	Thin filmy adhesion	
	2	More than one thin adhesion	
	3	Thick adhesion with focal point	
	4	Thick adhesion with planar attachment	
Fibrosis score	0	Small scattered area of green staining	
	1	Thin band of green staining	
	2	Thicker connected band of green staining	
	3	Thick and dense area of green staining	
	Inflammation score	Score	Definition
0		No inflammation	Microscopic findings None
1		Mild inflammation	Only a few scattered inflammatory cells were found
2		Moderate inflammation	Small groups of inflammatory cells in many high power fields
	3	Severe inflammation	Many inflammatory cells in a diffuse pattern or in large groups

Score 0: Small scattered area of green staining; Score 1: Thin band of green staining; Score 2: Thicker connected band of green staining; Score 3: Thick and dense area of green staining.

We also evaluated the Wound disruption strength (F-max) by the method that was first described by Greenhalgh *et al.*<sup>[25]</sup> and has been used in similar studies.<sup>[26]</sup> Skin strips for testing were cut at right angles to the long axis of the wound with cutters. The cutters are dumbbell shaped, with the narrower portion containing the incision, measuring 4 mm across. The wider portions of the skin strips were placed in the jaws of a tensiometer (Zwick-1406) and were stretched at a constant rate (3 cm/minute) until disruption occurred. Wound breaking strength was determined by a digital readout as F-max in cN [Figure 1].

### Sample size and statistical analysis

For the comparison of adhesion, fibrosis, inflammation, and F-max among the study groups, after consultation with the study statistician, the sample size was determined to be 11 in each group, and after considering the post surgery mortality, 15 rats were selected to enroll in each group. Statistical analyses were performed using the statistical software (SPSS version 16.0; SPSS, Inc., Chicago, IL), by ANOVA, and Tukey HSD tests, and  $p < 0.05$  was considered to be significant.

## RESULTS

Of the total of 60 rats in the four groups that were included in the study, nine died in the two-week interim after the first surgery. Three of them belonged to the vit A group, one rat died from the vit C group, three from the vit A and C, and two from the Sham group. The means of variables are shown in Table 2.

After evaluation by the ANOVA test, the analysis of variance showed that there was a statistically significant difference

in the adhesion formation score ( $p < 0.0001$ ) and fibrosis score among the study groups ( $p < 0.0001$ ). Vit C group had the lowest mean adhesion formation score and fibrosis among the study groups. The Tukey test confirmed that this difference was present in comparison with each of the other three groups. Detailed data are shown in Figures 1 and 2.

With regard to the inflammation score, we found that the mean inflammation score was lower in vit C group than in the others, however, this difference was not statistically significant ( $p = 0.558$ ) [Figure 3].

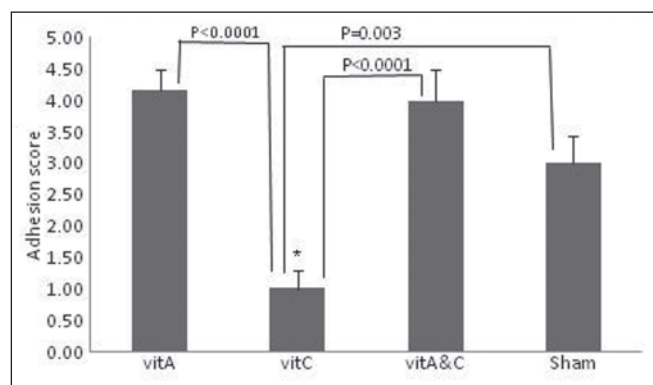
Data analyses showed that the wound disruption strength differed significantly among the study groups ( $p = 0.027$ ) and the Tukey test showed that this difference was significant between the vit C and the Sham groups. More detailed data are given in Figure 4.

## DISCUSSION

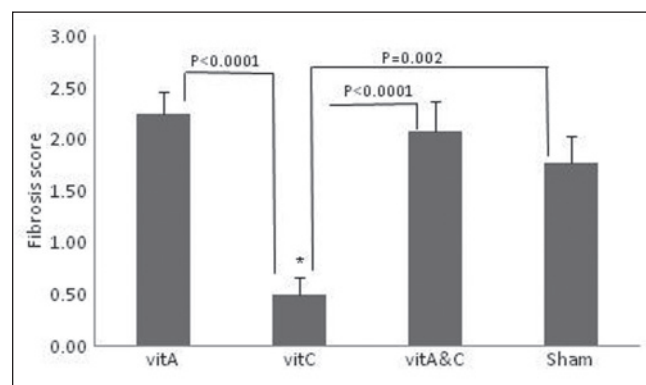
Nowadays, it is recognized that adhesion formation is a part of healing imbalance. In this study we aimed to determine the possible role of vitamin A and C on the postsurgical adhesion formation. We found that administration of oral vitamin C reduced adhesion formation and fibrosis among the study rats, and also, in the vitamin C group, the wound healing that had been evaluated by tensiometry was better than in the other study groups.

**Table 2: Means of variable in different groups**

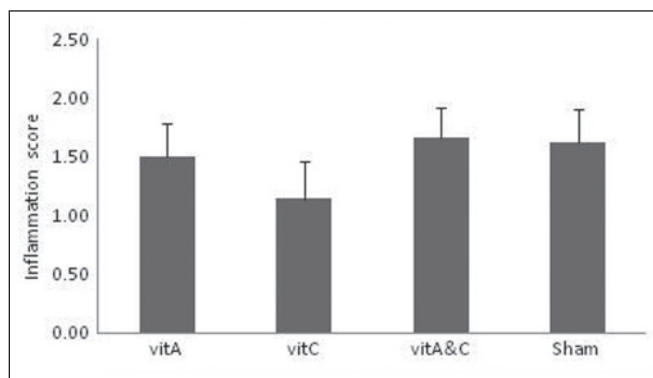
Groups	Adhesion score	Fibrosis score	Inflammation	F max (cN)
Vitamin A	4.17±0.32	2.25±0.21	1.5±0.28	1023.58±53.75
Vitamin C	1±0.29	0.5±0.17	1.14±0.31	1188.70±75.34
Vitamin A and Vitamin C	4±0.49	2.08±0.28	1.67±0.25	1162.49±110.19
Sham	3±0.43	1.77±0.25	1.61±0.28	893.04±51.99
p-value	<0.0001	<0.0001	0.558	0.027



**Figure 1:** Adhesion score among the study groups. Data are presented as mean + standard error. vit A = Vitamin A; vit C = Vitamin C; vit A and C = Vitamin A and vitamin C; sham = Sham group. \*:  $p < 0.05$  considered significant



**Figure 2:** Fibrosis score among study groups. Data are presented as mean + standard error. vit A = Vitamin A; vit C = Vitamin C; vit A and C = Vitamin A and vitamin C; sham = Sham group. \*:  $p < 0.05$  considered significant



**Figure 3:** Inflammation score among study groups. Data are presented as mean + standard error. vit A = Vitamin A; vit C = Vitamin C; vit A and C = Vitamin A and vitamin C; sham = Sham group. \*:  $p < 0.05$  considered significant

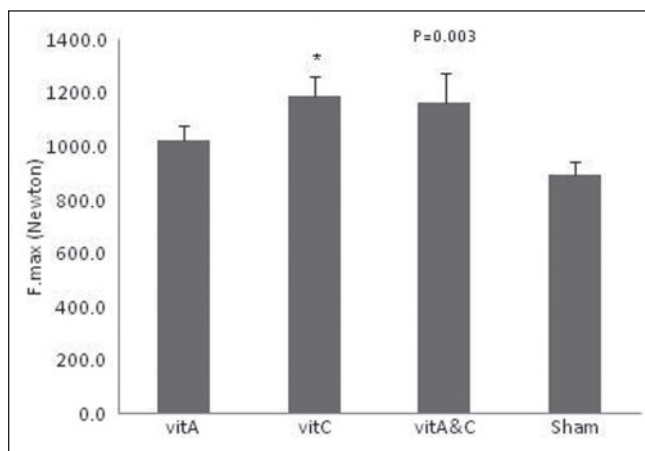
By considering that cytokines and inflammation play an important role in the adhesion formation process, previous studies mainly focused on the inhibition of the inflammatory system to reduce adhesion formation. In this study we focused on the improvement of wound healing by vitamin A and C and their effect on adhesion formation.

There are few studies in this field. One study that was performed by Demetriou *et al.* reveals that administration of vitamin A, of more than 150 mg orally, daily, increases adhesion formation and lower doses do not influence adhesion formation.<sup>[16]</sup> In line with this study we have found that by the administration of vitamin A, adhesion formation does not decrease and even increases, however, this change is not statistically significant.

It is well-known that vitamin C is an important cofactor for the synthesis of collagen, although the previous studies only mention its role in wound healing and none of them have evaluated its effect on adhesion formation.<sup>[14]</sup> Lima *et al.*'s study revealed that vitamin C has an anti-inflammatory and healing effect and improves skin wound healing.<sup>[27]</sup> In another study, performed by Petrinou *et al.*, they have found that oral vitamin C increases the intestinal anastomotic resistance in rats.<sup>[28]</sup> In our study we have found that vitamin C reduces adhesion formation and also increases the wound integrity, which has been assessed by tensiometry. This finding is against the theory which mentioned that adhesion formation is the pathological aspect of healing. In our study, administration of vitamin A and vitamin C has decreased adhesion formation, but it is not significant.

## CONCLUSION

In conclusion, we deduce that administration of oral vitamin C reduces adhesion formation and improves wound healing, and administration of vitamin A does



**Figure 4:** F-max among study groups. Data are presented as mean + standard error. vit A = vitamin A; vit C = Vitamin C; vit A and C = Vitamin A and vitamin C; sham = Sham group. \*:  $p < 0.05$  considered significant

not reduce adhesion formation. On the other hand the use of a combination of vitamin A and vitamin C does not reduce adhesion formation nor does it increase wound integrity.

## ACKNOWLEDGMENT

We acknowledge the Vice Chancellery for Research of the Isfahan University of Medical Science, for this project, which was done with their financial support. (Grant number 30158).

## REFERENCES

- Arung W, Meurisse M, Detry O. Pathophysiology and prevention of postoperative peritoneal adhesions. *World J Gastroenterol* 2011;17:4545-53.
- Bruggmann D, Tchatchchian G, Wallwiener M, Munstedt K, Tinneberg HR, Hackethal A. Intra-abdominal adhesions: Definition, origin, significance in surgical practice, and treatment options. *Dtsch Arztebl Int* 2010;107:769-75.
- Lauder CI, Garcea G, Strickland A, Maddern GJ. Abdominal adhesion prevention: Still a sticky subject? *Dig Surg* 2010;27:347-58.
- Liakakos T, Thomakos N, Fine PM, Derveniz C, Young RL. Peritoneal adhesions: Etiology, pathophysiology, and clinical significance. Recent advances in prevention and management. *Dig Surg* 2001;18:260-73.
- Rodgers KE, Girgis W, Campeau JD, diZerega GS. Reduction of adhesion formation by intraperitoneal administration of anti-inflammatory peptide 2. *J Invest Surg* 1997;10:31-6.
- Risberg B. Adhesions: Preventive strategies. *Eur J Surg Suppl* 1997;(577):32-9.
- Nappi C, Di Spiezio SA, Greco E, Guida M, Bettocchi S, Bifulco G. Prevention of adhesions in gynaecological endoscopy. *Hum Reprod Update* 2007;13:379-94.
- Menzies D, Ellis H. Intestinal obstruction from adhesions--how big is the problem? *Ann R Coll Surg Engl* 1990;72:60-3.
- Kucukozkan T, Ersoy B, Uygur D, Gundogdu C. Prevention of adhesions by sodium chromoglycate, dexamethasone, saline and aprotinin after pelvic surgery. *ANZ J Surg* 2004;74:1111-5.
- Replogle RL, Johnson R, Gross RE. Prevention of postoperative intestinal adhesions with combined promethazine and

- dexamethasone therapy: Experimental and clinical studies. *Ann Surg* 1966;163:580-8.
11. Hockel M, Ott S, Siemann U, Kissel T. Prevention of peritoneal adhesions in the rat with sustained intraperitoneal dexamethasone delivered by a novel therapeutic system. *Ann Chir Gynaecol* 1987;76:306-13.
  12. Uzunkoy A, Akinçi OF, Coskun A, Aslan O, Kocyigit A. Effects of antiadhesive agents on the healing of intestinal anastomosis. *Dis Colon Rectum* 2000;43:370-5.
  13. Ward BC, Panitch A. Abdominal adhesions: Current and novel therapies. *J Surg Res* 2011;165:91-111.
  14. MacKay D, Miller AL. Nutritional support for wound healing. *Altern Med Rev* 2003;8:359-77.
  15. Gross RL. The effect of ascorbate on wound healing. *Int Ophthalmol Clin* 2000;40:51-7.
  16. Demetriou AA, Seifter E, Levenson SM. Effect of vitamin A and Citral on peritoneal adhesion formation. *J Surg Res* 1974;17:325-9.
  17. Whang SH, Astudillo JA, Sporn E, Bachman SL, Miedema BW, Davis W, *et al.*. In search of the best peritoneal adhesion model: Comparison of different techniques in a rat model. *J Surg Res* 2011;167:245-50.
  18. Ara C, Kirimlioglu H, Karabulut AB, Coban S, Hascalik S, Celik O, *et al.*. Protective effect of melatonin against oxidative stress on adhesion formation in the rat cecum and uterine horn model. *Life Sci* 2005;77:1341-50.
  19. de Oliveira MR, Lorenzi R, Schnorr CE, Morrone M, Moreira JC. Increased 3-nitrotyrosine levels in mitochondrial membranes and impaired respiratory chain activity in brain regions of adult female rats submitted to daily vitamin A supplementation for 2 months. *Brain Res Bull* 2011;86:246-53.
  20. Ergul Y, Erkan T, Uzun H, Genc H, Altug T, Erginoz E. Effect of vitamin C on oxidative liver injury due to isoniazid in rats. *Pediatr Int* 2010;52:69-74.
  21. Kennedy R, Costain DJ, McAlister VC, Lee TD. Prevention of experimental postoperative peritoneal adhesions by N, O-carboxymethyl chitosan. *Surgery* 1996;120:866-70.
  22. Lauder CI, Garcea G, Strickland A, Maddern GJ. Use of a modified chitosan-dextran gel to prevent peritoneal adhesions in a rat model. *J Surg Res* 2011;171:877-82.
  23. Vlahos A, Yu P, Lucas CE, Ledgerwood AM. Effect of a composite membrane of chitosan and poloxamer gel on postoperative adhesive interactions. *Am Surg* 2001;67:15-21.
  24. Ersoy R, Celik A, Yilmaz O, Sarioglu S, Sis B, Akan P, *et al.* The effects of irbesartan and spironolactone in prevention of peritoneal fibrosis in rats. *Perit Dial Int* 2007;27:424-31.
  25. Greenhalgh D, Gamelli RL. Immunomodulators and wound healing. *J Trauma* 1987;27:510-4.
  26. Ranzer MJ, Chen L, DiPietro LA. Fibroblast function and wound breaking strength is impaired by acute ethanol intoxication. *Alcohol Clin Exp Res* 2011;35:83-90.
  27. Lima CC, Pereira AP, Silva JR, Oliveira LS, Resck MC, Grechi CO, *et al.* Ascorbic acid for the healing of skin wounds in rats. *Braz J Biol* 2009;69:1195-201.
  28. Petroianu A, Alberti LR. Effect of oral supplementation of vitamin C on intestinal anastomotic resistance. *Rev Col Bras Cir* 2011;38:54-8.

**Source of Support:** This project was a residency thesis that was performed by the financial support from the Vice Chancellery for Research of the Isfahan University of Medical Sciences, Isfahan, Iran. **Conflict of Interest:** None declared.