



A Newborn Infant with Congenital Central Hypoventilation Syndrome and Pupillary Abnormalities: A Literature Review

Mimily Harsono, MD, MSc¹ Sandeep Chilakala, MD, MPH¹ Shiva Bohn, MD² Eniko K. Pivnick, MD^{2,3}
Massroor Pourcyrus, MD¹

¹Division of Neonatal-Perinatal Medicine, Department of Pediatrics, University of Tennessee Health Science Center, Le Bonheur Children's Hospital, Memphis, Tennessee

²Division of Pediatric Ophthalmology, Department of Ophthalmology, University of Tennessee Health Science Center, Le Bonheur Children's Hospital, Memphis, Tennessee

³Division of Medical Genetic, Department of Pediatrics, University of Tennessee Health Science Center, Le Bonheur Children's Hospital, Memphis, Tennessee

Address for correspondence Mimily Harsono, MD, MSc, Department of Pediatrics, Division of Neonatal-Perinatal Medicine, Mailing Address: 853 Jefferson Avenue, Suite-201, Memphis, TN 38103 (e-mail: mharsono@uthsc.edu).

AJP Rep 2022;12:e139–e143.

Abstract

Keywords

- ▶ congenital central hypoventilation syndrome
- ▶ dilated oval pupil
- ▶ mydriasis oval-shaped pupil
- ▶ neonate
- ▶ newborn onset
- ▶ *PHOX2B*

We present a neonate with early onset apnea and bradycardia in the absence of primary cardiorespiratory and central nervous system disorders that eventually required chronic ventilator support starting at 6 hours of life. Molecular testing of paired-like homeobox 2b (*PHOX2B*) gene mutation confirmed the diagnosis of congenital central hypoventilation syndrome (CCHS). CCHS is a rare genetic disorder characterized by impaired central respiratory control with or without broad spectrum of autonomic nervous system (ANS) dysregulations. Ocular ANS dysregulation is a rare finding in CCHS individuals, and it is usually discovered later in life. However, the ophthalmic evaluation of this neonate on first day of life revealed persistent mild dilated oval pupils with limited light reactivity.

Congenital central hypoventilation syndrome (CCHS) is a rare life-threatening genetic disorder characterized by inadequate central respiratory responses to hypercarbia (CO₂) and/or hypoxemia (H⁺) particularly during sleep with or without broad spectrum of autonomic nervous system (ANS) dysregulations.^{1,2} CCHS is caused by mutations of paired-like homeobox 2b (*PHOX2B*) gene at chromosome 4p13.^{3,4} *PHOX2B* gene is a transcription factor that involves in embryogenesis of neural crest cells and development of ANS.⁵ ANS controls multiple organ functions such as breathing,

heart rate, blood pressure, body temperature, hormonal regulation, digestive function and pupillary reactivity. Few reports indicated that ocular abnormalities in CCHS individuals were discovered as a late-onset miosis, poor light reactivity, anisocoria, ptosis and tonic pupil.^{6,7} There are limited literatures on newborn onset ocular abnormalities in CCHS individuals.^{8,9} Pupillary size, shape, and light reactivity are controlled by tonic interaction between sympathetic and parasympathetic ANS. In this report, we presented a CCHS newborn with mild mydriasis oval-shaped pupils.

received
March 7, 2022
accepted after revision
June 1, 2022
accepted manuscript online
June 23, 2022

DOI <https://doi.org/10.1055/a-1883-0140>.
ISSN 2157-6998.

© 2022. The Author(s).

This is an open access article published by Thieme under the terms of the Creative Commons Attribution-NonDerivative-NonCommercial-License, permitting copying and reproduction so long as the original work is given appropriate credit. Contents may not be used for commercial purposes, or adapted, remixed, transformed or built upon. (<https://creativecommons.org/licenses/by-nc-nd/4.0/>)

Thieme Medical Publishers, Inc., 333 Seventh Avenue, 18th Floor, New York, NY 10001, USA

Case Presentation

A 36.1 weeks gestational age black female was delivered via emergent Cesarean-section due to non-reassuring fetal heart tone with Apgar scores of 7 and 9 at 1 and 5 minutes, respectively. Mother is a Gravida 1 Para 1, with good prenatal care and normal 3rd trimester prenatal laboratories, except for group B *Streptococcus* (GBS), which she received adequate intrapartum prophylactic antibiotic. Both parents were healthy 20 years old, non-consanguineous with no significant family medical history.

Infant was transferred to neonatal intensive care unit due to frequent apneic-bradycardic episodes that eventually required intubation with ventilator support at 6 hours of life. Septic work-up for bacterial infection was negative. The admission ophthalmic examination revealed abnormal-shaped pupils. Subsequently, the child developed abdominal distention with emesis and no bowel movement for over 48 hours which prompted an evaluation for intestinal obstruction. Eventually exploratory surgery confirmed the diagnosis of Hirschsprung's disease (HD).

The child continued to require ventilator support post-surgery with multiple failed extubations which necessitated an investigation for CCHS. Her *PHOX2B* gene sequence analysis confirmed heterozygous for 33 polyalanine repeat mutations (PRAM 20/33) in *PHOX2B* gene at exon 3 which suggested a severe form of CCHS. Molecular testing of *PHOX2B* gene mutation on both parents was negative. Chromosomal Microarray Analysis, Echocardiogram, electrocardiogram, head ultrasound, electroencephalogram, complete abdominal ultrasound, liver function test, thyroid function test, plasma-urine catecholamines, and complete blood counts/differentials/platelets counts were all reported as normal. Newborn screen was abnormal for sickle cell trait which was confirmed by hemoglobin electrophoresis.

Eye examination on the first day of life revealed abnormally "egg-shaped" pupils (horizontal oval-shaped pupil on right eye, vertical oval-shaped pupil on left eye) and limited pupillary reactivity to light on both eyes. Dilated fundoscopic eye evaluation at 1 week and again at 4 months of age showed abnormal findings that included mild dilated (~ 4 mm) horizontal oval-shaped right pupil, mild dilated (~ 4 mm) vertical oval-shaped left pupil, bilateral smooth iris surface with limited crypts, bilateral prominent iris collarette, and bilateral limited pupillary light reactivity with absent tonic pupil test to Pilocarpine 0.0625 and 0.125% (→Fig. 1A-C). Optic nerve, macula, sclera, cornea, lens, and conjunctiva appeared normal. Intraocular pressure and convergence exam were normal without nystagmus.

She was discharged home at 15 months of age with palliative care service, on 24 hours home ventilator, partial gastrostomy feeding, and partial parenteral nutrition support. She was readmitted to hospital multiple times for different medical issues and finally passed away at 22 months of age due to respiratory arrest at home. Autopsy was denied by the parents.

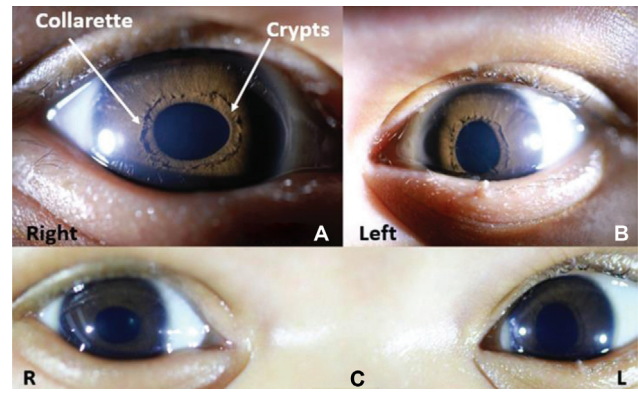


Fig. 1 (A) Righteye: mild dilated (~ 4 mm) horizontal oval-shaped right pupil, with prominent collarette, and smooth iris surface with limited crypts. (B) Left eye: mild dilated (~ 4 mm) vertical oval-shaped left pupil, with prominent collarette, and smooth iris surface with limited crypts. (C) Bilateral eyes: mild dilated (~ 4 mm) horizontal oval-shaped right pupil, mild dilated (~ 4 mm) vertical oval-shaped left pupil, with bilateral prominent collarette, and bilateral smooth iris surface with limited crypts.

Discussion

Congenital Central Hypoventilation Syndrome

CCHS is a rare genetic syndrome with incidence rate of 1 in 148,000 to 200,000 live births.^{10,11} The disease was first described in an infant by Mellins et al¹² in 1970 as "Ondine's curse" which was a unique respiratory control dysfunction with arrested breathing during sleep. In 1999, Pattyn et al⁵ described the role of *PHOX2B* gene in embryonic development of ANS from neural crest cell derivatives. In 2003, Amiel et al³ and Weese-Mayer et al⁴ independently discovered the association of inherited or mutations of *PHOX2B* gene at chromosome 4p13 in CCHS cases. CCHS disease-defining *PHOX2B* gene mutation is inherited in an autosomal dominant pattern with variable penetrance.^{1,2,13} Mutation can occur via de-novo mutation (90%) or germline mosaicism with/without somatic mosaicism (10%).^{14,15}

Clinical Symptoms of CCHS

The cardinal symptom of CCHS is an inadequate autonomic central control of breathing in response to hypercarbia (CO₂) or hypoxia (H⁺) particularly during non-rapid eye movement (non-REM) sleep, stress, illness or CNS (central nervous system) depressant medication, and in a severe type during awake in individuals without primary cardiorespiratory, neuromuscular, brain or metabolic pathology.^{1,2,13,15} Additionally, broad spectrum of multiorgan ANS dysregulation signs or symptoms have been reported in CCHS individuals, such as: (1) Cardiovascular symptoms: sinus pause for more than 3 seconds, syncope, bradycardia, altered blood pressure; (2) Digestive symptoms: esophageal dysmotility, constipation, HD; (3) Endocrine or metabolic symptoms: hypoglycemia, hyperglycemia, thyroid disease, hyperinsulinemia; (4) Sodomotor symptoms: altered thermoregulation, profuse sweating; (5) CNS symptoms: decrease pain or anxiety perception, seizure, neural crest tumors; (6) Ocular

symptoms: various pupillary abnormalities.^{1,2,11,13,15} Clinical symptoms of CCHS can be presented as (1) neonatal onset; (2) late-onset during childhood or adulthood.^{1,2,16,17}

Diagnosis of CCHS

Confirmatory diagnosis in an individual with clinical symptoms requires a molecular genetic test for *PHOX2B* gene mutation. Currently, there are three molecular testing methods to detect *PHOX2B* gene mutations^{1,2,18}: (1) *PHOX2B* gene targeted mutation analysis (fragment length analysis) detects all polyalanine repeat mutations (PARM), most non-polyalanine repeat mutations (NPARM), and low-level mosaicism; (2) *PHOX2B* sequencing test detects all PARM and NPARM cases but unable to detect low-level mosaicism; and (3) *PHOX2B* gene deletion/duplication analysis for less than 1% variants that could be missed by other tests. Targeted mutation analysis or sequencing test is the preferred initial test in a suspected individual. A combination of all molecular tests needs to be completed if one molecular test is negative in a highly suspicious clinical case.^{2,18} Also, parents of CCHS individual need molecular genetic testing for genetic counseling. Germline mutation mosaicism can only be detected on prenatal genetic testing or from sibling of proband.^{2,14}

PHOX2B Gene Mutation Variants

There are two major *PHOX2B* gene mutation variants found in majority of CCHS individuals^{15,19,20}: (1) Heterozygous in-frame PARM at exon 3 of *PHOX2B* gene (~ 90% of cases). Normal individuals have 20 alanine repeats on each allele, defined as 20/20, whereas CCHS individuals have 24 to 33 alanine repeats on the affected allele producing genotypes PARM 20/24 - 20/33 with PARM 20/25 - 20/27 being the most common genotypes. (2) Heterozygous NPARM at exon 1, 2, or 3 of *PHOX2B* gene include missense, nonsense, stop codon, splice intron, and frameshift mutations (~ 10% of cases).^{1-3,21} In addition, CCHS-like symptoms have been identified in mutations of *PHOX2B* gene co-activator or co-expression genes during the development of neural crest cells.²²

CCHS Phenotypic-Genotypic Correlations

Severity of CCHS phenotype correlates closely to the type of genotypic mutations of the *PHOX2B* gene.^{10,11,13,19,20} Clinical symptoms of CCHS can vary in their disease onset and severity.^{2,10,11} Facial dysmorphism has been reported as broad-flat-rectangular face which resembled "box-like appearance,"²³ though we did not notice this facial characteristic in our case. Individuals with shorter PARM, 20/24 - 20/25, have mild phenotypic features with milder symptoms, late-onset presentation, symptomatic during stress event, symptomatic during exposure to anesthesia (sedative) medication or may not reach threshold for clinical disease presentation.^{16,17} Individuals with PARM 20/27 - 20/33 are generally symptomatic at birth and require chronic ventilator support.¹³ NPARM and PARM 20/31 - 20/33 genotypes tend to correlate with more severe clinical condition, especially more severe respiratory symptoms and more likely to

be associated with HD, neural crest tumors or spectrum of ANS dysfunctions.^{11,24} The *PHOX2B* gene sequencing test in this case was positive for PARM 20/33 which was considered as a more severe form. Nevertheless, both PARM and NPARM mutations can have variable expressivity and incomplete penetrance that may be presented as asymptomatic or subtle symptoms or late-onset cases.^{1,4,10}

Ocular Abnormalities Associated with CCHS

ANS involves in regulating numerous ocular functions. Ocular disorders in CCHS can be categorized into two major types¹: (1) Intrinsic ocular denervation: pupil and iris abnormalities (more common); (2) Extrinsic ocular denervation: ocular motility and extraocular muscle dysfunctions. In CCHS, the severity of ocular abnormalities correlates with type of *PHOX2B* gene mutations.⁷ Ophthalmic symptoms in CCHS are commonly present as poor pupillary light reactivity, miosis, convergence insufficiency, anisocoria, tonic pupil, and strabismus.^{6,7,25} Majority of CCHS pupillary abnormalities were discovered during childhood or adulthood.^{6,7,25} Our patient had mild bilateral mydriasis (dilated) pupils that was detected on first day of life and persisted throughout. Only three cases of mydriasis tonic pupils were reported during neonatal period.^{8,9} However, our patient did not respond to tonic pupil test (Pilocarpine 0.0625 and 0.125%) at 1 week and again at 4 months of age. Other interesting finding in our patient was the oval-shaped pupils (horizontal on right pupil and vertical on left pupil) (► Fig. 1A-C). There was only one reported case of a CCHS adult with horizontal oval-shaped pupil in one eye.²⁵

Pupillary size and reactivity are controlled by tonic interaction between sympathetic and parasympathetic nervous system.^{26,27} Sympathetic nervous system stimulates pupil dilatation, and parasympathetic nervous system stimulates pupil constriction.²⁸ Constricted pupils with limited light response were more commonly reported in CCHS cases.^{6,7} Constricted pupils are most likely caused by defect in sympathetic superior cervical ganglion or ocular sympathetic pathway.^{28,29} Our patient had dilated pupils with limited responses to light. Poor light reactivity is most likely caused by defect involving parasympathetic ciliary ganglion or ocular parasympathetic pathway.^{26,27,29} Severe atrophied parasympathetic ciliary ganglion with dilated pupil was found in mice with mutant or reduce *PHOX2B* expression.²¹

Our patient had near smooth iris surface with limited crypts and prominent iris collarette (► Fig. 1A-B). Smooth iris surface with absent crypts was mentioned in few CCHS patients.^{6,25} Boulanger-Scemama et al²⁵ reported bilateral mydriasis with unilateral oval-shaped pupil and lack of iris crypts in one adult CCHS case. Embryologically, iris arises from ectodermal neural crest cells. Iris collarette is an area where iris sphincter muscle and iris dilator muscle overlap. It is typically a flat circumferential border. A prominent iris collarette is considered a normal variant.³⁰ Iris crypts are formed during approximately 3rd to 6th month of gestation from stroma and anterior border layer cells.³¹ Atrophy or frequency of iris crypts has strong genetic-based correlation.^{31,32} Iris crypts become more prominent when pupil

dilate. An oval-shaped pupil is affected by loss of segmental contraction of pupillary dilator (iris dilator) or segmental relaxation of pupillary constrictor (iris sphincter).^{28,33} Loss of segmental iris dilator and/or iris sphincter function can be a result of partial damage to the preganglionic parasympathetic pupillary fibers.³⁴ The presence of oval-shaped pupil usually is a clinical sign of acute midbrain neurological deficit (hemorrhage or infarct), increased intracranial pressure or acute glaucoma.³⁵ Our patient head ultrasound, brain-MRI and ophthalmic exam did not show any of these signs.

Conclusion

Pupillary abnormalities are rare findings in CCHS patients and are mostly detected later in life. However, the pupillary abnormalities in this case were discovered on first day of life and remained persistently abnormal. Early recognition of pupillary abnormalities in a newborn with early onset apnea in the absence of primary cardiorespiratory and CNS disorders will aid in expediting the diagnosis of CCHS.

Informed Consent

The case report study, which included the photographs (ophthalmology pictures) have received an IRB approval from the University of Tennessee Health Science Center and Le bonheur Children's Hospital to conduct the study. All photographs (ophthalmology pictures) and clinical history provided in this case report have a written consent form signed by patient's parent or legal guardian for the purpose of medical literature publication and education. Patient's personal information was de-identified in the manuscript article and pictures.

Authors' Contribution

M.H. was involved in diagnosing patient care, literature review, obtaining IRB approval, obtaining parental consent, writing the manuscript first draft, manuscript revision, manuscript edition, and approval of the final manuscript as submitted. S.C. was involved in diagnosing, patient care, literature review, ophthalmic photograph, manuscript revision and approval of the final manuscript as submitted. S.B. was involved in the ophthalmologic exam, ophthalmic photograph, manuscript revision, and approval of the final manuscript as submitted. E.P. was involved in diagnosing, genetic evaluation, literature review, critical review, manuscript revision, and approval of the final manuscript as submitted. M.P. was involved in diagnosing, patient care, literature review, critical review, obtaining IRB approval, manuscript revision, manuscript edition, and approval of the final manuscript as submitted.

Funding

None.

Conflict of Interest

None declared.

References

- Trang H, Samuels M, Ceccherini I, et al. Guidelines for diagnosis and management of congenital central hypoventilation syndrome. *Orphanet J Rare Dis* 2020;15(01):252
- Weese-Mayer DE, Berry-Kravis EM, Ceccherini I, Keens TG, Lohmanee DA, Trang HATS Congenital Central Hypoventilation Syndrome Subcommittee. An official ATS clinical policy statement: Congenital central hypoventilation syndrome: genetic basis, diagnosis, and management. *Am J Respir Crit Care Med* 2010;181(06):626–644
- Amiel J, Laudier B, Attié-Bitach T, et al. Polyalanine expansion and frameshift mutations of the paired-like homeobox gene PHOX2B in congenital central hypoventilation syndrome. *Nat Genet* 2003;33(04):459–461
- Weese-Mayer DE, Berry-Kravis EM, Zhou L, et al. Idiopathic congenital central hypoventilation syndrome: analysis of genes pertinent to early autonomic nervous system embryologic development and identification of mutations in PHOX2b. *Am J Med Genet A* 2003;123A(03):267–278
- Pattyn A, Morin X, Cremer H, Goridis C, Brunet JF. The homeobox gene Phox2b is essential for the development of autonomic neural crest derivatives. *Nature* 1999;399(6734):366–370
- Goldberg DS, Ludwig IH. Congenital central hypoventilation syndrome: ocular findings in 37 children. *J Pediatr Ophthalmol Strabismus* 1996;33(03):175–180
- Patwari PP, Stewart TM, Rand CM, et al. Pupillometry in congenital central hypoventilation syndrome (CCHS): quantitative evidence of autonomic nervous system dysregulation. *Pediatr Res* 2012;71(03):280–285
- Lambert SR, Yang LL, Stone C. Tonic pupil associated with congenital neuroblastoma, Hirschsprung disease, and central hypoventilation syndrome. *Am J Ophthalmol* 2000;130(02):238–240
- Mehta VJ, Ling JJ, Martinez EG, Reddy AC, Donahue SP. Congenital tonic pupils associated with congenital central hypoventilation syndrome and Hirschsprung disease. *J Neuroophthalmol* 2016;36(04):414–416
- Shimokaze T, Sasaki A, Meguro T, et al. Genotype-phenotype relationship in Japanese patients with congenital central hypoventilation syndrome. *J Hum Genet* 2015;60(09):473–477
- Trang H, Dehan M, Beaufils F, Zaccaria I, Amiel J, Gaultier CFrench CCHS Working Group. The French Congenital Central Hypoventilation Syndrome Registry: general data, phenotype, and genotype. *Chest* 2005;127(01):72–79
- Mellins RB, Balfour HH Jr, Turino GM, Winters RW. Failure of automatic control of ventilation (Ondine's curse). Report of an infant born with this syndrome and review of the literature. *Medicine (Baltimore)* 1970;49(06):487–504
- Berry-Kravis EM, Zhou L, Rand CM, Weese-Mayer DE. Congenital central hypoventilation syndrome: PHOX2B mutations and phenotype. *Am J Respir Crit Care Med* 2006;174(10):1139–1144
- Rand CM, Yu M, Jennings LJ, et al. Germline mosaicism of PHOX2B mutation accounts for familial recurrence of congenital central hypoventilation syndrome (CCHS). *Am J Med Genet A* 2012;158A(09):2297–2301
- Weese-Mayer DE, Rand CM, Zhou A, Carroll MS, Hunt CE. Congenital central hypoventilation syndrome: a bedside-to-bench success story for advancing early diagnosis and treatment and improved survival and quality of life. *Pediatr Res* 2017;81(1-2):192–201
- Antic NA, Malow BA, Lange N, et al. PHOX2B mutation-confirmed congenital central hypoventilation syndrome: presentation in adulthood. *Am J Respir Crit Care Med* 2006;174(08):923–927
- Repetto GM, Corrales RJ, Abara SG, et al. Later-onset congenital central hypoventilation syndrome due to a heterozygous 24-polyalanine repeat expansion mutation in the PHOX2B gene. *Acta Paediatr* 2009;98(01):192–195
- Jennings LJ, Yu M, Zhou L, Rand CM, Berry-Kravis EM, Weese-Mayer DE. Comparison of PHOX2B testing methods in the

- diagnosis of congenital central hypoventilation syndrome and mosaic carriers. *Diagn Mol Pathol* 2010;19(04):224–231
- 19 Bachetti T, Ceccherini I. Causative and common PHOX2B variants define a broad phenotypic spectrum. *Clin Genet* 2020;97(01):103–113
 - 20 Zhou A, Rand CM, Hockney SM, et al. Paired-like homeobox gene (PHOX2B) nonpolyalanine repeat expansion mutations (NPARMs): genotype-phenotype correlation in congenital central hypoventilation syndrome (CCHS). *Genet Med* 2021;23(09):1656–1663
 - 21 Cross SH, Morgan JE, Pattyn A, et al. Haploinsufficiency for Phox2b in mice causes dilated pupils and atrophy of the ciliary ganglion: mechanistic insights into human congenital central hypoventilation syndrome. *Hum Mol Genet* 2004;13(14):1433–1439
 - 22 Amiel J, Sproat-Emison E, Garcia-Barcelo M, et al; Hirschsprung Disease Consortium. Hirschsprung disease, associated syndromes and genetics: a review. *J Med Genet* 2008;45(01):1–14
 - 23 Todd ES, Weinberg SM, Berry-Kravis EM, et al. Facial phenotype in children and young adults with PHOX2B-determined congenital central hypoventilation syndrome: quantitative pattern of dysmorphology. *Pediatr Res* 2006;59(01):39–45
 - 24 Trochet D, Hong SJ, Lim JK, et al. Molecular consequences of PHOX2B missense, frameshift and alanine expansion mutations leading to autonomic dysfunction. *Hum Mol Genet* 2005;14(23):3697–3708
 - 25 Boulanger-Scemama E, Fardeau C, Straus C, et al. Ophthalmologic impairment during adulthood in central congenital hypoventilation syndrome: a longitudinal cohort analysis of nine patients. *Ophthalmic Genet* 2014;35(04):229–234
 - 26 Caglayan HZ, Colpak IA, Kansu T. A diagnostic challenge: dilated pupil. *Curr Opin Ophthalmol* 2013;24(06):550–557
 - 27 McDougal DH, Gamlin PD. Autonomic control of the eye. *Compr Physiol* 2015;5(01):439–473
 - 28 Bouffard MA. The Pupil. *Continuum (Minneap Minn)* 2019;25(05):1194–1214
 - 29 Bremner F. Pupil evaluation as a test for autonomic disorders. *Clin Auton Res* 2009;19(02):88–101
 - 30 Li S, Liang L. Protruding iris collarette. *N Engl J Med* 2017;376(11):1064
 - 31 Sturm RA, Larsson M. Genetics of human iris colour and patterns. *Pigment Cell Melanoma Res* 2009;22(05):544–562
 - 32 Edwards M, Cha D, Krithika S, Johnson M, Parra EJ. Analysis of iris surface features in populations of diverse ancestry. *R Soc Open Sci* 2016;3(01):150424
 - 33 Bremner FD, Drapkin AJ. The Dynamic Oval Pupil. *Front Neurol* 2019;10:75
 - 34 Fisher CM. Oval pupils. *Arch Neurol* 1980;37(08):502–503
 - 35 Mittal MK, Rabinstein AA, Wijdicks EF. Pearls & oysters: oval pupil: two observations. *Neurology* 2013;81(17):e124–e125