

# Quantitative Estimation of LIMA Blood Flow between Extraluminal Papavarine vs Extraluminal Papavarine Plus Intraluminal Vasodilator Cocktail in CABG Patients

## Abstract

**Objective:** In this study, we aimed at a comparative quantitative estimation of the difference in LIMA blood flow between LIMAs treated with topical papaverine alone and LIMAs treated with a combination of topical papaverine plus an intraluminal cocktail of papaverine, nitroglycerine, and milrinone. **Methods:** Nearly 50 consecutive patients with similar demographics undergoing elective on-pump CABG were recruited for the study. After pedicled LIMA harvest, topical papaverine was sprayed on the pedicle and kept enveloped in papaverine soaked gauze. LIMA flow was then estimated. Later, intraluminal vasodilator solution of papaverine, NTG, milrinone, and heparinized blood were instilled in LIMA, and LIMA flows were estimated. **Results:** The mean LIMA flows with topical papaverine alone was 47.19 mL/min whereas the mean LIMA flows with topical papaverine plus intraluminal cocktail was 104 mL/min. There was a significant difference between the two flows as their mean was 56.815 mL/min and the paired *t*-test for significance had a *P* value of 0.0001. **Conclusion:** There was a significant difference in the LIMA flow when the LIMA had been treated with the intraluminal instillation of the vasodilator cocktail in addition to the topical application of papaverine solution. Therefore, intraluminal vasodilator cocktail of milrinone, NTG, and papaverine mixed with heparinized blood in addition to topical papaverine is a simple and effective method for LIMA preparation in CABG.

**Keywords:** Coronary artery bypass grafting, intraluminal vasodilator, LIMA, topical vasodilator

## Introduction

An internal mammary artery has consolidated its place as the preferred conduit of choice for coronary artery bypass grafting (CABG).<sup>[1]</sup> Patency of LIMA is superior to the saphenous vein with longer durability, thus improving long-term survival.<sup>[2]</sup> Nevertheless, perioperative spasm of arterial grafts is a well-documented and potentially life-threatening complication when used as a conduit for CABG. Spasm reduces the size of the LIMA thus making the construction of the well-flowing anastomosis technically difficult. Moreover, reduced LIMA flows in the immediate postoperative period predisposes to a higher incidence of chronic LIMA occlusion.<sup>[3]</sup> The reported incidence in the literature of LIMA spasm is 0.43%.<sup>[4]</sup> The mechanisms and receptors that regulate the vascular smooth muscle tone involved in the process have been extensively

studied. A variety of techniques, both pharmacological and non-pharmacological are employed to prevent spasm of the left internal mammary artery (LIMA) when used as a conduit for CABG.<sup>[5,6]</sup> Papaverine, an opioid derivative produces vasodilatation by phosphodiesterase inhibition, decreasing calcium influx, and inhibiting the release of intracellularly stored calcium. Organic nitrates such as nitroglycerine (NTG) release nitric oxide (NO) which, in turn, raises cyclic guanosine monophosphate (cGMP) in the smooth muscle cells thus reducing intracellular calcium and vasodilation by vascular smooth muscle relaxation. Milrinone, a phosphodiesterase 3 inhibitor, increases intracellular cyclic adenosine monophosphate (cAMP) thus inhibiting myosin light chain kinase producing vasodilatation in the vascular system. In this observational study, we aimed at a comparative quantitative estimation of LIMA blood flow between LIMAs treated with topical papaverine alone and LIMAs

**Vivek V Pillai,  
Renjith  
Sreekanthan,  
Jayakumar  
Karunakaran**

*Department of Cardiothoracic Surgery, Sree Chitra Tirunal Institute for Medical Sciences and Technology, Trivandrum, Kerala, India*

**Submitted:** 14-Nov-2019  
**Accepted:** 01-Jan-2020  
**Published:** 19-Oct-2020

**Address for correspondence:**  
Dr. Vivek V Pillai,  
Department of Cardiothoracic Surgery,  
Sree Chitra Tirunal Institute for Medical Sciences and Technology,  
Trivandrum - 695 011, Kerala, India. E-mail: drvivekpillai@yahoo.co.in

### Access this article online

**Website:** www.annals.in

**DOI:** 10.4103/aca.ACA\_164\_19

### Quick Response Code:



**How to cite this article:** Pillai VV, Sreekanthan R, Karunakaran J. Quantitative estimation of LIMA blood flow between extraluminal papavarine vs extraluminal papavarine plus intraluminal vasodilator cocktail in CABG patients. *Ann Card Anaesth* 2020;23:414-8.

This is an open access journal, and articles are distributed under the terms of the Creative Commons Attribution-NonCommercial-ShareAlike 4.0 License, which allows others to remix, tweak, and build upon the work non-commercially, as long as appropriate credit is given and the new creations are licensed under the identical terms.

**For reprints contact:** reprints@medknow.com

treated with a combination of topical papaverine plus an intraluminal cocktail of papaverine, nitroglycerine, and milrinone.

**Methods**

**Study Algorithm [Figure 1]**

Between January 2019 and May 2019, after informed consent, 50 patients with comparable demographics features who underwent elective, on-pump, isolated, and primary CABG were selected for this observational study [Table 1]. Patients subjected to emergency CABG, patients with peripheral occlusive vascular disease (POVD) or stroke and patients with CABG plus associated combined procedures such as valve repair/replacement, ventricular restoration procedures were excluded. Technical Advisory Committee and Institutional Ethics Committee approval were obtained for the observational study.

All patients received 5 mg PO diazepam as preanesthetic medication. Based on institute protocol anesthesia was induced with propofol, fentanyl, midazolam, and pancuronium/vecuronium and maintained with fentanyl and sevoflurane. Radial or femoral blood pressure, heart rate, and central venous pressure were monitored. After skin incision from the suprasternal notch to the xiphoid, midline sternotomy was performed. Sternal edges were retracted and hemostasis achieved. Left pleura cavity was identified and opened from the diaphragm to the second intercostal space and LIMA harvested in a pedicled manner using low cautery and hemoclips (Ligaclip; Ethicon, Cincinnati, OH). After LIMA harvest, LIMA pedicle was sprayed with 10 mL of with diluted papaverine at room temperature (30 mg/mL solution of papaverine diluted with 30 mL of 0.9% normal saline to achieve a 1 mg/mL concentration of papaverine) and covering the pedicle with a diluted papaverine (1 mg/mL) soaked sponge for 10 min and mean blood pressure stabilized at 80–90 mmHg. After systemic heparinization to achieve a target activated clotting time of 480 s, the distal end of LIMA was divided proximal to the bifurcation. The distal cut end was then spatulated for 1–2 cm after freeing the LIMA from the endothoracic fascia and the muscles of the pedicle. LIMA free flow was estimated by allowing the open distal end of LIMA to freely bleed into a small bowl for 15 s (timed by the surgical assistant), measuring the amount of collected blood and the flow per minute was calculated accordingly. After

this measurement, a vasodilator solution was prepared by adding 2 drops of 1 mg/mL (0.1%) papaverine, 1 drop of 5 mg/mL (0.5%) nitroglycerine (NTG), 1 mL of 1 mg/mL (0.1%) milrinone to 4 mL of 0.9% normal saline and further diluted to 10 mL by adding heparinized blood. About 5 mL of this vasodilator “cocktail” solution was administered intraluminal into the LIMA in a slow retrograde manner through the distal end of LIMA over 30 s so as to avoid hydrostatic distension with a soft-tipped cannula inserted just 1 cm into distal end carefully so as to avoid intimal damage. The distal end of LIMA was then kept temporarily occluded with a bulldog clamp for 10 min. Arterial blood pressure (ABP) was stabilized to mean ABP of 80–90 mmHg by administering intravenous fluids and titrated doses of phenylephrine (50–100 µg intravenous bolus) and after 10 min, the LIMA flows were measured. Subsequently, routine on-pump CABG was performed. All patients had an uneventful postoperative course.

**Statistical analysis**

Statistical analysis was done using SPSS 15 (SPSS Inc, Chicago, Illinois, USA). Parametric data are represented as mean ± standard deviation. Tests of normality and correlation analyzed. Both the variables are normally distributed as per the Kolmogorov-Smirnov test. Paired ‘t’ test was used to compare the flows between the topical papaverine alone group and the topical papaverine plus intraluminal cocktail group. P value of less than 0.05 was considered to be significant.

**Results**

The LIMA flows after topical administration of papaverine is designated as Top Flow (FLOW 1) and LIMA flow after topical papaverine plus intraluminal cocktail was designated TopIL-C (FLOW 2) flow.

The observed mean LIMA (Top Flow) flow when topical papaverine alone was applied to LIMA is 47.19 mL/min [Image 1] and mean LIMA flow (TopIL-C Flow) when an intraluminal cocktail of papaverine, NTG, and milrinone was intraluminal instilled into the LIMA in addition to topical papaverine was 104 mL/min [Image 2]. There is a significant difference between the Top Flow and TopIL-C Flow as their mean difference (+/- SD) is 56.815 (+/- 10.88) mL/min and the paired ‘t’ test for significance has a P value of 0.0001 which is statistically significant. Thus there is a significant increase in the LIMA blood flow when vasodilator solution was instilled intraluminal into the LIMA. Table 2 compares the mean LIMA flow ± standard deviation for top flow and TopIL-C flow and Table 3 shows the mean increase in TopIL-C flow over top flow.

**Discussion**

Conduits commonly used for CABG are reversed saphenous veins, internal mammary arteries, and radial arteries. CABG

**Table 1: Preoperative demographic details**

	Number	Percentage
Age	60.158±7.454 (Mean±SD)	
Males	46	92%
Diabetes	36	72%
Hypertension	42	84%
Renal dysfunction	4	8%
COPD	4	8%

**Table 2: Analysis of Top Flow and TopIL-C Flow**

			Paired Samples Statistics				
			Value	Bootstrap <sup>a</sup>			
				Bias	Std. Error	95% Confidence Interval	
						Lower	Upper
Pair 1	TOP FLOW (ML/MIN)	Mean	47.19	0.21	4.06	39.56	55.19
		N	50				
		Std. Deviation	22.778	-.681	3.797	15.460	29.502
		Std. Error Mean	4.384				
	TOPIL-C FLOW (ML/MIN)	Mean	104.00	0.00	6.20	91.26	115.84
		N	50				
		Std. Deviation	33.650	-.707	3.728	25.361	39.927
		Std. Error Mean	6.476				

a. Unless otherwise noted, bootstrap results are based on 1000 bootstrap samples

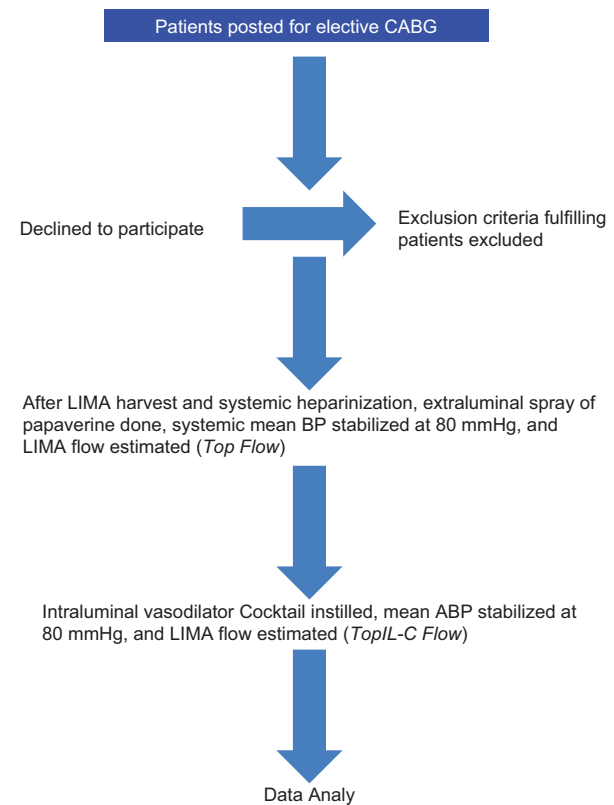
**Table 3: Paired Samples Test – Difference between TopIL-C Flow and Top Flow**

		Paired Differences				t	df	Sig. (2-tailed)	
		Mean	Std. Deviation	Std. Error Mean	95% Confidence Interval of the Difference				
					Lower	Upper			
Pair 1	TOP FLOW (ML/MIN) and TOPIL-C FLOW (ML/MIN)	-.56.815	29.080	5.596	-.68.318	-.45.311	-.10.152	50	0.000

with arterial grafts has been established as a reliable and durable standard of care in the management of coronary artery disease.<sup>[1]</sup> LIMA has been the first conduit of choice for revascularization of the left coronary system especially the left anterior descending artery.<sup>[2]</sup> Around 80% of internal mammary arteries are shown to be free of the significant disease up to 25 years.<sup>[7]</sup> LIMA patency at 5 years and 10 years is 98% and 95%, respectively.<sup>[8]</sup> Veins are about 2.6 times more prone to stenosis or occlusion than arteries.<sup>[9]</sup> High occlusion rates in veins are most often attributed to vein graft atherosclerosis which amounts to 50% graft occlusion in 12 years.<sup>[10]</sup> However, perioperative spasm of LIMA has been reported as a leading cause of perioperative and postoperative morbidity and mortality.<sup>[3]</sup> A number of pharmacological agents such as papaverine, verapamil, milrinone, sodium nitroprusside, and nitroglycerine have been used to address LIMA vasospasm. Several studies have been done to assess the efficacy of these agents in preventing vasospasm of LIMA.<sup>[11-13]</sup> Since a combination of drugs countering all these causes is probably an ideal solution. Papaverine is the most commonly used and widely evaluated agent. Papaverine administration has ranged from topical application to intraluminal instillation. Mills *et al.*<sup>[11]</sup> found LIMA flow to be 3 times greater after intraluminal administration of papaverine with hydrostatic dilation than with topical administration.

Papaverine, an opioid derivative produces vasodilatation by phosphodiesterase inhibition, decreasing calcium influx and inhibiting the release of intracellularly stored calcium. Myranppa *et al.*<sup>[14]</sup> and Dregelid *et al.*<sup>[15]</sup> have reported endothelial damage due to the low pH (4.4–4.8) of papaverine. This can be neutralized by keeping a very

Study Algorithm



**Figure 1: Study Algorithm**

low concentration of papaverine and by the action of buffering agents in heparinized blood used to dilute the vasodilator solution.<sup>[5]</sup> Organic nitrates such as (NTG) release nitric oxide (NO) which in turn raises cyclic

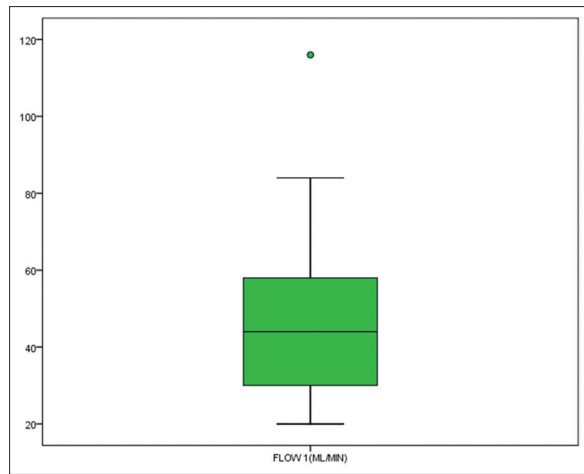


Image 1: Topical papaverine – Top Flow (Flow 1) distribution

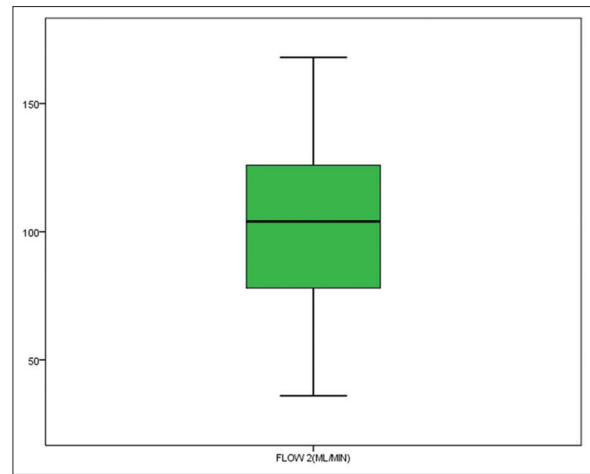


Image 2: Topical papaverine plus intraluminal vasodilator cocktail – TopL-C flow (Flow 2) distribution

guanosine monophosphate (cGMP) in the smooth muscle cells thus reducing intracellular calcium and vasodilation by vascular smooth muscle relaxation. Milrinone, a phosphodiesterase 3 inhibitor, increases intracellular cyclic adenosine monophosphate (cAMP) thus inhibiting myosin light chain kinase producing vasodilatation in vascular system. The reason for poor and inconsistent LIMA blood flow after topical application of papaverine alone in pedicled LIMA (1–1.5 cm) is the presence of thick tissue comprised of an intrathoracic fascia, adipose tissue, and muscle around the LIMA preventing the adequate contact of the conduit with the vasodilator.<sup>[16]</sup> Several investigators, Mulay *et al.*<sup>[17]</sup> and Girard *et al.*<sup>[18]</sup> have studied the effects of periadventitial infiltration of papaverine using a blunt needle to circumvent this problem. There were speculations whether LIMA would spontaneously dilate if given appropriate time. Various studies have yielded conflicting reports. Cooper *et al.*<sup>[19]</sup> and Bilgen *et al.*<sup>[20]</sup> have proven that LIMA does not dilate between harvest and initiation of cardiopulmonary bypass. Nevertheless, Vilandt *et al.*<sup>[21]</sup> and Sasson *et al.*<sup>[22]</sup> have proven that LIMA does dilate between 30–75 min after harvest. Thus the most effective method to administer papaverine remains controversial. Nitroglycerine (NTG) is a rapid-acting vasodilator which when used both topically and systemically can produce significant dilatation to the internal mammary artery.<sup>[12]</sup> Milrinone has been proven to be potent endothelium-independent vasodilator of the internal mammary artery.<sup>[13]</sup> Thus, we had intended to study the effects of a vasodilator cocktail solution which is a mixture of potent and proven vasodilators whose different modes of action ensure a rapid initiation and sustained vasodilatation in the LIMA, thus facilitating a technically less demanding anastomosis, better perioperative LIMA flows which, in turn, manifests as better long-term LIMA patency and improved patient outcomes. Our outcome reiterates the results of similar studies that have used various combinations of vasodilator substances to improve LIMA flows during the operation. Bilateral internal

mammary artery (BIMA) grafting has been proven to have much better clinical outcomes as compared to LIMA and saphenous veins.<sup>[23,24]</sup> RIMA patency is 96% and 81% at 5 years and 10 years, respectively.<sup>[8]</sup> Skeletonization of the IMA is thought to reduce the incidence of sternal wound infection.<sup>[25]</sup> Symptom-free survival and freedom from reintervention after CABG depends on long-term graft patency. This is where arterial conduits outperform venous conduits. Several unknown factors continue to play a significant role in the short-term and long-term durability of IMA grafts. Owing to the complexity of mechanisms that contribute to vascular smooth muscle contraction and relaxation, pharmacological agents for vasodilatation are increasingly becoming essential elements in the surgical LIMA harvest protocol. In the absence of convincing clinical data on a perfect vasodilator, we have an array of choices. However, the ideal solution would be a vasodilator cocktail that addresses the various mechanisms of reflex vasospasm to obtain a consistent and reliable effect. Though larger and long-term studies are necessary to reach a conclusion, this study was aimed at furthering our efforts for an effective vasodilator solution for LIMA.

The study, however, has many limitations. This is a small study with 50 patients. A larger study may have increased the statistical power of the observations. There is a male preponderance as well among the recruited cases. Also, we did not measure the cardiac index and analyze the effects on cardiac function on LIMA flows and vice versa. We have not analyzed the effects of vasodilators on cardiac function but considered only the mean arterial pressure and heart rate while comparing the two groups. In addition, advanced techniques for accurate measurement of LIMA flow especially after the anastomosis can be employed in subsequent studies. Moreover, further studies are warranted with a combination of proven arterial vasodilators so as to establish the ideal solution for an optimal effect.

## Conclusion

It was evident from the statistical analysis that there was a significant improvement in the LIMA flow when the LIMA had been treated with the intraluminal infection of the vasodilator cocktail in addition to the topical application of papaverine. There was almost 100% increase in the LIMA blood flow when the intraluminal cocktail was instilled in the LIMA along with the topical application of papaverine than when papaverine alone was topically applied. Hypothetically, this is possibly due to the reduction in the vascular resistance secondary to LIMA smooth muscle relaxation leading to an increase in LIMA intraluminal diameter and thus an enhanced blood flow. Therefore, an intraluminal cocktail of milrinone, NTG and papaverine mixed with heparinized blood in addition to topical papaverine is a simple and effective method for LIMA preparation in CABG.

## Declaration of patient consent

The authors certify that they have obtained all appropriate patient consent forms. In the form, the patient(s) has/have given his/her/their consent for his/her/their images and other clinical information to be reported in the journal. The patients understand that their names and initials will not be published and due efforts will be made to conceal their identity, but anonymity cannot be guaranteed.

## Financial support and sponsorship

Nil.

## Conflicts of interest

There are no conflicts of interest.

## References

- Scott R, Blackstone EH, McCarthy PM, Lytle BW, Loop FD, White JA, *et al.* Isolated bypass grafting of the left internal thoracic artery to the left anterior descending coronary artery: Late consequences of incomplete revascularization. *J Thorac Cardiovasc Surg* 2000;120:173-84.
- Loop FD, Lytle BW, Cosgrove DM, Stewart RW, Goormastic M, Williams GW, *et al.* Influence of the internal mammary artery graft on 10-year survival and other cardiac events. *N Engl J Med* 1986;314:1-6.
- Sarabu MR, McClung JA, Fass A, Reed GE. Early postoperative spasm in left internal mammary artery bypass grafts. *Ann Thorac Surg* 1987;44:199-200.
- He GW, Taggart DP. Spasm in arterial grafts in coronary artery bypass grafting surgery. *Ann Thorac Surg* 2016;101:1222-9.
- He GW, Taggart DP. Antispastic management in arterial grafts in CABG. *Ann Thorac Surg* 2016;102:659-68.
- Tarhan A, Kehlibar T, Yapici F, Yilmaz M, Arslan Y, Yapici N, *et al.* Role of physiological state 'normothermia' in internal thoracic artery spasm after harvesting. *Euro J Cardiothorac Surg* 2006;30:749-52.
- Buxton BF, Hayward PA. The art of arterial revascularization—total arterial revascularization in patients with triple vessel coronary artery disease. *Ann Cardiothorac Surg* 2013;2:543-51.
- Tatoulis J, Buxton BF, Fuller JA. Patencies of 2127 arterial to coronary conduits over 15 years. *Ann Thorac Surg* 2004;77:93-101.
- Magee MJ, Alexander JH, Hafley G, Ferguson TB Jr, Gibson CM, Harrington RA, *et al.* Coronary artery bypass graft failure after on-pump and off-pump coronary artery bypass: Findings from PREVENT IV. *Ann Thorac Surg* 2008;85:494-9; discussion 499-500.
- FitzGibbon GM, Kafka HP, Leach AJ, Burton JR. Interventions for coronary stenosis—A Canadian experience of 30 revolutionary years. *Can J Cardiol* 1996;12:893-900.
- Mills NL, Bringaze WL. Preparation of the internal mammary artery graft. Which is the best method? *J Thorac Cardiovasc Surg* 1989;98:73-9.
- Zabeeda D, Medalion B, Cohen AJ. Comparison of systemic vasodilators: Effects on flow in internal mammary and radial arteries. *Ann Thorac Surg* 2001;71:138-41.
- Liu JJ, Doolan LA, Xie B, Chen JR, Buxton BF. Direct vasodilator effect of milrinone, an inotropic drug, on arterial coronary bypass grafts. *J Thorac Cardiovasc Surg* 1997;113:108-13.
- Mäyränpää M, Simpanen J, Hess MW, Werkkala K, Kovanen PT. Arterial endothelial denudation by intraluminal use of papaverine-NaCl solution in coronary bypass surgery. *Eur J Cardiothorac Surg* 2004;25:560-6.
- Dregelid E, Heldal K, Resch F, Strangeland L, Breivik K, Svendsen E. Dilation of the internal mammary artery by external and intraluminal papaverine application. *J Thorac Cardiovasc Surg* 1995;110:697-703.
- Uzulku M, Aygan F. Effect of LIMA harvest technique on postoperative drainage in off pump CABG. *Braz J Cardiovasc Surg* 2016;31:120-6.
- Mulay AV, Dev KK, Nair RU. Prevention of internal thoracic artery spasm. *Ann Thorac Surg* 1997;6:564.
- Girard DS, Sutton JP 3<sup>rd</sup>, Williams TH, Crumbley AJ 3<sup>rd</sup>, Zellner JL, Kratz JM, *et al.* Papaverine delivery to the internal mammary artery pedicle effectively treats spasm. *Ann Thorac Surg* 2004;78:1295-8.
- Cooper GJ, Wilkinson GAL, Angelini GD. Overcoming perioperative spasm of the internal mammary artery: Which is the best vasodilator? *J Thorac Cardiovasc Surg* 1992;104:465-8.
- Bilgen F, Yapici F, Serbetcioglu A, Tarhan A, Coruh T, Ozler A. Effect of normothermic papaverine to relieve intraoperative spasm of the internal thoracic artery. *Ann Thorac Surg* 1996;62:769-71.
- Vilandt J, Kjaergard H, Aggestrup S, Andreasen JJ, Olesen A. Intraluminal papaverine with pH 3 doubles blood flow in the internal mammary artery. *Scand Cardiovasc J* 1999;33:330-2.
- Sasson L, Cohen AJ, Hauptman E, Schachner A. Effect of topical vasodilators on internal mammary arteries. *Ann Thorac Surg* 1995;59:494-6.
- Weiss AJ, Zhao S, Tian DH, Taggart DP, Yan TD. A meta-analysis comparing bilateral internal mammary artery with left internal mammary artery for coronary artery bypass grafting. *Ann Cardiothorac Surg* 2013;2:390-400.
- Grau JB, Ferrari G, Mak AW, Shaw RE, Brizzio ME, Mindich BP, *et al.* Propensity matched analysis of bilateral internal mammary artery versus single left internal mammary artery grafting at 17-year follow-up: Validation of a contemporary surgical experience. *Eur J Cardiothorac Surg* 2012;41:770-6.
- Kamiya H, Akhyari P, Martens A, Karck M, Haverich A, Lichtenberg A, Lichtenberg, Sternal microcirculation after skeletonized versus pedicled harvesting of the internal thoracic artery: A randomized study. *J Thorac Cardiovasc Surg* 2008;135:32-7.