



Received: 2016.05.25
Accepted: 2016.06.17
Published: 2017.01.24

Authors' Contribution:

- A** Study Design
- B** Data Collection
- C** Statistical Analysis
- D** Data Interpretation
- E** Manuscript Preparation
- F** Literature Search
- G** Funds Collection

Portal Annular Pancreas: A Rare and Overlooked Anomaly

Puneet Mittal^{1ABCDEF}, Ranjana Gupta^{1ABCDEF}, Amit Mittal^{1ABCDEF}, Arshad Ahmed^{2ACDEF}

¹ Department of Radiodiagnosis, Maharishi Markandeshwar Institute of Medical Sciences & Research, Mullana, Ambala, Haryana, India

² Department of Radiodiagnosis, Maharishi Markandeshwar Medial College & Hospital, Kumarhatti, Solan, Himachal Pradesh, India

Author's address: Puneet Mittal, Department of Radiodiagnosis, Maharishi Markandeshwar Institute of Medical Sciences and Research, Mullana (Distt-Ambala), Haryana, India, e-mail: drpuneetmittal@gmail.com

Summary

Background:

Portal annular pancreas is a rare pancreatic developmental anomaly which is often overlooked at imaging, and often diagnosed retrospectively when it is detected incidentally at the time of surgery. Although the anomaly itself is asymptomatic, it becomes important in cases where pancreatic resection/anastomosis is planned, because of varying ductal anatomy, risk of ductal injury and increased risk of postoperative pancreatic fistula formation.

Case Report:

We present imaging findings in a case of portal annular pancreas in a 45-year-old male patient.

Conclusions:

Portal annular pancreas is a rare and often neglected pancreatic anomaly due to a lack of awareness of this entity. With the advent of MDCT and MRI, accurate preoperative diagnosis of this condition is possible.

MeSH Keywords:

Magnetic Resonance Imaging • Multidetector Computed Tomography • Pancreatic Ducts • Portal Vein

PDF file:

<http://www.polradiol.com/abstract/index/idArt/899733>

Background

Portal annular pancreas is a rare congenital anomaly which is characterised by a complete circumferential encasement of the portal vein by pancreatic tissue. Its exact incidence is unknown as only few cases have been reported in the literature and many of them have been diagnosed incidentally at the time of surgery [1,2]. With the advent of multidetector computed tomography (MDCT) allowing thin slices and direct multiplanar imaging as well as with the advances in magnetic resonance imaging (MRI), it is possible to diagnose this condition accurately on imaging [3].

Case Report

A 45-year-old male patient with chronic Budd Chiari disease presented for a triphasic computed tomography (CT) scan of the abdomen to rule out a mass lesion due to poor acoustic window and heterogeneous hepatic echotexture on sonography. The patient underwent contrast-enhanced CT in a 128 slice MDCT scanner (Ingenuity CT, Philips

Healthcare, Cleveland, OH). The CT showed an intrapancreatic course of the portal vein with the pancreatic duct coursing anteriorly to it. The pancreatic duct was tortuous in the head region and was visualized partially. MRI was performed on a 1.5T MRI scanner (Philips Medical systems, the Netherlands), which revealed a tortuous course of the pancreatic duct without any evidence of divisum (Figures 1, 2). Based on the MDCT and MRI findings, a diagnosis of type III portal annular pancreas was made.

Discussion

During embryogenesis, pancreas is formed through two buds – the ventral and dorsal buds. The ventral bud forms the body and tail of pancreas and a small part of the head. The dorsal bud forms the majority of the head portion of pancreas and its uncinuate process. There is a posterior rotation of the ventral duct during early embryogenesis with its fusion with the dorsal duct on the right side of the portal vein. In rare cases, the fusion takes place to the left of portal vein which results in anomalous

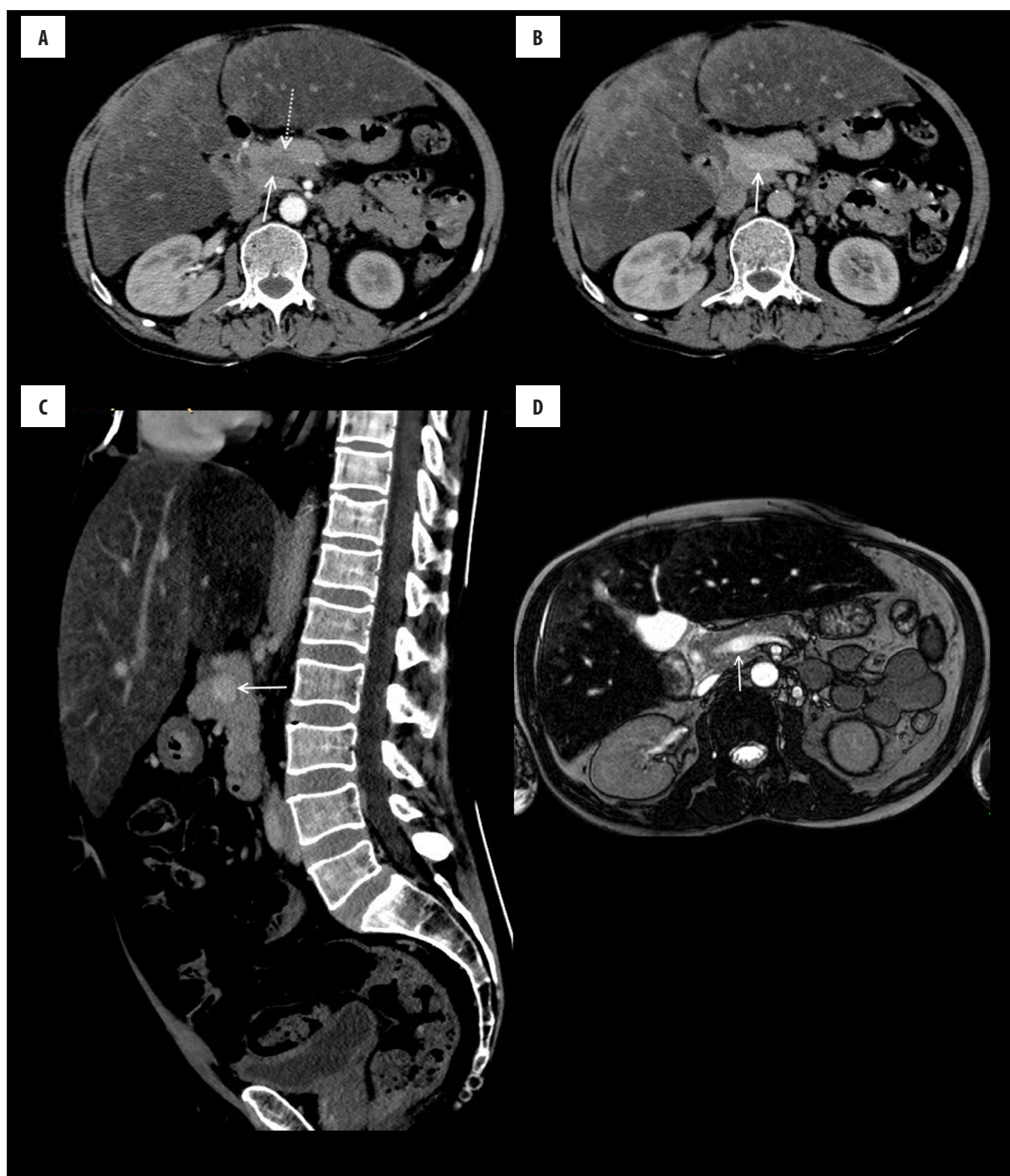


Figure 1. Axial arterial phase (A) and portal venous phase (B) and sagittal portal venous phase (C) CECT images showing a complete intrapancreatic course of the portal vein (white arrows). Pancreatic duct is seen to course anteriorly to the portal vein (dotted white arrow in A). Axial BTFE MR image (D) also shows a complete intrapancreatic course of the portal vein.

intrapancreatic course of the portal vein or the superior mesenteric vein [3].

Based on the variation in pancreatic ductal anatomy, three subtypes have been suggested. In type I, pancreatic ducts fuse and course posteriorly to the portal vein. In type II, there is pancreatic divisum with two ducts coursing anteriorly and posteriorly to the portal vein. In type III, the ducts course entirely anteriorly to the portal vein as was seen

in our case. Other rare types have also been defined, e.g. an encircling of the portal vein by the pancreatic duct that was forming a ring [1,4].

Contrast-enhanced MDCT is sufficient for preoperative diagnosis of this anomaly. With multiplanar imaging, a complete encasement of the portal vein by pancreatic tissue can be easily depicted. MRI can provide additional information on the ductal anatomy, which is often anomalous in such cases.

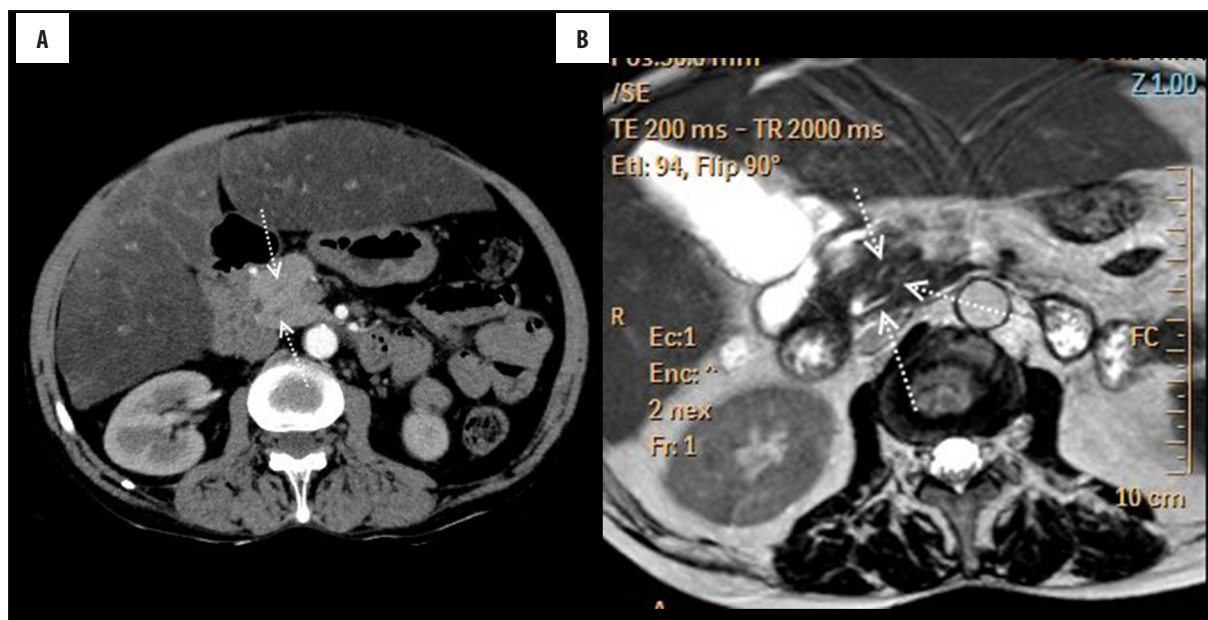


Figure 2. Axial arterial phase CECT (A) and axial T2W MR (B) images showing a tortuous course of the pancreatic duct in the head region (dotted white arrows).

Although this anomaly is clinically silent and asymptomatic, it becomes important in cases where pancreatic surgery is considered. Due to varying ductal anatomy, there is an increased risk of ductal injury during pancreatic resection and reconstruction procedures with a resultant increased risk of postoperative pancreatic fistula [1,5]. Therefore, preoperative diagnosis can be helpful for preoperative planning of the surgery. Moreover, intraoperative pancreatogram may be considered to better delineate the ductal anatomy in such cases.

Conclusions

Portal annular pancreas is a rare and often neglected pancreatic anomaly which can be diagnosed on MDCT. Radiologists should be aware of this entity and its surgical significance. Accurate preoperative diagnosis can assist in surgical planning and prevent/reduce potential complications.

Conflicting Interest

None.

References:

1. Harnoss JM, Harnoss JC, Diener MK et al: Portal annular pancreas: A systematic review of a clinical challenge. *Pancreas*, 2014; 43(7): 981-86
2. Matsumoto I, Shinzeki M, Fukumoto T, Ku Y: An extremely rare portal annular pancreas for pancreaticoduodenectomy with a special note on the pancreatic duct management in the dorsal pancreas. *Surgery*, 2013; 153(3): 434-36
3. Padmavathi G, Varalakshmi KL, Jyothi N Nayak: Portal annular pancreas - a case report. *Int J Med Res Rev*, 2014; 2(3): 259-61
4. Lath CO, Agrawal DS, Timins ME, Wein MM: Portal annular pancreas: The pancreatic duct ring sign on MRCP. *Radiol Case Rep*, 2015; 10(4): 42-25
5. Narita M, Hata H, Ikai I: Portal annular pancreas: An unusual pancreatic anomaly. *J Visc Surg*, 2016; 153(2): 153-55