

Arrhythmogenic triggers associated with an autonomic response from a posteroseptal region after extensive ablation in a patient with long-standing atrial fibrillation



Naoto Kino, MD, Toshiya Kurotobi, MD, PhD, Kazato Ito, MD, Daisuke Tonomura, MD, Kentaro Yano, MD, Yoshihisa Shimada, MD, PhD

From the Cardiovascular Division, Shiroyama Hospital, Habikino City, Osaka, Japan.

Introduction

The hyperactivity of the intrinsic cardiac autonomic nervous system (CANS) can cause rapid firing from pulmonary vein (PV) and non-PV sites, and the preserved CANS response after ablation may be associated with the recurrence of atrial fibrillation (AF) in patients with long-standing AF.

Case report

A 51-year-old man without any significant past illnesses but suffering from frequent palpitations due to long-standing persistent AF was referred to our institution. The patient had suffered from AF for 7 years, and the duration of persistent AF was at least no less than 3 years. The findings from the chest radiograph, laboratory data, including the thyroid hormone level, and echocardiography data, including the left atrial diameter, were within normal limits. After obtaining informed consent, an electrophysiological study and catheter ablation procedure were performed; however, 4 ablation sessions were required to improve the daily AF episodes in this case.

Summary of the first to third sessions

First session

We initially performed a PV isolation procedure using a double circular mapping catheter technique. We confirmed the success of the electrical PV isolation by monitoring the circumferential electrical isolation at the antrum level: approximately 2 cm from the ostium of both the right and left PVs. An additional roof line was created, and then

KEYWORDS Autonomic nervous system; Atrial fibrillation; Coronary sinus ostium; Ganglionated plexi

ABBREVIATIONS AF = atrial fibrillation; CS = coronary sinus; GP = ganglionated plexus; PV = pulmonary vein; RF = radiofrequency (Heart Rhythm Case Reports 2015;1:68–72)

Address reprint requests and correspondence: Dr Toshiya Kurotobi, Cardiovascular Division, Shiroyama Hospital, 2-8-1, Habikino, Habikino City, Osaka 583-0872, Japan. E-mail address: drk21cent@gmail.com.

bidirectional conduction block of the line was confirmed. Sinus rhythm was restored after the first session, and AF shifted from persistent to paroxysmal during the subsequent periods.

Second session

A second session was performed 1 year after the first session. PV reconnections were observed in the 4 PVs; therefore, we isolated the PV potentials at the reconnected PVs once again. Then, we ablated the left and right inferior ganglionated plexus (GP) region.

Third session

A third session was performed 3 months after the second session. The PV potentials were completely delineated, and an additional mitral isthmus line was created, resulting in complete electrical conduction block, and the superior vena cava was electrically isolated. Finally, we confirmed the noninducibility of AF with spontaneous sinus rhythm recovery by burst pacing of up to 150 ms at the end of the procedure.

The fourth session was performed 3 months after the third session. AF induced by burst atrial pacing spontaneously recovered to sinus rhythm, and no further AF occurred under an isoproterenol infusion (2 µg/min). When the dose of isoproterenol was increased to a high dose (20 µg/min), spontaneous AF abruptly occurred. After several direct cardioversions, subsequent AF incessantly occurred. The earliest activated area was always consistent with the area at the coronary sinus (CS) ostium (Figure 1).

The AF spontaneously terminated just after an injection of contrast medium into the CS ostium (Figure 1B), and the reproducibility of this termination was confirmed by a saline infusion. A remarkable bradycardic response during high-frequency stimulation was also confirmed in that area (Figure 2A). Radiofrequency (RF) energy applications of up to 35 W successfully terminated the AF at the base of an aneurysm and the CS ostium. Although AF still

KEY TEACHING POINTS

- Non-pulmonary vein (PV) foci are likely to be involved in the development of persistent atrial fibrillation (AF), and non-PV foci can sometimes arise from the coronary sinus ostium after extensive catheter ablation.
- In this case, the administration of a high dose of isoproterenol revealed non-PV triggers arising from the coronary sinus ostium, and the high-frequency stimulation technique at that site caused a remarkable bradycardic response, suggesting the location of ganglionated plexi.
- Because the residual non-PV foci after an extensive PV isolation are associated with an increased incidence of AF episodes in patients with long-standing AF, further attention should be paid to that area to improve the outcome of AF ablation in some treatment-resistant types of long-standing AF.

spontaneously recurred after that RF application, the incidence of AF occurrences and their persistence gradually decreased after multiple RF applications directed toward the CS ostial area (Figure 2B) and finally led to no further occurrences of AF without a CS disconnection (Figure 3). The bradycardic response to high-frequency stimulation also completely disappeared after the ablation. During the follow-up, a few AF episodes within 30 minutes occurred only in the setting of hard exercise training for a triathlon. After a beta-blocker medication (bisoprolol 5 mg/d), the AF episodes no longer occurred for 6 months.

Discussion

A rapidly firing source could be responsible for initiating AF and is mainly initiated by PV triggers in patients with paroxysmal AF¹; however, the mechanisms underlying persistent AF are more complex and other additional mechanisms could promote the initiation and maintenance of AF. The atrial structural changes due to AF persistence might promote the inconsistency and prolongation of the atrial conduction, which would lead to the perpetuation of AF even after PV delineation. In this case, additional line creation after the PV delineation successfully led to no further AF persistence by delineating the reentrant AF substrate; however, latent non-PV foci were revealed after isoproterenol administration.

Multiple non-PV foci are likely to be involved in the development of persistent AF,² and non-PV foci can

sometimes arise from the CS ostium. The hyperactivity of the intrinsic cardiac autonomic nervous system causes the release of an excessive amount of acetylcholine and catecholamines, which may lead to rapid firing from PV and non-PV sites.³ Most of the non-PV foci maybe revealed during the administration of a high dose of isoproterenol (~20 µg/min) or following AF occurring after cardioversion.^{4,5} High-dose isoproterenol might induce a simultaneous activated response from the sympathetic and parasympathetic nervous systems, which could cause an increased arrhythmogenicity due to autonomic nervous coactivation.

Regarding the cellular mechanism, the sympathetic activation induced by isoproterenol may promote focal firing via a delayed afterdepolarization associated with triggered activity, and the following increased heart rate could facilitate an increased calcium transient current and action potential duration shortening. Furthermore, the vagal coactivation could activate the acetylcholine-dependent K⁺ current (I_{K_{ACh}}) and allow for conditions that would promote late phase 3 early afterdepolarizations and triggered activity.

The high-frequency stimulation technique allows for the localization of parasympathetic and sympathetic responses of GPs. The stimulation of intrinsic GPs, associated with a parasympathetic response caused by the release of acetylcholine, increases the vulnerability to AF by shortening the refractory period of the atrium and PV sleeves, which favors high intracellular calcium concentrations leading to early afterdepolarizations.⁶ The anatomic distribution and major clusters of areas with GP responses in the left atrium are located near the PV ostia and right and left inferior PV regions. In addition, the largest number of ganglia is located on the posterior surface of the right atrium adjacent to the interatrial groove, and those GPs present ganglia containing many more neurons than do the ganglia in other GPs.⁷ Our previous study also confirmed that major GP responses were observed at the posteroseptal lesion after an extensive PV isolation procedure.⁸ This evidence may explain the clue why a number of RF applications were needed to suppress the autonomic activated AF occurrences around the CS ostium. Our previous study supported the necessity to vigorously delineate the residual non-PV foci after an extensive PV isolation procedure in patients with long-standing AF.⁹ Although the posteroseptal region around the CS ostium seems to be less important for the ablation of AF, further attention should be paid to that area to improve the outcome of AF ablation in some treatment-resistant types of long-standing AF.

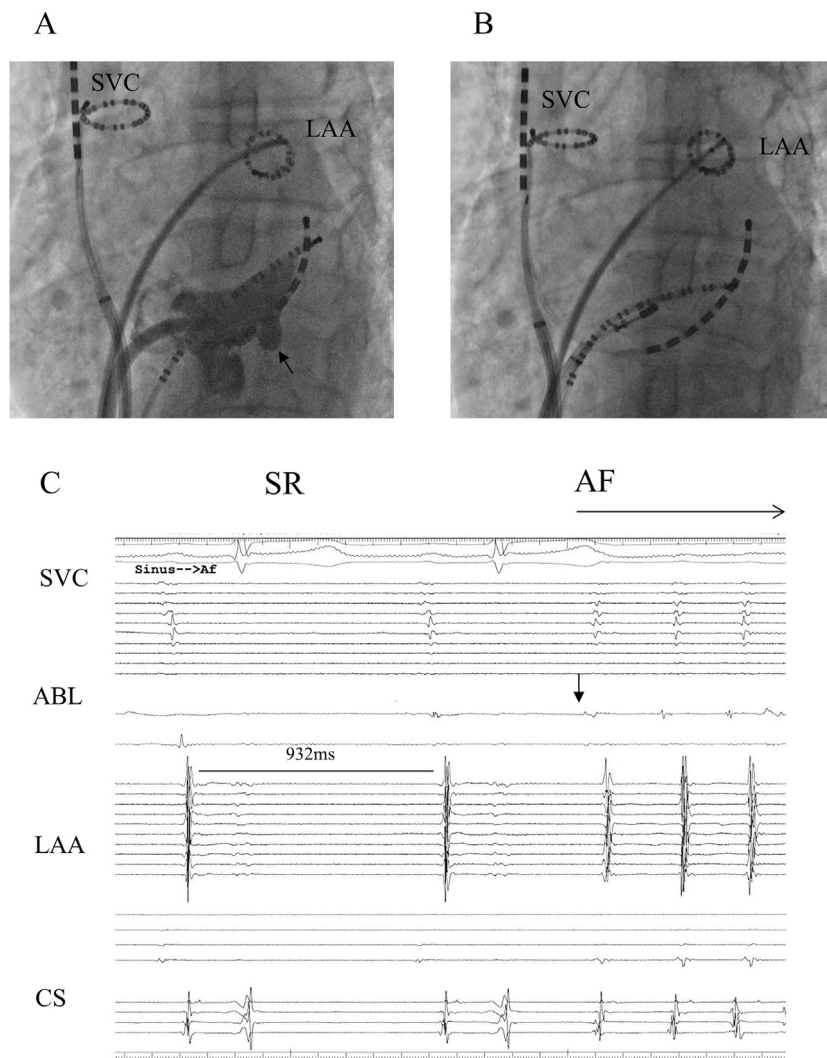


Figure 1 Contrast medium was injected from a long sheath located at the CS ostium into the AP projection. CS angiography revealed a dilated CS ostium with a diverticulum (arrow) (A). Adjustable 20-pole catheters are located in the LAA and the SVC ostium, and the ablation catheter is located at the upper margin of the CS ostium (B). After a contrast injection, the AF temporarily terminated, but a new AF episode immediately occurred. The earliest activated site was consistent with the CS ostium. Although multipolar catheters were widely spaced in both atria, the sequence of the earliest activation seems to be lined vertically, implying a focus originating from the septal region. The R-R interval during SR just before the AF initiation was 932 ms, implying that there was parasympathetic coactivation during the isoproterenol infusion (C). ABL = ablation; AF = atrial fibrillation; AP = anteroposterior; CS = coronary sinus; dis = distal electrode; LAA = left atrial appendage; prox = proximal electrode; SR = sinus rhythm; SVC = superior vena cava.

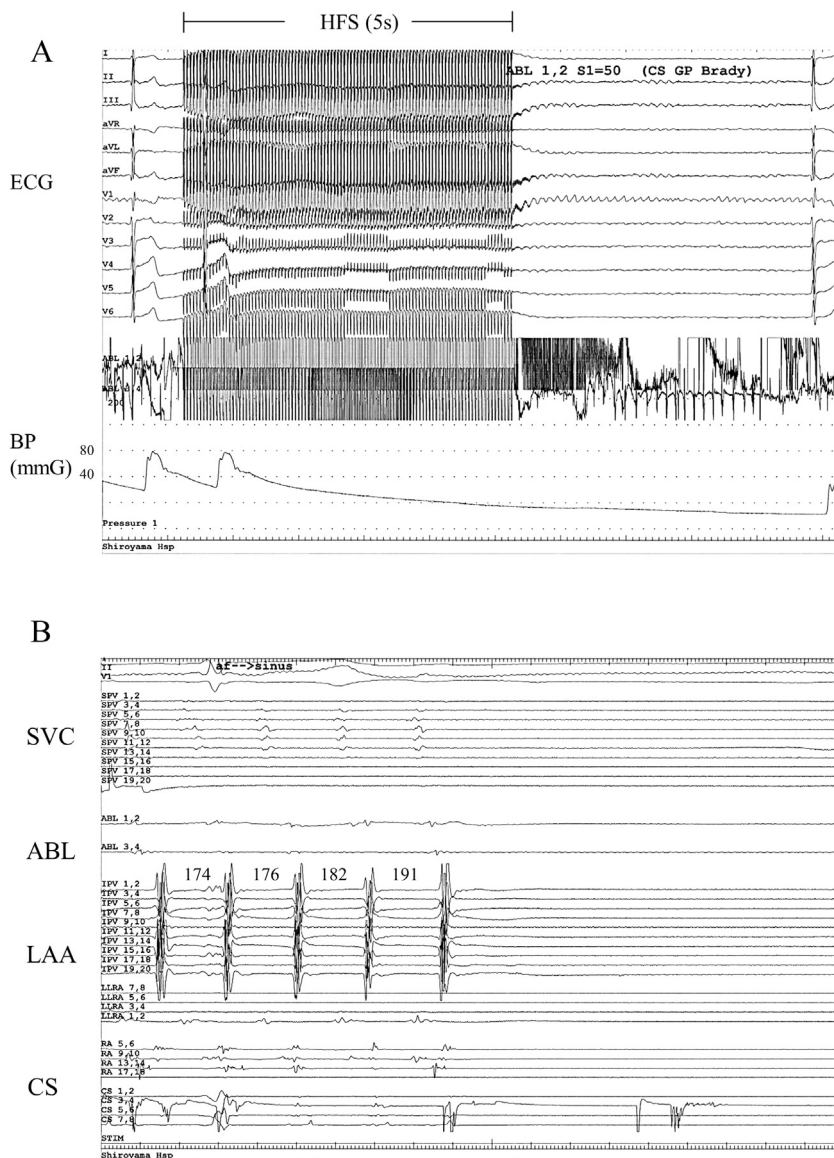


Figure 2 A remarkable bradycardic response during HFS (20 Hz, 30 mA, pulse width 10 ms) was also observed in that area. The mean heart rate was 100 beats/min, and the blood pressure was approximately 80 mm Hg just before the HFS (A). RF energy applications of up to 35 W successfully terminated the AF at the base of the aneurysm and the CS ostium. The AF cycle length just before the AF termination recorded in the LAA was 174–191 ms. Disorganized complex local electrograms were observed only around the CS ostium (B). ABL = ablation; AF = atrial fibrillation; CS = coronary sinus; BP = blood pressure; ECG = electrocardiogram; GP = ganglionated plexus; HFS = high-frequency stimulation; LAA = left atrial appendage; RF = radiofrequency; SVC = superior vena cava.

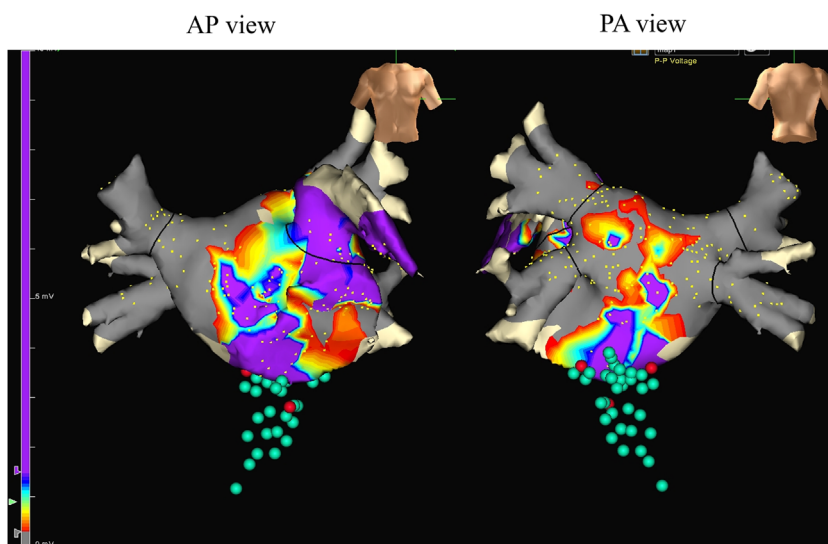


Figure 3 Voltage map using the NavX EnSite Velocity system (St Jude Medical, Inc, St. Paul, MN). The left panel is an AP view, and the right panel is a PA view. The voltage map shows a low-voltage scar zone detected around the PVs and left lateral area (gray, $< 0.2\text{ mV}$; purple, $> 1.5\text{ mV}$). The green dots represent the ablation sites (red dots, AF termination sites during an RF energy application possibly consistent with the CS ostium and the neck of the diverticulum). Multiple RF energy applications gradually decreased the incidence of any spontaneous AF occurrences, and then the AF could finally no longer be induced. AF = atrial fibrillation; AP = anteroposterior; CS = coronary sinus; PA = posteroanterior; PV = pulmonary vein; RF = radiofrequency.

References

- Haissaguerre M, Jais P, Shah DC, Takahashi A, Hocini M, Quiniou G, Garrigue S, Le Mouroux A, Le Metayer P, Clementy J. Spontaneous initiation of atrial fibrillation by ectopic beats originating in the pulmonary veins. *N Engl J Med* 1998;339:659–666.
- Kurotobi T, Iwakura K, Inoue K, Kimura R, Okamura A, Koyama Y, Tosyoshima Y, Ito N, Fujii K. Multiple arrhythmogenic foci associated with the development of perpetuation of atrial fibrillation. *Circ Arrhythm Electrophysiol* 2010;3:39–45.
- Ogawa M, Zhou S, Tan AY, Song J, Gholmieh G, Fishbein MC, Luo H, Siegel RJ, Karagueuzian HS, Chen LS, Lin SF, Chen PS. Left stellate ganglion and vagal nerve activity and cardiac arrhythmias in ambulatory dogs with pacing-induced congestive heart failure. *J Am Coll Cardiol* 2007;50:335–343.
- Kurotobi T, Ito H, Inoue K, Iwakura K, Kawano S, Okamura A, Date M, Fujii K. Marshall vein as arrhythmogenic source in patients with atrial fibrillation: correlation between its anatomy and electrophysiological findings. *J Cardiovasc Electrophysiol* 2006;17:1062–1067.
- Lin WS, Tai CT, Hsieh MH, Tsai CF, Lin YK, Tsao HM, Huang JL, Yu WC, Yang SP, Ding YA, Chang MS, Chen SA. Catheter ablation of paroxysmal atrial fibrillation initiated by non-pulmonary vein ectopy. *Circulation* 2003;107:3176–3183.
- Zipes DP, Mihalick MJ, Robbins GT. Effects of selective vagal and stellate ganglion stimulation of atrial refractoriness. *Cardiovasc Res* 1974;8:647–655.
- Armour JA, Murphy DA, Yuan BX, Macdonald S, Hopkins DA. Gross and microscopic anatomy of the human intrinsic cardiac nervous system. *Anat Rec* 1997;247:289–298.
- Kurotobi T, Shimada Y, Kino N, Ito K, Tonomura D, Yano K, Tanaka C, Yoshida M, Tsuchida T, Fukumoto H. Features of intrinsic ganglionated plexi in both atria after extensive pulmonary isolation and their clinical significance after catheter ablation in patients with atrial fibrillation [published online ahead of print November 26, 2014]. *Heart Rhythm* 2015;12:470–476.
- Kurotobi T, Shimada Y, Kino N, Ito K, Tonomura D, Yano K, Tanaka C, Yoshida M, Tsuchida T, Fukumoto H. Residual arrhythmogenic foci predict recurrence in long-standing persistent atrial fibrillation patients after sinus rhythm restoration ablation. *Can J Cardiol* 2014;30:1535–1540.