

Comparison of Antibodies to Detect Uroplakin in Urothelial Carcinomas

Heidi L. Kristoffersen, BMS, Rasmus Røge, MD, PhD, and Søren Nielsen, BMS

Abstract: Immunohistochemistry for Uroplakin (UP) II and III is used to determine urothelial origin of carcinomas of unknown primary site and are especially valuable to differentiate urothelial carcinomas (UCs) from lung squamous cell carcinomas and prostate carcinomas. In the Nordic immunohistochemical Quality Control assessment scheme, only 45% of the participants obtained a sufficient staining result for UP. Primary antibodies (Abs) against UPII were most successful with a pass rate of 86%. No Abs against UPIII provided sufficient staining results. A comparative study was carried out on a larger cohort of tissue samples with optimized methods for the UPII mouse monoclonal antibody (mmAb) clone BC21, UPIII mmAb clone AU-1, and rabbit monoclonal antibody (rmAb) clone SP73 to evaluate the performance in a standardized way. Tissue microarrays containing 58 UCs, 111 non-UCs, and 20 normal tissues were included. The UP stains were evaluated by using H-score. Based on H-scores, samples were categorized as high-expressor (150 to 300), moderate-expressor (10 to 149), low-expressor (1 to 9), and negative (<1). The UPII mmAb clone BC21 obtained a significant higher analytical sensitivity of 69% for UCs compared with the UPIII Abs mmAb clone AU-1 and rmAb clone SP73 with 19% and 29%, respectively. No high-expressor UCs were seen for the UPIII Abs, whereas 13% of the positive UCs obtained an H-score > 150 for the UPII Ab. The 2 UPIII Abs gave an analytical specificity of 100% compared with 97% for the UPII Ab being positive in 2 ovarian carcinomas and 1 cervical squamous cell carcinoma.

Key Words: Uroplakin, urothelial carcinomas, antibody clone, immunohistochemistry, external quality control

(*Appl Immunohistochem Mol Morphol* 2022;30:326–332)

Uroplakins (UPs) are a family of cell membrane glycoproteins that link with each other and create plaques on the apical surface of urothelium. At present, 4 main types of

UPs have been identified – UPIa, UPIb, UPII, and UPIII.¹ Immunohistochemistry (IHC) for UPII and UPIII is primarily used to determine the origin of a cancer of unknown primary site (CUP). Many publications focused on IHC for UPIII indicate a high analytical specificity but only a moderate analytical sensitivity for primary and metastatic invasive urothelial carcinoma (UC) in the range of 19% to 53%.^{2,3} Recently, antibodies (Abs) for UPII have been reported to provide an increased analytical sensitivity for UCs compared with IHC for UPIII. Recent publications indicate a range of 63% to 68%^{3,4} for UPII, where both UPII and UPIII show higher expression levels in primary UCs compared with metastatic UCs.

In 2020, the Nordic Immunohistochemical Quality Control (NordiQC) program performed the first assessment of UP. The purpose was to evaluate the technical performance of IHC assays and of central interest the level of analytical sensitivity and specificity of IHC tests for UPII/III, identifying and characterizing the urothelial origin of CUP. A total of 66 laboratories participated in the assessment and received sections from a tissue microarray (TMA) constructed by NordiQC. The laboratories stained the sections using their standard protocol for UP and returned one slide to NordiQC for assessment. A total of 45% of the participants obtained a sufficient staining result. The data analysis showed that primary Abs against UPII were most successful, with a pass rate of 86%. In contrast, Abs against UPIII all gave an insufficient staining result (0% pass rate), typically characterized by too weak or completely false negative results for UP.⁵ A total of 47% of the laboratories participating in the NordiQC assessment for UP used Abs against the unsuccessful UPIII, despite published literature indicates Abs toward UPII having a higher analytical sensitivity compared with UPIII.

In previously published studies, data for analytical sensitivity and specificity have mainly been generated using the UPIII mouse monoclonal antibody (mmAb) clone AU-1 and the UPII mmAb clone BC21. In the NordiQC assessment of UP, 39% of the participants used the rabbit monoclonal antibody (rmAb) clone SP73 for UPIII. To our knowledge, no data regarding analytical sensitivity and specificity have been published for this Ab clone.

The purpose of this study was to evaluate the analytical sensitivity and specificity and hereby diagnostic potential of the new UPIII rmAb SP73 clone compared with the 2 well-described and -characterized Abs (AU-1 and BC21) in a larger cohort of UC and non-UC tissue samples using optimized methods for all 3 Abs.

Received for publication August 26, 2021; accepted February 18, 2022. From the NordiQC, Institute of Pathology, Aalborg University Hospital, Aalborg, Denmark.

The authors declare no conflict of interest.

Reprints: Heidi L. Kristoffersen, BMS, NordiQC, Institute of Pathology, Aalborg University Hospital, Ladegårdsvej 3, Aalborg 9000, Denmark (e-mail: heidi.kristoffersen@rn.dk).

Copyright © 2022 The Author(s). Published by Wolters Kluwer Health, Inc. This is an open access article distributed under the terms of the Creative Commons Attribution-Non Commercial-No Derivatives License 4.0 (CCBY-NC-ND), where it is permissible to download and share the work provided it is properly cited. The work cannot be changed in any way or used commercially without permission from the journal.

MATERIALS AND METHODS

Tissue Specimens

Nine different TMAs with a core diameter between 1 and 4 mm, comprising formalin-fixed paraffin-embedded tissue samples of both normal and neoplastic tissues, were used in this study. All samples were fixed in neutral phosphate buffered formalin for 24 to 48 hours. In total, 73 samples of various normal tissue types, 58 surgical samples of primary UCs, and 111 samples of neoplastic non-UCs were included (see Table 1 for non-UCs).

Of the 58 UCs, 56 (97%) included in the study were characterized as GATA3 IHC positive using a cutoff of 1%.

Using the “TNM staging system,” the 58 UCs included 9 UCs categorized as T1-, 18 as T2-, 27 as T3-, and 4 as T4-tumours. One TMA containing UCs was purchased from US Biomax (Rockville, MD) and the remaining 8 TMAs were constructed in-house at the Department of Pathology, Aalborg University Hospital, Denmark. Sections were cut at 3 to 5 µm, dried overnight at room temperature, and baked for 30 minutes at 60°C before IHC staining.

Immunohistochemistry

Three Abs were used in this study: 2 Abs against UPIII and 1 against UPII. The UPIII Abs, both from Cell Marque (Merck KGaA, Darmstadt, Germany), were based on the mmAb clone AU-1 and rmAb clone SP73,

and the UPII from Biocare Medical (Pacheco, CA) was based on the mmAb clone BC21. The mmAbs AU-1 and BC21 were applied in concentrated (conc.) formats, and the rmAb SP73 was applied in a ready-to-use format.

The conc. Abs were diluted in EnVision Flex Antibody Diluent from Agilent (Santa Clara, CA), and the IHC stainings were performed on a Ventana BenchMark Ultra platform, Roche (Basel, Switzerland).

Protocols for each Ab were optimized to give the highest possible technical signal-to-noise ratio and were initially applied on a TMA with 20 normal tissues as bladder and urethra, expected to be positive, and different normal tissues as appendix, kidney, lung, etc. expected to be negative. In addition, the protocols were also tested on the NordiQC TMA used in the first assessment of UP.^{5,6} The conc. UPIII mmAb clone AU-1 were tested on both Ventana BenchMark Ultra, Roche, and Dako Omnis, Agilent, platforms, using various protocol settings for optimization, eg, heat-induced epitope retrieval in high and low pH buffers and a titration range. The basic vendor recommended protocol settings, regarding HIER conditions, Ab incubation time, and detection systems, were tested in addition to a preidentified standard IHC protocol applied by the laboratory for most primary Abs. The vendor recommended and final selected and optimized protocols are listed in Table 2.

In brief, the final IHC staining was performed on the fully automated BenchMark Ultra platform (Ventana), starting with deparaffinization followed by HIER in Cell Conditioning (CC1) pH 8.5 for 48 minutes at 99°C, incubation of primary Ab for 32 to 64 minutes at 36°C, OptiView DAB as detection system and contrast staining using Hematoxylin II and Bluing reagent. All reagents were from Ventana. The slides were manually washed in soap, dehydrated, and then mounted on Tissue-Tek Film (Sakura Finetek, Torrance, CA) coverslipper.

Evaluation

Slides were scanned using NanoZoomer 360 (Hamamatsu, Hamamatsu City, Shizuoka Pref., Japan). Assessment was conducted on a digital monitor using NDP.view2 Viewing software (Hamamatsu), where the individual TMA cores stained with the 3 Abs were aligned and viewed simultaneously. For each core and Ab, a H-score⁷ by consensus of the 3 authors was determined, based on the percentages of cells stained with the intensities 0 (none), 1+ (weak), 2+ (moderate), and 3+ (strong) giving a H-score between 0 and 300. A tumor was classified as high-expressor if obtaining a H-score between 150 and 300, moderate-expressor between 10 and 149, low-expressor between 1 and 9, and negative < 1.

RESULTS

Immunoreaction in Normal Tissues

Bladder and urethra showed a positive staining reaction for all 3 Abs (see urethra in Figs. 1A–C). The UPII mmAb clone BC21 gave a strong membranous and cytoplasmic staining reaction in virtually all umbrella cells and a weak to

TABLE 1. Nonurothelial Carcinomas

Neoplasia	No.
Diffuse large B-cell lymphoma	4
Cervical squamous cell carcinoma	1
Colon adenocarcinoma	5
Ductal breast carcinoma	4
Follicular lymphoma	2
Gastric adenocarcinoma	3
Gastrointestinal stromal tumor	1
Hepatocellular carcinoma	3
Hodgkin lymphoma	2
Intestinal neuroendocrine neoplasia	3
Lung neuroendocrine neoplasia	1
Leiomyoma	2
Leiomyosarcoma	2
Lobular breast carcinoma	4
Lung adenocarcinoma	4
Lung squamous cell carcinoma	23
Malignant melanoma	5
Ovarian serous carcinoma	4
Ovarian clear cell carcinoma	1
Ovarian endometrioid carcinoma	1
Pancreas adenocarcinoma	4
Prostate adenocarcinoma	11
Renal clear cell carcinoma	4
Renal papillary carcinoma	3
Rhabdomyosarcoma	1
Seminoma	1
Small cell lung carcinoma	2
T-cell lymphoma	2
Thyroid follicular carcinoma	1
Thyroid medullary carcinoma	1
Thyroid papillary carcinoma	3
Undifferentiated carcinoma	2
Uterine endocervical adenocarcinoma	1
Total	111

TABLE 2. Protocol Settings

Antibodies	Vendor Recommended Protocols				Optimized Protocols			
	Dilution	Epitope Retrieval	Primary Ab Incubation	Detection System	Dilution	Epitope Retrieval	Primary Ab Incubation	Detection System
mmAb AU-1 conc. Cell Marque Product no.: 345M-15	1:25-1:100	HIER Trilogy	10-30 min	HiDef HRP	1:80	HIER CCI 48 min, 99°C	64 min, 36°C	OptiView DAB Detection Kit
mmAb BC21 conc. Biocare Medical Product no.: ACI 3051 A	1:100	HIER Reveal Decloaker	30 min	MACH 4	1:25	HIER CCI 48 min, 99°C	32 min, 36°C	OptiView DAB Detection Kit
mmAb SP73 RTU Cell Marque Product no.: 760-4533	Prediluted	HIER CCI, 64 min	32 min	ultraView Universal DAB Detection Kit	Prediluted	HIER CCI 48 min, 99°C	64 min, 36°C	OptiView DAB Detection Kit

All stains are performed on the BenchMark Ultra, Ventana. Vendor recommended protocols are accessed online on August 17, 2021. CCI indicates Cell Conditioning 1; conc., concentrate; HIER, heat-induced epitope retrieval; mmAb, mouse monoclonal antibody; rmAb, rabbit monoclonal antibody; RTU, ready-to-use.

moderate staining reaction in most intermediate urothelial cells. A moderate, predominantly membranous staining reaction in most umbrella cells was obtained for UPIII rmAb clone SP73, whereas the UPIII mmAb clone AU-1 showed weak to moderate membranous staining reaction in the majority of umbrella cells. The UPIII mmAb clone AU-1 gave a weak background staining in more tissue types in the TMA with normal tissues, eg, kidney and esophagus. This was accepted, to evaluate the highest analytical sensitivity obtainable in the UCs (Figs. 1D–F). No staining reaction was seen in other normal tissues for the 3 Abs.

Immunoreaction in Urothelial Carcinomas

The UPII mmAb clone BC21 provided the highest analytical sensitivity of 69% in the UCs tested compared with UPIIIs rmAb clone SP73 and mmAb clone AU-1 with an analytical sensitivity of 29% and 19%, respectively (Table 3). Eight UCs were classified as high-expressor tumors using the UPII mmAb clone BC21 with a H-score between 150 and 210. No high-expressor UCs were obtained for the Abs against UPIII, rmAb clone SP73, and mmAb clone AU-1 (Table 3). UCs with medium expression were seen for all 3 Abs; however, the UPII mmAb clone BC21 provided a significant higher proportion of 38% compared with the 2 Abs against UPIII with 13% for the clone SP73 and 3% for clone AU-1. Figure 2 shows the range of H-scores for all 3 Abs in UCs. Focusing on UCs grouped by the TNM-staging system, more UCs categorized as T1 and T2 were positive for UP compared with T3 and T4 (Table 4). The UPII mmAb clone BC21 obtained a higher proportion of positive UCs in all T-stages compared with the UPIII Abs.

The 18 UCs negative for UPII mmAb clone BC21 were all negative for UPIIIs rmAb clone SP73 and mmAb clone AU-1. The UCs negative for GATA3 were also negative for UP Abs.

Immunoreaction in Neoplastic Nonurothelial Carcinomas

The 2 UPIII Abs were negative in all tested neoplastic non-UCs, giving an analytical specificity of 100% for both (Table 3). The UPII mmAb clone BC21 showed a positive staining reaction in 2 ovarian carcinomas (H-score at 2 and 37) and 1 cervical squamous cell carcinoma (H-score at 16) (Table 3), giving an analytical specificity of 97%. No staining reaction was observed in critical and common differential diagnostic cancers as lung squamous cell carcinomas or prostate carcinomas for the 3 Abs tested.

DISCUSSION

IHC for UP is useful to identify urothelial origin in the diagnostic work-up of CUP and as such in the differential diagnosis of, eg, UC from prostate or lung carcinoma, but the diagnostic utility has been compromised by a relatively low analytical sensitivity.^{3,8} The introduction of the mmAb clone BC21 toward UPII has shown to outperform the widely used clone AU-1 against UPIII, but no data are available on the performance of the

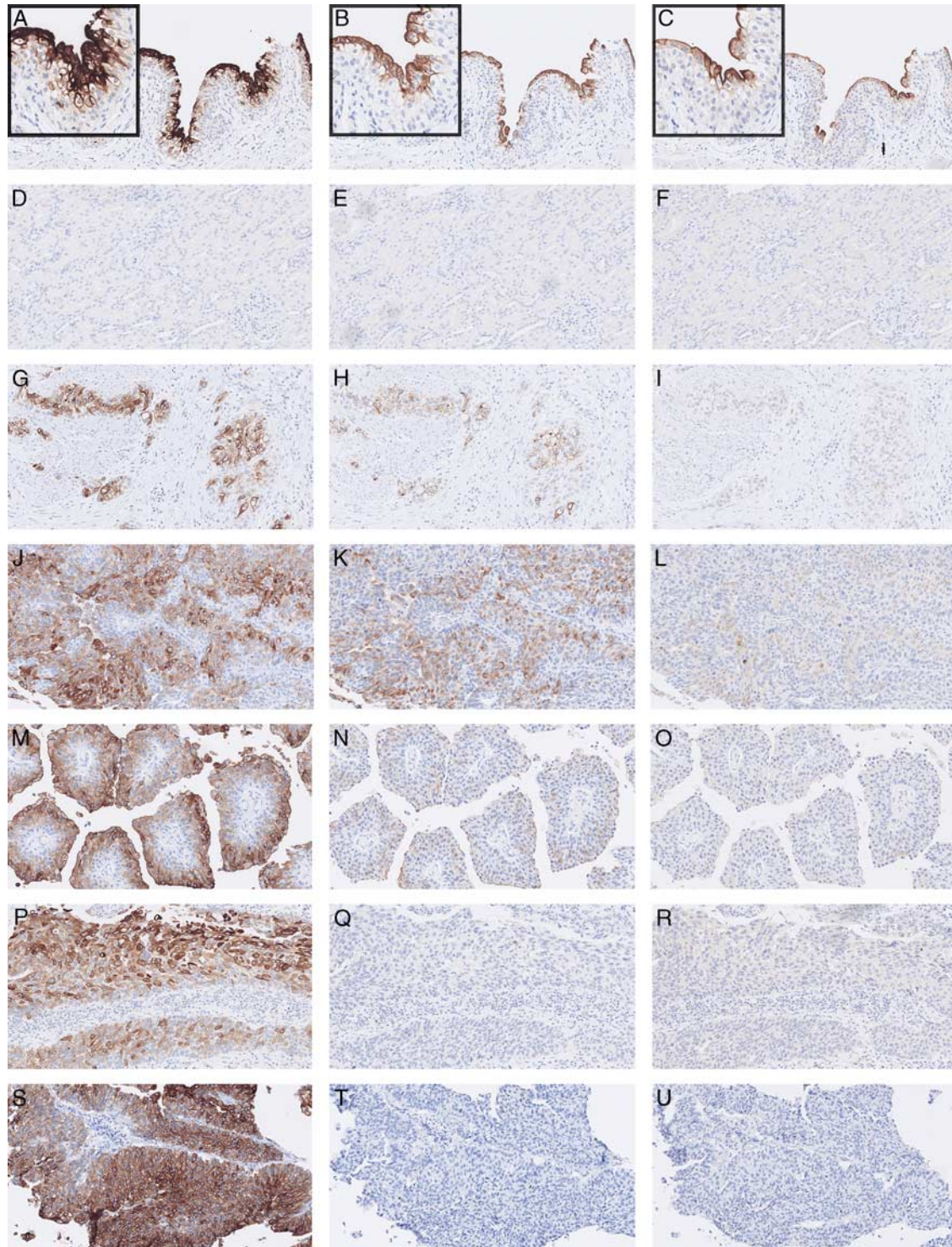


FIGURE 1. Examples of UP staining in normal tissue and UCs with various intensity using UPII mmAb clone BC21 (A, D, G, J, M, P, S), UPIII rmAb clone SP73 (B, E, H, K, N, Q, T), and UPIII mmAb clone AU-1 (C, F, I, L, O, R, U). A–C: normal urethra, insert high powerfield. D–F: normal kidney. G–I, J–L, M–O, P–R, and S–U: different UCs. mmAb indicates mouse monoclonal antibody; rmAb, rabbit monoclonal antibody; UCs, urothelial carcinomas; UP, uroplakin.

recently new UPIII rmAb clone SP73 compared with the 2 other well-described Abs. The NordiQC data for UP clearly indicated that the UPII mmAb clone BC21 was

most successful, but the inferior performance in the assessment of especially UPIII rmAb SP73 could be related to inappropriate protocols settings applied by the

TABLE 3. Results, H-scores

	mmAb BC21 Uroplakin II			rmAb SP73 Uroplakin III			mmAb AU-1 Uroplakin III		
	n	n%	Mean H-score	n	n%	Mean H-score	n	n%	Mean H-score
Urothelial carcinomas (n = 58)									
Positive total	40	69	72	17	29	19	11	19	4
High-expressor (H-score 150-300)	8	13	182	0	0	0	0	0	0
Medium-expressor (H-score 10-149)	23	38	60	8	13	36	2	3	10
Low-expressor (H-score 1-9)	9	15	6	9	15	3	9	15	3
Negative (H-score <1)	18	31	0	41	71	0	47	81	0
Nonurothelial carcinomas (n = 111)									
Positive total	3	3	18	0	0	0	0	0	0
High-expressor (H-score 150-300)	0	0	0	0	0	0	0	0	0
Medium-expressor (H-score 10-149)	2	2	27	0	0	0	0	0	0
Low-expressor (H-score 1-9)	1	1	2	0	0	0	0	0	0
Negative (H-score <1)	108	97	0	111	100	0	111	100	0

mmAb indicates mouse monoclonal antibody; rmAb, rabbit monoclonal antibody.

laboratories and not necessarily related to the clone. Consequently, the focus of this study was a direct comparison of the performance of three UP Abs with careful individually optimized protocols for each.

The results in this study showed that the UPIII mmAb clone BC21 obtained a significantly higher analytical sensitivity and more intense staining reactions in UCs compared with both UPIII Abs, as seen in the NordiQC assessment, and in line with other published studies comparing UP Abs.^{2,4,9} Despite optimizing the protocols for the 2 UPIII Abs, it was not possible to reach the same level of analytical sensitivity as for the UPII Ab.

Reviewing the literature for UPIII Abs, the most commonly applied Ab is the mmAb clone AU-1. The mmAb clone AU-1 was used by only 3% of the participants in the NordiQC assessment for UP, whereas the UPIII rmAb clone SP73 was used by 39%.

Focusing on the 2 UPIII Abs, the well-described mmAb clone AU-1 gave the lowest analytical sensitivity at 19% in this comparative study. If the sensitivity for the UPIII mmAb clone AU-1 was increased, an unspecific predominantly cytoplasmic staining reaction was seen in various cell types, complicating interpretation. It was not possible to reach the same level of analytical sensitivity as

described in 2 previously published studies using the UPIII Ab, both obtaining an overall sensitivity at 57%.^{10,11} One study of the UPIII mmAb clone AU-1 obtained a level of 62% and 56% positive T2 and T3/T4 UCs¹⁰ and a significantly higher positivity rate, compared with 22% and 13%, respectively, observed in this study. However, the low level of analytical sensitivity for UPIII, mmAb clone AU-1 observed in our study, has also been reported in other publications. Li et al¹² reported a positivity rate of 17% in conventional UCs (n = 105 samples) for the mmAb clone AU-1, compared with 44% obtained by the mmAb clone BC21 for UPII. In addition and also supportive to our data, Gruver et al⁸ obtained an analytical sensitivity for UPIII mmAb clone AU-1 of 20% for nonmetastatic UC, being the same level seen in our study and similar to the level of 20% to 50% reported by Paner et al.¹³

The low analytical sensitivity for the 2 UPIII Abs achieved in this study, compared with the initial data observed by Kauffmann et al,¹⁰ could be related to more factors and differences in the studies. An explanation of the inferior sensitivity in our study might be related to sample origin. We used TMA cores and hereby only a minor part of the tumor and as UP can be heterogeneously expressed, usage of whole sections as being applied by Kauffmann et al¹⁰ could give a higher level of analytical sensitivity, especially when a cutoff at 1% is being applied. However, this condition and limitation was the same for the 3 markers evaluated allowing for a direct comparison.

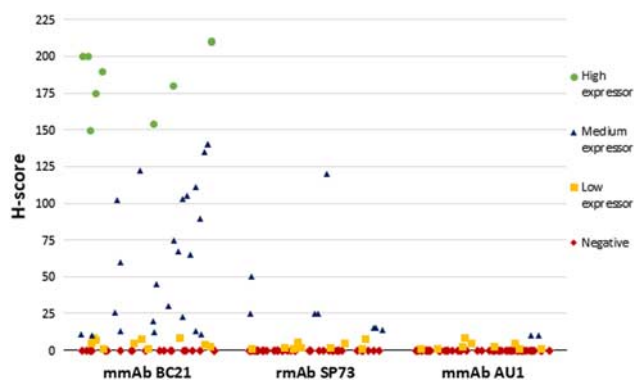


FIGURE 2. Jitter plot of H-scores for the 3 antibodies. mmAb indicates mouse monoclonal antibody; rmAb, rabbit monoclonal antibody.

TABLE 4. Number of Positive Urothelial Carcinomas Stratified in TNM Category T1-T4

	mmAb Clone BC21		rmAb Clone SP73		mmAb Clone AU-1	
	n	pos (pos%)	pos (pos%)	pos (pos%)		
T1	9	9 (100)	3 (33)	3 (33)		
T2	18	13 (72)	7 (39)	4 (22)		
T3	27	16 (59)	7 (26)	4 (15)		
T4	4	2 (50)	0 (0)	0 (0)		

mmAb indicates mouse monoclonal antibody; pos, positive; rmAb, rabbit monoclonal antibody.

The original study by Kaufmann et al¹⁰ was based on an IHC protocol using efficient HIER in an alkaline buffer in combination with an avidin-biotin-based detection system and no data on results observed for negative controls were reported. In theory, some of the positive cases could be related to endogenous biotin and not necessarily expression of UPIII. Our study and the studies by Smith et al⁴ and Li et al¹² were all based on polymer/multimer-based systems eliminating this risk. A study by Bussolati et al¹⁴ revealed that endogenous biotin was demonstrated in a high number of carcinomas and without taking this pitfall into consideration, a risk of false-positive results is introduced. In the study 29% (53 of 182) of neoplasias and 67% of bladder carcinomas showed positive reaction in tumor cells without application of a specific primary Ab and only incubation with an avidin-biotin-based detection system and as such potential “false positive” for any marker evaluated. In this context focusing on the low analytical sensitivity for the mmAb clone AU-1 in UC, several publications have not been able to confirm or validate the results obtained by Kaufmann et al,¹⁰ despite the biomarker has been commercially available for more than 20 years.

The relatively unknown rmAb clone SP73 for UPIII provided a higher analytical sensitivity at 29% compared with clone AU-1, but still not in the range of the UPII mmAb clone BC21. No background staining was seen during the optimization of the UPIII rmAb clone SP73, but it was not possible to achieve a stronger staining reaction by adjusting the protocol settings. It would have been preferred to use a conc. format of the UPIII rmAb clone SP73 as applied for the 2 mmAbs, but it was not available when the study was carried out. However, all methodological adjustments were tested to increase the sensitivity as much as possible including HIER, primary Ab incubation times and choice of detection system.

Fully in line with the NordiQC results, the UPII mmAb clone BC21 gave the best result, providing a significantly higher analytical sensitivity at 69% in UCs compared with the 2 UPIII Abs with 19% (mmAb AU-1) and 29% (rmAb SP73). Previously published studies focusing on the mmAb clone BC21 achieved similar results, with an analytical sensitivity for UCs in the range at 53% to 79%.^{2,9} However, even with optimal protocol settings, it was not possible to increase the moderate level of the analytical sensitivity of the UPII mmAb clone BC21 for UCs, giving limitations of the differential diagnostic use in the identification of urothelial lineage of CUP, if used as single marker. As indicated by Bellizzi and Tian,^{2,3} a panel of UPII and GATA3 could be beneficial to improve the analytical sensitivity of UC. However, the specificity will be reduced due to GATA3 reaction in more non-UCs. Tian et al² obtained an analytical sensitivity of 91% (cutoff 5% positivity) using UPII or GATA3 in UCs, but with a cost of a reduced analytical specificity (40%) compared with the level obtained by UPII as single marker (100%).

Hoang et al⁹ found the UPII mmAb clone BC21 to be almost 100% specific in neoplastic non-UCs. In this study, the UPII mmAb clone BC21 was found slightly less specific (97%) compared with the UPIII Abs (100%). One

cervical squamous cell carcinoma and 2 ovarian carcinomas were positive using the UPII Ab. In the “Instructions for Use” for the UPII Ab, all tested ovarian and cervix cancer were negative.¹⁵ This discrepancy might be related to different technical and scoring methods used in the Instructions for Use and this study.

One of the key purposes of IHC for UP is the use to distinguish between poorly differentiated UCs from squamous cell carcinomas of the lung, which is a frequent metastatic site for UCs.^{8,16} A total of 23 lung squamous cell carcinomas were included in this study, and no UP positivity was observed in any of these. A limitation in this study is the included UCs being primary tumors. There would be a diagnostic value to include metastatic tumors, being the most difficult to diagnose in a clinical setting. However, to evaluate the analytical performance of the relatively unknown UPIII rmAb clone SP73, the included samples were sufficient for comparison with the 2 other UP Abs.

CONCLUSION

The aim of this study was to evaluate the performance of most commonly used Abs against UPII and UPIII in the identification of UCs on a larger material of tumors than included in the NordiQC assessment comprising only 2 UCs.

The results seen in this study confirms the result from the NordiQC assessment. The UPII mmAb clone BC21 gave a significantly increased analytical sensitivity compared with both tested UPIII Abs, and also the H-scores were significantly increased for the UPII mmAb clone BC21. The UPIII rmAb clone SP73 obtained a higher level of analytical sensitivity compared with the UPIII mmAb clone AU-1, but the UPII mmAb clone BC21 outperforms both evaluated UPIII Abs and at present should be the preferred choice as UP marker. The UPII mmAb clone BC21, however, should be used in a panel with eg, GATA3, due to the level of moderate analytical sensitivity.

REFERENCES

1. Lee G. Uroplakins in the lower urinary tract. *Int Neurourol J.* 2011;15:4.
2. Tian W, Guner G, Miyamoto H, et al. Utility of uroplakin II expression as a marker of urothelial carcinoma. *Hum Pathol.* 2015; 46:58–64.
3. Bellizzi AM. An algorithmic immunohistochemical approach to define tumor type and assign site of origin. *Adv Anat Pathol.* 2020; 27:114–163.
4. Smith SC, Mohanty SK, Kunju LP, et al. Uroplakin II outperforms uroplakin III in diagnostically challenging settings. *Histopathology.* 2014;65:132–138.
5. NordiQC Uroplakin Assessment Report. 2020. Available at: https://nordiqc.org/downloads/assessments/134_112.pdf. Accessed August 17, 2021.
6. Moll R, Laufer J, Wu XR, et al. Uroplakin III, a specific membrane protein of urothelial umbrella cells, as a histological markers for metastatic transitional cell carcinomas. *Verh Dtsch Ges Pathol.* 1993;77:260–265.
7. Fitzgibbons PL, Dillon DA, Alsabeh R, et al. Template for reporting results of biomarker testing of specimens from patients with carcinoma of the breast. *Arch Pathol Lab Med.* 2014;138:595–601.
8. Gruver AM, Amin MB, Luthringer DJ, et al. Selective immunohistochemical markers to distinguish between metastatic high-grade urothelial carcinoma and primary poorly differentiated invasive squamous cell carcinoma of the lung. *Arch Pathol Lab Med.* 2012;136:1339–1346.

9. Hoang LL, Tacha DE, Qi W, et al. A newly developed uroplakin ii antibody with increased sensitivity in urothelial carcinoma of the bladder. *Arch Pathol Lab Med.* 2014;138:943–949.
10. Kaufmann O, Volmerig J, Dietel M. Uroplakin III is a highly specific and moderately sensitive immunohistochemical marker for primary and metastatic urothelial carcinomas. *Am J Clin Pathol.* 2000;113:683–687.
11. Parker DC, Folpe AL, Bell J, et al. Potential utility of uroplakin III, thrombomodulin, high molecular weight cytokeratin, and cytokeratin 20 in noninvasive, invasive, and metastatic urothelial (transitional cell) carcinomas. *Am J Surg Pathol.* 2003;27:1–10.
12. Li W, Liang Y, Deavers MT, et al. Uroplakin II is a more sensitive immunohistochemical marker than Uroplakin III in urothelial carcinoma and its variants. *Am J Clin Pathol.* 2014;142:864–871.
13. Paner GP, Annaiah C, Gulmann C, et al. Immunohistochemical evaluation of novel and traditional markers associated with urothelial differentiation in a spectrum of variants of urothelial carcinoma of the urinary bladder. *Hum Pathol.* 2014;45:1473–1482.
14. Bussolati G, Gugliotta P, Volante M, et al. Retrieved endogenous biotin: a novel marker and a potential pitfall in diagnostic immunohistochemistry. *Histopathology.* 1997;31:400–407.
15. Package Insert, mmAb clone BC21 from Biocare Medical. Available at: <https://biocare.net/wp-content/uploads/PDFDataSheets/3051.pdf>. Accessed August 17, 2021.
16. Shinagare AB, Ramaiya NH, Jagannathan JP, et al. Metastatic pattern of bladder cancer: correlation with the characteristics of the primary tumor. *Am J Roentgenol.* 2011;196:117–122.