



Published in final edited form as:

*Mod Pathol.* 2019 October ; 32(10): 1416–1420. doi:10.1038/s41379-019-0277-x.

## Detecting *MYB* and *MYBL1* Fusion Genes in Tracheobronchial Adenoid Cystic Carcinoma by Targeted RNA-Sequencing

Jianming Pei, MD<sup>1</sup> [Assistant Research Professor], Douglas B. Flieder, MD<sup>2</sup> [Professor], Arthur Patchefsky, MD<sup>2</sup> [Professor], Jacqueline N. Talarchek, BS<sup>1</sup> [Medical Laboratory Technologist], Harry Cooper, MD<sup>2</sup> [Professor], Joseph R. Testa, PhD, FACMG<sup>1,3</sup> [Professor], Shuanzeng Wei<sup>2,\*</sup> [Assistant Professor]

Jianming Pei: Jianming.Pei@fcc.edu; Douglas B. Flieder: Douglas.Flieder@fcc.edu; Arthur Patchefsky: Arthur.Patchefsky@fcc.edu; Jacqueline N. Talarchek: Jacqueline.Talarchek@fcc.edu; Harry Cooper: Harry.Cooper@fcc.edu; Joseph R. Testa: Joseph.Testa@fcc.edu

<sup>1</sup>Genomics Facility, Fox Chase Cancer Center, Philadelphia, PA, 19111, USA

<sup>2</sup>Department of Pathology, Fox Chase Cancer Center, Philadelphia, PA, 19111, USA

<sup>3</sup>Cancer Biology Program, Fox Chase Cancer Center, Philadelphia, PA, 19111, USA

### Abstract

Primary tracheobronchial adenoid cystic carcinoma is rare, accounting for less than 1% of all lung tumors. Many adenoid cystic carcinomas have been reported to have a specific chromosome translocation t(6;9)/*MYB-NFIB*. More recently, t(8;9)/*MYBL1-NFIB* gene fusion was reported in salivary gland adenoid cystic carcinomas which lacked a t(6;9)/*MYB-NFIB*. Two prior studies showed t(6;9)/*MYB-NFIB* in tracheobronchial adenoid cystic carcinoma; however, only rare cases of *MYBL1* rearrangement have been reported in this carcinoma. In this study, we used targeted RNA sequencing to investigate fusion genes in tracheobronchial adenoid cystic carcinoma at our institution. Fusions of either *MYB* or *MYBL1* genes were detected in 7 of 7 carcinomas. Three cases had *MYB-NFIB*, and 3 had *MYBL1-NFIB*. The remaining case showed a rare *MYBL1-RAD51B* fusion. These findings suggest that rearrangement involving *MYB* or *MYBL1* is a hallmark of tracheobronchial adenoid cystic carcinoma.

### Keywords

Tracheobronchial Adenoid Cystic Carcinoma; lung; *MYB-NFIB*; *MYBL1-NFIB*; *MYBL1-RAD51B*; RNA sequencing

Primary tracheobronchial adenoid cystic carcinoma is the second most common salivary gland-type carcinoma of the lung after mucoepidermoid carcinoma (1–3). It is rare, accounting for less than 1% of all lung tumors (1, 4, 5). The reported age of adenoid cystic carcinoma patients ranges from 21 to 76 years, with an equal gender distribution (2, 4).

Tracheobronchial adenoid cystic carcinoma generally has a protracted clinical course, with

Users may view, print, copy, and download text and data-mine the content in such documents, for the purposes of academic research, subject always to the full Conditions of use:[http://www.nature.com/authors/editorial\\_policies/license.html#terms](http://www.nature.com/authors/editorial_policies/license.html#terms)

\*Correspondence: Shuanzeng Wei, M.D., Ph.D., Fox Chase Cancer Center, 333 Cottman Avenue, Philadelphia, PA 19111 USA Phone: 215-728-5504; Fax: 215-728-2848; weishuanzeng@hotmail.com.

multiple recurrences and late metastases. Advanced stage, the presence of positive margins, and a solid histologic pattern are associated with poor prognosis(4). Tracheobronchial adenoid cystic carcinoma has similar pathological features to adenoid cystic carcinoma identified at other anatomical sites, such as: tubular, cribriform, and solid architectural patterns with a variably myxoid/hyalinized basement membrane-like extracellular matrix. The tumor is composed of two different cell types: ductal and myoepithelial cells (4, 5).

Recent genomic studies of adenoid cystic carcinoma have demonstrated a low mutation frequency (6–8). However, 23% to 92% of adenoid cystic carcinoma from the head/neck and breast have been reported to have a specific chromosome translocation  $t(6;9)(q22-q23;p23-p24)/MYB-NFIB$ , resulting in the fusion of *MYB* protooncogene and the transcription factor gene *NFIB* (5, 9–14). This fusion has been shown to be highly specific for adenoid cystic carcinoma (10) at multiple anatomical locations, including the breast (13, 15), lacrimal glands (16) and skin (17–19). More recently, two groups independently identified a *MYBL1-NFIB* gene fusion resulting from a (8;9) translocation in salivary gland adenoid cystic carcinomas which lacked a  $t(6;9)/MYB-NFIB$  (8, 20).

Using RT-PCR, Brill et al. identified the  $t(6;9)/MYB-NFIB$  in 5 of 10 cases of tracheobronchial adenoid cystic carcinoma (21). In a separate study using fluorescence *in situ* hybridization (FISH) analysis, Roden et al. identified the  $t(6;9)/MYB-NFIB$  in 12 of 29 cases (41%) of pulmonary adenoid cystic carcinoma (5). To date, only rare cases of *MYBL1* rearrangement have been reported in tracheobronchial adenoid cystic carcinoma (22).

RNA sequencing can identify multiple fusion genes including new fusion partners in a single assay compared to PCR or FISH tests; which can only detect a limited number of known fusion genes. In this study, we used targeted RNA sequencing to investigate fusion genes in tracheobronchial adenoid cystic carcinoma at our institution. We report fusions of either *MYB* or *MYBL1* genes in 7 of 7 tumors tested, 6 of which involved the fusion partner *NFIB*. The remaining case showed a rare *MYBL1-RAD51B* fusion.

## Materials and methods

### Patients and samples

Seven cases of tracheobronchial adenoid cystic carcinoma diagnosed between 2005 and 2016 were retrieved from the Department of Pathology, Fox Chase Cancer Center. For case 2, a metastasis in the lung was analyzed, as the primary tracheal adenoid cystic carcinoma was not available for testing (Table 1). Pertinent clinical information was collected. This study was approved by the Institutional Review Board at our institution.

### RNA-sequencing and data analysis

Archived formalin-fixed paraffin embedded tumor tissue was used for RNA sequencing. For each tumor, RNA was isolated from five 10- $\mu$ m thick tissue sections. A High Pure FFPE RNA Isolation Kit (Roche, Indianapolis, IN) was used according to the manufacturer's protocol. RNA was quantified using a Nanodrop apparatus and evaluated with an Agilent 2100 bioanalyzer.

Next generation sequencing-based targeted RNA-sequencing analysis was performed using the Illumina TruSight RNA Fusion Panel and a MiniSeq sequencer according to the manufacturer's recommendations (Illumina, San Diego, CA) (23). The Trusight RNA fusion panel is a targeted RNA fusion panel that consists of 507 of the most well-known cancer-related fusion partners. This panel covers 7,690 exonic regions that are targeted with a total of 21,283 probes. The gene list is available at [www.illumina.com](http://www.illumina.com).

## Results

### Clinical Characteristics

The adenoid cystic carcinoma cohort consisted of four females and three males ranging in age from 51 to 81 (mean, 63 years) (Table 1). Three of seven cases had a smoking history. For case 1, only a biopsy was available; and the patient received radiation therapy. This patient died 8 years after. All other patients underwent surgical resection; and five of which had clinical follow-up. Within a follow-up period between 2 and 27 years, four patients were alive without disease; and one lived with disease.

### Pathological Findings

The pathological features are summarized in Table 1. Five tumors were in the trachea, and 2 were from the main bronchus. Tumor size ranged from 1.5 to 6 cm. Four tumors were predominantly cribriform, and 3 cases showed a more tubular formation (Fig 1). All 7 cases (100%) demonstrated fusions involving either *MYB* or *MYBL1*, and in 6 of the 7 cases, the fusion partner was *NFIB*. In one case, however, we identified a fusion of *MYBL1-RAD51B*.

## Discussion

Adenoid cystic carcinoma is the second most common malignancy of salivary glands with a poor long-term prognosis (24). The identification of recurring t(6;9)/*MYB-NFIB* and t(8;9)/*MYBL1-NFIB* chromosomal rearrangements have significantly enhanced our knowledge of the pathogenesis of adenoid cystic carcinoma (19). *MYB* is a member of the c-MYB transcription factor family, which also encompasses the structurally related *MYBL1* (*AMYB*) and *MYBL2* (*BMYP*) proteins. The encoded proteins by *MYB* and *MYBL1* genes have a nearly identical DNA binding domain and a similar overall structure (25). The structure of the *MYB-NFIB* fusion gene is very similar to the *MYBL1-NFIB* fusion; which preserves the DNA binding and transactivation domains in all fusion proteins. These two fusions are mutually exclusive in adenoid cystic carcinoma (8, 19, 20). In addition, adenoid cystic carcinoma tumors with *MYB* and *MYBL1* fusions display similar gene expression profiles, suggesting that the related *MYB* proteins are interchangeable oncogenic drivers in adenoid cystic carcinoma (8, 20).

Mitani et al. found the t(8;9)/*MYBL1-NFIB* in 35% of t(6;9)/*MYB-NFIB*-negative salivary gland adenoid cystic carcinomas, and all of the *MYBL1* alterations they identified involved deletion of the C-terminal negative regulatory domain and were associated with high *MYBL1* expression (8). Togashi et al. reported that 97 of 100 cases of head/neck adenoid cystic carcinoma harbored genomic rearrangements of the *MYB* (73 cases) or *MYBL1* loci (24 cases) (22). Fujii and colleagues found that 29 of 33 (88%) cases of salivary gland

adenoid cystic carcinoma exhibited rearrangements in *MYB*, *MYBL1* or *NFIB* based on FISH analysis (26).

Among tracheobronchial adenoid cystic carcinoma, there have been two other reports on *MYB-NFIB* fusion. In one study, Brill et al. found the *MYB-NFIB* fusion in 50% of cases of tracheobronchial adenoid cystic carcinoma by RT-PCR (21). In the second report, Roden identified the t(6;9)/*MYB-NFIB* in 41% of tracheobronchial/pulmonary adenoid cystic carcinoma by FISH (5).

In this report, we identified fusion genes involving either *MYB* or *MYBL1* in all 7 cases of tracheobronchial adenoid cystic carcinoma, including 3 with *MYB-NFIB*, 3 with *MYBL1-NFIB*, and 1 with a *MYBL1-RAD51B*. Only one previous salivary gland adenoid cystic carcinoma case with a *MYBL1-RAD51B* fusion gene has been reported, in which an *MYBL1* protein truncation occurred due to a translocation between exon 9 of *MYBL1* and intron 5 of the *RAD51B* gene, which resides on chromosome 14 (20). This fusion led to antisense transcription of part of the *RAD51B* intron, such that there was no expression of the *RAD51B* protein (20).

The *MYB-NFIB* fusion protein is the major mechanism of 5' *MYB* up-regulation in adenoid cystic carcinoma, since 3' *MYB* contains highly conserved binding sites for certain microRNA molecules, including miR-15a, miR-16 and miR-150. These miRNAs can down regulate 30% of wild-type *MYB* mRNA (9, 19). Furthermore, fusion genes involving *MYB* and *MYBL1* lose 3' elements which are responsible for their target specificity. Therefore, the encoded fusion oncoproteins can induce general/non-specific downstream gene expression (27). The exact role of *NFIB* as a fusion partner remains to be elucidated; although it has been proposed that it may provide stabilizing or regulatory elements to transcription factors such as *MYB* and *MYBL1* (19, 21).

As the genomic hallmark of adenoid cystic carcinoma, *MYB* and *MYBL1* fusion genes can be used for differential diagnosis in routine clinical practice. Concurrently, there is no consensus on the utility of *MYB* and *MYBL1* fusions as prognostic markers (19), although they and their downstream effectors are being investigated as potential therapeutic targets (19, 21). For example, Andersson et al demonstrated that *MYB-NFIB* is an oncogenic driver that can be targeted therapeutically in adenoid cystic carcinoma by inhibiting *IGF1R/AKT* signaling (28). Moreover, targeting downstream effectors of *MYB/MYBL1*, such as *c-KIT*, might provide an alternative approach to treat adenoid cystic carcinoma (19).

## Conclusion

In this study, seven cases (100%) of tracheobronchial adenoid cystic carcinoma demonstrated translocations involving either *MYB* or *MYBL1* genes; in six of which the fusion partner was *NFIB*. The remaining case showed a fusion *MYBL1-RAD51B* fusion. These findings suggest that rearrangement involving *MYB* or *MYBL1* is a hallmark of this carcinoma. RNA-sequencing studies in a large cohort are warranted to confirm the high frequency of these fusions.

## Acknowledgments

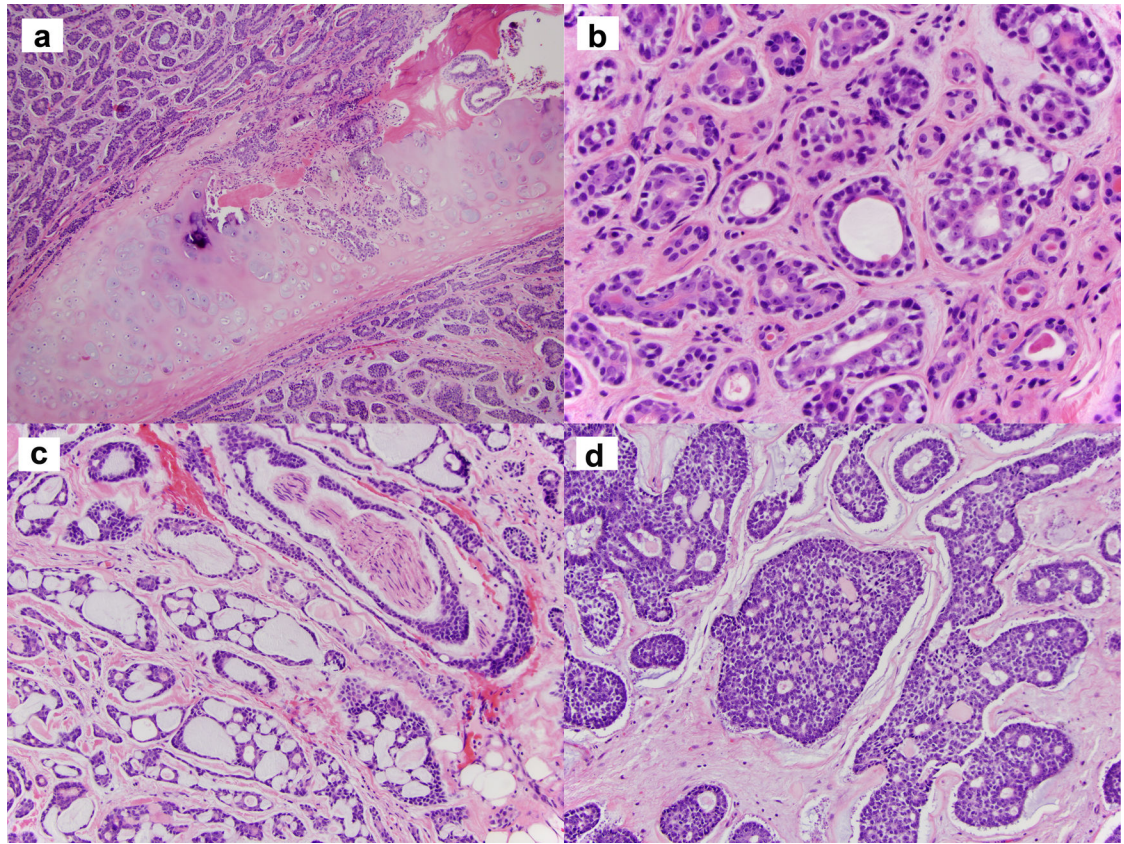
Supported by: NCI grant P30 CA006927

## References

1. Zhu F, Liu Z, Hou Y, He D, Ge X, Bai C, et al. Primary salivary gland-type lung cancer: clinicopathological analysis of 88 cases from China. *J Thorac Oncol* 2013;8:1578–84. [PubMed: 24389442]
2. Molina JR, Aubry MC, Lewis JE, Wampfler JA, Williams BA, Midthun DE, et al. Primary salivary gland-type lung cancer: spectrum of clinical presentation, histopathologic and prognostic factors. *Cancer* 2007;110:2253–9. [PubMed: 17918258]
3. Falk N, Weissferdt A, Kalhor N, Moran CA. Primary Pulmonary Salivary Gland-type Tumors: A Review and Update. *Adv Anat Pathol* 2016;23:13–23. [PubMed: 26645458]
4. Ishikawa Y, Dacic S, Nicholson AG. Adenoid cystic carcinoma In: Travis WD, Brambilla E, Burke A, Marx A, Nicholson AG (eds). *WHO Classification of Tumours of the Lung, Pleura, Thymus and Heart*. International Agency for Research on Cancer: Lyon, France, 2015, pp 101–102.
5. Roden AC, Greipp PT, Knutson DL, Kloft-Nelson SM, Jenkins SM, Marks RS, et al. Histopathologic and Cytogenetic Features of Pulmonary Adenoid Cystic Carcinoma. *J Thorac Oncol* 2015;10:1570–5. [PubMed: 26309189]
6. Stephens PJ, Davies HR, Mitani Y, Van Loo P, Shlien A, Tarpey PS, et al. Whole exome sequencing of adenoid cystic carcinoma. *J Clin Invest* 2013;123:2965–8. [PubMed: 23778141]
7. Ho AS, Kannan K, Roy DM, Morris LG, Ganly I, Katabi N, et al. The mutational landscape of adenoid cystic carcinoma. *Nat Genet* 2013;45:791–8. [PubMed: 23685749]
8. Mitani Y, Liu B, Rao PH, Borra VJ, Zafereo M, Weber RS, et al. Novel MYBL1 Gene Rearrangements with Recurrent MYBL1-NFIB Fusions in Salivary Adenoid Cystic Carcinomas Lacking t(6;9) Translocations. *Clin Cancer Res* 2016;22:725–33. [PubMed: 26631609]
9. Persson M, Andren Y, Mark J, Horlings HM, Persson F, Stenman G. Recurrent fusion of MYB and NFIB transcription factor genes in carcinomas of the breast and head and neck. *Proc Natl Acad Sci U S A* 2009;106:18740–4. [PubMed: 19841262]
10. Mitani Y, Li J, Rao PH, Zhao YJ, Bell D, Lippman SM, et al. Comprehensive analysis of the MYB-NFIB gene fusion in salivary adenoid cystic carcinoma: Incidence, variability, and clinicopathologic significance. *Clin Cancer Res* 2010;16:4722–31. [PubMed: 20702610]
11. D'Alfonso TM, Mosquera JM, MacDonald TY, Padilla J, Liu YF, Rubin MA, et al. MYB-NFIB gene fusion in adenoid cystic carcinoma of the breast with special focus paid to the solid variant with basaloid features. *Hum Pathol* 2014;45:2270–80. [PubMed: 25217885]
12. West RB, Kong C, Clarke N, Gilks T, Lipsick JS, Cao H, et al. MYB expression and translocation in adenoid cystic carcinomas and other salivary gland tumors with clinicopathologic correlation. *Am J Surg Pathol* 2011;35:92–9. [PubMed: 21164292]
13. Wetterkog D, Lopez-Garcia MA, Lambros MB, A'Hern R, Geyer FC, Milanezi F, et al. Adenoid cystic carcinomas constitute a genomically distinct subgroup of triple-negative and basal-like breast cancers. *J Pathol* 2012;226:84–96. [PubMed: 22015727]
14. Almeida-Pinto YD, Costa S, Andrade BAB, Altemani A, Vargas PA, Abreu LG, et al. t(6;9)(MYB-NFIB) in head and neck adenoid cystic carcinoma: A systematic review with meta-analysis. *Oral Dis* 2018. doi: 10.1111/odi.12984. [Epub ahead of print]
15. Martelotto LG, De Filippo MR, Ng CK, Natrajan R, Fuhrmann L, Cyrta J, et al. Genomic landscape of adenoid cystic carcinoma of the breast. *J Pathol* 2015;237:179–89. [PubMed: 26095796]
16. von Holstein SL, Fehr A, Persson M, Therkildsen MH, Prause JU, Heegaard S, et al. Adenoid cystic carcinoma of the lacrimal gland: MYB gene activation, genomic imbalances, and clinical characteristics. *Ophthalmology* 2013;120:2130–8. [PubMed: 23725736]
17. Fehr A, Kovacs A, Loning T, Frierson H Jr., van den Oord J, Stenman G. The MYB-NFIB gene fusion—a novel genetic link between adenoid cystic carcinoma and dermal cylindroma. *J Pathol* 2011;224:322–7. [PubMed: 21618541]

18. North JP, McCalmont TH, Fehr A, van Zante A, Stenman G, LeBoit PE. Detection of MYB Alterations and Other Immunohistochemical Markers in Primary Cutaneous Adenoid Cystic Carcinoma. *Am J Surg Pathol* 2015;39:1347–56. [PubMed: 26076064]
19. Wysocki PT, Izumchenko E, Meir J, Ha PK, Sidransky D, Brait M. Adenoid cystic carcinoma: emerging role of translocations and gene fusions. *Oncotarget* 2016;7:66239–54. [PubMed: 27533466]
20. Brayer KJ, Frerich CA, Kang H, Ness SA. Recurrent Fusions in MYB and MYBL1 Define a Common, Transcription Factor-Driven Oncogenic Pathway in Salivary Gland Adenoid Cystic Carcinoma. *Cancer Discov* 2016;6:176–87. [PubMed: 26631070]
21. Brill LB 2nd, Kanner WA, Fehr A, Andren Y, Moskaluk CA, Loning T, et al. Analysis of MYB expression and MYB-NFIB gene fusions in adenoid cystic carcinoma and other salivary neoplasms. *Mod Pathol* 2011;24:1169–76. [PubMed: 21572406]
22. Togashi Y, Dobashi A, Sakata S, Sato Y, Baba S, Seto A, et al. MYB and MYBL1 in adenoid cystic carcinoma: diversity in the mode of genomic rearrangement and transcripts. *Mod Pathol* 2018;31:934–46. [PubMed: 29410490]
23. Pei J, Cooper H, Flieder DB, Talarchek JN, Al-Saleem T, Uzzo RG, et al. NEAT1-TFE3 and KAT6A-TFE3 renal cell carcinomas, new members of MiT family translocation renal cell carcinoma. *Mod Pathol* 2019. doi: 10.1038/s41379-018-0191-7. [Epub ahead of print]
24. Xu B, Drill E, Ho A, Ho A, Dunn L, Prieto-Granada CN, et al. Predictors of Outcome in Adenoid Cystic Carcinoma of Salivary Glands: A Clinicopathologic Study With Correlation Between MYB Fusion and Protein Expression. *Am J Surg Pathol* 2017;41:1422–32. [PubMed: 28719465]
25. George OL, Ness SA. Situational awareness: regulation of the myb transcription factor in differentiation, the cell cycle and oncogenesis. *Cancers (Basel)* 2014;6:2049–71. [PubMed: 25279451]
26. Fujii K, Murase T, Beppu S, Saida K, Takino H, Masaki A, et al. MYB, MYBL1, MYBL2 and NFIB gene alterations and MYC overexpression in salivary gland adenoid cystic carcinoma. *Histopathology* 2017;71:823–34. [PubMed: 28594149]
27. Gao R, Cao C, Zhang M, Lopez MC, Yan Y, Chen Z, et al. A unifying gene signature for adenoid cystic cancer identifies parallel MYB-dependent and MYB-independent therapeutic targets. *Oncotarget* 2014;5:12528–42. [PubMed: 25587024]
28. Andersson MK, Afshari MK, Andren Y, Wick MJ, Stenman G. Targeting the Oncogenic Transcriptional Regulator MYB in Adenoid Cystic Carcinoma by Inhibition of IGF1R/AKT Signaling. *J Natl Cancer Inst* 2017;109.





**Figure 1.**

(a), Tubular-predominant tumor invades bronchial cartilage (case 3). (b), Tubular-predominant tumor (case 7) shows two cell populations: inner ductal cells and the outer myoepithelial cells. (c), Cribriform-predominant tumor with cylindromatous microcystic spaces containing basophilic mucoid material and perineural invasion (case 6). (d), Cribriform tumor with hyalinized basement membrane material (case 5).

**Table 1.**

Clinicopathological characteristics of 7 cases of Tracheobronchial adenoid cystic carcinoma

No.	Sex	Age (Years)	Smoker	Tumor Location	Size (cm)	Histologic Pattern <sup>#</sup>	Gene Fusion	Pathologic Stage	Treatment	Follow-up (Years)
1	M	51	No	Trachea	6.0 <sup>1</sup>	Tubular	MYB-NFIB	N/A	Radiation	8/DOD
2	F	68	No	Trachea	N/A <sup>2</sup>	Cribriform	MYB-NFIB	N/A	Surgery	27/AWD
3	F	61	No	Trachea	4	Tubular	MYB-NFIB	pT2NxM0	Surgery/radiation	4/AWOD
4	M	52	Yes	Main bronchus	3.5	Cribriform	MYBL1-NFIB	pT3N1M0	Surgery/chemo/radiation	3
5	F	81	Yes	Trachea	2.5	Cribriform	MYBL1-NFIB	pT4N0Mx	Surgery/radiation	12/AWOD
6	F	61	No	Main bronchus	1.5	Cribriform	MYBL1-NFIB	pT3N2M0	Surgery/radiation	3/AWOD
7	M	64	Yes	Trachea	3.2	Tubular	MYBL1-RAD51B	pT4N0M0	Surgery/radiation	2/AWOD

<sup>#</sup>Predominant histological pattern,

<sup>1</sup>Biopsy only, size on CT scan,

<sup>2</sup>Metastasis,

<sup>3</sup>Loss of follow-up, DOD, died of disease, AWD, alive with disease, AWOD, alive without disease,