

# Chilaiditi's sign, a cause of pseudo-pneumoperitoneum: A case report

SAGE Open Medical Case Reports  
Volume 6: 1–4  
© The Author(s) 2018  
Article reuse guidelines:  
sagepub.com/journals-permissions  
DOI: 10.1177/2050313X18812213  
journals.sagepub.com/home/sco



Benjamin Sachdev Manjit Singh<sup>1</sup>,  
Muhammad Daniel Azlan Mahadzir<sup>2</sup>   
and Lee Tiong Chan<sup>3</sup>

## Abstract

The differentiation between a pseudo-pneumoperitoneum and true pneumoperitoneum on an initial chest radiograph is challenging but essential to clinical practice. The former is managed conservatively whereas the latter may require surgical intervention. Chilaiditi's sign describes a rare incidental radiological finding of gas filled bowel interpositioned between the right hemi-diaphragm and the liver, which is visible on a plain abdominal or chest radiograph. It is often misdiagnosed as a pneumoperitoneum. Correct diagnosis of Chilaiditi's sign in an asymptomatic patient can prevent unnecessary procedures. We have reported one incidental chest radiograph with Chilaiditi's sign in a patient presenting and treated for pneumonia. The report aims to illustrate the diagnostic dilemma experienced by clinicians in distinguishing a true versus pseudo-pneumoperitoneum on a chest radiograph.

## Keywords

Gastroenterology/hepatology, radiology, critical care/ emergency, medicine

Date received: 17 September 2018; accepted: 25 September 2018

## Background

The presence of free air under the diaphragm on a chest radiograph is characteristic of a pneumoperitoneum.<sup>1–3</sup> This sign often signifies the presence of a perforated intra-abdominal viscous particularly if accompanied by signs such as abdominal tenderness and guarding.<sup>1–3</sup> Conversely, a pseudo-pneumoperitoneum describes the presence of intra-peritoneal air which appears as free but in reality is contained within an organ.<sup>1,2</sup> The radiographic distinction between a 'true' and pseudo-pneumoperitoneum is often challenging but remains essential in clinical practice.<sup>1</sup> This is partly due to management differences in which the former often requires urgent further investigation leading to invasive intervention while the latter may be treated conservatively.<sup>1,3–5</sup> Accordingly, misidentification may result in unnecessary referrals, investigations or invasive procedures.

We present a patient presenting with Chilaiditi's sign incidentally found on a chest radiograph which is a cause of pseudo-pneumoperitoneum. This case report aims to illustrate the diagnostic dilemma experienced by clinicians in distinguishing a true versus pseudo-pneumoperitoneum at the initial consultation and highlights elements in the

diagnosis, investigation and treatment in patients who have Chilaiditi's sign.

## Case report

A 60-year-old female, post-menopausal and Para 3 presented to the emergency department of a district hospital in Sarawak, Malaysia, with a history of cough, fever and non-localising pleuritic chest pain for 2 days. She denied any significant past surgical history and did not have any abdominal pain or altered bowel habits. She had a significant history of severe pulmonary hypertension due to chronic pulmonary vascular thromboembolism on treatment with warfarin and hypertension under cardiology follow-up. Initial examination revealed crackles over the right lung base and a loud P2 on auscultation. Abdominal examination was soft non-tender

<sup>1</sup>Hospital Sri Aman, Sri Aman, Malaysia

<sup>2</sup>Monash University Malaysia, Subang Jaya, Malaysia

<sup>3</sup>Hospital Segamat, Segamat, Malaysia

### Corresponding Author:

Benjamin Sachdev Manjit Singh, Hospital Sri Aman, Jalan Hospital, Sri Aman 95000, Sarawak, Malaysia.  
Email: benjaminsachdev@gmail.com



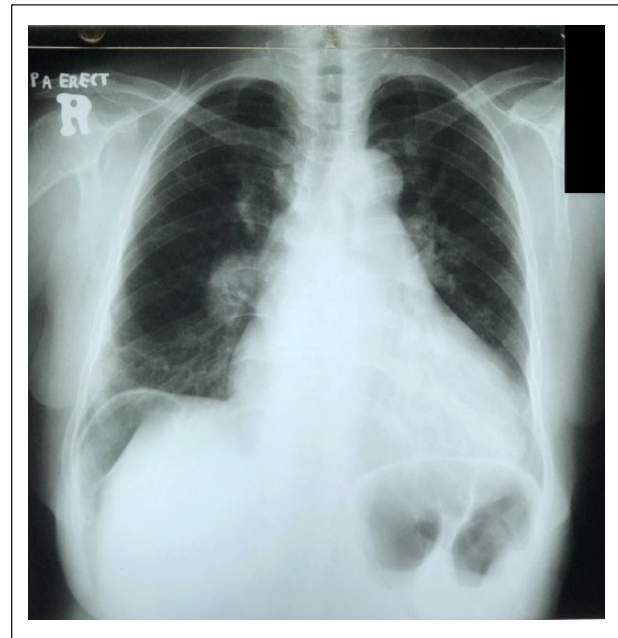with no palpable masses. There was no rebound and guarding. Her blood pressure was 123/86 mmHg and heart rate 90 beats per minute. Oxygen saturations were initially 91% under room air but increased to 94%–96% with oxygen supplementation. Routine blood investigations returned as within normal ranges and the International Normalized Ratio (INR) within the target range. A provisional diagnosis of Community Acquired Pneumonia was made and a chest radiograph obtained.

The chest radiograph incidentally showed the presence of air under the right hemi-diaphragm and right lower zone infiltrates (Figure 1). A repeated chest radiograph (Figure 2) taken 6 h later showed gas under the diaphragm with the appearance of haustral folds. A bedside abdominal ultrasound showed no evidence of free fluid within the peritoneum. As there was no resident surgeon available, consultation through telephone was obtained for suspected perforated viscus. As the patient was asymptomatic for peritonitis and had normal bowel movements, a conservative approach was adopted with regular ward review for symptom development. It was later determined that the gas under the diaphragm with the appearance of haustral folds on the chest radiograph was consistent with Chilaiditi's sign. Consequently, she was treated for pneumonia, able to be weaned off oxygen support and recovered uneventfully. A repeated chest radiograph (Figure 3) on day 3 of admission showed complete disappearance of sub-diaphragmatic air and complete resolution of the abnormality.

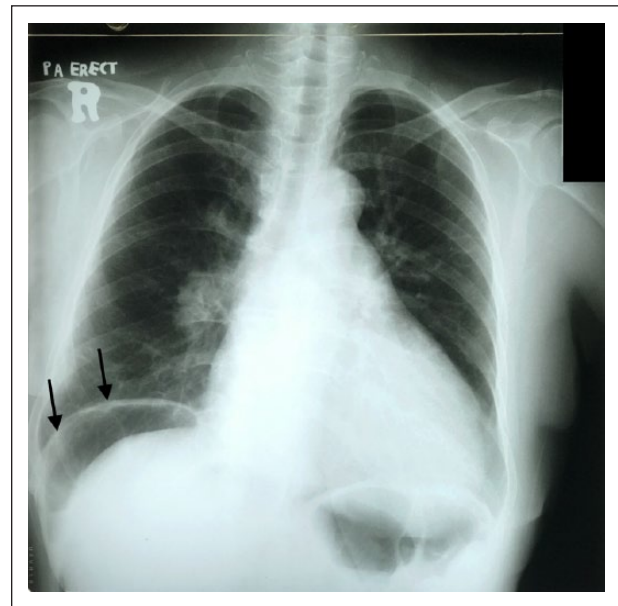
## Discussion

The diagnosis of a true versus pseudo-pneumoperitoneum may represent a diagnostic dilemma for clinicians working in a district hospital without a resident radiologist or radiology services. In our case, the initial chest radiograph performed for pneumonia unexpectedly revealed free air under the right hemi-diaphragm prompting suspicion of a perforated viscus. As described above, this incidental finding caused uncertainty for the treating team prompting further investigations to confirm the abnormality such as a repeated chest radiograph, referral to the surgical team and bedside abdominal ultrasound, although the patient remained completely asymptomatic for peritonitis. The chest radiograph (Figures 1 and 2) was later determined to show Chilaiditi's sign.

Chilaiditi's sign is the presence of air under the right hemi-diaphragm with the appearance of haustral folds indicating confinement of gas within the bowel.<sup>1,3</sup> It represents an asymptomatic colonic interposition between the liver and right hemi-diaphragm.<sup>4–6</sup> Initially reported by Demetrius Chilaiditi in 1910, it is a cause of the appearance of pseudo-pneumoperitoneum on the chest radiograph.<sup>6,7</sup> The cause of the signs appearance is poorly understood. Ordinarily, colonic fixation and suspensory ligaments prevent interposition of the colon between the diaphragm and liver.<sup>4</sup> Therefore, Chilaiditi sign could be

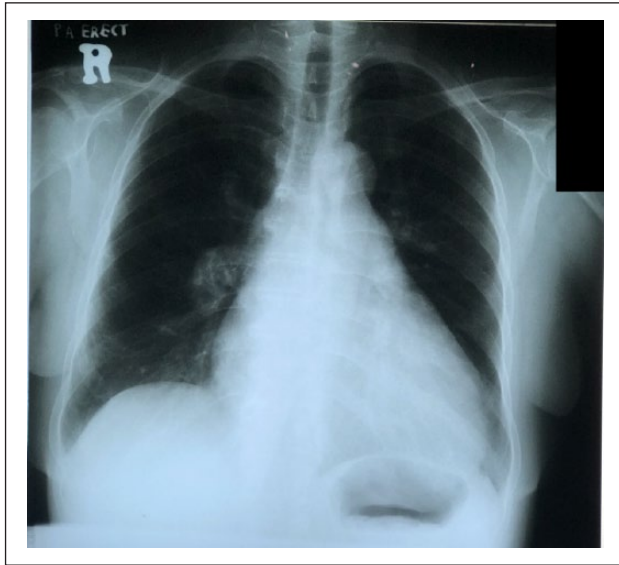


**Figure 1.** First chest radiograph upon presentation to the Emergency Department. This chest radiograph showed the presence of air under the right hemi-diaphragm and also slight right lower zone infiltrates.



**Figure 2.** Repeated chest radiograph 6 h after presentation and post review of the first chest radiograph. The presence of Chilaiditi's sign is noted. There is gas under the diaphragm with the appearance of haustral folds (marked by black arrows) indicating the gas is confined within the bowel. This sign represents the colonic interposition between the liver and right hemi-diaphragm.

due to anatomical variations and abnormalities of the fal-ciform ligament or the ligaments suspending the transverse colon.<sup>1,3–5</sup>



**Figure 3.** Chest radiograph repeated at day 3 of admission showed complete resolution of Chilaiditi's sign.

Chilaiditi's sign is usually incidentally found on routine chest or abdominal radiography and occurs in 0.025%–0.28% of the population, commonly affecting men in the geriatric age group four times more than women.<sup>2–4,6,11</sup> In our patient, a repeated chest radiograph at the third day of admission (Figure 3) showed complete resolution of the sign. This highlights the intermittent nature of the signs appearance as similarly discussed in a case report by Kapania et al.<sup>9</sup> Distinctly, the presence of Chilaiditi's sign with symptoms like abdominal pain, constipation or vomiting is termed as Chilaiditi's syndrome.<sup>1,3–5,8,10</sup> The syndrome has been associated with gastrointestinal or pulmonary malignancies and may rarely cause intestinal obstruction.<sup>4,6</sup>

The distinction between Chilaiditi's sign, syndrome and a true pneumoperitoneum is essential as misdiagnosis may lead to inappropriate management.<sup>6</sup> Chilaiditi's sign is asymptomatic and requires no intervention.<sup>3</sup> Chilaiditi's syndrome, conversely, is initially managed with intravenous fluids, bowel decompression and laxatives but in 26% of patients may require surgical intervention especially if there is evidence of bowel ischemia or perforation.<sup>3,5,6,9</sup>

In the event of diagnostic uncertainty, additional imaging modalities such as ultrasound or computed tomography (CT) of the abdomen may be requested.<sup>2–4</sup> Some important ultrasound findings suggestive of Chilaiditi's sign are the lack of impact from body position change on air echo, the gas surface being distant in relation to the diaphragmatic peritoneum, an uneven gas surface distribution and the presence of colonic haustra.<sup>2,4</sup> Where the ultrasound is inconclusive, a CT of the abdomen can be obtained to clarify the diagnosis.<sup>3,4</sup>

Apart from Chilaiditi's sign and syndrome, other causes of a pseudo-pneumoperitoneum on a radiograph should also

be considered, which according to Mistry et al includes, basal linear atelectasis, linear collapse of lower lung tissue, peritoneal fat stripe and hepatobiliary and portal gas and fat within the sub-diaphragmatic area.<sup>3</sup>

## Conclusion

In conclusion, differences in management and investigation highlight the importance of correct initial identification between a pseudo versus 'true' pneumoperitoneum on chest radiography. Furthermore, clinicians should always correlate history and physical findings when determining the nature of the radiographic findings. For this patient, the lack of symptoms suggestive of peritonism prompted the treating team to consider the presence of a benign condition which in this case was retrospectively determined to be Chilaiditi's sign. Nonetheless, diagnostic uncertainty and absence of awareness prompted an unnecessary referral to the surgical team in order to exclude a more sinister intra-abdominal pathology. Conceivably, recognition of Chilaiditi's sign by clinicians as a cause of pseudo-pneumoperitoneum will reduce the number of unnecessary investigations, referrals and procedures for an otherwise benign condition.

## Acknowledgements

The authors would like to thank and acknowledge the Director of Health Malaysia Datuk Dr Noor Hisham Abdullah, for allowing the publication of this case report.

## Consent for publication

Patient explicitly consented to the use of information and chest radiographs taken during admission for the case report. Consent form signed.

## Declaration of conflicting interests

The author(s) declared no potential conflicts of interest with respect to the research, authorship and/or publication of this article.

## Ethical approval

Our institution does not require ethical approval for reporting individual cases or case series.

## Funding

The author(s) received no financial support for the research, authorship and/or publication of this article.

## Informed consent

Written informed consent was obtained from the patient(s) for their anonymised information to be published in this article.

## ORCID iD

Muhammad Daniel Azlan Mahadzir  <https://orcid.org/0000-0003-1253-1426>

## References

1. Lo BM. Radiographic look-alikes: distinguishing between pneumoperitoneum and pseudopneumoperitoneum. *J Emerg Med* 2010; 38(1): 36–39.
2. Smereczynski A and Kolaczyk K. Is it possible to differentiate between pseudopneumoperitoneum and similar pathologies ultrasonographically. *J Ultrason* 2017; 17(68): 30–35.
3. Mistry KA, Bhoil R, Kumar N, et al. Significance of Chilaiditi sign and Chilaiditi syndrome. *Emerg Nurse* 2017; 25(3): 26–31.
4. Moaven O and Hodin RA. Chilaiditi syndrome: a rare entity with important differential diagnoses. *Gastroenterol Hepatol* 2012; 8(4): 276–278.
5. Ghani S, Course CW and Bodla HP. From sign to syndrome: Chilaiditi. *Arch Dis Child* 2017; 102(12): 1117–1117.
6. Mateo De Acosta Andino DA, Aberle CM, Ragauskaite L, et al. Chilaiditi syndrome complicated by a closed-loop small bowel obstruction. *Gastroenterol Hepatol* 2012; 8(4): 274–276.
7. Chilaiditi D. Zur Frage der Hepatoptose und Ptose im allgemeinen im Anschluss an drei Falle von temporarer, partieller Leberverlagerung. *Fortschr Geb Rontgenstr Nukl Ergänzungsband* 1910; 11(16): 173–208.
8. Ansari H and Lay J. Chilaiditi syndrome and associated caecal volvulus. *ANZ J Surg* 2011; 81(6): 484–485.
9. Kapania EM, Link C and Eberhardt JM. Chilaiditi syndrome: a case report highlighting the intermittent nature of the disease. *Case Rep Med* 2018; 2018: 3515370.
10. Plorde JJ and Raker EJ. Transverse colon volvulus and associated Chilaiditi's syndrome: case report and literature review. *Am J Gastroenterol* 1996; 91(12): 2613–2616.
11. Vallee P. Symptomatic Morgagni hernia misdiagnosed as Chilaiditi syndrome. *West J Emerg Med* 2011; 12(1): 121–123.