

Effects of Biphenyldimethyl-dicarboxylate Administration Alone or Combined with Silymarin in the CCl₄ Model of Liver Fibrosis in Rats

Omar M.E. Abdel-Salam¹, Amany A. Sleem¹, and Fatma A. Morsy²
Pharmacology¹ and Pathology², National Research Centre, Tahrir St., Dokki, Cairo, Egypt.

E-mail: omasalam@hotmail.com

Received May 6, 2007; Revised July 4, 2007; Accepted July 6, 2007; Published August 24, 2007

The effect of biphenyldimethyl-dicarboxylate (DDB), a synthetic compound, in use for the treatment of chronic hepatitis was studied on hepatic injury caused in rats by administration of carbon tetrachloride (CCl₄). Starting at time of administration of the first dose of CCl₄, rats received DDB at four dose levels (3, 15, 75 or 375 mg/kg), silymarin (22 mg/kg), a combination of DDB (75 mg/kg) and silymarin (22 mg/kg) or saline (control) once orally daily for 30 days. The administration of DDB in CCl₄-treated rats at 75 or 375 mg/kg resulted in 61.2-76.2% decrease in alanine aminotransferase (ALT) and 46.9-60.8% decrease in aspartate aminotransferase (AST), respectively compared with the CCl₄ control group. Silymarin treatment resulted in 34.6 and 30% decrease in ALT and AST, while DDB (75 mg/kg) combined with silymarin (22 mg/kg) resulted in 58.2 and 31% decrease in ALT and AST, respectively. Serum creatinine increased by 50% by DDB at 375 mg/kg. After treatment with DDB at 75 or 375 mg/kg or DDB combined with silymarin, the development of liver necrosis and fibrosis caused by CCl₄ was markedly reduced, while after DDB combined with silymarin no DNA aneuploid cells could be observed. The decrease in glycogen and protein contents in hepatocytes caused by CCl₄ was markedly prevented by co-treatment with DDB at 75 or 375 mg/kg or DDB combined with silymarin. It is concluded that in the model of hepatic injury caused by chronic administration of CCl₄ in rats, the synthetic compound DDB, limits hepatocellular injury and exerts antifibrotic effect. Better improvement in protein, DNA, mucopolysaccharide content was seen after both DDB and silymarin compared to DDB alone. It is suggested, therefore, that DDB alone or in combination with silymarin might prove of benefit in the therapy of chronic liver disease. Monitoring of kidney functions in patients taking DDB is warranted.

KEY WORDS: biphenyldimethyl-dicarboxylate, silymarin, carbon tetrachloride, liver, rat

INTRODUCTION

Hepatitis C virus infection is the most frequent cause of chronic liver disease and the most common indication for liver transplantation. The disease is characterized by continuing necroinflammatory

*Corresponding author.

©2007 with author.

Published by TheScientificWorld: www.thescientificworld.com

process and progressive deposition of extracellular matrix (fibrosis) ultimately resulting in severe architectural distortion (cirrhosis). The result is a progressive loss of liver function and end-stage liver disease necessitating liver transplantation[1,2,3]. Cirrhosis is also a risk factor for developing hepatocellular carcinoma[4]. Treatments that could halt or diminish the progression of fibrosis would thus theoretically be beneficial. Combination therapy with PEG-interferon and ribavirin has emerged as the best current treatment for chronic hepatitis C (HCV) infection, but the overall sustained response rate to PEG interferon with ribavirin is about 55%[5]. This therapy however is not feasible in a significant proportion of patients and is associated with important side effects requiring discontinuation of therapy in many instances[6,7]. Therefore, there is an immense need for developing new drugs or finding alternative strategies to prevent fibrosis and slow down disease progression.

Dimethyl-4,4'-dimethoxy-5,6,5',6'-dimethylenedioxybiphenyl-2,2'-dicarboxylate(dimethyl bicarboxylate; DDB) is a synthetic compound which is in use in China and other countries for the treatment of chronic hepatic diseases e.g., that caused by hepatitis C virus. The drug is a synthetic analogue of Schizandrin C, a component isolated from Fructus Schizandrae, a traditional Chinese medicine that has been shown at the beginning of 70's to lower the elevated serum alanine aminotransferase (ALT) levels of patients suffering from chronic viral hepatitis[8,9]. The reduction in serum ALT levels by DDB is considered to represent a hepatoprotective effect, since serum levels of this enzyme are sensitive indicators of liver-cell injury and are released into the blood in increasing amounts when the liver cell membrane is damaged[10,11]. Indeed rapid decrease and even normalization of serum transaminases has been noted in patients with chronic hepatitis C and B and remained normal during treatment with DDB[12,13]. Furthermore, in experimental models of hepatocyte injury, certain components isolated from Fructus Schizandrae as well as DDB decreased serum ALT levels along with an inhibitory effect on CCl₄-induced lipid peroxidation[8,14,15]. Other researchers, however, noted no beneficial effect on the histological grade and stage of liver disease and suggested that DDB affects the synthesis and/or degradation of ALT in liver cells and that the normalization of ALT during DDB treatment does not indicate therapeutic efficacy[13].

Silymarin (Milk Thistle, Silybum marianum) is a commonly used herbal therapy, particularly by patients who have liver disease e.g., that caused by alcohol or hepatitis C virus, where it resulted in reducing serum bilirubin, and transaminases[16,17,18]. In experimental models of hepatic injury e.g., carbon tetrachloride[19], paracetamol[20], d-galactosamine[21], ischaemia/reperfusion[22], silymarin exerted protective effects and reduced liver fibrosis induced by carbon tetrachloride[23], bile-duct ligation[24] or ethanol[25]. This hepatoprotective effect of silymarin has been suggested to result from membrane-stabilizing, free radicals scavenging properties[19], inhibition of lipid peroxidation[26] and modulation of hepatocyte Ca⁺⁺[27].

The ability of both DDB and silymarin to reduce serum transaminases and hepatocyte injury has prompted the development of commercial preparations containing mixture of silymarin and DDB for the treatment of chronic liver disease. Therefore the present study was designed to investigate the effect of DDB alone or in combination with silymarin on acute hepatic damage caused by the administration of carbon tetrachloride in rats. It was also aimed to see whether combined therapy with silymarin and DDB would offer any potential advantage over therapy with either drug alone. The effect of both drugs was evaluated on biochemical markers, histologically as well as by histochemical techniques. The severity of liver fibrosis and DNA content in hepatocytes were determined by image analysis system.

MATERIALS AND METHODS

Animals

Sprague-Dawley rats, weighing 130-150g of body weight were used. They were housed under standard laboratory conditions with free access to standard laboratory chow and water. All animal procedures were

performed according to approved protocols and in accordance with the recommendations for the proper care and use of laboratory animals.

Drugs and Chemicals

Carbon tetrachloride (BDH Chemicals, England), biphenyldimethyldicarboxylate (DDB), silymarin (SEDICO, Cairo) were used in the experiments. Biphenyldimethyldicarboxylate and silymarin were dissolved in saline to obtain the necessary doses. The doses of DDB and silymarin used in the study were chosen based on other studies in which the drugs produced beneficial effects in models of hepatic injury[14,15,28,29].

The Carbon Tetrachloride Model of Hepatic Damage

Liver damage was induced by CCl₄-olive oil given orally (1:1, 2.8 ml/kg). One week after the initial dose of CCl₄, rats were administered CCl₄ (1.4 ml/kg) weekly so as to maintain hepatic damage. Starting on the time of the first dose of CCl₄ administration, rats (n = 6/group) also received either DDB at four dose levels (3, 15, 75 or 375 mg/kg), silymarin (22 mg/kg) or a combination of DDB (75 mg/kg) and silymarin (22 mg/kg) orally daily for 30 days. Control rats were treated with olive oil (2.8 ml/kg followed by 1.4 ml/kg one week later) (n = 6). One more group (n = 6 each) received saline, but no CCl₄ daily for 30 days. The animals were killed 30 days after the first dose of CCl₄ or olive oil administration. Rats had free access to food and drinking water during the study.

Biochemical Analyses

Blood samples obtained from the retro-orbital vein plexuses under ether anaesthesia were analyzed for alanine aminotransferase (ALT), aspartate aminotransferase (AST), alkaline phosphatase (ALP), serum bilirubin, urea, creatinine, total proteins and glucose levels. ALT and AST activities in serum were measured according to Reitman-Frankel colorimetric transaminase procedure[30], whereas colorimetric determination of ALP activity was done according to the method of Belfield and Goldberg[31], using commercially available kits (BioMérieux, France).

Histological and Histochemical Studies

After the end of the treatment period, rats were killed; livers of the different groups were excised and fixed in 10% formalin saline. Paraffin sections 5 μ thick were prepared and stained with haematoxylin and eosin (H & E) for the histological investigations. Further sections were stained by Periodic acid-Schiff stain and bromophenol for intracellular mucopolysaccharides and protein detection, respectively.

Quantitative Measurements

Quantitative measurement of the severity of liver fibrosis and DNA content were achieved by using computerized image analyzer (Qwin Leica image processing and analysis system, Cambridge- England). To measure the severity of liver fibrosis, Masson's trichrome stain stained sections were used. The image analyzer was first calibrated automatically to convert the measurement units (Pixels) produced by image analyzer program into actual micrometer units. Ten fields were chosen in each specimen and the mean values were obtained. DNA content analysis was performed on sections stained with Feulgen methods. For each section 100-120 cells were randomly measured. The threshold values were defined by measuring control cells. The result is presented as histogram, in which normal diploid cells are separated clearly from aneuploid cells.

Statistical Analysis

All results are expressed as means ± SE. Comparison of the values before and after CCl₄ was made by paired Student's t-test. Multiple group comparisons were performed by ANOVA followed by Duncan test. P < 0.05 was considered statistically significant.

RESULTS

CCl₄-Induced Hepatic Injury

Biochemical Results

The administration of CCl₄ was associated with marked increase in serum alanine aminotransferase (ALT), aspartate aminotransferase (AST), alkaline phosphatase (ALP) and bilirubin by 92.8%, 104.6%, 55% and 208%, respectively (Table 1). The administration of DDB in CCl₄-treated rats at 3 or 15 mg/kg failed to reduce the indices of hepatocellular injury, while DDB at higher doses of 75 or 375 mg/kg resulted in 61.2-76.2% decrease in ALT and 46.9-60.8% decrease in AST, respectively compared with the CCl₄ control group. Serum ALP did not change after DDB (15, 75 or 375 mg/kg) treatment. Silymarin (22 mg/kg) treatment resulted in 34.6, 30 and 36% decrease in ALT, AST and ALP, respectively. Meanwhile, DDB (75 mg/kg) combined with silymarin (22 mg/kg) resulted in 58.2, 31 and 19.4% decrease in ALT, AST and ALP, respectively. The increase in serum bilirubin in CCl₄-treated rats was not altered by either treatment. Serum creatinine increased by 32% in CCl₄-treated rats compared with the vehicle-treated group. In the CCl₄-treated rats, serum creatinine was reduced to near normal value by silymarin, but increased by further 50% after the highest dose of DDB. Serum glucose increased by 41% in the CCl₄-treated control group and restored to near normal values after silymarin or DDB treatment. Serum proteins did not change in CCl₄-treated rats.

Table 1.
Serum bilirubin, urea, creatinine, proteins, glucose and enzyme activities of alanine aminotransferase (ALT), aspartate aminotransferase (AST) and alkaline phosphatase (ALP) in CCl₄-treated rats treated with biphenyldimethyl-dicarboxylate (DDB) and/or silymarin

	ALT (U/l)	AST (U/l)	ALP (U/l)	Total bilirubin (mg/dl)	Urea (mg/dl)	Creatinine (mg/dl)	Total protein (g/l)	Glucose (mg/dl)
Saline (normal)	34.5 ± 3.4	58.5 ± 5.7	90.11 ± 8.0	0.50 ± 0.03	59.27 ± 3.96	0.50 ± 0.06	11.24 ± 0.66	59.27 ± 3.96
CCl ₄ (control)	66.5 ± 5.7 [#]	119.7 ± 6.6 [#]	139.7 ± 4.3 ⁺	1.54 ± 0.12 [#]	48.19 ± 3.5	0.66 ± 0.06	11.42 ± 0.5	83.85 ± 6.5 [#]
CCl ₄ + silymarin 22 mg/kg	43.5 ± 6.8 [*]	83.8 ± 5.6 [*]	89.3 ± 2.7 [*]	1.41 ± 0.14	67.55 ± 3.4	0.53 ± 0.08	11.53 ± 0.26	57.39 ± 5.7 [*]
CCl ₄ + DDB								
3 mg/kg	68.6 ± 4.6	104.7 ± 8.3	90.5 ± 2.6 [*]	1.44 ± 0.13	60.98 ± 7.0	0.64 ± 0.02	12.24 ± 0.42	61.22 ± 4.4 [*]
15 mg/kg	56.8 ± 3.9	101.4 ± 6.4	123.2 ± 8.2	1.34 ± 0.16	65.13 ± 3.8	0.74 ± 0.06	12.25 ± 0.37	60.73 ± 4.3 [*]
75 mg/kg	25.8 ± 2.8 [*]	74.2 ± 4.3 [*]	114.0 ± 8.4	1.66 ± 0.2	67.49 ± 2.4	0.76 ± 0.01	11.76 ± 0.79	55.22 ± 4.6 [*]
375 mg/kg	15.8 ± 1.7 [*]	54.8 ± 5.3 [*]	117.5 ± 7.5	1.67 ± 0.11	67.42 ± 1.2	0.99 ± 0.05 [*]	14.54 ± 0.89	62.74 ± 6.1 [*]
CCl ₄ + DDB 75 mg/kg + silymarin	27.75 ± 3.0 [*]	82.5 ± 6.3 [*]	112.6 ± 9.4	1.51 ± 0.16	50.1 ± 3.9	0.65 ± 0.06	13.35 ± 0.98	41.87 ± 4.4 [*]

Results are mean ± S.E. # : P < 0.05 vs saline group. * : P < 0.05 vs CCl₄ control group. One way ANOVA and Duncan's multiple range test.

Histological Results

The liver of saline-treated normal rats revealed the normal characteristic hepatic architecture (Fig. 1A). No pathological changes could be observed in the liver of rats treated with either DDB or silymarin per se. The livers of rats treated with CCl_4 showed cirrhotic nodules and marked fibrosis. The degree of fibrosis varied from moderate to severe. The microscopic examination of the cirrhotic nodules showed marked fibrosis, architecture distortion and the appearance of many pseudo lobules. The fibrous tissues ran in septa between the nodules (Fig. 1B). In rats treated with CCl_4 together with silymarin, some protection was observed in the form of diminution of cirrhosis, while moderate fibrosis, vacuolar degeneration and haemorrhagic areas were also seen. Signs of degeneration in the form of some pyknotic nuclei and karyolysis were present (Fig. 1C). Examination of liver sections from rats treated with CCl_4 together with DDB at 3 mg/kg revealed no protective effects as compared to the group treated with CCl_4 -olive oil only. The livers still suffered from marked fibrosis, architecture distortion and the appearance of many pseudo lobules (Fig. 1D). Meanwhile, liver sections of rats treated with CCl_4 + DDB at 75 mg/kg showed mild fibrosis, vacuolar degeneration and fatty changes. Signs of degeneration in the form of pyknosis, karyolysis and karyorrhexis were seen. Red blood cells could be noticed in dilated blood sinusoids (Fig. 2A). With the higher dose of DDB of 375 mg/kg, there was minimal fibrosis, macro and micro-vacuolar degeneration and fatty changes. Signs of degeneration in the form of pyknosis, karyolysis were still seen (Fig. 2B). The administration of DDB (75 mg/kg) combined with silymarin to CCl_4 -treated rats resulted in some protection compared with treated with CCl_4 only. Cirrhosis and fibrosis were decreased, while vacuolar degeneration, fatty change, signs of degeneration in the form of pyknosis, karyolysis were still seen. Hypertrophy of Kupffer cells could be noticed (Fig. 2C).

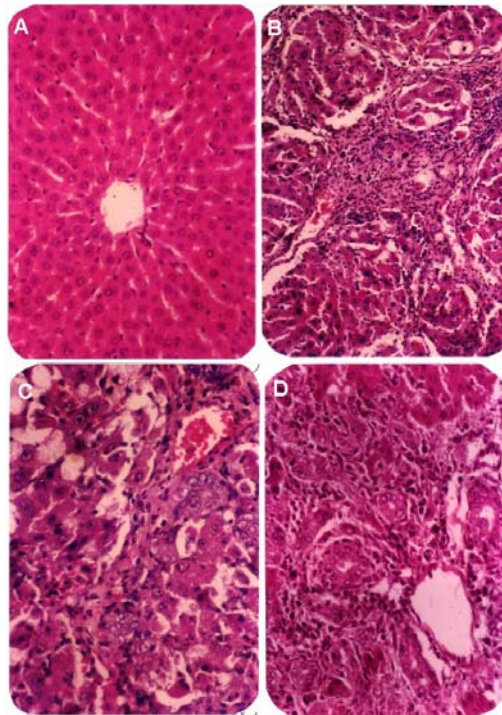


FIGURE 1. Section of liver from (A) an untreated control (normal) rat showing normal histological structure of hepatic lobules and central veins; (B) CCl_4 -treated rat showing marked fibrosis (arrow), the fibrous tissue runs in septa between the nodules. Many pseudolobules could be noticed; (C) CCl_4 and silymarin-treated rat showing moderate fibrosis, vacuolar degeneration, haemorrhagic area, but no cirrhosis; (D) CCl_4 and biphenyldimethyldicarboxylate (DDB) (3 mg/kg)-treated rat showing marked fibrosis and cirrhosis (H & E x 200).

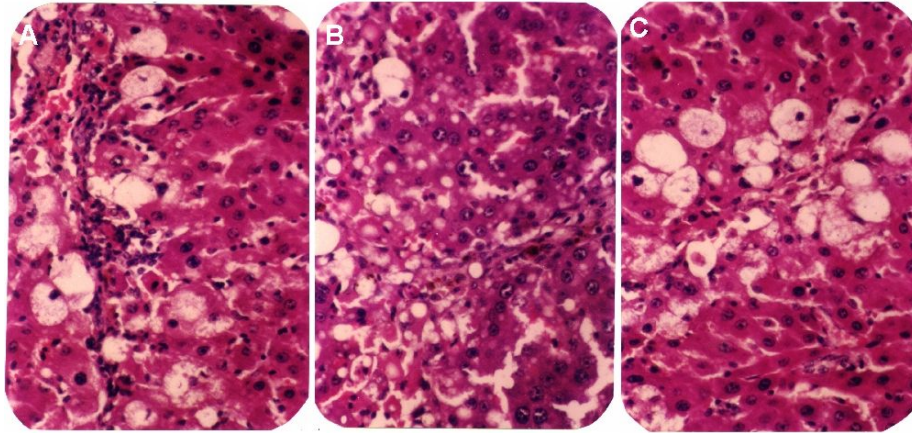


FIGURE 2. Section of liver from (A) CCl₄ and biphenyldimethyldicarboxylate (DDB) (75 mg/kg)-treated rat showing mild fibrosis, vacuolar degeneration, some pyknotic nuclei, karyolysis and karyorrhexis; (B) CCl₄ and biphenyldimethyldicarboxylate (DDB) (375 mg/kg)-treated rat showing minimal fibrosis, macro and microvacuolar degeneration, some pyknotic nuclei and karyolysis; (C) CCl₄ and DDB (75 mg/kg) + silymarin (22 mg/kg)-treated rat showing vacuolar degeneration, signs of degeneration in the form of pyknosis, karyolysis and hypertrophy of Kupffer cells (H & E x 200).

Image Analysis of Liver Fibrosis

Examination Masson's trichrome stained sections from normal rats showed that collagen occurred as wavy fibril either singly or fused together in dense bundles (Fig. 3A). Liver fibrosis was assessed directly by the hepatic morphometric analysis that has been considered the gold standard for quantification of fibrosis. Significant increase in the area of fibrosis ($p < 0.05$) was observed in liver sections from rats treated with CCl₄ only or CCl₄ together with DDB at 3 mg/kg (Table 2 & Fig. 3B). Significant decrease in the area of fibrosis was seen in liver sections from rats treated with CCl₄ together with DDB at 15, 75 or 375 mg/kg compared with CCl₄ control group (Fig. 3C). Significant decrease in the area of fibrosis was also observed after treatment with DDB (75 mg/kg) combined with silymarin (Table 2 & Fig. 3D).

Table 2.
Quantitative study of the area of fibrosis in different groups

Treatment	Area of damage
Saline (normal)	0.0 ± 0.0
CCl ₄ control	42.2 ± 5.2
+ silymarin 22 mg/kg	20.2 ± 5.2*
+ DDB 3 mg/kg	38 ± 4.1
+ DDB 15 mg/kg	26.9 ± 4.0*
+ DDB 75 mg/kg	23.6 ± 2.3*
+ DDB 375 mg/kg	22.0 ± 3.1*
+ DDB 75 mg/kg + silymarin 22 mg/kg	21.9 ± 1.4*

$P < 0.05$ vs CCl₄ control group. One way ANOVA and Duncan's multiple range test.

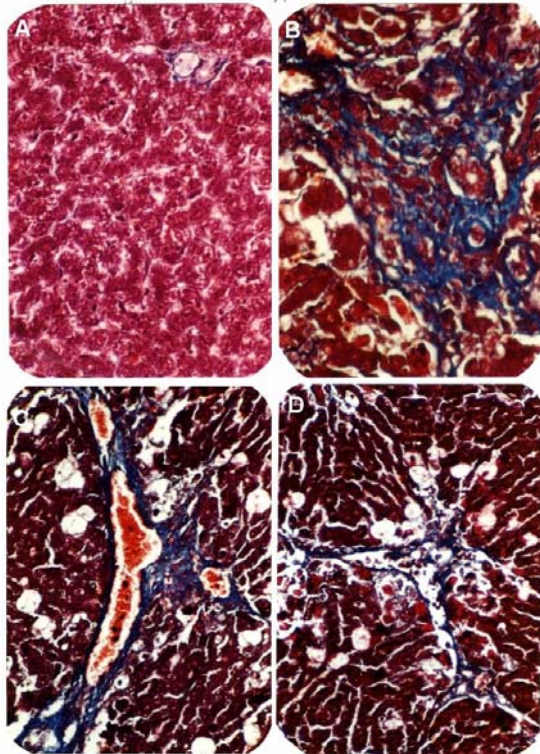


FIGURE 3. Section of liver stained with Masson trichrome stain showing collagen occurred as wavy fibrils either singly or fused together in dense bundles (A) control (normal) rat; (B) CCl_4 -treated rat: increased deposition of fibrous tissue; (C) CCl_4 + biphenyldimethylidicarboxylate (DDB) (375 mg/kg)-treated rat: moderate amount of fibrous tissue; (D) CCl_4 + DDB (75 mg/kg) + silymarin (22 mg/kg)-treated rat: mild deposition of fibrous tissue (Masson trichrome stain x 200).

Table 3.
DNA content in rat hepatocytes treated with CCl_4 , silymarin, DDB or DDB + silymarin

Group	<1.5c		1.5c-2.5c		2.5c-3.5c		3.5c-4.5c		>4.5c	
	% cells	DNA index	% cells	DNA index	% cells	DNA index	% cells	DNA index	% cells	DNA index
Saline (normal)	22.0 ± 0.15	0.65	71.0 ± 0.26	1.01	14.0 ± 0.21	1.37	2.0 ± 0.63	(2.02)	0.00	
CCl_4 control	8.0 ± 0.21	0.63	60.0 ± 0.28	1.03	29.0 ± 0.33	1.46	2.0 ± 0.25	(1.86)	3.0 ± 0.4	2.66
+ DDB 3 mg/kg	3.0 ± 0.2	0.56	31.0 ± 0.29	1.04	41.0 ± 0.31	1.49	20.0 ± 0.26	(1.95)	5.0 ± 0.6	2.87
+ DDB 75 mg/kg	22.0 ± 0.22	0.65	38.0 ± 0.29	1.01	31.0 ± 0.25	1.45	10.0 ± 0.22	(1.94)	2.0 ± 0.04	2.48
+ DDB 375 mg/kg	16.0 ± 0.1	0.68	52.0 ± 0.28	1.01	30.0 ± 0.23	1.41	6.0 ± 0.12	(1.87)	2.0 ± 0.01	2.33
+ DDB 75 mg/kg + silymarin 22 mg/kg	66.0 ± 0.18	0.59	34.0 ± 0.2	0.86	0.00	0.00	0.00	0.00	0.00	

* $P < 0.05$ (ANOVA) vs CCl_4 control group. One-way ANOVA and Duncan's multiple range test.

Histochemical Results

DNA Content

Image analyzer automatically expresses the DNA content of each individual cell measured then give the percentage of each cell out of the total number of cells examined and classifies cells into four categories namely diploid (2c), proliferation index (s-phase cells)(3c), tetraploid (4c) and cells with more than 4.5c DNA content which indicates aneuploidy. Table 3 & Fig. 4A shows the DNA content in normal rats. The liver of rats treated with CCl₄ only resulted in 3% of the examined cells more than 4.5c (aneuploid), 60% of cells contained diploid DNA value (2c), 29% of the examined cells contained 3c DNA value (proliferation index was high), 2% of the examined cells were at the 4c area (tetraploid), 18% of the examined cells contained DNA<1.5c (Table 3 & Fig. 4B). Examination of liver sections from rats treated with CCl₄ together with DDB at 15 mg/kg showed that 5% of the examined cells were more than 5c (aneuploid), 31% of the cells contained diploid DNA value (2c), 41% contained 3c DNA (proliferation index was high), 20% were at the 4c area (tetraploid) (Table 3). In liver sections from rats treated with CCl₄ and DDB at 75 mg/kg, 38% of cells contained diploid DNA value (2c), 31% of cells contained 3c DNA value (high proliferation index), 10% of cells were at 4C area (tetraploid) (Table 3). In liver sections from rats treated with CCl₄ and DDB at 375 mg/kg, 52% of cells contained diploid DNA value, 16% of cells contained DNA <1.5c, 30% contained 3c DNA value (high proliferation index) (Table 3 & Fig. 4C). In liver sections from rats treated with CCl₄ and DDB combined with silymarin, 34% of cells contained diploid DNA value, 66% of cells contained DNA <1.5c, no DNA aneuploid cells could be observed proliferation index equal zero (Table 3 & Fig. 4D).

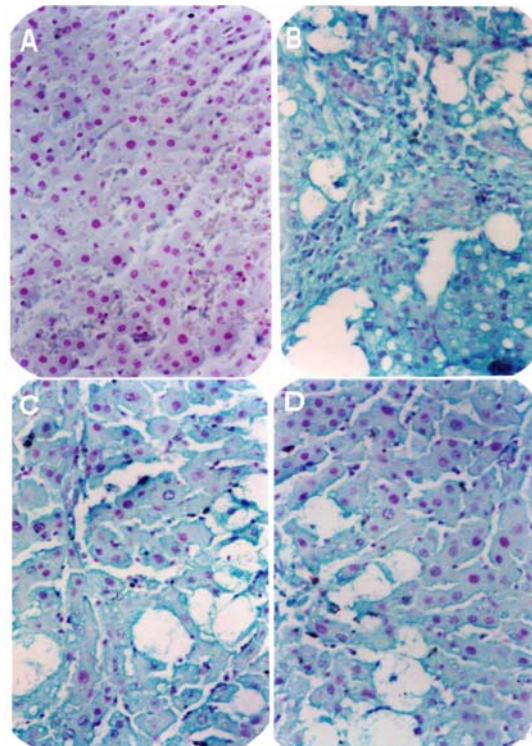


FIGURE 4. Section of liver stained with Feulgen stain showing DNA in hepatocytes (A) control (normal) rat; (B) CCl₄-treated rat showing decreased DNA contents; (C) CCl₄ + DDB (375 mg/kg)-treated rat showing mild improvement in DNA content; (D) CCl₄ + DDB (75 mg/kg) + silymarin (22 mg/kg)-treated rat showing moderate improvement in DNA contents (Feulgen reaction x 200).

Glycogen Content

Fig. 5A shows the distribution of glycogen contents in liver tissue stained by Periodic acid Schiff's (PAS), characterized in normal rats by deeply stained reddish granules in the cytoplasm of hepatocytes. The peripheral zonal cells showed higher mucopolysaccharide content than the central cells. The glycogen content was sharply reduced in the cytoplasm of hepatocytes from rats treated with CCl_4 alone (control) or CCl_4 combined with DDB 15 mg/kg (Fig. 5B). In rats treated with CCl_4 combined with DDB 75 or 375 mg/kg, moderate increase in mucopolysaccharide content was observed especially in the center of the lobules (Fig. 5C), while in rats treated with CCl_4 combined with DDB and silymarin, mucopolysaccharide content almost approximated normal control (Fig. 5D).

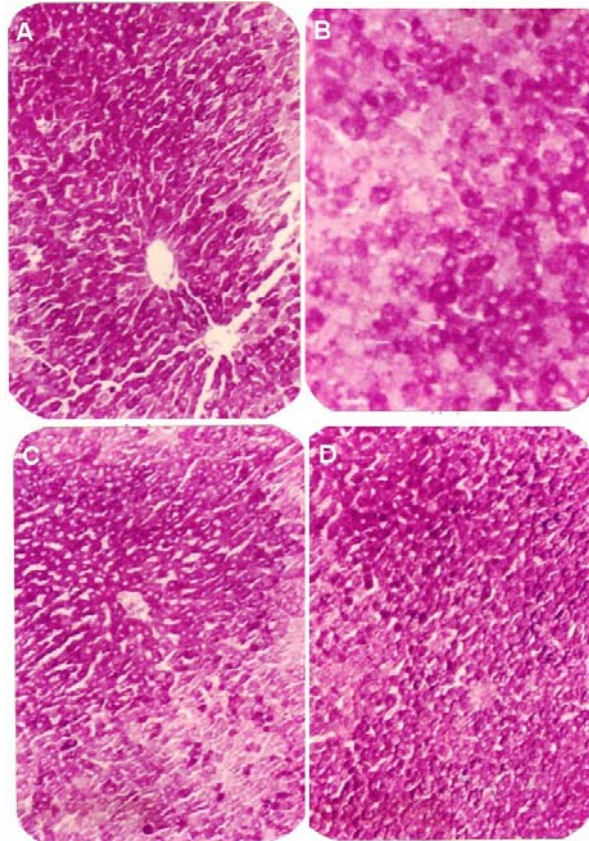


FIGURE 5. Section of liver stained with Periodic acid-Schiff stain showing mucopolysaccharide materials in the cytoplasm of hepatocytes: (A) control (normal) rat; (B) CCl_4 -treated rat showing marked diminution of mucopolysaccharides in the cytoplasm of some hepatocytes; (C) CCl_4 + DDB (375 mg/kg)-treated rat showing increase in mucopolysaccharide content; (D) CCl_4 + DDB (75 mg/kg) + silymarin (22 mg/kg)-treated rat showing mucopolysaccharide contents more or less normal (Periodic acid-Schiff reaction x 200).

Protein Content

Mercuric bromophenol blue staining was used to demonstrate total protein content in liver sections. Examination of liver sections from normal rats showed moderate protein content in the cytoplasm of hepatocytes. Some nuclei showed deep protein content (Fig. 6A). Rats treated with CCl_4 alone (control) or CCl_4 combined with DDB 15 mg/kg exhibited marked diminution of protein content in the cytoplasm of hepatocytes and the stainability was mostly diffused (Fig. 6B). Moderate increase in protein content was recorded in case of rats with CCl_4 along with DDB 75 or 375 mg/kg, compared to rats treated with

CCl₄ alone (Fig. 6C). An increase in protein content was also observed in case of rats with CCl₄ along with DDB and silymarin, compared to rats treated with CCl₄ alone (Fig. 6D).

DISCUSSION

The present study provides evidence that in a model of hepatic injury and fibrosis caused by chronic administration of CCl₄ in rats, the synthetic compound DDB decreased leakage of hepatocellular enzymes ALT and AST into plasma and lessened the development of hepatic fibrosis necrosis and fibrosis caused by CCl₄. Cellular dysfunction induced by CCl₄ and evidenced by reduced glycogen and protein content in hepatocytes and DNA alterations was largely prevented by DDB. Similar findings were observed on treatment with silymarin. These findings indicate that both DDB and silymarin limit hepatocellular injury and exert antifibrotic effect. A benefit from combining both DDB and silymarin was seen on histochemical investigation in the form of a better improvement in protein, DNA, mucopolysaccharide content compared to DDB alone.

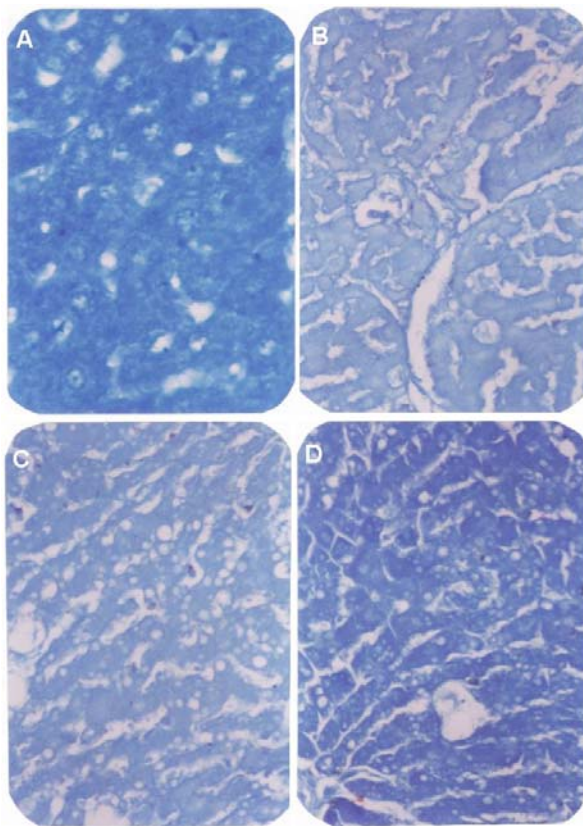


FIGURE 6. Section of liver stained with bromophenol blue showing greenish blue protein content in the cytoplasm of hepatocytes: (A) control (normal) rat; (B) CCl₄-treated rat showing marked diminution of protein content; (C) CCl₄ + DDB (375 mg/kg)-treated rat showing moderate improvement in DNA content; (D) CCl₄ + DDB (75 mg/kg) + silymarin (22 mg/kg)-treated rat showing that protein content approximated control (Bromophenol blue stain x 200).

In a number of *in vivo* and *in vitro* models of hepatocyte injury, the administration of DDB has been reported to protect the liver from a variety of toxicants. The drug decreased serum ALT levels along with an inhibitory effect on CCl₄-induced lipid peroxidation and on the binding of CCl₄-metabolites to lipids of liver microsomes[8,14,15,32]. In isolated suspended rat hepatocytes, DDB protected the hepatocytes against CCl₄ and D-galactosamine induced damage. Membrane lipid peroxidation (malondialdehyde

formation) and ALT release from the hepatocytes were markedly decreased. The damage of the cell surfaces of the hepatocytes was also reduced as seen under a scanning electron microscope[32]. Increased oxidative stress is a feature of CCl₄-induced liver injury in which Kupffer cells and neutrophils have significant role[33,34]. Excessive lipid peroxidation results from CCl₄ due to formation of trichloromethyl free radical within the membrane of the endoplasmic reticulum[35,36]. The beneficial effects of DDB in protecting the hepatocytes from CCl₄-induced damage could thus be the result of decreased oxidative burden. In other studies, DDB reduced hepatic fatty degeneration induced by ethanol treatment in rats along with an inhibitory effect on malondialdehyde formation in liver homogenates[37]. The administration of DDB also ameliorated the reduction of liver glycogen and blood glucose caused by D-galactosamine in mice[14]. Liver injury mediated by immune response in concanavalin A-treated mice was markedly reduced by prior administration of DDB with serum ALT and bilirubin being decreased[38]. In man and despite the widespread use of DDB in patients with chronic liver diseases, little information is available as regards to the effect of this drug on disease progression. In patients with chronic liver disease, rapid decrease and even normalization of serum transaminases has been reported[12,13]. Unlike ALT levels, aspartate aminotransferase, gamma-glutamyl transferase and glutamate dehydrogenase levels were not affected and it was suggested that the normalization of ALT during DDB treatment does not indicate therapeutic efficacy[13].

Silymarin, a standardized plant extract, has a worldwide reputation as a hepatoprotective agent. In chronic alcoholic liver disease, silymarin reduced serum bilirubin, and transaminases[16,17]. Others, however, failed to demonstrate such benefit from silymarin in patients with chronic hepatitis C infection[11]. Studies in patients with liver disease have shown that silymarin increased superoxide dismutase activity of lymphocytes and erythrocytes[39], increased glutathione levels and decreased lipid peroxidation in peripheral blood cells[40,41].

In the present study, treatment of rats with CCl₄ for one month induced marked fibrosis, architectural distortion, cirrhotic nodules and the appearance of many pseudo lobules, which in accordance with other studies[42,43]. Hepatic fibrosis is the most important pathogenic mechanism towards end-stage liver disease necessitating liver transplantation[3]. Liver fibrosis represents the response of the liver to diverse chronic insults e.g., viral, toxic, metabolic and immunological. Regardless of the aetiology, liver fibrosis is characterized by an increase in extracellular matrix proteins including collagen in perisinusoidal and periportal spaces that collectively form hepatic scars. The significance of liver fibrosis derives from the fact that it progresses rapidly to cirrhosis in several clinical settings[44] and is a high risk factor for developing hepatocellular carcinoma[4]. Hepatic inflammation appears to be the key pathological substrate that drives fibrogenesis. This makes sense as inflammation and cellular damage are intuitively linked to the fibrotic process via leucocyte/hepatic stellate cell (HSC) interaction, cytokine networks, proinflammatory small molecules (for example, reactive oxygen species), and insoluble mediators such as the hepatic neomatrix during wound healing[45].

In the present work, treatment of rats with DDB or silymarin along with CCl₄ resulted in diminution of cirrhosis and fibrosis. Other researchers reported that dimethylnitrosamine (DMN)-induced liver fibrogenesis, however, was not reduced by DDB[28]. In rats treated with CCl₄, Favari and Perez-Alvarez[46] reported a 55% reduction in liver collagen by silymarin. In rats with secondary biliary cirrhosis, silymarin reduced hepatic collagen accumulation by 35%[47]. It is worth to note that both DDB and silymarin possess important anti-inflammatory properties, which are likely to be of relevance to their hepatoprotective and antifibrotic effects. Kang et al.[28] suggested that DDB decreases liver cell injury and inflammation through inhibition of nuclear factor- κ B. In an immune-mediated liver injury caused by concanavalin A in mice, the elevation of serum TNF- α and liver TNF- α mRNA expression 2 h after Con A injection was decreased by the prior administration of DDB[38]. Silymarin inhibited the migration of neutrophils into the inflamed site[48], an important early event in the inflammation cascade. The reduction of plasma levels of the liver associated enzymes, ALT and AST by DDB or silymarin observed in the present study and in other studies suggests a reduction of hepatic inflammation by either drug. Aminotransferase levels are sensitive indicators of liver-cell injury. Both enzymes are released into the blood in increasing amounts whenever the liver cell membrane is damaged. It is thus likely that the

observed effect of DDB or silymarin on hepatic fibrosis in the present study is a consequence of a reduction in the inflammatory response caused by CCl₄.

Image cytometry for DNA quantitation has become an established technique in the field of analytical cellular pathology, providing significant information about biological behavior of cells[49]. In the hepatocyte, clonal perpetuation of accumulated DNA aneuploid affecting growth regulatory genes eventually leads to a continuation of severe progressive abnormalities characterized by dysplasia, formation of adenoma and, finally, cancer[50]. In the present study, treatment of rats with CCl₄, resulted in 3% of hepatocytes being aneuploid (>5c), while 60% of the examined cells contained diploid DNA value (2c) together with high proliferation index. Carbon tetrachloride-induces liver cell dysplasia which is a step towards the development of hepatocellular carcinoma. The dysplastic hepatocytes shows aneuploid DNA patterns which increase with increasing histological grade and stage of tumours[51,52]. In the present study, in liver sections from rats treated with CCl₄ and DDB at 75 mg/kg combined with silymarin, no aneuploid cells could be noticed, while proliferation index equaled zero. Other researchers reported a chemopreventive and tumour reversing effect for biphenyl dimethyl dicarboxylate on malignant transformation[53,54]. DDB significantly inhibited hepatocyte nuclear DNA fragmentation 12 h after Con A injection and prevented the direct DNA damage induced by CuSO₄ *in vitro*[38]. In human prostate cancer (PCA) PC3 cells, silymarin and its principle component silibinin inhibited cell proliferation, induced cell death, and caused G1 and G2-M cell cycle arrest in a dose/time-dependent manner[55]. Silibinin treatment of human bladder cancer cells had similar effects[56].

The present study in addition aimed to investigate whether there would be a benefit from combining both DDB and silymarin. It was observed that the combination DDB 75 mg/kg + silymarin did not improve AST, ALT and ALP activity compared with DDB 75 or 375 mg/kg alone. In addition, the effect of DDB (75mg/kg) plus silymarin (22 mg/kg) on area of fibrosis was similar to that obtained with the administration of DDB alone. Nevertheless, a benefit from combining both DDB and silymarin was observed on histochemical investigation in the form of a better improvement in protein, DNA, mucopolysaccharide content compared to DDB alone. Furthermore, no aneuploid cells were present when silymarin was combined with DDB. Silymarin has metabolic and cell-regulating effects at concentrations found in clinical conditions, namely carrier-mediated regulation of cell membrane permeability, inhibition of the 5-lipoxygenase pathway, scavenging of reactive oxygen species and an action on DNA-expression, for example, via suppression of nuclear factor (NF)-kappaB[57]. This in addition to the effect of silymarin on cell proliferation[55,56] suggests that silymarin may be a useful additive therapy in patients with chronic liver disease treated with DDB.

In summary, hepatocellular injury and hepatic fibrosis evoked by the administration of CCl₄ for one month in rats was ameliorated by the co-administration of the synthetic compound DDB. Furthermore, these effects were associated with a reduction in aneuploid cells particularly when DDB was given together with silymarin. The drug in combination with silymarin is therefore likely to be of benefit in reducing the likelihood of malignant transformation in patients with chronic liver disease. With high doses of DDB, blood urea and creatinine were raised which warrants monitoring of kidney functions in patients taking the drug.

REFERENCES

1. Alter, M., Kruszon-Moran, D., Nainan, O., McQuillan, G., Gao, F., Moyer, L., Kaslow, R., et al. (1999). The prevalence of hepatitis C virus infection in the United States, 1988 through 1994. *N Engl J Med*, **341**, 556-562.
2. Takahashi, M., Yamada, G., Miyamoto, R., Doi, T., Endo, H., and Tsuji, T. (1993). Natural course of chronic hepatitis C. *Am J Gastroenterol*, **88**, 240-243.
3. Poynard, T., Bedossa, P., and Opolon, P. (1997.) Natural history of liver fibrosis progression in patients with chronic hepatitis C. The OBSVIRC, METAVIR, CLINIVIR, and DOSVIRC groups. *Lancet* **349**, 825-832.
4. Ohata, K., Hamasaki, K., Toriyama, K., Ishikawa, H., Nakao, K., and Eguchi, K. (2004). High viral load is a risk factor for hepatocellular carcinoma in patients with chronic hepatitis B virus infection. *J Gastroenterol Hepatol*. **19**, 670-675.
5. Manns, M.P., McHutchison, J.G., Gordon, S.C., Rustgi, V.K., Shiffman, M., Reindollar, R., Goodman, Z.D., Koury, K., Ling, M., and Albrecht, J.K. (2001). Peginterferon alfa-2b plus ribavirin compared with interferon alfa-2b plus ribavirin

- for initial treatment of chronic hepatitis C: a randomised trial. *Lancet*, **358**, 958-965.
6. Fried, M.W. (2002). Side effects of therapy of hepatitis C and their management. *Hepatology* **36**, S237-S244.
 7. Bacon, B.R. (2004). Managing Hepatitis C. *Am J Manag Care*. **10**, S30-S40.
 8. Liu, K.T. and Lesca, P. (1982). Pharmacological properties of Dibenz[a,c]cyclooctene derivatives isolated from *Fructus Schizandrae Chinesis* III. Inhibitory effects on carbon tetrachloride-induced lipid peroxidation, metabolism and covalent binding of carbon tetrachloride to lipids. *Chem Biol Interact*. **41**, 39-47.
 9. Li XY. 1991. Bioactivity of neolignans from fructus *Schizandrae*. *Mem Inst Oswaldo Cruz*. 86 Suppl 2: 31-37.
 10. Pratt, D.S. and Kaplan, M.M. (1999). Laboratory tests. In: Schiff ER, Sorrell MF, Maddrey WC, eds. Schiff's diseases of the liver. 8th ed. Vol. 1. Philadelphia: Lippincott-Raven, 205-244.
 11. Gordon, S.C., Fang, J.W.S., Silverman, A.L., Mchutchison, J.G., and Albert, J.K. (2000). The significance of baseline serum alanine aminotransferase on pretreatment disease characteristics and response to antiviral therapy in chronic hepatitis C. *Hepatology* **32**, 400-404.
 12. Akbar, N., Tahir, R.A., Santoso, W.D., Soemarno, Sumaryono, Noer, H.M., and Liu, G. (1998). Effectiveness of the analogue of natural Schisandrin C (HpPro) in treatment of liver diseases: an experience in Indonesian patients. *Chin Med J (Engl)*. **111**, 248-251.
 13. Huber, R., Hockenjos, B., and Blum, H.E. (2004). DDB treatment of patients with chronic hepatitis. *Hepatology*. **39**, 1732-1733.
 14. Fu, T. and Liu, G. (1992). Protective effects of dimethyl-4,4'-dimethoxy-5,6,5',6'-dimethylene dioxybiphenyl-2,2'-dicarboxylate on damages of isolated rat hepatocytes induced by carbon tetrachloride and D-galactosamine. *Biomed Environ Sci*. **5**, 185-194.
 15. Liu, T.Y., Hwua, Y.S., Chao, T.W., and Chi, C.W. (1995). Mechanistic study of the inhibition of aflatoxin b1-induced hepatotoxicity by dimethyl 4,4'-dimethoxy-5,6,5',6'-dimethylenedioxy biphenyl-2, 2'-dicarboxylate. *Cancer Lett*. **89**, 201-205.
 16. Feher, J., Deak, G., Muzes, G., Lang, I., Niederland, V., Nekam, K., and Kartesz, M. (1989). Liver protective action of silymarin therapy in chronic alcoholic liver diseases. *Orv Hetil*. **130**, 2723-2727.
 17. Pares, A., Planas, R., Torres, M., Caballeria, J., Viver, J.M., Acero, D., Panes, J., Rigau, J., Santos, J., and Rodes, J. (1998). Effects of silymarin in alcoholic patients with cirrhosis of the liver: results of a controlled, double-blind, randomized and multicenter trial. *J Hepatol*. **28**, 615-621.
 18. Wellington, K. and Jarvis, B. (2001). Silymarin: a review of its clinical properties in the management of hepatic disorders. *BioDrugs*. **15**, 465-489.
 19. Muriel, P. and Mourelle, M. (1990). Prevention by silymarin of membrane alterations in acute CCl₄ liver damage. *J Appl Toxicol*. **10**, 275-279.
 20. Muriel, P., Garciapina, T., Perez-Alvarez, V., and Mourelle, M. (1992). Silymarin protects against paracetamol-induced lipid peroxidation and liver damage. *J Appl Toxicol*. **12**, 439-442.
 21. Chungoo, V.J., Singh, K., and Singh, J. (1997) Silymarin mediated differential modulation of toxicity induced by carbon tetrachloride, paracetamol and d-galactosamine in freshly isolated rat hepatocytes. *Indian J Exp Biol*. **35**, 611-617.
 22. Wu, C.G., Chamuleau, R.A., Bosch, K.S., and Frederiks, W.M. (1993). Protective effect of silymarin on rat liver injury induced by ischemia. *Virchows Arch B Cell Pathol*. **64**, 259-263.
 23. Mourelle, M., Muriel, P., Favari, L., and Franco, T. (1989). Prevention of CCl₄-induced liver cirrhosis by silymarin. *Fundam Clin Pharmacol*. **3**, 183-191.
 24. Jia, J.D., Bauer, M., Cho, J.J., Ruehl, M., Milani, S., Boigk, G., Riecken, E.O., and Schuppan, D. (2001). Antifibrotic effect of silymarin in rat secondary biliary fibrosis is mediated by downregulation of procollagen alpha1(I) and TIMP-1. *J Hepatol*. **35**, 392-398.
 25. Lieber, C.S., Leo, M.A., Cao, Q., Ren, C., and DeCarli, L.M. (2003). Silymarin retards the progression of alcohol-induced hepatic fibrosis in baboons. *J Clin Gastroenterol*. **37**, 336-339.
 26. Flora, K., Hahn, M., Rosen, H., and Benner, K. (1998). Milk thistle (*Silybum marianum*) for the therapy of liver disease. *Am J Gastroenterol*. **93**, 139-143.
 27. Farghali, H., Kamenikova, L., Hynie, S., and Kmonickova, E. (2000). Silymarin effects on intracellular calcium and cytotoxicity: a study in perfused rat hepatocytes after oxidative stress injury. *Pharmacol Res*. **41**, 231-237.
 28. Kang, K.W., Kim, Y.G., Kim, C.W., and Kim, S.G. (2002). The anti-fibrogenic effect of a pharmaceutical composition of [5-(2-pyrazinyl)-4-methyl-1,2-dithiol-3-thione] (oltipraz) and dimethyl-4,4'-dimethoxy-5,6,5',6'-dimethylene dioxybiphenyl-2,2'-dicarboxylate (DDB). *Arch Pharm Res*. **25**, 655-663.
 29. Abdel-Salam, O.M.E., Sleem, A.A., Hassan, N.S., Sharaf, H.A., and Mózsik, Gy. (2006). Capsaicin ameliorates hepatic injury caused by carbon tetrachloride in the rat. *J Pharmacol Toxicol*. **1**, 147-156.
 30. Crowley, L.V. (1967). The Reitman-Frankel colorimetric transaminase procedure in suspected myocardial infarction. *Clin Chem*. **13**, 482-487.
 31. Belfield, A. and Goldberg, D.M. (1971). Revised assay for serum phenyl phosphatase activity using 4-amino-antipyrine. *Enzyme*. **12**, 561-573.
 32. Oh, S.Y., Lee, C.H., and Ku, Y.S. (2000). Pharmacokinetics and hepatoprotective effects of 2-methylaminoethyl-4,4'-dimethoxy-5,6,5',6'-dimethylenedioxybiphenyl-2-carboxylic acid-2'-carboxylate monohydrochloride in rats with CCl₄-induced acute hepatic failure. *J Pharm Pharmacol*. **52**, 1099-1103.
 33. Montosi, G., Garuti, C., Iannone, A., and Pietrangelo, A. (1998). Spatial and temporal dynamics of hepatic stellate cell

- activation during oxidant-stress-induced fibrogenesis. *Am J Pathol.* **152**, 1319-1326.
34. Poli, G. (2000). Pathogenesis of liver fibrosis: role of oxidative Stress. *Mol Asp Med.* **21**, 49-98.
 35. Lee, P.Y., McCay, P.B., and Hornbrook, K.R. (1982). Evidence for carbon tetrachloride-induced lipid peroxidation in mouse liver. *Biochem Pharmacol.* **31**, 405-409.
 36. Muriel P, Alba N, Perez-Alvarez VM, Shibayama M, Tsutsumi VK. 2001. Kupffer cells inhibition prevents hepatic lipid peroxidation and damage induced by carbon tetrachloride. *Comp Biochem Physiol C Toxicol Pharmacol.* **130**, 219-226.
 37. Kim, S.N., Kim, S.Y., Yim, H.K., Lee, W.Y., Ham, K.S., Kim, S.K., Yoon, M.Y., and Kim, Y.C. (1999). Effect of dimethyl-4,4'-dimethoxy-5,6,5',6'-dimethylenedioxybiphenyl-2,2'-dicarboxylate (DDB) on chemical-induced liver injury. *Biol Pharm Bull.* **22**, 93-95.
 38. Gao, M., Zhang, J., and Liu, G. (2005). Effect of diphenyl dimethyl bicarboxylate on concanavalin A-induced liver injury in mice. *Liver Int.* **25**, 904-912.
 39. Feher, J., Lengyel, G., and Blazovics, A. (1998). Oxidative stress in the liver and biliary tract diseases. *Scand J Gastroenterol (Suppl).* **228**, 38-46.
 40. Par, A., Roth, E., Rumi, G., Kovacs, Z., Nemes, J., and Mozsik, G. (2000). Oxidative stress and antioxidant defense in alcoholic liver disease and chronic hepatitis C. *Orv Hetil.* **141**, 1655-1659.
 41. Lucena, M.I., Andrade, R.J., de-la-Cruz, J.P., Rodriguez-Mendizabal, M., Blanco, E., and Sanchez-de-la-Cuesta, F. (2002). Effects of silymarin MZ-80 on oxidative stress in patients with alcoholic cirrhosis. Results of a randomized, double-blind, placebo-controlled clinical study. *Int J Clin Pharmacol Ther.* **40**, 2-8.
 42. Gonzalez-Reimers, E., Lopez-Lirola, A., Olivera, R.M., Santolaria-Fernandez, F., Galindo-Martin, L., Abreu-Gonzalez, P., Sanchez-Sanchez, J.J., and Martinez-Riera, A. (2003). Effects of protein deficiency on liver trace elements and antioxidant activity in carbon tetrachloride-induced liver cirrhosis. *Biol Trace Elem Res.* **93**, 127-140.
 43. Lee, J.Y., Lee, S.H., Kim, H.J., Ha, J.M., Lee, S.H., Lee, J.H., and Ha, B.J. (2004). The preventive inhibition of chondroitin sulfate against the CCl₄-induced oxidative stress of subcellular level. *Arch Pharm Res.* **27**, 340-345.
 44. Bataller, R. and Brenner, D.A. (2005). Liver fibrosis. *J Clin Invest.* **115**, 209-218.
 45. McCaughan, G.W. and George, J. (2004). Fibrosis progression in chronic hepatitis C virus infection. *Gut.* **53**, 318-321.
 46. Favari, L. and Perez-Alvarez, V. (1997). Comparative effects of colchicine and silymarin on CCl₄-chronic liver damage in rats. *Arch Med Res.* **28**, 11-17.
 47. Boigk, G., Stroedter, L., Herbst, H., Waldschmidt, J., Riecken, E.O., and Schuppan, D. (1997). Silymarin retards collagen accumulation in early and advanced biliary fibrosis secondary to complete bile duct obliteration in rats. *Hepatology* **26**, 643-649.
 48. De La Puerta, R., Martinez, E., Bravo, L., and Ahumada, M.C. (1996). Effect of silymarin on different acute inflammation models and on leukocyte migration. *J Pharm Pharmacol.* **48**, 968-970.
 49. Cohen, C. (1996). Image cytometric analysis in pathology. *Hum Pathol.* **27**, 482-493.
 50. Dragan, Y.P. and Pitot, H.C. (1992). The role of stages of initiation and promotion in phenotypic diversity during hepatocarcinogenesis in the rat. *Carcinogenesis.* **13**, 379-750.
 51. Thomas, R.M., Berman, J.J., Yetter, R.A., Moore, G.W., and Hutchins, G.M. (1992). Liver cell dysplasia: a DNA aneuploid lesion with distinct morphologic features. *Hum Pathol.* **23**, 496-503.
 52. Rim, K.S., Sakamoto, M., Watanabe, H., Matsuno, Y., Nakanishi, Y., Mukai, K., Hirohashi, S. (1993). Pathology and DNA Cytophotometry of Small Hepatocellular Carcinoma with a Nodule-in-nodule Appearance—Evidence for Stepwise Progression of Hepatocellular Carcinoma. *Jap J Clin Oncol.* **23**, 26-33.
 53. Liu, Z., Liu, G., and Zhang, S. (1996). Reversing effect of dimethyl-4,4'-dimethoxy-5,6,5', 6'-dimethylenedioxybiphenyl-2,2'-dicarboxylate (DDB) on the phenotypes of human hepatocarcinoma cells line. *Cancer Lett.* **108**, 67-72.
 54. Sun, H. and Liu, G.T. (2005). Chemopreventive effect of dimethyl dicarboxylate biphenyl on malignant transformation of WB-F344 rat liver epithelial cells. *Acta Pharmacol Sin.* **26**, 1339-1344.
 55. Deep, G., Singh, R.P., Agarwal, C., Kroll, D.J., and Agarwal, R. (2006). Silymarin and silibinin cause G1 and G2-M cell cycle arrest via distinct circuitries in human prostate cancer PC3 cells: a comparison of flavanone silibinin with flavanolan mixture silymarin. *Oncogene.* **25**, 1053-1069.
 56. Tyagi, A., Agarwal, C., Harrison, G., Glode, L.M., and Agarwal, R. (2004). Silibinin causes cell cycle arrest and apoptosis in human bladder transitional cell carcinoma cells by regulating CDKI-CDK-cyclin cascade, and caspase 3 and PARP cleavages. *Carcinogenesis* **25**, 1711-1720.
 57. Saller, R., Meier, R., and Brignoli, R. (2001). The use of silymarin in the treatment of liver diseases. *Drugs.* **61**, 2035-2063.

This article should be cited as follows:

Abdel-Salam, O.M.E., Sleem, A.A., and Morsy, F.A. (2007) Effects of Biphenyldimethyl-dicarboxylate administration alone or combined with silymarin in the CCL₄ model of liver fibrosis in rats. *TheScientificWorldJOURNAL* **7**, 1242-1255. DOI 10.1100/tsw.2007.193.
