

Renal failure caused by a partly calcified aortic aneurysm in a patient with dabigatran therapy

A case report

Philipp Jud, MD^{a,*}, Thomas Gary, MD^a, Kurt Tiesenhausen, MD^b, Rupert Portugaller, MD^c, Gerald Hackl, MD^d, Marianne Brodmann, MD^a

Abstract

Rationale: Abdominal aortic aneurysms (AAAs) are mostly asymptomatic. If aortic aneurysms become symptomatic, complications include peripheral embolization, acute aortic occlusion, and aortic rupture. However, there are also unusual complications caused by aortic aneurysms.

Patient concerns: An 87-old male with dabigatran therapy presented with newly developed melena and acute renal failure. Radiological imaging revealed an AAA with thrombotic and calcified deposits which affected the renal arteries.

Diagnoses: Gastrointestinal bleeding and hypercoagulation caused by renal failure which was triggered in turn due to an AAA.

Interventions: Adapted antihypertensive therapy and initiation of simvastatin 40mg once daily as well as antiplatelet therapy with aspirin 50mg once daily due to patient's refusal of any aneurysm intervention.

Outcome: Neither bleeding event nor aneurysm rupture occurred with the adapted antihypertensive therapy, simvastatin and aspirin.

Lessons: Nonruptured AAAs can cause rare, unusual, and even life-threatening complications depending on their size and anatomical position.

Abbreviation: AAA = abdominal aortic aneurysm.

Keywords: abdominal aortic aneurysm, gastrointestinal bleeding, hypercoagulation, renal failure

1. Introduction

Aortic aneurysms are mostly located in the abdominal aorta and usually asymptomatic. However, complications of aortic aneurysms are feared, especially the rupture with a mortality rate up to 90% and other complications including acute aortic occlusion or affection of adjacent organs.^[1] In our case, an asymptomatic abdominal aortic aneurysm (AAA) led to renal failure, which resulted consecutively in hypercoagulation and gastrointestinal bleeding.

Editor: Rita Marchi.

Ethics approval: Our institution does not require ethical approval for this type of research (case report).

The authors have no funding and conflicts of interest to disclose.

^a Division of Angiology, Department of Internal Medicine, ^b Division of Vascular Surgery, Department of Surgery, ^c Division of Vascular and Interventional Radiology, Department of Radiology, ^d Division of Intensive Care Medicine, Department of Internal Medicine, Medical University of Graz, Graz, Austria.

* Correspondence: Philipp Jud, Division of Angiology, Department of Internal Medicine, Medical University of Graz, Auenbruggerplatz 15, 8036 Graz, Austria (e-mail: philipp.jud@medunigraz.at).

Copyright © 2017 the Author(s). Published by Wolters Kluwer Health, Inc. This is an open access article distributed under the Creative Commons Attribution-NoDerivatives License 4.0, which allows for redistribution, commercial and non-commercial, as long as it is passed along unchanged and in whole, with credit to the author.

Medicine (2017) 96:17(e6789)

Received: 9 February 2017 / Received in final form: 25 March 2017 / Accepted: 7 April 2017

<http://dx.doi.org/10.1097/MD.0000000000006789>

2. Case

An 87-old male underwent a routine check after pacemaker implantation 3 years ago due to atrial fibrillation with slow ventricular response. He denied vertigo, dyspnea, or palpitations but he noticed melena without hematemesis for a few days. Due to the newly developed melena, the patient was transferred to the emergency department. His vital signs were stable and his abdomen was only slightly distended with regular bowel movements. However, laboratory tests revealed a low hemoglobin level (8.5 g/dL), a high creatinine level (3.12 mg/dL) as well as a prolonged thrombin time (>160 seconds). Except for pacemaker implantation, coronary artery bypass grafting and arterial hypertension were also previously known. Since the pacemaker implantation, the patient had an anticoagulant therapy with dabigatran 110 mg twice daily due to a CHA₂DS₂-VASc score of 4 points, a HAS-BLED score of 2 points, and normal creatinine levels (1.00 mg/dL).

During patient's hospitalization, dabigatran was paused and intravenous fluids were administered but the hemoglobin level decreased further and also the vital signs of the patient deteriorated. Therefore, blood substitution was administered and the patient underwent a gastroscopy whereby hematin residues with no obvious active bleeding site were detected. Despite initiation of high-dose pantoprazole and continued intravenous fluid therapy, the patient developed massive melena with a further decrease of the hemoglobin level. After another blood substitution and administration of 4000 IU prothrombin complex concentrate due to the persistent prolonged thrombin time (>160 seconds), the patient was transferred to the intensive

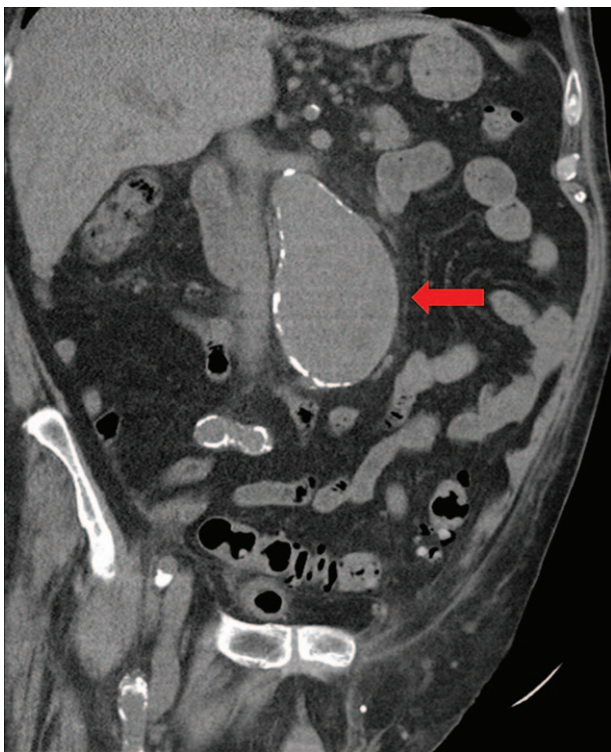

Figure 1. Computed tomography of the abdomen without contrast agent. Arrow points toward the infra-renal aortic aneurysm.

care unit for further observation. Due to the persistent anticoagulative effect of dabigatran caused by the renal failure, the patient underwent hemodialysis by which the effect of dabigatran decreased and the renal function ameliorated. The patient's vital signs as well as hemoglobin levels were stable, so that he was transferred back to the vascular ward.

On the next days, the patient's clinical condition began to deteriorate again with a reduced urine output. Creatinine level increased again and there was still a residual effect of dabigatran with a stable hemoglobin level. Dialysis was repeated and subsequently diuretic therapy with torasemide 10 mg twice daily

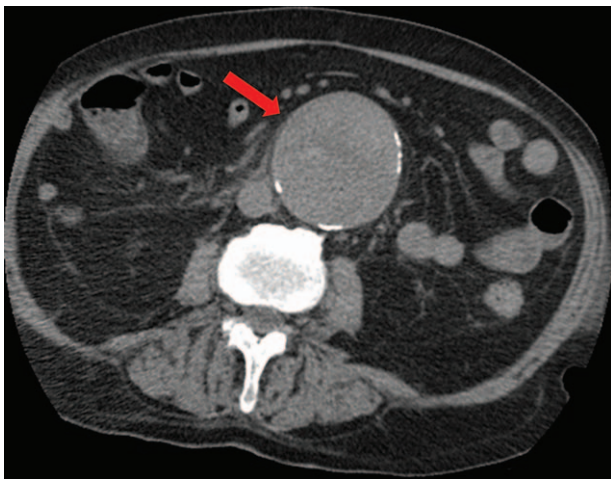


Figure 2. Computed tomography of the abdomen without contrast agent. Arrow points toward the infra-renal aortic aneurysm with a transversal diameter of 7.4 cm.

was initiated. To exclude renal and extra-renal causes for the renal failure, an abdominal ultrasonography including the kidneys and urinary tract was performed which revealed a diminished blood flow in the renal arteries and an AAA, which could be confirmed in a computed tomography. The computed tomography displayed a nonruptured AAA with marginal calcifications measuring approximately $6.9 \times 7.4 \times 9.4$ cm in size (Figs. 1 and 2). Additionally, the AAA affected both renal arteries and showed thrombotic deposits as well as calcifications at the exits of the renal arteries (Fig. 3).

Due to the poor clinical condition of the patient, an aortic surgery was not eligible. An endovascular aortic repair was technically possible in that patient, but the patient refused any intervention of the AAA. Therefore, the AAA was treated conservatively including an adapted antihypertensive therapy and initiation of simvastatin 40 mg once daily as well as antiplatelet therapy with aspirin 50 mg once daily to reduce the risk of plaque progression. Due to the gastrointestinal bleeding and the persistent impaired renal function, dabigatran was stopped. With that medication, the hemoglobin level remained stable so that the patient could be discharged. Since patient's discharge, no bleeding complication occurred and the size of the AAA remained so far.

3. Discussion

Aortic aneurysms are enlargements of the aorta, mostly located in the abdominal aorta. Known risk factors of AAA are age, male sex, smoking, arterial hypertension, and hypercholesterolemia.^[2] AAA are usually asymptomatic but if they increase in size, they can cause abdominal pain and back pain as well. Nevertheless, the complications of aortic aneurysms are feared, especially the rupture which results often in a massive bleeding with

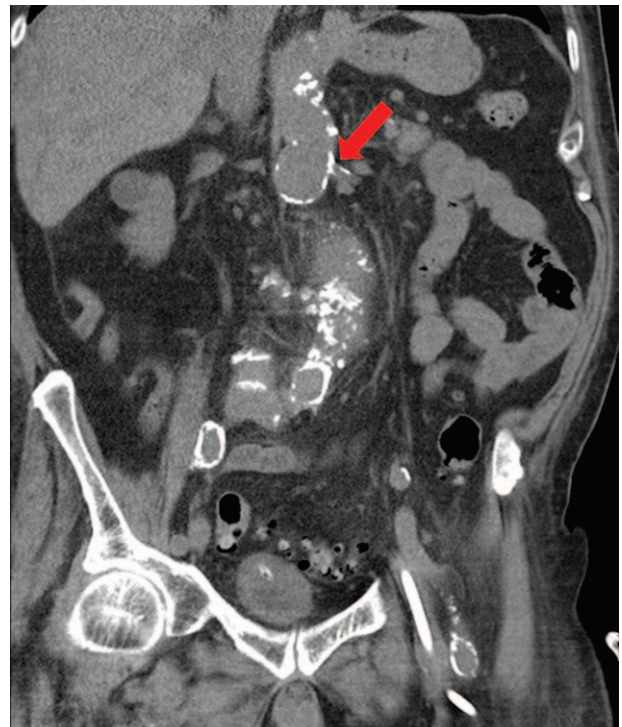

Figure 3. Computed tomography of the abdomen without contrast agent. Arrow points toward the calcified exit of the left renal artery.

hypovolemic shock. The mortality of an acute AAA rupture is up to 90%.^[1] Other complications of AAA include peripheral embolization and acute aortic occlusion. Adjacent organs and vessels can be affected and compressed due to the expansion of aortic aneurysm too. This could lead to nutcracker-syndrome or obstructive uropathy.^[3,4] In our case, the AAA with its thrombotic and calcified deposits led to a decreased perfusion of the kidneys and therefore to renal failure. Creatinine levels and creatinine clearance were normal when the patient underwent the pacemaker implantation 3 years ago and in the last pacemaker control 1 year ago. But within 1 year, the thrombotic and calcified deposits of the AAA led to a significant decrease of the renal arterial perfusion and consecutively to renal failure.

Many drugs can accumulate in patients with renal failure due to the reduced creatinine clearance rate. Dabigatran is one of such drugs. Side effects of dabigatran include anemia, thrombocytopenia, liver dysfunction, and several bleeding complications. The risk for hypercoagulation is increased in patients with a low creatinine clearance, and the administration of dabigatran is not recommended at a creatinine clearance lower than 30 mL/min.^[5] Our patient had a creatinine clearance of approximately 20 mL/min, and the dabigatran accumulation could be noticed by the prolonged thrombin time. An antidote to antagonize the effect of

dabigatran is idarucizumab which was unfortunately not approved at that time.

In conclusion, we want to remind physicians about rare and unusual complications of an asymptomatic AAA, which could be even life-threatening. In our case, an asymptomatic AAA got symptomatic by impairing the renal perfusion, promoted consecutively renal failure, and resulted in hypercoagulation and gastrointestinal bleeding.

References

- [1] Brown LC, Powell JT. Risk factors for aneurysm rupture in patients kept under ultrasound surveillance. UK Small Aneurysm Trial Participants. *Ann Surg* 1999;230:289–96.
- [2] Forsdahl SH, Singh K, Solberg S, et al. Risk factors for abdominal aortic aneurysms: a 7-year prospective study: the Tromsø Study, 1994–2001. *Circulation* 2009;119:2202–8.
- [3] Lozuk B, Tanaskovic S, Radak D, et al. Infrarenal abdominal aorta aneurysm: a rare cause of anterior nutcracker syndrome with associated pelvic congestion. *Ann Vasc Surg* 2014;28:263.e17–20.
- [4] Wu CJ, Hou SK, How CK, et al. Obstructive uropathy caused by atherosclerotic abdominal aortic aneurysm. *Intern Med* 2012;51:133.
- [5] Kirchhof P, Benussi S, Kotecha D, et al. 2016 ESC Guidelines for the management of atrial fibrillation developed in collaboration with EACTS. *Europace* 2016;18:1609–78.