


HOSTED BY



ELSEVIER

Contents lists available at ScienceDirect

International Journal of Pediatrics and Adolescent Medicine

journal homepage: <http://www.elsevier.com/locate/ijpam>

Images in pediatrics

Gastric bezoar

Farida Mohsin Sulaiman Ambusaidi ^a, Maryam Al-Yaqoubi ^{b, *}^a Radiology Department, Ibri Regional Hospital, Oman^b Family Medicine, Ibri Polyclinic, Oman

ARTICLE INFO

Article history:

Received 17 March 2020
 Received in revised form
 27 April 2020
 Accepted 18 May 2020
 Available online 30 May 2020

Keywords:

Gastric bezoar
 Tricobezoar
 Tricotillomania
 Gastrostomy
 Shadowing mass
 Filling defects

ABSTRACT

Gastric bezoar is an accumulation of indigestible masses in stomach. Depending on the composites of these masses, descriptive names are given like tricobezoar if the mass contains hair. Most of the patients have psychological issues that result in their desire to eat hair which predispose them to have gastric tricobezoar. Unfortunately, the presentation is usually very late with signs of gastric outlet obstruction which include abdominal pain, distension, nausea and vomiting. There are typical findings seen in abdominal radiograph like large intraluminal filling defect with mottled translucency and ultrasound finding of shadowing intra-luminal masses. The treatment of such cases includes laproscopic trial to remove the bezoar and if not successful to proceed for gastrostomy.

© 2020 Publishing services provided by Elsevier B.V. on behalf of King Faisal Specialist Hospital & Research Centre (General Organization), Saudi Arabia. This is an open access article under the CC BY-NC-ND license (<http://creativecommons.org/licenses/by-nc-nd/4.0/>).

1. Gastric bezoar

A previously known healthy 10-year-old female child presented to the radiology department for an abdominal ultrasound to assess the causes of one month history of abdomen pain and vomiting. Her previous records showed dermatology clinic follow ups for hair loss as a result of 5 months history of the child pulling out her hair and swallowing it. Abdominal ultrasound was done and it showed a distended stomach with shadowing mass (Fig. 1). Abdominal radiograph was done for correlation and demonstrated a large mass occupying the stomach with mottled lucencies (Fig. 2). There were also staples and tiny metallic foreign bodies within the mass. The picture was in keeping with a large bezoar causing gastric outlet obstruction. The child was referred to the gastroenterology department. Orogastrodoudenoscopy was done and revealed a large collection of hair in the stomach which could not be removed by endoscopy. The child underwent laparotomy and removal of the trichobezoar of the stomach. She was discharged from the hospital in good general health and oral intake, with unremarkable follow up with gastroenterology and psychiatric departments.

2. Discussion

Bezoars are indigestible masses accumulating in gastrointestinal tracts [1]. Depending on the composites of these masses, descriptive names are given such as trichobezoar if the mass contains hair, phytobezoar if it contains non digestible fruits and vegetables, lactobezoar if it contains non digestible milk content, and medication or metallic bezoar if it contains either of these components [1,2]. Most trichobezoars are located in the stomach and patients are commonly young female with psychiatric illness. Small bowel location and history of previous surgery are frequently observed in patients with phytobezoars who present with small bowel obstruction. Patients with medication and metallic bezoars usually have psychiatric illness. Lactobezoars are seen in infants with a history of dehydration or consumption of concentrated milk formula. Our patient had trichophagia (desire to eat hair) which predisposed her to have a gastric trichobezoar. Similar to our patient, most patients present very late with obstructive symptoms which include abdominal pain, distension, nausea, and vomiting. Imaging in these patients plays a significant role in assessing the causes of the bowel obstruction and the location of the bezoars. The abdominal radiograph typically shows large intraluminal filling defect with mottled translucency. The ultrasound findings include intra-luminal masses with posterior acoustic shadowing and echogenic arch-like surfaces [1–3]. With expertise, differentiation of gastric bezoars from gas and food particles could be easy as

* Corresponding author.

E-mail addresses: farida.ambusaidi@gmail.com (F.M. Sulaiman Ambusaidi), Omcf11167@omc.edu.om (M. Al-Yaqoubi).

Peer review under responsibility of King Faisal Specialist Hospital & Research Centre (General Organization), Saudi Arabia.

<https://doi.org/10.1016/j.ijpam.2020.05.002>

2352-6467/© 2020 Publishing services provided by Elsevier B.V. on behalf of King Faisal Specialist Hospital & Research Centre (General Organization), Saudi Arabia. This is an open access article under the CC BY-NC-ND license (<http://creativecommons.org/licenses/by-nc-nd/4.0/>).

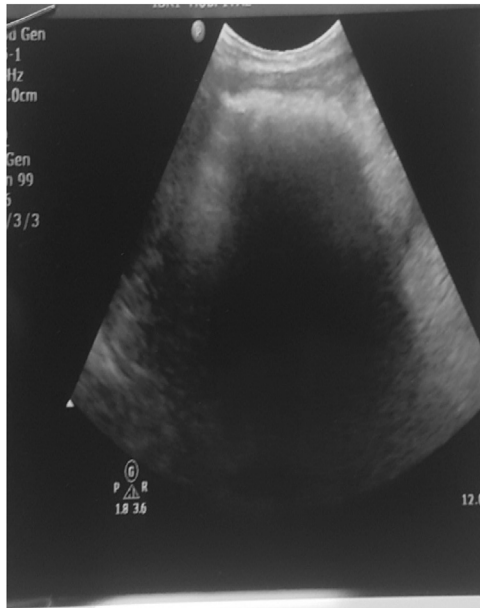


Fig. 1. Ultrasound abdomen with large shadowing epigastric mass.

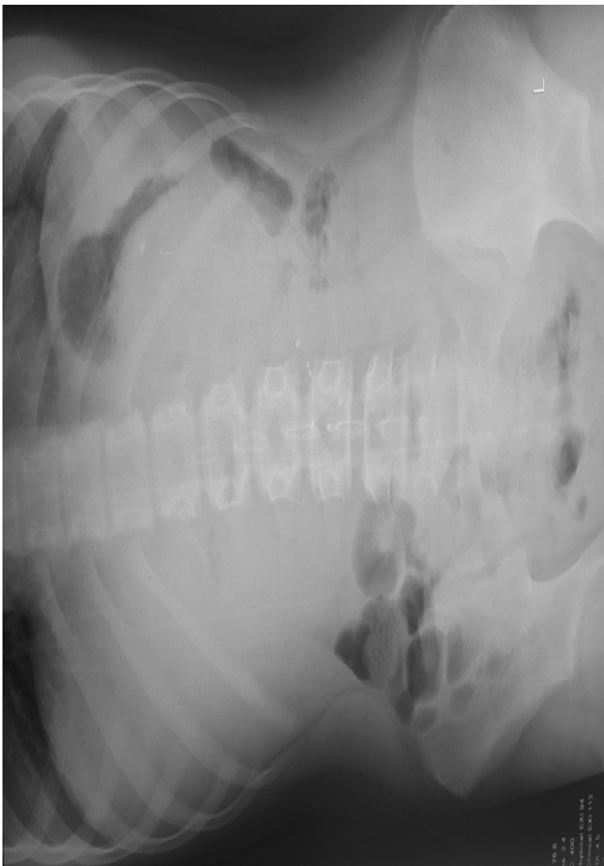


Fig. 2. Abdominal radiograph showing large intraluminal filling defect with mottled lucencies, staples, and a few metallic foreign bodies.

bezoars show a marked posterior acoustic shadowing in comparison to the hazy shadowing of the later. The CT scan of the abdomen is superior in locating the site and length of Bezoars which appear as well-defined low-density intraluminal masses containing air bubbles within the matrix [2] and resulting in dilatation of bowel loops proximal to bezoars.

In view of typical radiological findings from abdominal radiograph and ultrasound with the provided history of trichophagia, no further CT scan imaging was needed in our case. Laproscopic removal of the bezoar can be attempted, like in our patient, however due to their large size at presentation, most are removed by gastrostomy. For trichobezoar, the treatment also means overcoming the psychiatric factors resulting in the trichophagia [3].

Ethical statement

No disclosure of interest.

Author statement

Farida Ambusaidi: Idea of case report, writing the discussion and references, sending case for publication, changes of case according to reviewer and editor comments. Maryam Al-Yaqoubi: Writing history and clinical presentation, writing follow up of care, changes of case according to reviewer and editor comments.

Declaration of competing interest

No conflict of interest.

References

- [1] Ripolles T, Garcia-Aguayo J, Martinez MJ, Gil P. Gastrointestinal bezoars sonographic and CT characteristics. *AJR* 2001;177(1):65–9.
- [2] Altintoprak F, Degirmenci B, Dikicier E, Cakmak G, Kivilcim T, Akbulut G, Dilek ON, Gunduz Y. CT findings of patients with small bowel obstruction due to bezoar: a descriptive study. *Sci World J* 2013;2013:298392.
- [3] Maharaj N, Naidoo P, Naidu V, Maharajh J. Gastric trichobezoar: food for thought. *S Afr J Radiol* 2013;17(1):19–20.