



# Pediatric food impaction detected through point-of-care ultrasonography

Takaaki Mori, Takateru Ihara, Yusuke Hagiwara

Division of Pediatric Emergency Medicine, Department of Pediatric Emergency and Critical Care Medicine, Tokyo Metropolitan Children's Medical Center, Tokyo, Japan

A previously healthy 1-year-old boy suddenly began coughing while eating a dried sweet potato. Because he continued gagging after vomiting a piece of the dried sweet potato, his mother brought him to our emergency room. Upon arrival, despite normal pulmonary findings, he was drooling and gagging. Ultrasonography was performed because food impaction at the upper esophagus was suspected based on his medical history and physical examination, and results showed that a linear hyperechoic lesion was obstructing the posterior esophageal wall. Computed tomography was also considered for a detailed examination of the foreign body. However, the patient vomited the dried sweet potato before the test was performed. After vomiting the foreign body, the patient stopped gagging, and his ultrasonographic findings were normal. Therefore, the patient was discharged without any complications.

**Keywords** Ultrasonography; Foreign bodies; Child

Received: 10 May 2017

Revised: 31 May 2017

Accepted: 9 June 2017

**Correspondence to:** Takaaki Mori  
Division of Pediatric Emergency  
Medicine, Department of Pediatric  
Emergency and Critical Care Medicine,  
Tokyo Metropolitan Children's Medical  
Center, 2-8-29, Musashidai, Fuchu-shi,  
Tokyo 183-8561, Japan  
E-mail: frf\_03\_underworld@hotmail.  
com



**How to cite this article:**

Mori T, Ihara T, Hagiwara Y. Pediatric food impaction detected through point-of-care ultrasonography. Clin Exp Emerg Med 2018;5(2):135-137.

This is an Open Access article distributed under the terms of the Creative Commons Attribution Non-Commercial License (<http://creativecommons.org/licenses/by-nc/4.0/>).

## Capsule Summary

### What is already known

*Esophageal foreign bodies commonly lodge in the upper esophagus. Although esophageal foreign bodies are commonly diagnosed through radiography, the detection of radiolucent foreign objects is still difficult.*

### What is new in the current study

*Point-of-care ultrasound is useful in detecting radiolucent esophageal foreign bodies in pediatric patients.*

## INTRODUCTION

The ingestion of esophageal foreign bodies (EFBs) commonly occurs in the pediatric population. Radiography is a reliable diagnostic tool for these cases because commonly ingested foreign bodies, including coins, toys, and bones, are radiopaque. However, in some cases, children ingest organic matter, such as food, which is radiolucent.<sup>1</sup> A rare case of food impaction diagnosed through point-of-care ultrasonography (POCUS) is discussed in the present study.

## CASE REPORT

A previously healthy 1-year-old boy suddenly began coughing while eating a dried sweet potato. Because he continued gagging after vomiting a piece of the potato, his mother brought him to our emergency room.

Upon physical examination, the patient was alert with a respiratory rate of 36 breaths per minute and a heart rate of 127 beats per minute. His oxygen saturation was 96% on room air, and his body temperature was 36.5°C. Although respiratory distress was ruled out and his pulmonary examination was normal, he was drooling and gagging.

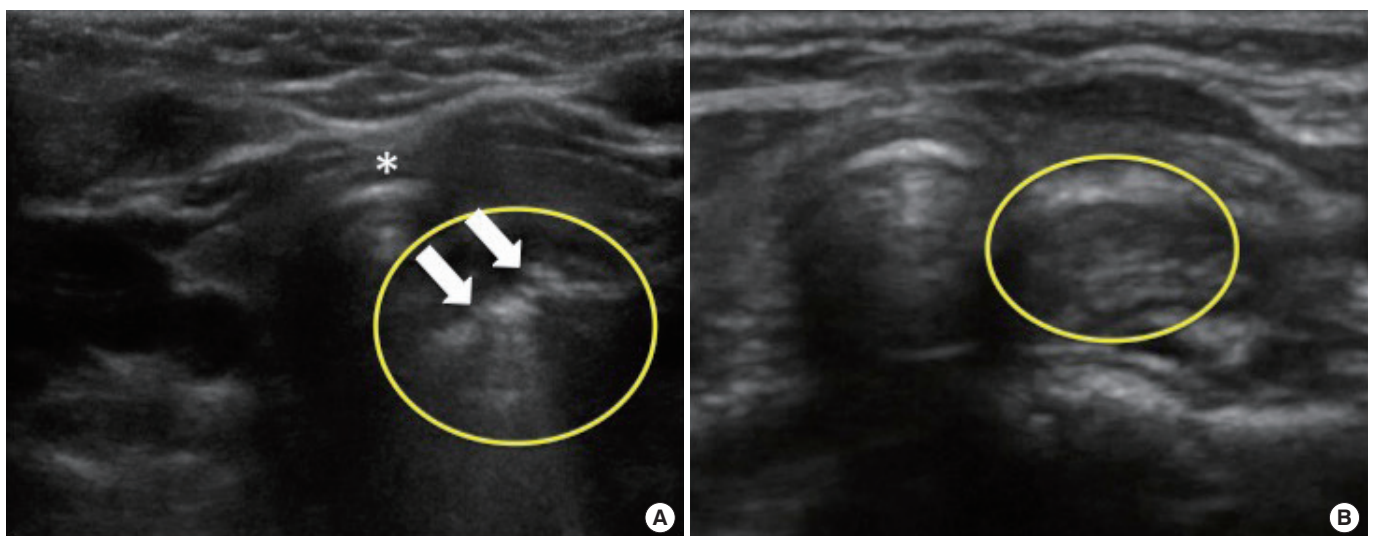
Based on his medical history and physical examination, food impaction at the upper esophagus was suspected. POCUS was performed to detect the ingested foreign body, and it was carried out by placing a linear transducer transversally on the anterior neck and then scanning the thyroid cartilage at the suprasternal

notch. Results showed that a linear hyperechoic lesion was obstructing the posterior esophageal wall. The lesion did not move during swallowing (Fig. 1A). Therefore, computed tomography (CT) scanning was considered for a detailed examination of the foreign body prior to emergency removal because plain radiography was not capable of visualizing organic matter. However, the patient vomited the object before CT was performed.

After the object was removed, the patient stopped gagging, and the ultrasonographic findings were normal (Fig. 1B). Thus, the patient was discharged without any complications. Prior to leaving the hospital, his parents were educated on injury prevention.

## DISCUSSION

EFBs lodge primarily in any of these three sites, including the esophageal orifice, aortic arch, and lower esophageal sphincter, all of which are characterized by a structural narrowing of the esophageal lumen. However, most foreign bodies obstruct the esophageal orifice.<sup>2</sup> Although coins, batteries, and similar objects are considered as common foreign bodies, the ingestion of other X-ray permeable objects, such as food and plastic items, is also common. CT is a sensitive modality for identifying EFBs. However, this test should be the last resort to avoid radiation exposure, which may enhance the patient's lifetime risk for malignancies.<sup>3</sup> POCUS is a simple, non-invasive technique that does not use radiation and can detect even permeable objects. Moreover, it is an effective modality for detecting EFBs, particularly radiolucent objects,



**Fig. 1.** Transverse views of the anterior neck superior to the sternal notch in a 1-year-old boy who ingested a dried sweet potato. (A) A linear hyperechoic lesion on the posterior esophageal wall is seen (arrows) to the right of the trachea (asterisk). (B) After the patient vomited the impacted food, test results were normal. The esophagus had a round appearance, and a clear posterior esophageal wall was also observed (circular).

although the impaction site needs to be considered.

The management of EFBs depends on the location of impaction, object size, its composition, and the patient's condition.<sup>4</sup> In cases of esophageal food impaction, emergency endoscopic removal of the object is needed if the patient is symptomatic or shows signs of esophageal obstruction, such as drooling.<sup>4</sup> Endoscopic removal is a safe and effective method for treating esophageal food impaction, although the patient's airway should be secured prior to the procedure.<sup>5</sup> Katsinelos et al.<sup>6</sup> showed that the success rate of endoscopic retrieval in 139 patients with a foreign body obstructed at the upper gastrointestinal tract was 98.6%, and no procedure-related complications were recognized. In the present case, emergency endoscopic removal was indicated due to the patient's symptoms, which suggested an esophageal obstruction. Fortunately, the patient vomited the foreign body before the procedure. Although a bougie dilator can be used to advance a foreign object into the stomach as an alternative to endoscopic removal, it is not recommended for esophageal food impaction due to the risk of esophageal perforation.<sup>4,5</sup>

Reports on the use of POCUS for this purpose are extremely limited. However, Salmon and Doniger<sup>7</sup> successfully used POCUS to detect a foreign body at the first narrowing of the esophagus in a child who was asymptomatic upon hospital arrival. Moreover, Singleton et al.<sup>8</sup> published a case series on the successful detection of food impaction in adults, and Simone et al.<sup>9</sup> reported numerous pediatric cases. Although further studies are needed to fully assess its efficacy, this technique may be effective in diagnosing EFBs, particularly radiopaque objects, while avoiding radiation exposure.

## CONFLICT OF INTEREST

No potential conflict of interest relevant to this article was reported.

## ACKNOWLEDGMENTS

The authors would like to thank James R. Valera for his help in editing this manuscript.

## REFERENCES

1. Shivakumar AM, Naik AS, Prashanth KB, Yogesh BS, Hongal GF. Foreign body in upper digestive tract. *Indian J Pediatr* 2004; 71:689-93.
2. Athanassiadi K, Gerazounis M, Metaxas E, Kalantzi N. Management of esophageal foreign bodies: a retrospective review of 400 cases. *Eur J Cardiothorac Surg* 2002;21:653-6.
3. Pearce MS, Salotti JA, Little MP, et al. Radiation exposure from CT scans in childhood and subsequent risk of leukaemia and brain tumours: a retrospective cohort study. *Lancet* 2012;380: 499-505.
4. Kramer RE, Lerner DG, Lin T, et al. Management of ingested foreign bodies in children: a clinical report of the NASPGHAN Endoscopy Committee. *J Pediatr Gastroenterol Nutr* 2015;60: 562-74.
5. ASGE Standards of Practice Committee, Ikenberry SO, Jue TL, et al. Management of ingested foreign bodies and food impactions. *Gastrointest Endosc* 2011;73:1085-91.
6. Katsinelos P, Kountouras J, Paroutoglou G, Zavos C, Mimidis K, Chatzimavroudis G. Endoscopic techniques and management of foreign body ingestion and food bolus impaction in the upper gastrointestinal tract: a retrospective analysis of 139 cases. *J Clin Gastroenterol* 2006;40:784-9.
7. Salmon M, Doniger SJ. Ingested foreign bodies: a case series demonstrating a novel application of point-of-care ultrasonography in children. *Pediatr Emerg Care* 2013;29:870-3.
8. Singleton J, Schafer JM, Hinson JS, Kane EM, Wright S, Hoffmann B. Bedside sonography for the diagnosis of esophageal food impaction. *Am J Emerg Med* 2017;35:720-4.
9. Simone LA, Orsborn J, Berant R, Tessaro MO. Point-of-care ultrasonography in the detection of pediatric esophageal food impaction. *Am J Emerg Med* 2016;34:763.