


# Trichoscopic Features of Scalp Discoid Lupus Erythematosus versus Lichen Planopilaris: A Systematic Review

Shreya K Gowda<sup>1</sup>, Enzo Errichetti<sup>2</sup>, Vishal Thakur<sup>1</sup>, Maitreyee Panda<sup>3</sup>, Siddhartha Dash<sup>4</sup>, Akash Agarwal<sup>3</sup>, Madhusmita Sethy<sup>5</sup>, Pavithra Ayyanar<sup>5</sup>, Biswanath Behera<sup>1</sup>

<sup>1</sup>Department of Dermatology and Venereology, All India Institute of Medical Sciences, Bhubaneswar, OD, India; <sup>2</sup>Institute of Dermatology, Department of Medicine, University of Udine, Udine, Italy; <sup>3</sup>Department of Dermatology, IMS and SUM Hospital, Bhubaneswar, OD, India; <sup>4</sup>Department of Dermatology, Srirama Chandra Bhanja Medical College and Hospital, Cuttack, OD, India; <sup>5</sup>Department of Pathology, All India Institute of Medical Sciences, Bhubaneswar, OD, India

Correspondence: Biswanath Behera, Department of Dermatology and Venereology, All India Institute of Medical Sciences, Bhubaneswar, 751019, India, Email biswanathbehera61@gmail.com

**Introduction:** Lichen planopilaris (LPP) and discoid lupus erythematosus (DLE) are primary scarring alopecias that pose diagnostic challenges clinically, where trichoscopy features may provide benefit in delineating these two cicatricial alopecia, and also helps in assessing the evolution and therapeutic response. To date, there are few reviews on dermoscopic findings in differentiating these two alopecias.

**Methods:** A systematic literature review was conducted using the PubMed and Google Scholar databases. The search terms included for scalp DLE were ‘lupus’ OR ‘discoid lupus’ OR ‘scalp lupus’ and for scalp LPP were “lichen planopilaris” OR “scalp follicular lichen planus” OR “lichen planus follicularis” and were combined with “dermoscopy” OR “dermatology” OR “videodermoscopy” OR “video dermatology” OR “trichoscopy”. The differences in the prevalence of dermoscopic features in scalp DLE and LPP were calculated using the Chi-square test.

**Results:** Of 52 articles, 36 (17 LPP, 19 DLE) were eligible for quantitative analysis. We found predominant peripilar tubular casts and perifollicular erythema with the presence of arborizing vessels in the vicinity of these changes, indicating early LPP. In contrast, follicular red dots, speckled brown pigmentation, and hair diameter variability indicated active DLE. Shiny white areas were common in both the groups in late stages. The target pattern of distribution of blue-grey dots, milky red areas, and irregular white fibrotic dots were seen in LPP, and pink-white background, follicular plugs, perifollicular and interfollicular scale, rosettes, chrysalides, and red spider on yellow dots were detected in DLE. Features such as yellow dots and blue-grey structureless areas were nonspecific and did not have a major role in differentiating DLE from LPP.

**Conclusion:** This article provides a comprehensive review of the literature and delineates the trichoscopic differences and peculiarities of scalp DLE and LPP, including the correlation of dermoscopic features with histopathological findings.

**Keywords:** scalp discoid lupus erythematosus, lichen planopilaris, trichoscopy, dermoscopy, primary cicatricial alopecia

## Introduction

Scalp alopecias are broadly classified as scarring and nonscarring types. Primary cicatricial alopecia (PCA) results from the destruction of the hair follicle unit (stem cell niche).<sup>1</sup> PCA is further subcategorized based on the inflammatory infiltrate as lymphocytic (discoid lupus erythematosus [DLE], lichen planopilaris [LPP], central centrifugal cicatricial alopecia, pseudopelade of Brocq, and alopecia mucinosa), neutrophilic (acne necrotica, erosive pustular dermatosis, and acne keloidalis nuchae), and mixed infiltrate (dissecting cellulitis of scalp and folliculitis decalvans).<sup>2</sup> Early diagnosis and treatment halt the further progression of disease and permanent scarring, hence improving the patient’s quality of life. Scalp DLE and LPP pose diagnostic dilemmas in routine practice, as both present as grey-blue discolored scarring alopecia patches, and many times, a scalp biopsy is necessary to detect the primary cause. Even though histopathology

(sensitivity of 40%, 70% for LPP, DLE respectively and specificity of 92%, 63% for LPP, DLE respectively) and direct immunofluorescence (sensitivity of 34%, 83% for LPP, DLE respectively, and a specificity of 95%, 93% for LPP, DLE respectively) are considered the important diagnostic, trichoscopy can be utilized to diagnose scalp pathology and as a prognostic tool during follow-up.<sup>3–6</sup>

The most common PCA encountered is LPP.<sup>7</sup> It usually clinically presents as violaceous papules, which are replaced with follicular plugs and scarring. Eventually, it progresses to white smooth atrophic plaques. The earlier changes of violaceous papules are not seen in all cases. The sites of predilection of LPP, apart from the scalp, are axillae, limb flexures, and inguinal folds.<sup>5</sup> Scalp DLE presents as an itchy, erythematous, scaly plaque with follicular plugs in the early active stage. Pigmentary disturbances are seen in the skin of color.<sup>8</sup> Dermoscopy is a non-invasive diagnostic tool with an inbuilt illumination and magnifying system that enables the visualization of deeper structure, pigmentary, and vascular patterns of skin, mucosa, nails, and hair (trichoscopy).<sup>7</sup>

There are currently no documented reports in the literature delineating the distinguishing trichoscopic features between LPP and DLE. This article aims to compare the trichoscopy findings of reported scalp DLE and LPP in terms of frequencies of dermoscopic features of follicular openings, perifollicular pattern, interfollicular areas, vessel pattern, and hair shafts.

## Materials and Methodology

This review included original reports, case series, and case reports on videodermoscopic and hand-held dermoscopic findings describing scalp DLE and LPP, described in standardized dermoscopic terms of any skin type. Frontal fibrosing alopecia and lichen planopilaris involving other areas were excluded from the analysis. The systematic analysis was performed as per PRISMA (“Preferred Reporting Items for Systematic Reviews and Meta Analyses”) guidelines. A detailed search in “PubMed” and “Google Scholar” was performed and all studies published until August 2023 on scalp DLE and LPP fulfilling the inclusion criteria were analyzed. The following search terms were used: “lupus” OR “discoid lupus” OR “scalp lupus” and for scalp LPP, “lichen planopilaris” OR “scalp follicular lichen planus” OR “lichen planus follicularis”. They were combined with “dermoscopy” OR “dermatology” OR “videodermoscopy” OR “video-dermatology” OR “trichoscopy”. Trichoscopic features on scalp DLE and lichen planopilaris were divided into five categories: follicular openings, perifollicular surface, interfollicular pattern, vessel pattern, and hair shafts. The differences in the prevalence of dermoscopic features in scalp DLE and LPP were calculated using the Chi-square test. P values less than 0.05 were considered statistically significant.

## Results

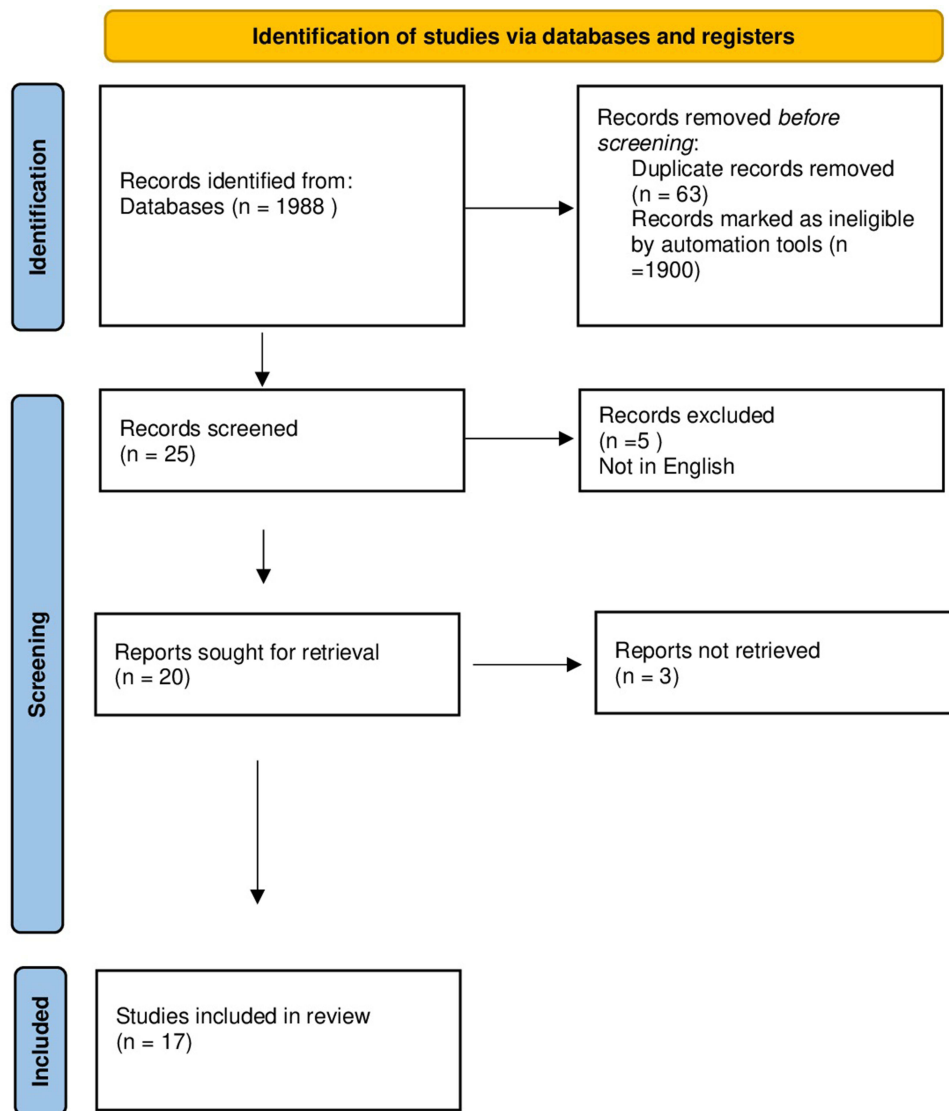
A total of 36 (17 LPP, 19 DLE) articles with full text and English literature were included for further analysis [Figures 1 and 2].<sup>1–59</sup> Table 1 depicts the differentiating features of LPP and scalp DLE.

### Hair Follicular Features

Absent follicular opening was seen in approximately 45 to 50% of the cases included in the analysis. Follicular red dots (Figure 3) were seen exclusively in DLE ( $p < 0.01$ ).<sup>12</sup> White dots can be pinpoint and fibrotic (Figure 4), corresponding to the opening of the eccrine sweat gland and the fibrotic follicular column (Figure 5), respectively.<sup>13</sup> These fibrotic white dots were significantly higher in the LPP group ( $p < 0.01$ ). Yellow dots are follicular orifices filled with keratin and/or sebaceous secretions and were found in both groups. Follicular keratotic plugs (Figure 6) are comprised of keratotic mass filling the follicular orifice, corresponding to infundibular hyperkeratosis and plugging (Figure 7).<sup>14</sup> The plugs were small, white in lichen planopilaris, and large, yellow color in scalp DLE ( $p < 0.01$ ). Loss of follicular openings in the late stage was seen in both groups.

### Perifollicular Features

Perifollicular erythema (Figure 8) was seen predominantly in LPP and scalp DLE; however, this finding was not seen in DLE involving other than the scalp.<sup>15</sup> Perifollicular scales (Figure 6) were significantly higher in DLE than in LPP. Perifollicular tubular casts are cylindrical scales encircling the hair shaft, which is approximately 3 mm in length, and

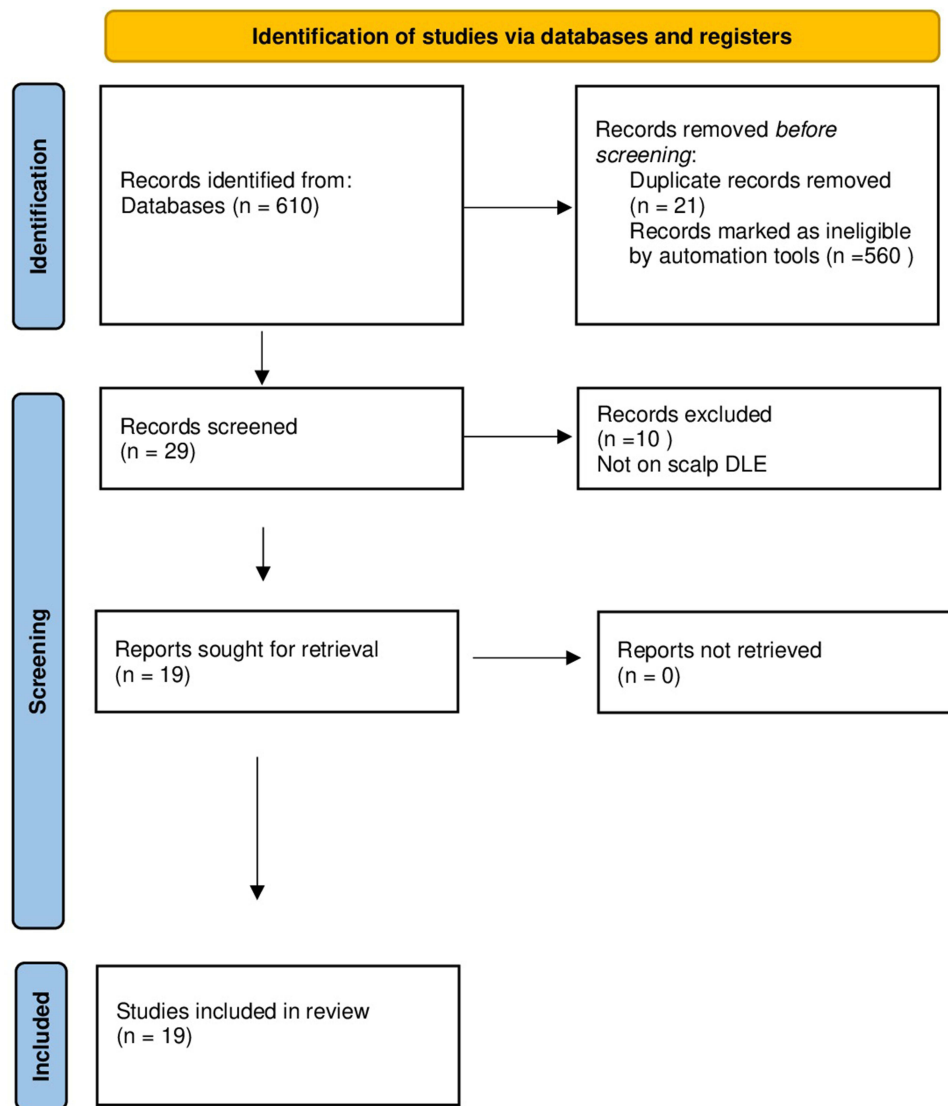


**Figure 1** PRISMA 2020 flowchart for lichen planopilaris.

were seen in LPP predominantly ( $p < 0.01$ ).<sup>16</sup> Perifollicular blue-grey dots were seen in both LPP and scalp DLE, but the characteristic “target pattern” (Figure 9) of distribution of the dots was seen in LPP due to characteristic interface changes and melanin incontinence around the hair follicle (Figure 10) ( $p < 0.01$ ). Perifollicular gray to blue-gray structureless areas were seen in both groups.

## Interfollicular Areas

In this study, pigmentation patterns identified were honeycomb and speckled brown pigmentation, which correspond to melanin deposits in epidermal ridges and melanophages, respectively, and these findings were seen in DLE. The optical phenomenon of polarization in the follicular and perifollicular structures, which leads to white rosettes (Figure 11), was seen significantly in scalp DLE ( $p < 0.01$ ).<sup>18</sup> The background was pink-white ( $p < 0.01$ ) and milky white ( $p = 0.02$ ) in scalp DLE and LPP, respectively. Chrysalides are shiny white lines that correlate with stromal fibrosis and were seen in longstanding DLE ( $p < 0.01$ ).<sup>19</sup> Interfollicular structureless white areas were seen in both groups, which correlates with epidermal acanthosis and dermal fibrosis in scarring alopecias. Interfollicular white scales and yellow scales ( $p < 0.01$ ) and interfollicular erythema were seen significantly in scalp DLE ( $p < 0.01$ ). Interfollicular scattered blue-grey dots, brown globules, red globules, and blue



**Figure 2** PRISMA 2020 flowchart for scalp discoid lupus erythematosus.

structureless areas were seen significantly in LPP (Figure 7). Scattered blue-grey dots in the interfollicular area were seen in LPP ( $p < 0.01$ ). Erosions and ulcerations were described only in one case of scalp DLE.<sup>20</sup>

## Blood Vessel Patterns

Six morphologies of blood vessels were found on trichoscopy of scalp DLE and LPP: arborizing, dotted, comma-shaped, linear, hairpin, and polymorphous vessels (Figure 12). Vasculature was more prominent in scalp DLE than LPP. Thin arborizing vessels around the large yellow dot are termed as a red spider (Figure 8) in the yellow dot, which is a highly specific finding of DLE ( $p = 0.02$ ), and this is not seen in skin of color due to masking of cutaneous vasculature. Dotted and hairpin vessels were seen to be significantly higher in scalp DLE ( $p < 0.01$ ).<sup>20</sup>

## Hair Shaft Features

Black dots result from the breakage of the hair shaft at emergence from the scalp.<sup>19</sup> Black dots were exclusively seen in DLE. In a study, hair diameter variability was seen predominantly in scalp DLE ( $p < 0.01$ ) at the periphery of the alopecia patch.<sup>21</sup> Hair tufting (Figure 10) is defined as tufts of more than six hair shafts originating from the single follicular orifice.<sup>22</sup> The emergence of two to three hair shafts from follicular opening was seen in LPP ( $p < 0.01$ ). “Lonely hair

**Table 1** Trichoscopic Features of Discoid Lupus Erythematosus and Lichen Planopilaris

Trichoscopic Features	LPP Scalp N=279 (%)	DLE Scalp N=166 (%)	P value
<b>Follicular features</b>			
Follicular plugs	11 (3.94)	78 (46.98)	<0.01
Red dots	0 (0.0)	22 (13.25)	<0.01
Fibrotic white dots	189 (67.75)	56 (33.73)	<0.01
Absence of follicular openings	159 (56.98)	76 (45.78)	0.19
Dilated follicles	1 (0.35)	0 (0.0)	0.44
Yellow dots	50 (17.92)	35 (21.08)	0.50
<b>Perifollicular features</b>			
Target sign	73 (26.16)	0 (0.0)	<0.01
Perifollicular scales	14 (5.08)	73 (43.97)	<0.01
Perifollicular tubular cast	60 (21.50)	2 (1.20)	<0.01
Perifollicular erythema	119 (42.65)	23 (13.85)	<0.01
Perifollicular blue-grey dots/globules	26 (9.31)	20 (12.05)	0.36
Perifollicular gray to blue-gray structureless area	4 (1.43)	6 (3.60)	0.14
<b>Interfollicular features</b>			
Chrysalides	0 (0.0)	18 (10.84)	<0.01
White rosettes	0 (0.0)	18 (10.84)	<0.01
Scales	0 (0.0)	90 (54.21)	<0.01
Yellow scales	0 (0.0)	35 (21.08)	<0.01
White scales	0(0.0)	90 (54.21)	<0.01
Interfollicular erythema	9 (33.34)	16 (9.63)	<0.01
Speckled brown pigmentation	0 (0.0)	63 (37.95)	<0.01
Pink-white background	0 (0.0)	67 (40.36)	<0.01
Honeycomb pigment pattern	17 (6.09)	24 (14.45)	<0.01
Epidermal atrophy	5 (1.79)	22 (13.25)	<0.01
Interfollicular brown globules	21 (7.52)	1 (0.60)	<0.01
White perifollicular halo	0 (0.0)	2 (1.20)	0.29
Crust formation	0 (0.0)	3 (1.80)	0.12
Blue-white veil	3 (1.07)	2 (1.20)	0.99
Red globules	10 (3.58)	1 (0.60)	0.05
Erosions/ulcerations	0 (0.0)	1 (0.60)	0.71
White structureless areas	118 (42.29)	103 (62.04)	0.02
Milky white areas	13 (49.46)	0 (0.0)	0.02

(Continued)

**Table 1** (Continued).

<b>Trichoscopic Features</b>	<b>LPP Scalp N=279 (%)</b>	<b>DLE Scalp N=166 (%)</b>	<b>P value</b>
Bluish deep discoloration	14 (5.01)	3 (1.80)	0.98
Splinter hemorrhage	0 (0.0)	4 (2.40)	0.02
<b>Vasculature</b>			
Dotted	7 (2.50)	14 (8.43)	<0.01
Hairpin vessels	2 (0.71)	11 (6.62)	<0.01
Arborizing	110 (39.42)	96 (57.83)	0.02
Linear	2 (0.71)	5 (3.00)	0.06
Comma	0 (0.0)	3 (1.80)	0.05
Polymorphous	0 (0.0)	1 (0.60)	0.29
<b>Hair shaft features</b>			
Hair diameter variability	0 (0.0)	11 (6.62)	<0.01
Pili Torti	0 (0.0)	5 (3.00)	<0.01
Black dots	0 (0.0)	29 (17.46)	<0.01
Regrowing hairs	22 (7.88)	0 (0.0)	<0.01
Tapered hairs	21 (7.52)	0 (0.0)	<0.01
Proximal hair emergence	40 (14.35)	0 (0.0)	<0.01
Broken hairs	5 (1.7)	10 (12.00)	0.02
Lonely hair sign	1 (0.35)	0 (0.0)	0.44
Tufting	11 (3.94)	0 (0.0)	0.01
Loss of Vellus hair	4 (1.43)	2 (1.20)	0.84
Circular pigtail hairs	16 (5.73)	5 (3.00)	0.20
Pustules	1 (0.35)	0 (0.0)	0.44
Vellus hairs	22 (7.88)	13 (7.83)	0.98

**Notes:** The bold words represent the broad subheading for the analysis of trichoscopic features.

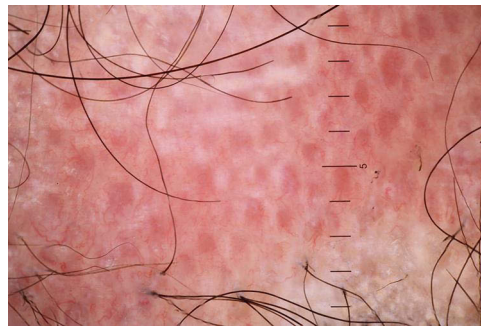
**Abbreviations:** LPP, lichen planopilaris; DLE, discoid lupus erythematosus.

sign”, an isolated single hair in the frontal area, was seen in LPP (Figure 13). Pili torti was seen in scalp DLE ( $p < 0.01$ ).<sup>16</sup> Regrowing hairs (Figure 14) and tapered hairs were seen significantly in LPP ( $p < 0.01$ ).

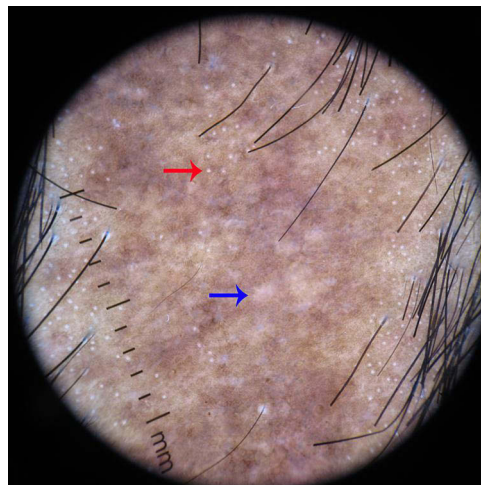
Table 2 and Table 3 summarize the findings of LPP and scalp DLE described in various studies.

## Discussion

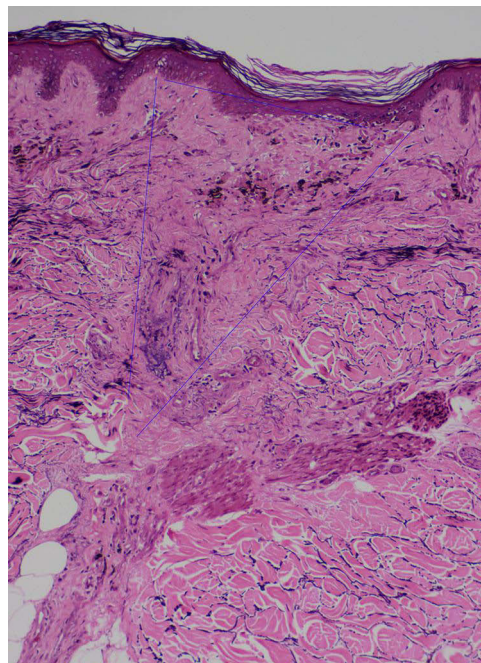
Trichoscopy is a non-invasive diagnostic tool for unveiling the diagnosis of different scarring alopecias, although histopathology with DIF is considered the standard tool in diagnosing PCA. Among the PCA, scalp DLE, and LPP create a diagnostic dilemma in daily practice. Our review focuses on the key features that help distinguish these two scalp pathologies and may avoid invasive tests.



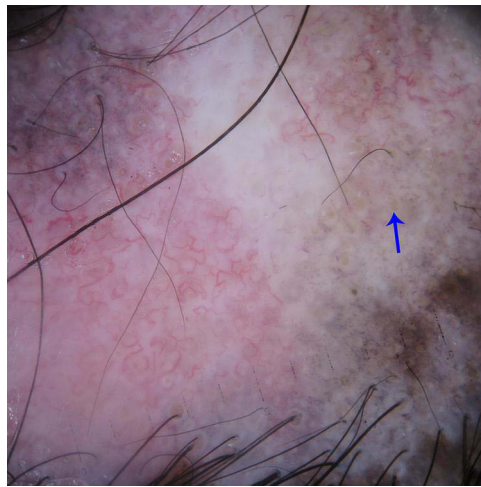
**Figure 3** Trichoscopy of scalp discoid lupus erythematosus shows follicular red dots, interfollicular pink-white structureless area, and polymorphous vessels.



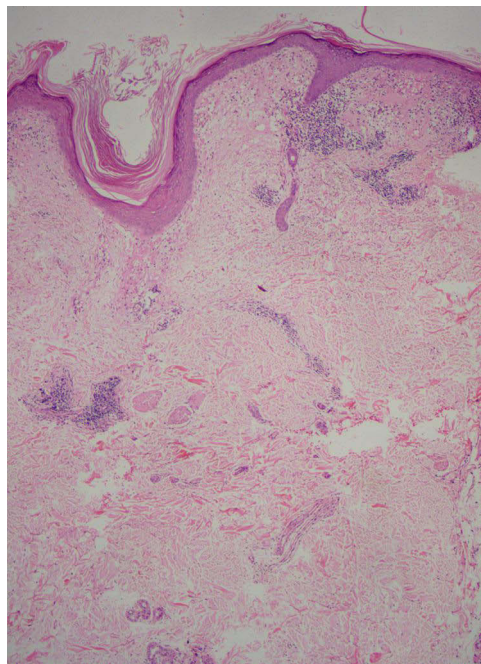
**Figure 4** Trichoscopy of lichen planopilaris shows fibrotic white dots (blue arrow) and pinpoint white dots (red arrow).



**Figure 5** Histopathology of lichen planopilaris shows wedge-shaped perifollicular fibrosis with loss of elastic fibers (blue triangle) corresponding to the white fibrotic dots (VVG, X100).



**Figure 6** Trichoscopy of scalp discoid lupus erythematosus shows yellow follicular plugs (blue arrow), perifollicular and interfollicular blue-gray dots, and arborizing vessels. Note the hair diameter variability at the lower part of the image.

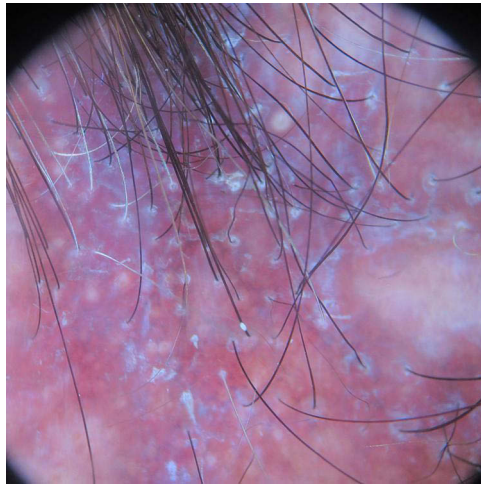


**Figure 7** Histopathology of scalp discoid lupus erythematosus shows follicular dilatation, plugging, and perifollicular and interfollicular dilated vessels (H & E, X50).

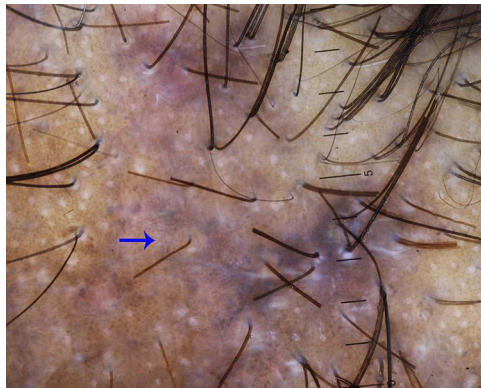
## Follicular and Perifollicular Features

Although the absence of follicular opening is considered characteristic of cicatricial alopecia, this finding is not appreciated in the early lesions of DLE or LPP. As per the analysis, it was seen in around 45% to 50% of the cases in both groups. In the early stages of the disease, the follicular opening may be intact, even in the scarring type. Follicular keratotic plugs correlate with the hyperkeratosis and plugging of the follicular ostia with keratotic material on histology. They were initially attributed as a sign of early and active DLE. However, these findings were recorded in even later stages.<sup>24</sup> Fibrotic white dots are irregularly blurred round structures that tend to merge, which later progress to form white structureless areas. Fibrotic white dots correspond to fibrotic tracts arranged vertically in histopathology.<sup>25</sup> Fibrotic white dots must be differentiated from pinpoint white dots, which are regularly spaced sharply demarcated small dots with a peripheral hyperpigmented halo. These pinpoint white dots correspond to eccrine duct openings or follicular

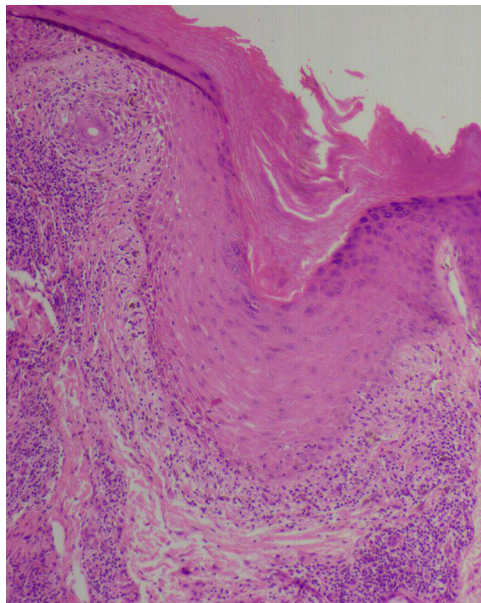




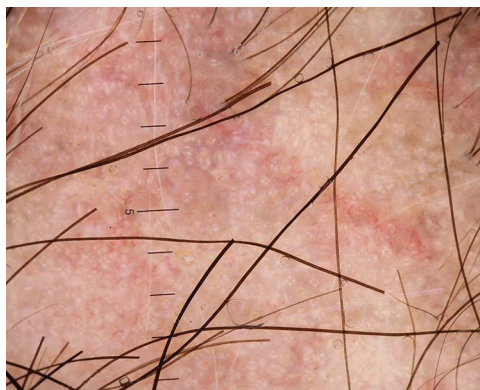
**Figure 8** Trichoscopy of lichen planopilaris shows perifollicular scales and perifollicular and interfollicular erythema.



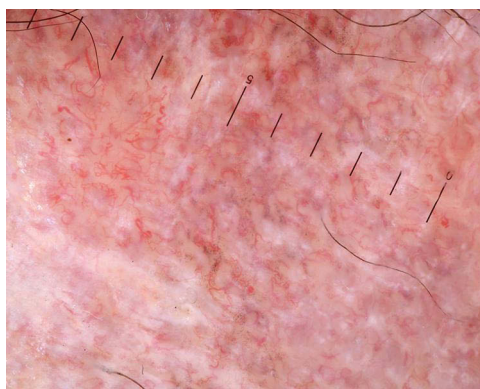
**Figure 9** Trichoscopy of lichen planopilaris shows target sign (blue arrow).



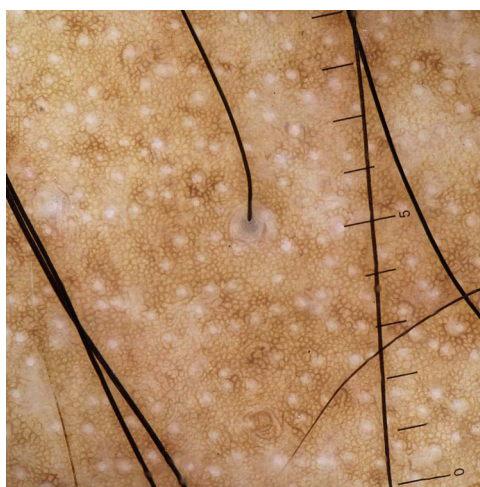**Figure 10** Histopathology of scalp discoid lupus erythematosus shows periinfundibular pigment incontinence corresponding to the perifollicular blue-gray dots (H & E, X100).



**Figure 11** Trichoscopy of scalp discoid lupus erythematosus shows rosette and shiny-white lines.

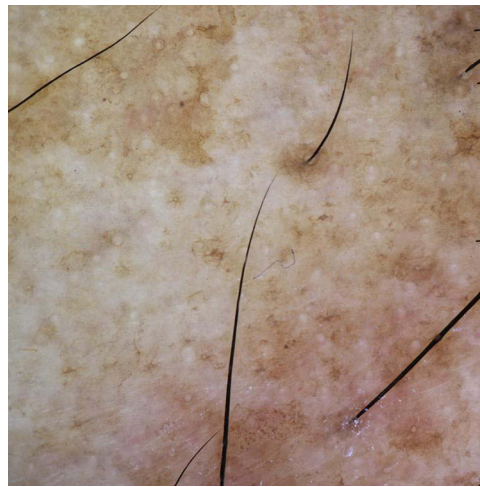


**Figure 12** Trichoscopy of scalp discoid lupus erythematosus shows polymorphous vessels.



**Figure 13** Trichoscopy of lichen planopilaris shows lonely hair sign.

openings.<sup>26</sup> Yellow dots are better visualized in polarized mode reflection and correlate with the follicular ostia filled with sebaceous secretions.<sup>27</sup> Follicular red dots are erythematous polycyclic structures seen around the hair follicle, which correlate with dilated follicular openings with perifollicular vasculature and extravasated erythrocytes on histopathology and were only found in DLE. Yellow dots in scalp DLE were reported to be large, and thin arborizing vessels were



**Figure 14** Trichoscopy of lichen planopilaris shows regrowing vellus hair.

described at the periphery of yellow dots, which was specific for inactive longstanding DLE and termed as “red spider on a yellow dots”. This finding was not visible in skin of color.<sup>20</sup>

Perifollicular white and yellow scales were significantly noted in DLE. Scales of LPP are usually adherent and encircle the hair shafts and later tend to climb along the proximal portion of hair shafts, referred to as a “perifollicular tubular cast”. These are better appreciated in polarized mode and were thought to be specific to LPP but later were described in pemphigus foliaceus, folliculitis decalvans, and scalp DLE. Peripilar cast corresponds to perifollicular hyperkeratosis on histopathology.<sup>17</sup> In LPP, interface dermatitis in a shaped manner limited to follicular area sparing interfollicular areas on histopathology leads to a target pattern of blue-gray dots on trichoscopy and helps discriminate it from scalp DLE.

## Interfollicular Features

The pink-white background was seen significantly in scalp DLE, which corresponds to partial fibrosis and inflammatory infiltration. The blue-white veil is characterized by central white areas and peripheral irregular patches of blue-brown pigment

**Table 2** The Summary of Studies on Trichoscopy of Lichen Planopilaris

Author	Study Design	Study Participants	Dermoscopy Results	Other Findings	Level of Evidence
Lajevardi et al <sup>32</sup> 2019	Cross-sectional study	Histopathological confirmed LPP patients (117)	Follicular pattern: Loss of follicular opening 111(95%) Perifollicular: Perifollicular erythema 70(60%), Perifollicular scale 102(88%), Perifollicular vessel 69(59%), Targetoid pigmentation 72(62%), Scattered pigmentation 94(80%) Interfollicular: Big irregular white areas 110(94%), Milky-red areas 110(94%) Hair shaft: Shaft deformities 43(37%), broken hairs 41(35%), loss of Vellus hair 36 (31%), tuft of 4 hairs and more 26 (22%), circular pigtail hairs 12(10%), pustules 6(5%), yellow dots 5(4%)	Targetoid pigment pattern, perifollicular scale, and milky-red areas were significantly correlated with LPP activity index (P-value < 0.05) and positive anagen pull test (P value < 0.001).	III

(Continued)

Table 2 (Continued).

Author	Study Design	Study Participants	Dermscopy Results	Other Findings	Level of Evidence
Eftekhari et al <sup>33</sup> 2019	Prospective observational study	44 patients with a definite diagnosis of LPP	Follicular pattern: Small yellow dots 6(13%), Large yellow dots 8(18%), White dots fibrotic 7(15%), White dots pinpoint 34(77%) Perifolliculars: Tubular scales 20(45%) Interfollicular: Peripilar sign yellowish brown 6 (13%), honeycombing 13(29%), black-blue peripilar pigment 23 (52%) Vascular pattern: Dilated lesional telangiectatic vessels 26(59%), pinpoint red dots 7 (16%), perilesional thick vessels 11 (25%), Red blotches 5(11%) Hair shaft: Vellus hair 22(50%), coiled twisted hairs 14(31%), regrowing hairs 22 (50%), tufting 7(16%)	About 33(75%) of patients had shaft disorders. 35(77%) of patients had at least one form of the follicular opening disorder. The most common pattern of pigmentation was milky-red 43 (97%). The irregular and ectatic vascular network were seen in 26 (59%) of patients. Patients with coiled and twisted hairs, small yellow dots, large yellow dots, and peripilar sign were more likely to have shorter disease duration (P <0.05). Those with overall shaft disorders were younger (P = 0.02). Small yellow dots (P = 0.025) and peripilar sign (P = 0.039) were more common in female patients. Patients with coiled and twisted hairs (mean duration SD=12.00 15.27, P=0.015)	II
Estrada et al <sup>34</sup> 2010	cross-sectional study	14 patients Four patients with classic LPP, five with FFA	LPP trichoscopy revealed Follicular: Reduction in follicular ostia 4(100%) Perifollicular: perifollicular scales 4(100%) Interfollicular: pigment network 2(50%), white patch 2(50%), white dots 3(75%), blue grey dots 1(25%)	FFA dermoscopy showed perifollicular scales 3(60%), perifollicular erythema 3(60%), branching capillaries 3(60%), pigment network 2(40%), white patch 1(20%), white dots 2(40%), vellus hairs 1(20%), and reduction in follicular ostia 4(80%)	III
Olga Warszawik et al <sup>1</sup> 2012	Prospective study	Total primary 84 cicatricial alopecia (20—DLE, 28—LPP, 19—FFA 8—dissecting cellulitis and 9—Folliculitis decalvans)	Trichoscopy of LPP revealed Perifollicular: The silver-white tubular structure around the emerging hair shafts, usually reaching about 1mm to 3 mm above the scalp surface 28 (100%) Interfollicular: white dots 28(100%), bluish deep discoloration 15(53%) white and milky-red areas lacking follicular openings 28(100%) Vasculature: Elongated vascular loops 15(53%) located in close proximity to hair shaft openings.	Perifollicular scaling (78.9%), white dots (5.2%), and follicular red dots (31.6%) were noted in dermoscopy of FFA.	II

(Continued)

Table 2 (Continued).

Author	Study Design	Study Participants	Dermoscopy Results	Other Findings	Level of Evidence
Panchaprateep et al <sup>36</sup> 2020	Retro-prospective cohort	58 patients of LPP	Follicular: Lack of follicular ostia 53(91%), Perifollicular: perifollicular scales 46(79%), perifollicular erythema 37(63.8%) Interfollicular: brownish hyperpigmentation 19(32%) Hair shafts: transparent proximal hair emergence 40(69%) Vasculature: telangiectasia 13(22%)		III
Thakur et al <sup>37</sup> 2015	Retrospective	5 cases of lichen planopilaris 2 cases of pseudopelade of Brocq, folliculitis decalvans, and frontal fibrosing alopecia. 10 patients with scalp DLE	Trichoscopy of LPP showed Follicular: absent follicular opening 5(100%), Perifollicular: peripilar cast 5(100%), perifollicular erythema 3(60%), perifollicular scales 5(100%), Interfollicular: Epidermal atrophy 5(100%), cicatricial white patch 5(100%), scattered brown discoloration 2(40%), Vasculature: Elongated linear blood vessels 2(40%)		III
Rossi et al <sup>48</sup> 2013	Retrospective study	48 FFA 86 LPP	Dermoscopy of LPP revealed involvement of total preterminal, terminal and vellus-like follicles, a partial or total loss of follicular openings, diffuse hair thinning, perifollicular blue-gray dots, with white structureless areas corresponding to scalp sclerosis	Dermoscopy of FFA revealed white structureless areas, corresponding to skin atrophy, a total loss of the follicular openings with an exclusive involvement of vellus-like hair follicles, mostly located on the frontoparietal region, but also on the temples and the hairline occipital region	III
Abhijeet et al <sup>48</sup> 2018	Retrospective observational study	6 LPP, 6DLE, 6 pseudopelade of Brocq	Follicular: Decreased follicular ostia 6(100%) Perifollicular: Perifollicular scaling 6(100%), perifollicular erythema 6(100%) Interfollicular: White dots 6(100%), blue grey dots 3(50%), white structureless area 3(50%), blue-white veils 3(50%)		III
Woo-Haing et al <sup>43</sup> 2014	Cross-sectional	alopecia areata (n=81), trichotillomania (n=24), tinea capitis (n=13), traction alopecia (n=12), lichen planopilaris (n= 8), discoid lupus erythematosus (n=7), congenital triangular alopecia (n=2) and pseudopelade of Brocq (n=1).	Follicular: Reduced follicular ostia 8(100%) Perifollicular: Perifollicular hyperkeratosis 7(88%) Perifollicular erythema 7(88%) Interfollicular: Pigment network 3(38%) Vasculature: Atypical red vessels 5(63%) Hair shafts: Black dots 1(13%)		III

(Continued)

Table 2 (Continued).

Author	Study Design	Study Participants	Dermscopy Results	Other Findings	Level of Evidence
Arshdeep et al <sup>39</sup> 2018	Case series	4 cases involving Scalp (all), face (1) forearm (2), and back (2) Trichoscopy was done in two cases.	Case 1 trichoscopy revealed showed multiple discrete peripilar casts. A dermoscopy of the trunk revealed the overall absence of follicular openings and residual body hair with no appreciable peripilar casts, suggestive of "burnt-out" disease. Case 2: Dermoscopy of scalp showed blue-gray dots in targetoid pattern, discrete peripilar casts, and white patches of scarring alopecia	Case 3: Dermoscopy of the right cheek with facial papules (lichen planus) showed partial loss of vellus hairs in patients of LPP with LP Case 4: Dermoscopy of follicular plugs on the back in the patient of LPP showed discrete peripilar casts and gray-brown dots (peppering) around the follicular ostia with broken hairs.	IV
Ankad et al <sup>40</sup> 2013	Case report	2 patient I LPP I DLE	LPP: Trichoscopy showed perifollicular scales (black stars), diminished follicular ostia and white dots (red stars). Blue-grey dots (yellow arrows) around the follicular structures ["target" pattern]	DLE: Trichoscopy showed branching capillaries (yellow diamond), white patches (yellow star), keratin plugs (red arrow), reduced follicular ostia and white dots (red stars). Blue-grey dots (yellow arrow) inside the patch of alopecia labeled as "speckles" pattern	V
Friedman et al <sup>41</sup> 2015	Case report	I LPP	Trichoscopy revealed multiple irregular cicatricial alopecic areas with perifollicular whitish-gray scaling associated with erythema, arboriform vessels, absence of follicular openings, and follicular plugging		V
Góes et al <sup>44</sup> 2017	Case report	LPP	Trichoscopy evidenced erythema and perifollicular scaling on the plaques' periphery. Central areas were slightly erythematous, shiny, and did not exhibit scaling, with an absence of follicular ostia – aspect compatible with scarring alopecia with a predilection for hair follicles		V
Batra et al <sup>46</sup> 2020	Case reports	2 cases of LPP	Trichoscopy showed elimination of hyperkeratosis and evidence of inflammation on the frontal hairline		V
Kaliyadan et al <sup>47</sup> 2015	Case report		The violaceous pattern over the normal pseudo-network of the region associated whitish striations (corresponding to Wickham's striae) and prominent pigment clumps (corresponding to the dermal melanophages)		V
Andziukeviciute et al <sup>49</sup> 2016	Case report		Trichoscopy showed zones of extinct hair follicles, follicular hyperkeratosis and erythema		V

**Abbreviations:** LPP, lichen planopilaris; DLE, scalp discoid lupus erythematosus; FFA, frontal fibrosing alopecia.

**Table 3** Trichoscopic Studies of Scalp Discoid Lupus Erythematosus Included in the Analysis

Author	Study Design	Study Participants	Dermoscopy Results	Other Findings	Level of Evidence
Żychowska et al <sup>20</sup> 2021	Systematic review	Scalp DLE (n=166), Non-scalp DLE (n=129)	In scalp DLE (n = 166), the trichoscopy findings were: Follicular: Follicular keratotic plugs 78(47%), absence of follicular openings 74(45%), fibrotic white dots 55(33%), yellow dots 35(21%), black dots 28(17%), red dots 21(13%), reduced follicular ostia 20(12%) Perifollicular: Perifollicular scaling 71(43%), perifollicular erythema 21(13%), perifollicular pigmentation 50(3%), tubular hair casts 2(1%), white perifollicular halo 2(1%) Interfollicular: White structureless areas 102(62%), white scales 89(54%) pink-white background 66(40%), speckled brown pigmentation 63(38%), yellowish scales 35(21%), honeycomb pigment pattern 23(14%), epidermal atrophy 21(13%), blue-grey dots/globules 20(12%), chrysalides 17(10%), white rosettes 17(10%), background erythema 15(9%), splinter hemorrhage 3(2%), bluish deep discoloration 2(1%), crust formation 2(1%), blue-white veil 2(1%), red globules 1(0.6%), brown globules 1(0.6%), erosions/ulcerations 1(0.6%) Vascular pattern: Arborizing vessels 95(57%), dotted vessels 13(8%), hairpin vessels 9(6%), linear vessels 5(3%), coiled vessels 2(1%), polymorphous vessels 1(0.6%)	In non-scalp DLE, the dermoscopy showed (n=129), Follicular keratotic plugs 86(66%), white perifollicular halo 85(65%), white scale 51(39%), speckled brown pigmentation 50(38%), white structureless areas 48(37%), and arborizing vessels 45(34%).	I
Melo et al <sup>50</sup> 2020	Observational and cross-sectional study	12 patients of scalp DLE	Trichoscopy of scalp DLE showed Yellow dots 12(100%), thick arborizing vessels 12(100%), scattered dark-brown skin discoloration 12(100%), and structureless white areas 12(100%).	Consistent correlation between reflectance confocal microscopy and histopathology in the diagnosis of scalp DLE	III

(Continued)

Table 3 (Continued).

Author	Study Design	Study Participants	Dermoscopy Results	Other Findings	Level of Evidence
Nikam et al <sup>52</sup> 2014	Nonrandomized, single-arm observational study	17 scalp alopecia Scalp DLE- 5 LPP- 4 PPB- 3 Systemic lupus erythematosus- 5	Polarized dermoscopy of scalp DLE: Follicular: Yellow dots 3(60%), black dots 1(20%), perifollicular pigmentation 4(80%), follicular hyperkeratosis 2(40%), and loss of follicular ostia 5(100%). Inter follicular: White dots 3(60%), blotchy pigmentation 2(40%), honeycomb pigmentation 4(80%), flakes scale 3(60%), red lines 4(80%), and red dots 5(100%) Hair: Short vellus hair 2(40%)	Nonpolarized dermoscopy of scalp DLE: Follicular Perifollicular pigmentation 1(20%), follicular hyperkeratosis 1(20%) and loss of follicular ostia 5(100%) Inter follicular: White dots 1(20%), blotchy pigmentation 1(20%), flakes scale 1(20%), red lines 1(20%) and red dots 1(20%) Hair: Short vellus hair 2(40%)	II
Chiramel et al <sup>53</sup> 2016	Cross-sectional study	90 non-cicatrical, 30 cicatricial 9 cases were scalp DLE	Follicular: Loss of follicle openings 8(89%), follicular plugs 4(44%), Perifollicular: peripilar scales 3(33%), peripilar erythema 4(44%), red dots 4(44%), tubular scales 1(11%). Interfollicular: white areas 7(77%), honey comb pigment pattern 3(33%), interfollicular red loops 3(33%), crust formation 2(22%), blue-gray dots 2(22%). Vasculature: arborizing red loops 5(55%) Hair shafts: coiled hairs 1(11%)		III
Karadag Köse et al <sup>54</sup> 2019	Prospective study	7- DLE 27- LPP 17- FD 6- DC of scalp 5- PPB 7- FFA	Follicular: Absence of follicular openings 7(100%), large keratotic yellow dots 3(42%), fibrotic white dots 2(28%). Perifollicular: peripilar cast 1(14%), perifollicular scales 3(42%) Interfollicular: Pink-white appearance 7(100%), honeycomb pattern 1(14%), brown scattered pattern 2(28%), crust formation 1(14%), interfollicular scaling 6(85%) Hair shaft: Absence of vellus hairs 2(28%), short vellus hairs 1(14%), broken hairs 1(14%), and pili torti 1(14%).		III



Estrada et al <sup>13</sup> 2010	Cross-sectional study	14 patients Five cases of DLE, four patients with classic LPP, five with FFA	Trichoscopy of scalp DLE: Follicular: Reduction in the number of follicular ostia 4(80%), keratin plugs 5(100%) Interfollicular: Pigment network 2(40%), white patches 5(100%), white dots 2(40%), blue-grey dots 2(40%) Vasculature: Coiled capillaries 1(20%), branching capillaries 5(100%),		III
Abedini et al <sup>55</sup> 2016	Cross-sectional study	DLE-14 LPP-70 FD- 5 DC- 6 FFA- 5	Trichoscopy of scalp DLE revealed Follicular: Absence of follicular opening 14(100%), follicular keratotic plugging 8(57%), follicular red dot 2(14%), fibrotic white dot 1(7%) Perifollicular: Perifollicular erythema 1(7%), perifollicular scale 13(92%), peripilar white halo 1(7%) Interfollicular: Non-follicular red dots 7(50%), black dot 2(14%), speckled pigmentation 1(7%), honeycomb pigment pattern 7(50%), white patch 11(78%), interfollicular scale 12(85%), scalp erythema 4(28%) and red scalp erythema 4(28%) Vasculature: Tortuous branching vessels 5(35%), enlarged branching vessels 8(57%)		III
Olga Warszawik et al <sup>1</sup> 2012	Prospective study	Total primary 84 cicatricial alopecia (20-DLE, 28-LPP, 19-FFA 8-DC and 9-FD)	Trichoscopy of scalp DLE Follicular: Yellow dots with radial, thin arborizing vessels 7(35%), large yellow dots 11(55%), white dots 1(5%), and follicular red dots 1(5%). Interfollicular: white and milky-red homogenous areas 8(40%), dark-brown scattered discoloration 9(45%), and bluish deep discoloration 3(15%). Vasculature: thick arborizing vasculature 18(90%)	A total of 15 patches were in the active stage, and the trichoscopy showed thick arborizing vessels 15(100%), dark-brown scattered discoloration 7(46%), large yellow dots 14(93%), and follicular red dots 1(6%). A total of 17 patches were in the inactive stage, and the trichoscopy revealed thick arborizing vessels 17(100%), milky-red areas 10(58%), yellow dots with radial, thin arborizing vessels 15(88%), white dots 2(11%), and lack of follicular orifices 17(100%).	II

(Continued)

Table 3 (Continued).

Author	Study Design	Study Participants	Dermoscopy Results	Other Findings	Level of Evidence
Melo et al <sup>56</sup> 2022	Multicentric retrospective study	10 cases of a confirmed diagnosis of lupus erythematosus mimicking alopecia areata	All variants of lupus erythematosus may cause hair loss. Systemic lupus erythematosus produces nonscarring alopecia, whereas DLE at initial presentation nonscarring patches are seen. Patchy alopecia of lupus erythematosus may also mimic alopecia areata, which can co-occur with lupus erythematosus. Trichoscopy of lupus erythematosus revealed. Follicular: white dots 5(50%), red dots 4(40%), dilated follicular ostia 4 (40%), yellow dots 3(30%) Interfollicular: honeycomb pattern 3(30%), and visible scales 1(10%) Hair shafts: thin hair 8(80%), black dots 7(70%), pili torti 3(30%), and circular hair 2(20%) Vasculature: Interfollicular arborizing vessels 9(90%), perifollicular simple red loops 3(30%)		III
Thakur et al <sup>37</sup> 2015	Retrospective study	10 patients with scalp DLE 5 cases of LPP 2 cases of PPB, FD, and FFA	Trichoscopy of DLE Follicular: Yellow dots 7(70%), black dots 2(20%), follicular hyperkeratosis 9(90%), and absent follicular opening 10 (100%). Perifollicular: Perifollicular erythema 10(100%), perifollicular scales 8(80%) Interfollicular: scattered brown discoloration 7(70%), interfollicular scaling 10(100%), epidermal atrophy 10(100%), cicatricial white patch 10(100%), and blue grey dots 2(20%). Vasculature: Thick arborizing blood vessels 8(80%)		III

Mikiel et al <sup>57</sup> 2021	Case-control study	44 adults: 11 with DLE, 8 with classic LPP, 14 with FFA, and 11 healthy volunteers	Trichoscopic structures in active DLE Interfollicular scaling in 11(100%), large yellow dots in 10 (89%), thick arborizing vessels in 7(67%), and red dots 6 (56%) White structureless areas 11(100%) were the most frequent in inactive DLE. Thin arborizing vessels were present in 4(33%) of patients with active and 5(50%) with inactive DLE.	On ultrasonography, the entrance echo thickness in each group of patients was greater than in the control group. The highest value was obtained in active DLE ( $0.219 \pm 0.069$ mm). Partially thickened, doubled, irregular entrance echo was found, which corresponds to the longest follicular structure, which was observed in active lichen planopilaris ( $1.190 \pm 0.180$ mm) and active DLE ( $1.107 \pm 0.379$ mm).	III
Mathur et al <sup>17</sup> 2019	Cross-sectional study	Total 21 cases 5 DLE 1 Alopecia areata 11 Pemphigus foliaceus 4 LPP	In this study the presence of tubular casts in various alopecia were observed and it was seen 5 cases of scalp DLE.		III
Abraham et al <sup>13</sup> 2010	Case series	1 DLE 1 FFA 1 LPP 1 CCCA 1 FD	Pinpoint white dots on scalp dermoscopy were analyzed on histopathology. The white dot in dark-skinned patients corresponds to eccrine openings in histopathology.		IV
Cervantes et al <sup>11</sup> 2017	Case series	2 African American patients	Dry trichoscopy of scalp DLE revealed a multicolor pattern consisting of a central white area surrounded by irregular patchy areas of confluent blue and brown pigment and an overlying white "ground-glass" hue (blue-white veil). Thick arborizing vessels in the hypopigmented center. A brown rim of pigmented network and focal scale was seen in both cases.	The blue-white veil on dermatoscopic findings of DLE without evidence of underlying melanoma. This is more prevalent in patients of color because of the heavier load of pigment incontinence in the papillary dermis.	IV

(Continued)

Table 3 (Continued).

Author	Study Design	Study Participants	Dermoscopy Results	Other Findings	Level of Evidence
Lanuti et al <sup>58</sup> 2012	Case series	3 DLE	Follicular red dots correlated with widened infundibula plugged by keratin and surrounded by dilated vessels and extravasated RBCs. Pinpoint white dots correlate with openings of eccrine sweat ducts and hair follicles. White patches correspond to regression and tissue fibrosis. Blue-grey dots correspond to melanophages in the papillary dermis. Follicular keratotic plugs correlate with hyperkeratosis and plugging follicular ostia by keratotic material.	Follicular keratotic plugs are a marker of DLE and were seen in early and active lesions and not in areas of scarring or healed skin	IV
Tosti et al <sup>12</sup> 2009	Case series	5 scalp DLE	Follicular red dots appear as erythematous polycyclic, concentric structures, with a diameter ranging from 0.16 to 0.47 mm, regularly distributed in and around the follicular ostia was described in scalp DLE.	The follicular red dot pattern is a specific feature of scalp lesions of active lupus erythematosus of the scalp	IV
Ankad et al <sup>40</sup> 2013	Case report	2 patients 1 DLE 1 LPP	Trichoscopy of scalp DLE showed branching capillaries (yellow diamond), white patches (yellow star), keratin plugs (red arrow), reduced follicular ostia and white dots (red stars). Blue-grey dots (yellow arrow) inside the patch of alopecia labelled as “speckles” pattern.		V
Jha et al <sup>14</sup> 2016	Case report	1 scalp DLE	Dermoscopy of scalp DLE revealed linear as well as branching vessels, focal keratin plugs, perifollicular whitish halo, rosettes, and structure-less white and brown areas	Rosettes vary in size from 0.2–0.5 mm, and are believed to stem from an optical effect of the polarized light and its interaction with adnexal openings that are narrowed or filled with keratin; larger rosettes may be attributed to concentric perifollicular fibrosis.	V
Ankad et al <sup>18</sup> 2017	Case report	1 scalp DLE	Dermoscopy of scalp DLE revealed white rosettes are shiny white structures seen as four oval-shaped points that come together in the center. They resemble four-leaf clover.		V
Nascimento et al <sup>59</sup> 2018	Case report	1 DLE and FFA overlap	Perifollicular scaling, small caliber white dots and preservation of the pigment network		V

**Abbreviations:** CCCA, Central centrifugal alopecia; DC, Dissecting cellulitis; FD, Folliculitis decalvans; LPP, Lichen planopilaris; DLE, Discoid Lupus Erythematosus; FFA, Frontal Fibrosing Alopecia; PPB, Pseudopelade of Brocq.

with an overlying “ground-glass” hue corresponding to hyperkeratosis overlying lichenoid infiltrate with melanophages in the upper dermis.<sup>11,31</sup> Speckled brown pigmentation in the interfollicular area (Figure 4) correlates with the involvement of interfollicular interface dermatitis with melanin incontinence, which was seen significantly in active DLE.

## Vessels

Thick arborizing vessels have a diameter more than the diameter of the hair shafts and were reported in scalp DLE with a mean vessel thickness of  $114 \pm 28$  nm. These correspond to subpapillary plexus on histology. This was seen in both groups, but the distribution around the follicle points towards LPP, and the presence of vasculature in the interfollicular area indicates scalp DLE.<sup>24</sup> As per Tosti et al, nonfollicular red dots visualized on hand-held dermoscopy correspond to coiled vessels on videodermoscopy, a specific indication of active DLE.<sup>13</sup> Hairpin vessels are seen in the normal scalp, but in DLE, the density of the vasculature was significantly increased in our review.<sup>32</sup>

## Hair Shaft Features

Black dots represent cadaverized or broken hair before the emergence of hair from the scalp surface. Vellus hairs are thin hair shafts (less than 0.03mm in diameter) with less pigmentation, while the regrowing hairs and circular pigtail hairs are darkly pigmented upright shafts with tapered ends. Both vellus hairs and regrowing hairs were seen predominantly in LPP. Pili torti on trichoscopy shows flattening at irregular intervals, with twisting at 180°, and was described in scalp DLE.<sup>2</sup>

Limitations of this review were inconsistent and variability in the terminologies of dermoscopic features, the inclusion of all tools [dermoscope and videodermoscope], and data on variability in the findings on polarized and nonpolarized light were not assessed. While the study included participants of various skin types, the specific nuances and differences within skin of color may not have been explicitly examined or emphasized. Nevertheless, the broader literature recognizes the importance of considering skin type diversity and its potential impact on trichoscopic findings. Detailed analysis of variation in the trichoscopic findings in skin of color could be extrapolated, and further stratification of the scalp and non-scalp DLE and follicular LP could be evaluated.

## Conclusion

In conclusion, this systematic review indicates that trichoscopy can be an effective tool in differentiating the two common forms of cicatricial alopecias: the presence of follicular red dots, perifollicular scales, pink-white background, speckled brown pigmentation, chrysalides, white rosettes, and vessels indicate scalp DLE and follicular white fibrotic dots, perifollicular tubular casts, blue-gray dots/globules in a target pattern, and milky white areas point LPP. In the future, a large comparison study involving both fair and dark-skinned individuals and using standardized trichoscopic terms will be able to further explore the distinguishing trichoscopic features of scalp DLE from LPP.

## Acknowledgment

We thank the patient for granting permission for clinical photography.

## Funding

There is no funding to report.

## Disclosure

The authors report no conflicts of interest in this work.

---

## References

1. Olga Warszawik M. Trichoscopy of cicatricial alopecia. *J Drugs Dermatol*. 2012;11:753–758.
2. Stefanato CM. Histopathology of alopecia: a clinicopathological approach to diagnosis. *Histopathology*. 2010;56(1):24–38. doi:10.1111/j.1365-2559.2009.03439.x
3. Rudnicka L, Olszewska M, Rakowska A, Kowalska-Oledzka E, Slowinska M. Trichoscopy: a new method for diagnosing hair loss. *J Drugs Dermatol*. 2008;7:651–656.

4. Trachsler S, Trüeb RM. Value of direct immunofluorescence for differential diagnosis of cicatricial alopecia. *Dermatology*. 2005;211(2):98–102. doi:10.1159/000086436
5. Bharti S, Dogra S, Saikia B, Walker RM, Chhabra S, Saikia UN. Immunofluorescence profile of discoid lupus erythematosus. *Indian J Pathol Microbiol*. 2015;58(4):479–482. doi:10.4103/0377-4929.168850
6. Bary AA, Eldeeb M, Hassan E. Cicatricial alopecia: do clinical, trichoscopic, and histopathological diagnosis agree? *Acta Dermatovenerol Alp Pannonica Adriat*. 2021;30:129–137.
7. Mehta P, Malakar S. Trichoscope as a monitoring tool for therapeutic efficacy in lichen planopilaris. *Int J Dermoscopy*. 2017;1:38–39. doi:10.5005/jp-journals-10061-0009
8. Panjwani S. Early diagnosis and treatment of discoid lupus erythematosus. *J Am Board Fam Med*. 2009;22(2):206–213. doi:10.3122/jabfm.2009.02.080075
9. Vendramini DL, Silveira BR, Duque-Estrada B, et al. Isolated body hair loss: an unusual presentation of lichen planopilaris. *Skin Appendage Disord*. 2017;2:97–99. doi:10.1159/000449229
10. Lacarrubba F, Musumeci ML, Ferraro S, et al. A three-cohort comparison with videodermoscopic evidence of the distinct homogeneous bushy capillary microvascular pattern in psoriasis vs atopic dermatitis and contact dermatitis. *J Eur Acad Dermatol Venereol*. 2016;30:701–703. doi:10.1111/jdv.12998
11. Cervantes J, Hafeez F, Miteva M. Blue-white veil as novel dermoscopic feature in discoid lupus erythematosus in 2 African-American patients. *Skin Appendage Disord*. 2017;3:211–214. doi:10.1159/000477354
12. Tosti A, Torres F, Misciali C, et al. Follicular red dots: a novel dermoscopic pattern observed in scalp discoid lupus erythematosus. *Arch Dermatol*. 2009;145(12):1406–1409. doi:10.1001/archdermatol.2009.277
13. Abraham LS, Pineiro-Maceira J, Duque-Estrada B, et al. Pinpoint white dots in the scalp: dermoscopic and histopathologic correlation. *J Am Acad Dermatol*. 2010;63(4):721–722. doi:10.1016/j.jaad.2009.12.011
14. Jha AK, Sonthalia S, Sarkar R. Dermoscopy of discoid lupus erythematosus. *Indian Dermatol Online J*. 2016;7(5):458. doi:10.4103/2229-5178.190493
15. Souissi A, Ben Tanfous A, Azzouz H, et al. When trichoscopy enlightens clinics. *Int J Dermatol*. 2016;55(11):1278–1280. doi:10.1111/ijd.13139
16. Choundhary SV, Tarafdar PP, Jawade S, Singh A. A point to note in pili torti. *Int J Trichol*. 2018;10:95–97. doi:10.4103/ijt.ijt\_111\_16
17. Mathur M, Acharya P, Karki A, Shah J, Kc N. Tubular Hair Casts in Trichoscopy of Hair and Scalp Disorders. *Int J Trichol*. 2019;11:14–19. doi:10.4103/ijt.ijt\_77\_18
18. Ankad BS, Shah SD, Adya KA. White rosettes in discoid lupus erythematosus: a new dermoscopic observation. *Dermatol Pract Concept*. 2017;7:9–11. doi:10.5826/dpc.0704a03
19. Tosti A. Lonely hair sign: not specific for frontal fibrosing alopecia-reply. *Arch Dermatol*. 2012;148:1208–1209. doi:10.1001/archdermatol.2012.1873
20. Żychowska M. Dermoscopy of discoid lupus erythematosus—a systematic review of the literature. *Int J Dermatol*. 2021;60:818–828. doi:10.1111/ijd.15365
21. Gomez-Quispe H, de Las Heras-Alonso ME, Lobato-Berezo A, et al. Trichoscopic findings of discoid lupus erythematosus alopecia: a cross-sectional study. *J Am Acad Dermatol*. 2020;S0190-9622:31021–31025.
22. Qi S, Zhao Y, Zhang X, Li S, Cao H, Zhang X. Clinical features of primary cicatricial alopecia in Chinese patients. *Indian J Dermatol Venereol Leprol*. 2014;80:306–312. doi:10.4103/0378-6323.136833
23. Sillani C, Bin Z, Ying Z, Zeming C, Jian Y, Xingqi Z. Effective treatment of folliculitis decalvans using selected antimicrobial agents. *Int J Trichol*. 2010;2:20–23. doi:10.4103/0974-7753.66908
24. Miteva M, Tosti A. Dermoscopy guided scalp biopsy in cicatricial alopecia. *J Eur Acad Dermatol Venereol*. 2013;27(10):1299–1303. doi:10.1111/j.1468-3083.2012.04530.x
25. Tawfik SS, Sorour OA, Alariny AF, et al. White and yellow dots as new trichoscopic signs of severe female androgenetic alopecia in dark skin phototypes. *Int J Dermatol*. 2018;57:1221–1228. doi:10.1111/ijd.14140
26. Inui S, Itami S, Murakami M, Nishimoto N. Dermoscopy of discoid lupus erythematosus: report of two cases. *J Dermatol*. 2014;41(8):756–757. doi:10.1111/1346-8138.12547
27. Choundhary SV, Tarafdar PP, Jawade S, Singh A. A point to note in pili torti. *Int J Trichol*. 2018;10:95–97.
28. Lallas A, Apalla Z, Lefaki I, et al. Dermoscopy of discoid lupus erythematosus. *Br J Dermatol*. 2013;168(2):284–288. doi:10.1111/bjd.12044
29. Massi D, De Giorgi V, Carli P, Santucci M. Diagnostic significance of the blue hue in dermoscopy of melanocytic lesions: a dermoscopic-pathologic study. *Am J Dermatopathol*. 2001;23:463–469. doi:10.1097/0000372-200110000-00013
30. Liebman TN, Rabinovitz HS, Dusza SW, Marghoob AA. White shiny structures: dermoscopic features revealed under polarized light. *J Eur Acad Dermatol Venereol*. 2012;26(12):1493–1497. doi:10.1111/j.1468-3083.2011.04317.x
31. Jain N, Doshi B, Khopkar U. Trichoscopy in alopecias: diagnosis simplified. *Int J Trichol*. 2013;5:170–178. doi:10.4103/0974-7753.130385
32. Lajevardi V, Mahmoudi H, Moghanlou S, Ansari M, Teimourpour A, Daneshpazhooh M. Assessing the correlation between trichoscopic features in lichen planopilaris and lichen planopilaris activity index. *Australas J Dermatol*. 2019;60(3):214–218. doi:10.1111/ajd.13022
33. Eftekhari H, Azimi SZ, Rafiei R, et al. Dermoscopic features of lichen planopilaris in Northern Iran: a prospective observational study. *Int J Dermatol*. 2019;58(12):1406–1414. doi:10.1111/ijd.14589
34. Estrada BD, Tamlar C, Sodré CT, Barcaui CB, Pereira FB. Dermoscopy patterns of cicatricial alopecia resulting from discoid lupus erythematosus and lichen planopilaris. *Anais brasileiros de dermatologia*. 2010;85:179–183. doi:10.1590/S0365-05962010000200008
35. Farag AM, Salem RM, Abdelrahman AM, EL-Adawy DM. Trichoscopic Findings of Frontal Fibrosing Alopecia. *Benha J Appl Sci*. 2020;5:71–74. doi:10.21608/bjas.2020.136217
36. Panchaprateep R, Ruxrungham P, Chancheewa B, Asawanonda P. Clinical characteristics, trichoscopy, histopathology and treatment outcomes of frontal fibrosing alopecia in an Asian population: a retro-prospective cohort study. *J Dermatol*. 2020;47:1301–1311. doi:10.1111/1346-8138.15517
37. Thakur BK, Verma S, Raphael V. Clinical, trichoscopic, and histopathological features of primary cicatricial alopecias: a retrospective observational study at a tertiary care centre of North East India. *Int j Trichol*. 2015;7(3):107. doi:10.4103/0974-7753.167459
38. Starace M, Brandi N, Alessandrini A, Bruni F, Piraccini BM. Frontal fibrosing alopecia: a case series of 65 patients seen in a single Italian centre. *J Eur Acad Dermatol Venereol*. 2019;33(2):433–438. doi:10.1111/jdv.15372

39. Arshdeep BM, Kubba A, Kubba R. Lichen planopilaris beyond scalp: a case series with dermoscopy-histopathology correlation. *Int J Dermatol*. 2018;57:e127–31. doi:10.1111/ijd.14168
40. Ankad BS, Beergoudar SL, Moodalgiri VM. Lichen planopilaris versus discoid lupus erythematosus: a trichoscopic perspective. *Int J Trichol*. 2013;5(4):204. doi:10.4103/0974-7753.130409
41. Friedman P, Sabban EC, Marcucci C, Peralta R, Cabo H. Dermoscopic findings in different clinical variants of lichen planus. Is dermoscopy useful? *Dermatol Practical Conceptual*. 2015;31:51–55. doi:10.5826/dpc.0504a13
42. Thompson CT, Velasco MA, Tosti A. Three-dimensional imaging of a peripilar cast and compound follicle in frontal fibrosing alopecia. *JAAD Case Rep*. 2022;23:46–48. doi:10.1016/j.jcdr.2022.02.036
43. Shim WH, Jwa SW, Song M, et al. Dermoscopic approach to a small round to oval hairless patch on the scalp. *Ann Dermatol*. 2014;26:214–220. doi:10.5021/ad.2014.26.2.214
44. Góes HF, Dias MF, Salles SD, Lima CD, Vieira MD, Pantaleão L. Lichen planopilaris developed during childhood. *Anais Brasileiros de Dermatologia*. 2017;92:543–545. doi:10.1590/abd1806-4841.20174890
45. Zeeshan M, Chaudhary RK, Roy PK, Jha AK. Dermoscopy in selected disorders of scarring alopecia. *J Pakistan Assoc Dermatol*. 2018;28:449–451.
46. Batra P, Sukhdeo K, Shapiro J. Hair loss in lichen planopilaris and frontal fibrosing alopecia: not always irreversible. *Skin Appendage Disorders*. 2020;6(2):125–129. doi:10.1159/000505439
47. Kaliyadan F, Ameer AA. Localized and linear lichen planopilaris over the face and scalp with associated alopecia—clinical and dermoscopy pattern. *Dermatol Online J*. 2015;21:13030. doi:10.5070/D3219028698
48. Rossi A, Iorio A, Scali E, et al. Frontal fibrosing alopecia and lichen planopilaris: clinical, dermoscopic and histological comparison. *Eur J Inflammation*. 2013;11(1):311–314. doi:10.1177/1721727X1301100134
49. Andziukeviciute J, Makstiene J, Valiukeviciene S. Trichoscopy as an Additional Diagnostic Tool for Monitoring of Lichen planopilaris. *Aktuelle Dermatologie*. 2016;280–282.
50. Rakowska A, Slowinska M, Kowalska-Oledzka E, et al. Trichoscopy of cicatricial alopecia. *J Drugs Dermatol*. 2012;11:753–758.
51. Melo DF, De Carvalho N, Ardigò M, et al. Concordance among in vivo reflectance confocal microscopy, trichoscopy, and histopathology in the evaluation of scalp discoid lupus. *Skin Res Technol*. 2020;26:675–682. doi:10.1111/srt.12852
52. Nikam VV, Mehta HH. A nonrandomized study of trichoscopy patterns using nonpolarized (contact) and polarized (noncontact) dermatoscopy in hair and shaft disorders. *Int J Trichol*. 2014;6(2):54. doi:10.4103/0974-7753.138588
53. Chiramel MJ, Sharma VK, Khandpur S, Sreenivas V. Relevance of trichoscopy in the differential diagnosis of alopecia: a cross-sectional study from North India. *Indian J Dermatol Venereol Leprol*. 2016;82:651. doi:10.4103/0378-6323.183636
54. Karadag O, Güleç AT. Evaluation of a handheld dermatoscope in clinical diagnosis of primary cicatricial alopecias. *Dermatol Therapy*. 2019;9:525–535. doi:10.1007/s13555-019-0304-3
55. Abedini R, Kamyab Hesari K, Daneshpazhooh M, Ansari MS, Tohidinik HR, Ansari M. Validity of trichoscopy in the diagnosis of primary cicatricial alopecias. *Int J Dermatol*. 2016;55(10):1106–1114. doi:10.1111/ijd.13304
56. Melo DF, Müller Ramos P, Iorizzo M, et al. Epidemiological, Clinical, Trichoscopic, and Histopathological Features of Lupus Erythematosus Mimicking Alopecia Areata: a Multicenter Retrospective Study. *Skin Appendage Disorders*. 2022;8:236–240. doi:10.1159/000520825
57. Mikiel D, Polańska A, Żaba R, Adamski Z, Dańczak-Pazdrowska A. Suitability of high-frequency ultrasonography (20 MHz) in evaluation of various forms of primary cicatricial alopecia in relation to trichoscopy—pilot study. *Skin Res Technol*. 2021;27:774–784. doi:10.1111/srt.13018
58. Lanuti E, Miteva M, Romanelli P, Tosti A. Trichoscopy and histopathology of follicular keratotic plugs in scalp discoid lupus erythematosus. *Int j Trichol*. 2012;4(1):36. doi:10.4103/0974-7753.96087
59. Nascimento LLD, Enokihara MMSES, Vasconcellos MRA. Coexistence of chronic cutaneous lupus erythematosus and frontal fibrosing alopecia. *An Bras Dermatol*. 2018;93:274–276. doi:10.1590/abd1806-4841.20186992

## Clinical, Cosmetic and Investigational Dermatology

Dovepress

### Publish your work in this journal

Clinical, Cosmetic and Investigational Dermatology is an international, peer-reviewed, open access, online journal that focuses on the latest clinical and experimental research in all aspects of skin disease and cosmetic interventions. This journal is indexed on CAS. The manuscript management system is completely online and includes a very quick and fair peer-review system, which is all easy to use. Visit <http://www.dovepress.com/testimonials.php> to read real quotes from published authors.

Submit your manuscript here: <https://www.dovepress.com/clinical-cosmetic-and-investigational-dermatology-journal>