

CASE REPORT

Open Access



# An unusual cause of infant's stridor – congenital laryngocele

Ambrus Andrea<sup>1\*</sup>, Sztanó Balázs<sup>1</sup>, Szabó Miklós<sup>2</sup>, Vasas Béla<sup>3</sup>, Sziller István<sup>4</sup> and Rovó László<sup>1</sup>

## Abstract

Congenital laryngocele is an uncommon cause of neonatal stridor. There are only a few cases reported in the literature. The authors present a successfully treated case of an infant, whose life could only be saved by urgent tracheostomy. On the 5th postoperative day endoscopic excision and marsupialization provided patent airway. The patient could be decannulated. During follow-up no recurrence was observed.

**Keywords:** Congenital stridor, Laryngocele, Airway obstruction

## Introduction

The neonatal laryngocele is an extremely rare phenomenon, which is defined as an air-filled cystic dilatation of the laryngeal saccule. The incidence is estimated to be 1 per 2.5 million people per year [1]. Although it is a benign lesion, it may cause stridor, respiratory distress and serious airway obstruction in the narrow airway of a newborn which necessitates urgent intervention [2]. The authors present a newborn baby successfully endoscopically treated with congenital laryngocele.

## Case report

A 5-day-old male newborn was referred to our tertiary department. He was a normal-appearing, 3135 g, full-term baby with no significant prenatal medical history. In another hospital, after birth (Apgar score: 7/7/9), immediately severe stridor and respiratory distress occurred. He required DuoPAP ventilation. Direct laryngoscopy revealed a large cystic mass bulging from the right aryepiglottic fold, which obstructed the glottis. He could not be intubated, so an urgent tracheotomy was performed. MRI described a well-circumscribed, thin-walled fluid attenuation mass, measuring 20 × 18 mm, localized at the level

of the glottis (Fig. 1 a, b). No other congenital malformation occurred.

After his admission a direct laryngoscopy under general anaesthesia was performed: a swollen cystic mass bulging from the right pharyngoepiglottic and aryepiglottic folds was found (Fig. 2 a). The cyst was incised by ultra-pulse mode CO<sub>2</sub> laser (Dhaesin U-40, Dhaesin Enterprise, South Korea; 315 W, 90 μs, 20 ms) (Fig. 2b). Thick mucoid fluid came out, then marsupialization was done. The supraglottic mass which caused laryngeal asymmetry immediately disappeared (Fig. 2c). At the end of the surgery, the baby was decannulated, but he was intubated for four days with a 3.5 cuffed tracheal tube. Parenteral antibiotic (Clindamycin 5 mg/ kg /3 times a day, Cefotaxime 25 mg/ kg/ 2 times a day) was administered for 4 days. After his extubation no dyspnea re-occurred and his stoma closed spontaneously. Postoperative period was uneventful. Control endoscopy performed on the 7th postoperative day revealed no recurrence. During the 6-month follow up period the growing of the baby was appropriate and his parents noticed no voice disturbance. Histologic report confirmed the diagnosis of a congenital laryngocele. (Fig. 3).

## Discussion

The first air-containing 'tumors' of the neck were reported in 1829. The first laryngeal cyst in a newborn

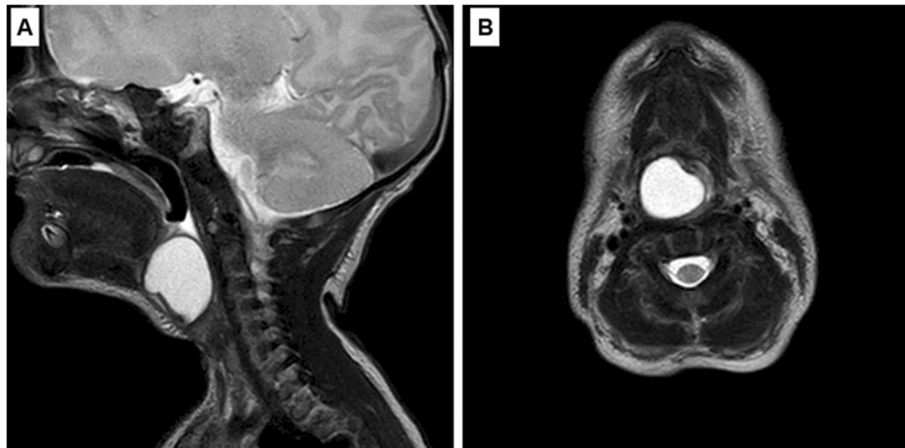
\* Correspondence: [ambrus.andrea@med.u-szeged.hu](mailto:ambrus.andrea@med.u-szeged.hu)

<sup>1</sup>Department of Otorhinolaryngology, Head and Neck Surgery, University of Szeged, Szeged, Hungary

Full list of author information is available at the end of the article



© The Author(s). 2020 **Open Access** This article is licensed under a Creative Commons Attribution 4.0 International License, which permits use, sharing, adaptation, distribution and reproduction in any medium or format, as long as you give appropriate credit to the original author(s) and the source, provide a link to the Creative Commons licence, and indicate if changes were made. The images or other third party material in this article are included in the article's Creative Commons licence, unless indicated otherwise in a credit line to the material. If material is not included in the article's Creative Commons licence and your intended use is not permitted by statutory regulation or exceeds the permitted use, you will need to obtain permission directly from the copyright holder. To view a copy of this licence, visit <http://creativecommons.org/licenses/by/4.0/>. The Creative Commons Public Domain Dedication waiver (<http://creativecommons.org/publicdomain/zero/1.0/>) applies to the data made available in this article, unless otherwise stated in a credit line to the data.



**Fig. 1** Preoperative MRI. A: Sagittal contrast MRI image shows well-circumscribed, thin-walled fluid attenuation mass. B: Axial contrast MRI image reveals the cystic mass at the level of the glottis

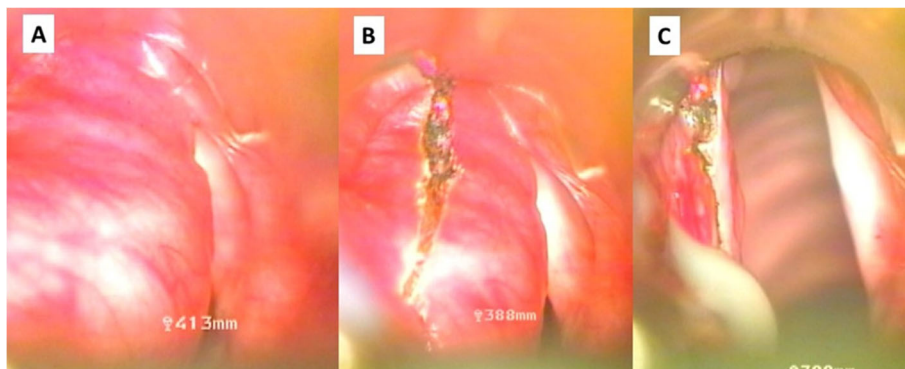
was published in 1876 [3, 4]. The first reports were based on postmortem diagnosis - all newborns died with any type of airway obstruction. Since 1970s with modern neonatology, the introduction of intubation and advanced endoscopic diagnostic and microsurgical techniques the patients' life could have been saved.

Laryngocele is an abnormal dilatation of the appendix of the laryngeal ventricle and is classified as internal and mixed or combined type according to its relationship with the thyrohyoid membrane. In reviewing the English-language literature and focusing on the pediatric population, there are very few cases of successfully treated neonatal laryngoceles. Embryologically, the ventricle of the larynx and the saccule develops at the end of the second intrauterine month as a secondary out-pouching from the laryngeal lumen. Congenitally large saccule, weakness of the periventricular connective tissues, and the thyroepiglottic and aryepiglottic muscles are accepted as predisposing factors [2].

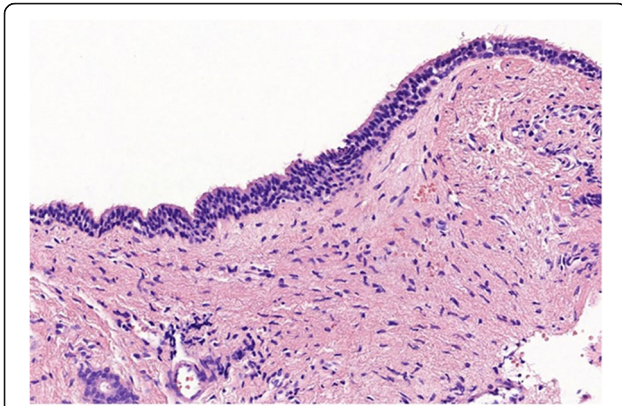
Airway obstruction cannot always be diagnosed or predicted prenatally [2]. The clinical features of this rare pathology depend on the size and type of laryngocele and are highly variable. In mild cases it is usually asymptomatic. But it may cause severe respiratory distress and inspiratory stridor and become a life-threatening event due to mechanical obstruction of the narrow and small airway of a neonate [5, 6].

The diagnosis of laryngocele mainly depends on physical examination, symptoms and laryngeal examination by direct laryngoscopy [2]. High resolution imaging modalities such as computed tomography or magnetic resonance imaging may help to delineate the structures involved and the exact location of the mass [7].

If the patient has respiratory distress and dyspnea, the airways should immediately be secured by intubation or tracheostomy. In our case the infant could not be intubated; only the urgent tracheostomy could save his life. Various surgical techniques have been utilized such as



**Fig. 2** Endoscopic surgery for congenital laryngocele - intraoperative photos. A: Cystic mass of the left false vocal cord cause severe obstruction. B: CO2 laser excision. C: After thick mucoid fluid came out, and marsupialization was done, the asymmetry of the supraglottis disappeared



**Fig. 3** Histologic finding. A hematoxylin-eosin (H&E) stained slide demonstrates the cyst lining, which is comprised of a ciliated pseudostratified columnar epithelium without atypia. There was no mucin accumulation observed in the lumen

external approach, endolaryngeal microlaryngoscopy, carbon-dioxide laser excision and transoral robotic surgery [1, 6–8]. Transoral laser endoscopic excision and marsupialization of the cyst's wall is a minimally invasive solution. Temporary intubation and administration of antibiotics prevented postoperative edema. Although Mysiorek et al. reported that marsupialization has a higher risk of recurrence, during the 6 month follow-up there was no evidence of laryngocele persistence [3, 9, 10].

### Conclusion

Congenital laryngocele is a rare cause of laryngeal dyspnea in neonates. In severe cases urgent surgical intervention must be performed because of the life-threatening airway obstruction. Laryngoscopy may establish the proper diagnosis. Laser excision with complete removal of the cyst's wall under jet ventilation anesthesia might be a successful treatment without performing a tracheostomy.

### Acknowledgements

Not applicable.

### Authors' contributions

AA collected the patient's data and reviewed the literature, wrote the manuscript. SB and RL performed the operation and were the major contributors in writing the manuscript. SI and SM recognized the dyspnea immediately after birth, performed tracheostomy. VB performed the histological examination. All authors read and approved the final manuscript.

### Funding

Authors received no funding.

### Availability of data and materials

Video documentation of the pre- and postoperative status was achieved.

### Ethics approval and consent to participate

The study was approved by our institutional ethics committee (registration number 49/2018).

### Consent for publication

Obtained from the patient's family.

### Competing interests

The authors declare that they have no competing interests.

### Author details

<sup>1</sup>Department of Otorhinolaryngology, Head and Neck Surgery, University of Szeged, Szeged, Hungary. <sup>2</sup>1st Department of Paediatrics, Semmelweis University, Budapest, Hungary. <sup>3</sup>Department of Pathology, Budapest, Hungary. <sup>4</sup>Szent Imre University Teaching Hospital, Budapest, Hungary.

Received: 12 December 2018 Accepted: 24 May 2020

Published online: 01 June 2020

### References

1. Yilmaz S, Yildizbas S, Yaman H, et al. Stridor in a newborn caused by a congenital laryngocele and bifid epiglottis: a case report and review of literature international. *J Pediatric Otorhinolaryngol Extra*. 2010;5:28–31.
2. Tasinklar H, Vayisoglu Y, Avlan D, et al. Congenital Laryngomucocele: a rare cause of airway obstruction in a newborn. *J Craniofacial Surg*. 2015;26:238–40.
3. Borko R, Szucs S [Congenital laryngeal cysts] *HNO* 2000; 48:843–845.
4. DeSanto LW. Laryngocele, laryngeal mucocele, large saccules, and laryngeal saccular cysts: a developmental spectrum. 1974; 84:1291–1296.
5. Lim EH, Mohamad H, Hamid SSA. Congenital laryngeal cyst: a report of 2 cases. *Egyptian Journal of Ear, Nose, Throat and Allied Sciences*. 2017;18: 187–9.
6. Ahmed H, Ndiaye C, Barry MW, Thiongane A, et al. A rare cause of upper airway obstruction in a child. *Case Rep Otolaryngol*. 2017;2017:2017265.
7. Chu L, Gussack GS, et al. A cause for airway obstruction. *Arch Otolaryngol Head Neck Surg*. 1994;120:454–8.
8. Saha D, Sinha R, Pai RR, Kumar A, Chakraborti S. Laryngeal cysts in infants and children—a pathologist's perspective (with review of literature). *Int J Pediatr Otorhinolaryngol*. 2013;77:1112–7.
9. Holinger LD, Barnes DR, Smid LJ. Laryngocele and saccular cysts. *Ann Otol* 87:1978.
10. Chu L, Gussack GS, Orr JB, Hood D. Neonatal Laryngoceles *Arch Otolaryngol Head and Neck Surg*. 1994;120:454–8.

### Publisher's Note

Springer Nature remains neutral with regard to jurisdictional claims in published maps and institutional affiliations.

Ready to submit your research? Choose BMC and benefit from:

- fast, convenient online submission
- thorough peer review by experienced researchers in your field
- rapid publication on acceptance
- support for research data, including large and complex data types
- gold Open Access which fosters wider collaboration and increased citations
- maximum visibility for your research: over 100M website views per year

At BMC, research is always in progress.

Learn more [biomedcentral.com/submissions](https://biomedcentral.com/submissions)

