



Pterygium: epidemiology prevention and treatment



Prof Dr Sanjay Kumar Singh

Director, Eastern Regional Eye Care Programme, Biratnagar, Nepal.

Epidemiology

Pterygium is a degenerative disorder of the conjunctiva. It is usually seen as a triangular fleshy fibrovascular proliferation from the bulbar conjunctiva onto the cornea, located mostly on the nasal side. Though it occurs worldwide, its prevalence is high in the "pterygium belt" between 30 degrees north and 30 degrees south of the equator.¹ The prevalence of pterygium is reported to be 3% in Australians, 23% in blacks in United States, 15% in Tibetans in China, 18% in Mongolians in China, 30% in Japanese and 7% in Singaporean Chinese and Indians.²⁻⁷

In a population-based study from rural central India, prevalence of pterygium increased from 6.7±0.8% in the age group from 30-39 years to 25.3±2.1% in the age group of 70-79 years. Three population based studies have described the incidence of pterygium. Barbados eye study has described the nine year incidence of pterygium to be 11.6% (95% CI, 10.1-13.1), the Beijing Eye Study described the 10 year incidence of pterygium in the adult Chinese population to be 4.9%, and the five year cumulative incidence in Bai Chinese population in a rural community was 6.8% (95% CI, 5.2-8.4).⁸⁻¹⁰

Risk factors and pathogenesis

These population-based studies suggest that cumulative ultraviolet light exposure due to outdoor occupation is a major risk factor for the development of pterygium. Other factors associated with pterygium development are age, being male and having dry eyes.¹¹⁻¹³ Genetic factors, tumor suppressor gene p53 and other genes may be involved in the pathogenesis of pterygium.¹⁴

A study indicated a two-stage hypothesis for pterygium pathogenesis: initial disruption of the limbal barrier and progressive active "conjunctivalisation" of the cornea.¹⁵ Identifi-

cation of Fuchs Flecks at the head of pinguecula, primary pterygium, recurrent pterygium, and macroscopically normal nasal and temporal limbus may represent precursor lesions to UV associated ocular surface pathology.¹⁶

Prevention

Avoidance of environmental risk factors like sunlight, wind and dust by wearing UV rays protecting sunglasses and hat may prevent development of pterygium. These protective measures may help to prevent recurrence of pterygium after surgery. Similarly, wearing of eye safety equipment is recommended in environment exposed to chemical pollutants as a preventive measure for pterygium.

Indication for surgery

The main indication for pterygium surgery is visual disturbance secondary to encroachment over the pupillary area or induced astigmatism. Other indications which can be considered are, restriction in eye movements, chronic redness and foreign body sensation, and cosmetic concerns.¹⁷

Management

Surgery is the mainstay of treatment for pterygium causing visual disturbances. The primary complication of pterygium surgery is recurrence defined by regrowth of fibrovascular tissue across the limbus and onto the cornea. No uniformity of opinion exists regarding the ideal pterygium excision procedure associated with lowest recurrence rate. Bare sclera technique, which is widely used in the developing world for the ease and speed of surgery, is associated with high recurrence rates.¹⁸ Other adjunctive therapies combined with bare sclera technique have significantly reduced the recurrence rate (2% to 15%).¹⁹ Application of different agents like Strontium 90, Beta irradiation and cytotoxic drugs like Mitomycin-C and 5-Fluorouracil to the scleral bed have been tried but sight threatening complications like inflammatory scleritis, scleromalacia and loss of the eye have been occasionally reported.²⁰ Amniotic membrane transplan-

tation has been used after bare sclera technique with a reported recurrence rate of 4% to more than 60%.^{21,22} Currently, the most widely used procedure is pterygium excision with conjunctival autograft.²³ Superior bulbar conjunctiva has been used widely since the early 1980s and is associated with recurrence rate of approximately 2% to 12% along with few complications.²⁴⁻²⁶ In the 1980s, Barraquer introduced the concept that removal of Tenon's layer may be important in reducing recurrence rate after pterygium removal as the tenon is the main source of fibroblasts.²⁷ This was also emphasised by Solomon et al who combined this technique with Mitomycin-C application and amniotic membrane transplantation to achieve a low recurrence rate.²⁸ A near zero recurrence rate with a good aesthetic result can be achieved by using Pterygium Extended Removal Followed by Extended Conjunctival Transplantation (P.E.R.F.E.C.T.).²⁹⁻³¹ There is no ideal technique for conjunctival autografting which is safe, fast, easy and inexpensive. Various methods such as sutures, fibrin glue, autologous serum and electrocautery have been used for conjunctival autografting.^{32,33} Surgical steps for pterygium excision with conjunctival autograft that we have adopted at our hospitals under Eastern Regional Eye Care Programme in the eastern part of Nepal are as follows:

Anaesthesia: Peribulbar anaesthesia is preferable over the topical or subconjunctival to avoid pain during operation and to have smooth surgical procedure.

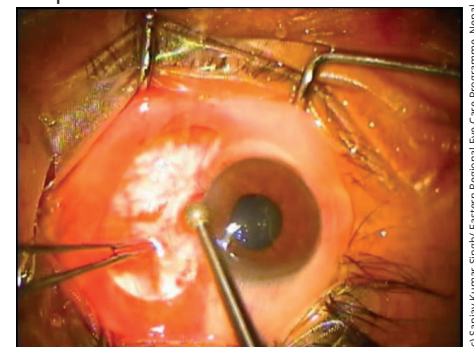


Figure 1. A diamond burr is used for smoothing of corneal surface

© Sanjay Kumar Singh Eastern Regional Eye Care Programme, Nepal

Continues overleaf ▶

Pterygium excision: Pterygium body is excised carefully with conjunctival scissors and the head of pterygium can be removed from cornea by using a 15 degree Bard Parker blade. Tenons and subtenon tissue must be removed carefully as much as possible. Remaining pterygium tissues from over the corneal surface can be removed with a diamond burr.

Conjunctival autograft preparation: The conjunctival defect created by pterygium excision should be measured with a caliper and the superior bulbar conjunctiva should be marked by a marker. It is always preferable to use the marker to create exactly the same size of the graft. After marking, a subconjunctival injection of normal saline, around 2 ml, is injected on the superior bulbar conjunctiva to create the conjunctival balloon. A thin layer of conjunctival graft, devoid of tenons and subtenon tissue is prepared.

Conjunctival grafting: The thin conjunctival graft is placed with correct orientation on the area of the conjunctival defect created by pterygium excision. The marker helps to identify the correct orientation of the graft. The conjunctival graft can be sutured with the 8/0 Vicryl or 10/0 Nylon sutures or can be glued with fibrin glue.

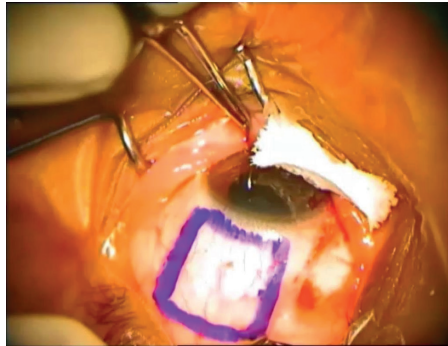


Figure 2. A conjunctival autograft marking

Conjunctival grafting with fibrin glue is a faster procedure and patients complain of less pain in the post-operative period.

Post-operative management: Antibiotic and steroid eye drops are given in tapering doses for one month.

Conclusion

Many ophthalmologists think that pterygium is a trivial condition for which not much time should be expended in surgery and for which the financial remuneration is low.³⁴ But the patients want a cure, free of recurrence with good cosmesis after surgery. Pterygium excision with conjunctival autograft with fibrin glue offers a low recurrence rate, good cosmetic outcome with a reasonable speed of the pterygium surgery.

References

- Detels R, Dhir SP, Pterygium: a geographical study. *Arch Ophthalmol.* 1967;78: 485-491.
- McCarty CA, Fu CL, Taylor HR. Epidemiology of Pterygium in Victoria, Australia. *Br J Ophthalmology.* 2000;84:289-292.
- Luthra R, Nemesure BB, Wu SY, et al. Frequency and Risk Factors for Pterygium in the Barbados Eye Study. *Arch Ophthalmology.* 2001;119:1827- 1832.
- Lu P, Chen X, Kang Y, et al. Pterygium in Tibetans: a population-based study in China. *Clin Experiment Ophthalmol.* 2007;35:828-833.
- Lu J, Wang Z, Lu P, et al. Pterygium in an aged Mangolian Population: a population based study in China. *Eye (Lond)* 2009;23:421-427.
- Shirma H, Higa A, Sawaguchi S, et al. Prevalence and risk factors of Pterygium in southwestern island of Japan: the Kumejima Study. *Am J Ophthalmol.* 2009;148:766-771.e761.
- Ang M, Li X, Wong W, et al. Prevalence of and racial differences in pterygium a multiethnic population study in Asians. *Ophthalmology.* 2012;119:1509-1515.
- Nemesure B, Wu SY, Hennis A et al. Nine-year incidence and risk factors for pterygium in the Barbados eye studies. *Ophthalmology.* 2008;115:2153-2158.
- Zhao L, You QS, Xu L, et al. 10 year incidence and association of Pterygium in adult Chinese: the Beijing Eye Study. *Invest Ophthalmol Vis Science.* 2013; 54:1509-1514.
- Lan Li, Hua Zhong, Ermio Tian et al. Five-Year Incidence and Predictors for Pterygium in a Rural Community in China: The Unnan Minority Eye Study. *Cornea.* 2015;34:1564-1568.
- Wong TY, Foster PJ, Johnson GJ, et al. The Prevalence and risk factors for pterygium in an adult Chinese population in Singapore: the Tanjong Pagar survey. *Am J Ophthalmol.* 2001;131:176-183.
- Saw SM, Banerjee K, Tan D. Risk factors for the development of pterygium in Singapore: a hospitalbased case control study. *Acta Ophthalmol Scand.* 2000;78:216-220.
- Ishioke M, Shimmura S, Yagi Y et al. Pterygium and dry eye. *Ophthalmologica.* 2001;215:209- 211.
- Liu T, Liu Y, Xie L, et al. Progress in the pathogenesis of pterygium. *Current Eye Res.* 2013;38:1191-1197.
- M.T. Coroneo, N. Di Girolamo and D. Wakeeld. The pathogenesis of pterygia. *Current Opinion in Ophthalmology.* 1999;10:282-288.
- Matthew H. Ip, Jeanie J Chui, Lien Tat and Minas T. Coroneo. Significance of Fuchs Flecks in Patients With Pterygium/Pinguecula: Earliest Indicator of Ultraviolet Light Damage. *Cornea.* 2015;34:1560- 1563.
- Lawrence W. Hirst. The Treatment of Pterygium. *Survey of Ophthalmology.* 2003;48:2: 145-179.
- Lawrence W. Hirst. Prospective Study of Primary Pterygium surgery using Pterygium Extended Removal Followed by Extended Conjunctival Transplantation. *Ophthalmology.* 2008;115:1663- 1672.
- Simsek T, Gunlap I, Atilla H. Comparative efficacy of beta irradiation and mitomycin-C in primary and recurrent pterygium. *Eur J Ophthalmol.* 2001;11:126-132.
- Dougherty PJ, Hardten DR, Lindstrom RL. Corneoscleral melt after pterygium surgery using a single intraoperative application of mitomycin-C. *Cornea.* 1996;15:537-540.
- Ma DH, See LC, Liao SB, Tsai RJ. Amniotic Membrane graft for primary pterygium: comparison with conjunctival autograft and topical mitomycin C treatment. *Br J Ophthalmol.* 2000;84:973-978.
- Essex RW, Snibson GR, Daniell M, Tole DM. Amniotic membrane grafting in the surgical management of primary pterygium. *Clin. Experiment Ophthalmol.* 2004;32:501-504.
- Kenyon KR, Wagoner MD, Hettinger ME. Conjunctival autograft transplantation for advanced and recurrent pterygium. *Ophthalmology.* 1985;92:1461-1470.
- Young AL, Leung GY, Wong AK et al. A randomized trial comparing 0.02% mitomycin-C and limbal conjunctival autograft after excision of primary pterygium. *Br J Ophthalmol.* 2004;88:995-997.
- Mejia LF, Sanchez JG, Escobar H. Management of primary pterygia using free conjunctival and limbal conjunctival autografts without antimetabolites. *Cornea.* 2005;24:972-975.
- Fernandes M, Sangwan VS, Bansal AK et al. Outcome of pterygium surgery: analysis over 14 years. *Eye.* 2005;19:1182-1190.
- Barraquer JL. Etiology, pathogenesis and treatment of the pterygium. *Trans New Orleans Acad Ophthalmol.* 1980;167-178.
- Solomon A, Pires RT, Tseng SC. Amniotic membrane transplantation after extensive removal of primary and recurrent pterygia. *Ophthalmology.* 2001;108:449-460.
- Hirst LW. Prospective study of Primary Pterygium Surgery using Pterygium Extended Removal Followed by Extended Conjunctival Transplantation. *Ophthalmology.* 2008;115:1663-1672.
- Hirst LW. Cosmesis after Pterygium extended removal followed by extended conjunctival transplantation as assessed by a new, web-based grading system. *Ophthalmology.* 2011;118:1739- 1746.
- Hirst LW. Pterygium Extended Removal Followed by Extended Conjunctival Transplantation: But on which eye? *Cornea.* 2013;32:799-802.
- Vaniha Ratnalingam, Andrew Lim Keat Eu, Gem Leong et al. Fibrin Adhesive is Better Than Sutures in Pterygium Surgery. *Cornea.* 2010;29:485-489.
- Fan Xu, Min Li, Yumei Yan et al. A Novel Technique of Sutureless and Glueless Conjunctival Autografting in Pterygium Surgery by Electrocautery Pen. *Cornea.* 2013;32:290-295.
- Essex RW, Snibson GR, Daniell M et al. Amniotic Membrane grafting in the surgical management of primary pterygium. *Clin Experiment Ophthalmol.* 2004;32:501-504.