

Available online at [www.sciencedirect.com](http://www.sciencedirect.com)

ScienceDirect

journal homepage: [www.elsevier.com/locate/radcr](http://www.elsevier.com/locate/radcr)

## Case Report

# Case of Brown Sequard syndrome with ipsilateral peripheral vasodilation ☆☆☆★

Kari Nelson, MD, Eleanor Chu, MD\*, Nadine Abi-Jaoudeh, MD

University of California Irvine School of Medicine, 101 The City Drive South, Building 20, Room 144, Orange, CA 92868, USA

## ARTICLE INFO

## Article history:

Received 23 May 2020

Revised 2 June 2020

Accepted 2 June 2020

## Keywords:

Brown-Sequard

Cord transection

Vasodilation

Sympathetic tone

## ABSTRACT

Brown-Sequard Syndrome is a neurologic disorder caused by partial spinal cord injury and disruption of the corticospinal tract, dorsal columns, and spinothalamic tract. We present a 32-year-old male with partial T11-12 cord transection due to a penetrating knife injury. In addition to the classical neurological symptoms of Brown-Sequard Syndrome, he also exhibited ipsilateral peripheral vasodilatation below the level of injury. This finding is attributed to the disruption of the intermediolateral columns of the spinal cord and impaired sympathetic tone on the peripheral vasculature. Awareness of this finding can raise the radiologist's suspicion for spinal cord injury in the setting of trauma and peripheral vasodilation.

© 2020 The Authors. Published by Elsevier Inc. on behalf of University of Washington.

This is an open access article under the CC BY-NC-ND license.

(<http://creativecommons.org/licenses/by-nc-nd/4.0/>)

☆ No funding was received for this project.

☆☆ Competing Interest: Kari Nelson: None; Eleanor Chu: None; Nadine Abi-Joudeh: Philips Healthsystems (collaborative research agreement); Sillajen Inc (PI on research grant); Teclison Cheery Pharma (PI on research grant); Sirtex Inc (PI on research grant); Guerbet Inc (PI on grant funding); Bruin Biosciences Inc (ownership).

\* Activities that Do Not Constitute Human Subjects Research. The University of California, Irvine (UCI) Human Research Protections Program complies with all review requirements defined in 45 CFR Part 46, *Protection of Human Subjects*. 45 CFR 46.102(e) defines research as “a systematic investigation, including research development, testing and evaluation, designed to develop or contribute to generalizable knowledge; and 45 CFR 46.102(f) defines a human subject as “a living individual about whom an investigator conducting research obtains (i) Obtains information or biospecimens through intervention or interaction with the individual, and uses, studies, or analyzes the information or biospecimens; or (ii) Obtains, uses, studies, analyzes, or generates identifiable private information or identifiable biospecimens. Private information includes information about behavior that occurs in a context in which an individual can reasonably expect that no observation or recording is taking place, and information that has been provided for specific purposes by an individual and that the individual can reasonably expect will not be made public (eg, a medical record).

The UCI Human Research Protections (HRP) staff reviewed the information you submitted pertaining to your project “Vasodilation after spinal cord injury” and concluded that the project, as described, does not qualify as human subjects research because the activities do not constitute research or involve human subjects. Therefore, the activities are not subject to UCI IRB review and approval. If your project changes in ways that may affect this determination, please contact the HRP staff for additional guidance.

Sincerely,

Jessica Sheldon, CIP.

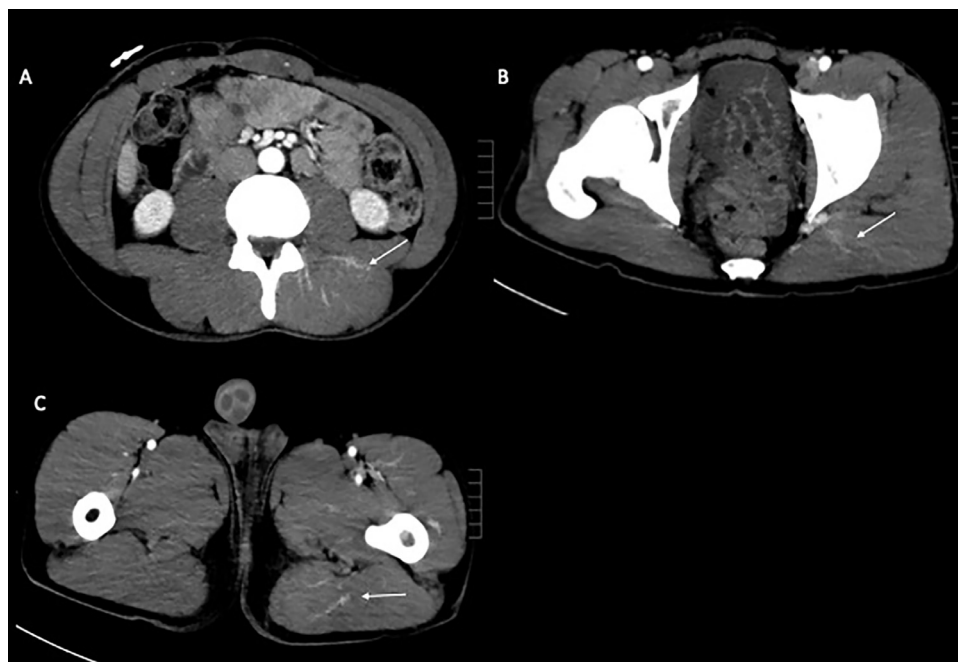
Alternate Member, Institutional Review Board.

\* Corresponding author.

E-mail address: [eleanor.chu@gmail.com](mailto:eleanor.chu@gmail.com) (E. Chu).

<https://doi.org/10.1016/j.radcr.2020.06.005>

1930-0433/© 2020 The Authors. Published by Elsevier Inc. on behalf of University of Washington. This is an open access article under the CC BY-NC-ND license. (<http://creativecommons.org/licenses/by-nc-nd/4.0/>)



**Fig. 1** – Postcontrast axial CT images caudal to the level of penetrating trauma show vasodilation of the (A) left paraspinous muscles, (B) left gluteal muscles, and (C) left lower extremity.

## Introduction

Brown-Sequard Syndrome is a neurologic disorder caused by partial spinal cord injury and disruption of the corticospinal tract, dorsal columns, and spinothalamic tract. We present a case of Brown-Sequard Syndrome with additional injury to the intermediolateral columns resulting in impaired sympathetic tone and peripheral vasodilation.

## Case report

A 32-year-old male was brought to the emergency department following penetrating knife injury to the posterior thorax. The patient complained of left lower extremity numbness and weakness, and right lower extremity burning sensation. Physical exam was significant for left lower extremity paresis, as well as diminished proprioception, touch, and pinprick sensation. The right lower extremity demonstrated intact motor function, and intact proprioception, touch, and pinprick sensation. The patient complained of burning sensation with contact to the right lower extremity.

CT of the abdomen and pelvis demonstrated posterior soft tissue injury with tiny foci of air at the posterior elements of T12. No air, foreign body, or hematoma was seen in the spinal canal on CT. Additionally, CT showed vasodilatation in the left paraspinous, left gluteal, and left leg muscles (Fig. 1). No contrast extravasation was present. MRI of the thoracic spine was subsequently obtained and demonstrated linear T2-hyperintensity in the T11-12 cord (left greater than right) concerning for partial cord transection (Fig. 2).

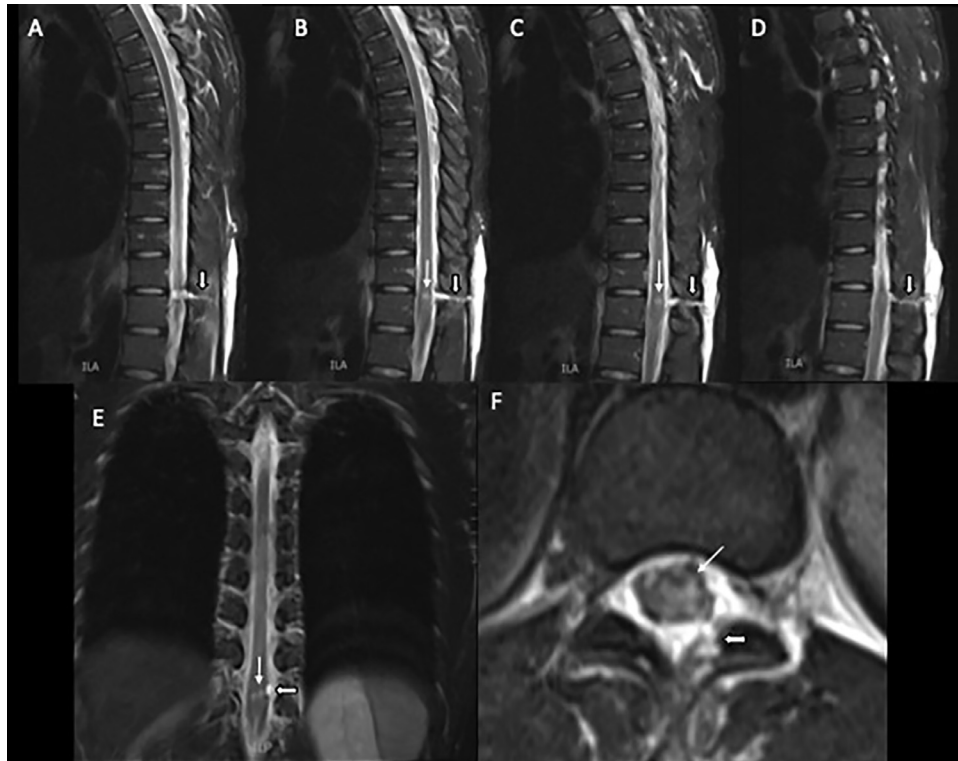
The patient was treated conservatively with pain management, physical therapy, and occupational therapy. He was discharged on hospital day 23 with residual left lower extremity weakness. The patient did not receive further care at our institution and his long-term outcome is unknown.

## Discussion

In 1846, Dr. Brown-Sequard first described ipsilateral loss of motor function, proprioception, and vibration sensation with contralateral loss of pain and temperature sensation below the spinal cord level of injury [1]. In 1868, Dr T. Henry Green reported a case of “Unilateral Hyperemia in Hemiplegia” in The British Medical Journal. In this case report, he cited Dr Brown-Sequard’s subsequent 1863 observations of ipsilateral vasodilatation and temperature elevation in a case of hemiplegia, and ascribed his observation of unilateral hyperemia to vasodilatation [2].

Brown-Sequard syndrome results from hemicord injury [3]. Disruption of the descending lateral corticospinal tract impairs motor function. Disruption of the ascending dorsal columns impairs touch and proprioception. Disruption of the ascending lateral spinothalamic tracts impairs pain and temperature sensation [4]. Spinal cord syndromes, such as Brown-Sequard syndrome, frequently exist in partial or incomplete forms [1].

Injury to the sympathetic nervous system is known to accompany spinal cord injuries, such as those resulting in Brown-Sequard Syndrome [5]. The sympathetic nervous system is part of the efferent limb of the autonomic nervous system controlling the cardiovascular system. The sympathetic



**Fig. 2 – MRI images show T11-12 spinal cord injury (thin white arrow) and fluid/hemorrhage along the knife tract (thick white arrow) on (A-D) sagittal T2 from left to right, (E) coronal T2, and (F) axial T2.**

fibers travel in the bulbospinal tract and synapse with preganglionic neurons in the intermediolateral columns of the spinal cord from T1-L3. These preganglionic axons synapse with the sympathetic chain ganglia, whose postganglionic axons innervate different organ systems [6]. Under normal conditions, activity in the sympathetic nervous system causes vasoconstriction. Impairing sympathetic tone, as with spinal anesthesia or cord injury, causes vasodilatation [6].

Loss of sympathetic vasomotor tone after thoracic spinal cord injury may result in neurogenic shock, which is characterized by loss of neurologic function and autonomic tone below the level of an acute spinal cord lesion [1]. The inciting injury occurs at or above the thoracic level [6], with a higher incidence and increased severity when injuries occur at or above T6 [5]. Disruption of sympathetic innervation results in vasodilatation, bradycardia, and severe hypotension, indicating the body's inability to respond appropriately to decreased systemic vascular resistance with vasoconstriction and tachycardia [7].

Our patient's lower thoracic cord injury spared sympathetic tone to the heart and potential bradycardia and neurogenic shock. His impaired sympathetic tone manifested as ipsilateral peripheral vasodilatation below the level of injury.

This case of Brown-Sequard syndrome demonstrates unilateral peripheral vasodilation due to ipsilateral spinal cord injury and disruption of the sympathetic nervous

system. With this awareness, unilateral vasodilatation on a post-traumatic CT should alert the radiologist to possible ipsilateral spinal cord injury and recommend MRI. To the best of our knowledge, imaging documentation of this phenomenon has not been previously described.

#### REFERENCES

- [1] Marx J. *Rosen's emergency medicine: concepts and clinical practice*. 7th ed. Philadelphia, PA: Mosby Elsevier; 2010. p. 1389–97.
- [2] Green TH. Unilateral Hyperaemia in Hemiplegia. *Br Med J* 1868;2:334–5.
- [3] Lipper MH, Goldstein JH, Do HM. Brown-Sequard syndrome of the cervical spinal cord after chiropractic manipulation. *Am J Neuroradiol* 1998;19:1349–52.
- [4] Yousem DM, Grossman RI. *Neuroradiology: the requisites*. 3rd ed. Philadelphia, PA: Mosby Elsevier; 2010. p. 23–57.
- [5] Issaivanan M, Nhlane NM, Rizvi F, Shukla M, Baldauf MC. Brown-Sequard-plus syndrome because of penetrating trauma in children. *Pediatr Neurol* 2010;43(1):57–60.
- [6] Caldicott L, Lumb A, McCoy D. *Vascular anaesthesia: a practical handbook*. Woburn, MA: Reed Elsevier; 1999. p. 1–32.
- [7] Griffiths MJD, Cordingley JJ, Price S. *Cardiovascular critical care*. Oxford, UK: Wiley-Blackwell; 2010. p. 1–21.