

CASE REPORT

Successful percutaneous extraction of malpositioned pacemaker lead in the left ventricle after proper dabigatran treatment

Maiwand Farouq MD | Rasmus Borgquist MD, PhD | Johan Brandt MD, PhD |
David Mörtzell MD, PhD | Lingwei Wang MD, PhD 

Section of Arrhythmias, Skåne University Hospital & Department of Cardiology, Clinical Sciences, Lund University, Lund, Sweden

Correspondence

Lingwei Wang, Section of Arrhythmias, Skåne University Hospital, Getingevägen 4, SE-221 85 Lund, Sweden.
Email: Lingwei.Wang@med.lu.se

Abstract

Malpositioned pacemaker lead in the left ventricle (LV) is a rare procedural complication, which causes a special risk of thromboembolic events. Hence, prompt identification and early management of misplaced leads inside the LV is critical. Herein, we present a case of malpositioned pacemaker lead with transient ischemic attacks after the pacemaker implantation. The misplaced ventricular lead was discovered during regular echocardiography. Both leads were extracted percutaneously after dabigatran treatment. To our knowledge, this is the first report of uncomplicated percutaneous extraction of an inadvertently placed LV lead after dabigatran treatment. No neurologic events during a follow-up of 4 years.

KEYWORDS

malpositioned pacemaker lead, percutaneous lead extraction, thromboembolic complication

1 | INTRODUCTION

Misplacement of a permanent pacing lead in the left ventricle (LV) is a rare procedural complication of transvenous pacemaker implantation, which causes special risk of thromboembolic events, ranging from mental confusion to cerebrovascular insults with permanent neurologic deficits.¹ Hence, prompt identification and early management of misplaced leads inside the LV is critical. Surgical removal of the lead was often considered to avoid the risk of left-sided endocarditis, ventricle perforation and systemic thromboembolism. Although there have been reports describing transvenous extraction of inadvertently placed LV leads,^{1,2} it remains a debatable approach due to the risk of thromboembolic events during lead removal.³ Direct oral anticoagulants are attractive alternatives for warfarin to treat left atrial (RA) and LV thrombosis.⁴ We report a percutaneous extraction of misplaced pacemaker lead in the LV after proper pre- and post-operative dabiga-

tran treatment without any complications. To our knowledge, this is the first reported such case.

2 | CASE REPORT

The patient is a 62-year-old woman with intermittent dizziness. ECG showed bifascicular block (right bundle branch block (RBBB) and left anterior hemiblock). Under exercise test, second-degree type II AV block developed. A permanent pacemaker was implanted with an atrial lead and a ventricular lead at our hospital in 2015. Routine chest X-ray performed after device implantation showed no pneumothorax (Figure 1), but neither the implanter nor the radiologist reacted to the aberrant anatomic position of the ventricular lead. Three weeks later, the patient contacted the outpatient clinic due to symptoms consisting of irregular heartbeats and pulsations up to the neck.

This is an open access article under the terms of the [Creative Commons Attribution-NonCommercial](https://creativecommons.org/licenses/by-nc/4.0/) License, which permits use, distribution and reproduction in any medium, provided the original work is properly cited and is not used for commercial purposes.

© 2022 The Authors. *Pacing and Clinical Electrophysiology* published by Wiley Periodicals LLC

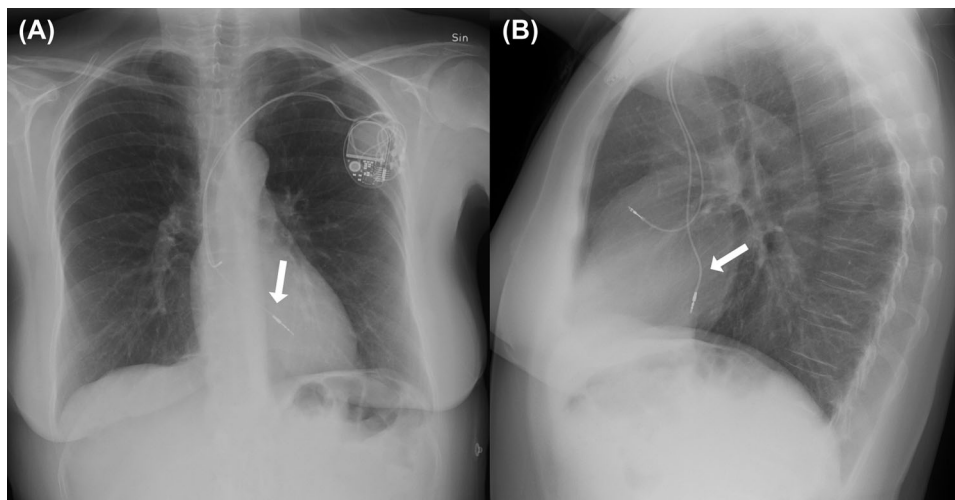


FIGURE 1 Chest X-ray postero-anterior view showing ventricular lead (arrows) superior to usual course (A) and lateral view showing the posteriorly directed ventricular lead (B), indicating position in the left ventricle

Pacemaker interrogation showed 5800 short mode switch episodes which looked like far-field R wave sensing. Higher detection rate of mode switches and a longer PVAB was programmed in the pacemaker. A week later, the patient called and reported the irregular heartbeats and pulsations up to the neck had resolved, but she had suffered 21 short migraine attacks after the operation. The patient also reported an episode when she could not communicate verbally and was absent-minded for approximately 15 min. A new pacemaker interrogation was performed and showed normal findings. Since the patient had a known history of migraine attacks, no further action was taken although she had previously only had migraine attacks 1–2 times per year, and not as severe in nature.

A year later, the patient came to the out-patient clinic. She did not feel well and was very out of breath. She tried to keep going with different activities, but she felt her heart beating fast from time to time and then a pressure over her neck and chest. Pacemaker control showed 9000 short mode switch episodes which again looked like far-field R wave sensing. P sensitivity was lowered in the pacemaker. Six months later, the patient felt that she had become much worse over time, with worsening general weakness and more general discomfort with exertion-induced shortness of breath. She experienced repeated episodes of what could almost be described as aphasia, numbness in the left hand but also a feeling of tingling/rippling in the right forearm radially and down the hand, and sometimes bilateral ailments.

An exercise test was performed, which showed ordinary exercise capacity and no chest pain. There was alternating atrial and ventricular pacing and sinus rhythm both at rest, before and after work. QRS morphology was an atypical RBBB pattern indicating capture of the basal lateral segment of the LV during ventricular pacing (Figure 2).

A transthoracic echocardiography (TTE) was also performed, which clearly demonstrated a ventricular pacing lead originating from the superior aspect of the right atrium, crossing the atrial septum (patent foramen ovale, PFO) into the LA (Figure 3). We reviewed the chest X-

ray again and realized an abnormal position of the ventricular lead, suggesting it was in the left rather than in the right ventricle (Figure 1A,B). Chest X-ray posteroanterior view showed that the ventricular lead had a more superior course than normal (Figure 1A). Chest X-ray lateral view showed a posteriorly directed ventricular lead, suggesting an LV site (Figure 1B).

She was treated with dabigatran 150 mg twice a day immediately after the finding of pacemaker lead LV misposition. A new TTE and a transesophageal echocardiogram (TEE) were performed 1 month after dabigatran treatment, which reconfirmed an endocardial pacemaker lead originating from the RA crossing the atrial septum (PFO) and through the mitral valve into the LV with a mild mitral regurgitation. The presence of any mobile thrombus or fibrous material along pacemaker lead in the LA or LV was meticulously excluded.

Lead extraction was performed under local anesthesia with sedation and prepared for emergency general anesthesia in September 2017, 1 month after initiation of dabigatran treatment. The pacemaker leads were dissected and freed. Regular stylets were used inside the leads. Before the malpositioned lead was extracted, the head side was lowered, and heparin 5000 IU was given intravenously. The lead was slowly extracted with traction alone without complications. A new right atrial and a right ventricular (RV) lead were implanted immediately after lead extraction.

Postoperative computed tomography (CT) scan of the brain showed no new ischemic lesions. Dabigatran 150 mg twice a day was used an additional year after the extraction.

During 4 years of follow-up, the new pacemaker works well. The patient has been feeling well, experiencing no dizziness, no aphasia, no numbness in hands and no paresthesia. No transient ischemic attacks (TIA) or other cerebrovascular events have been observed, and the patient stopped taking oral anticoagulants 3 years ago. Renewed exercise test showed ordinary exercise capacity and adequate ventricular pacing. Closure of the small PFO was not indicated, due to lack of clinical symptoms after the lead extraction.

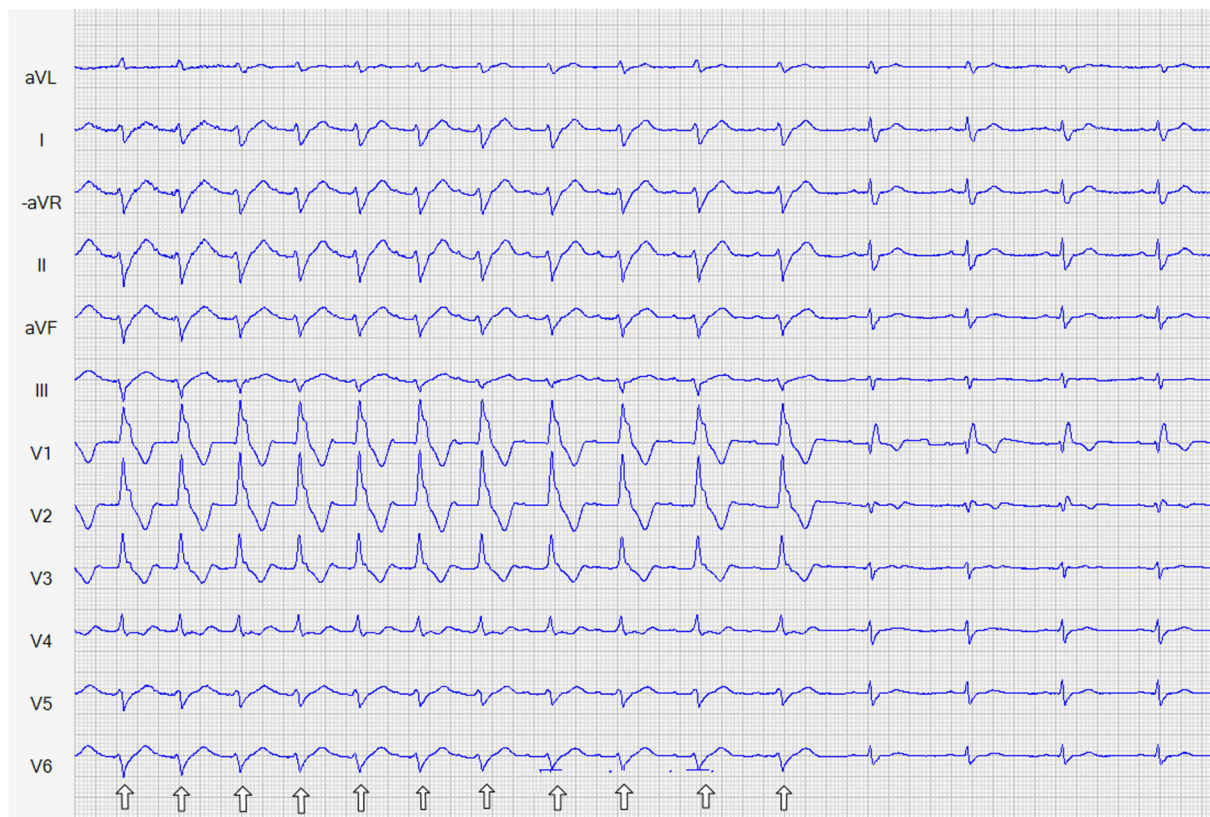

FIGURE 2 ECG during exercise test after implantation showing atrial sensed ventricular pacing with an atypical RBBB configuration of the stimulated QRS complex (arrows show ventricular pacing; the rest were without ventricular pacing) [Color figure can be viewed at wileyonlinelibrary.com]

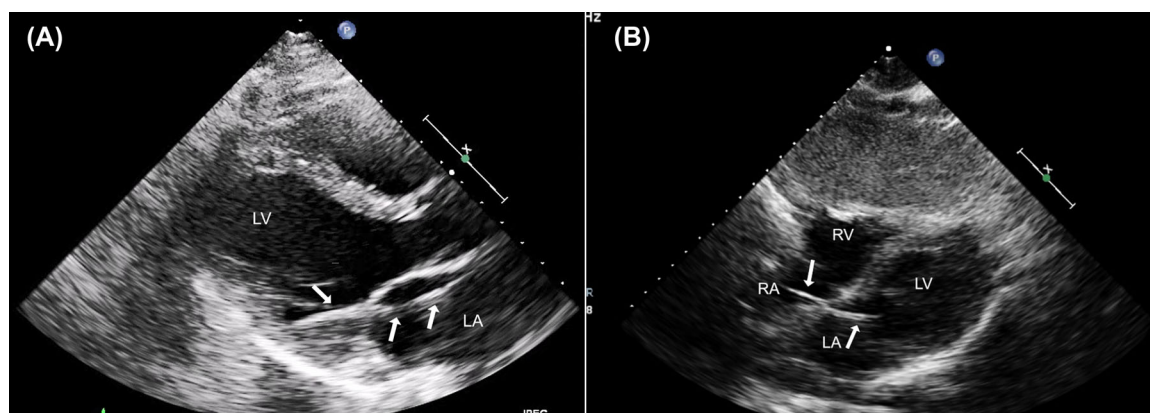


FIGURE 3 Echocardiographic left parasternal view and subcostal view showing a pacing lead (arrows) originating from the RA crossing the atrial septum and mitral valve embedded into the lateral LV wall. LA, Left atrium; LV, Left ventricle; RA, Right atrium; RV, Right ventricle [Color figure can be viewed at wileyonlinelibrary.com]

3 | DISCUSSION

Malpositioned pacing lead in the LV is a rare procedural complication, which was first reported by Stillman and Richards in 1969.⁵ Since then, stimulation of the LV has been reported due to the passage of the pacing lead through an atrial-septum defect, a PFO, or a sinus venosus

defect. Other possibilities include perforation of the inter-ventricular septum, and erroneous introduction of the pacing lead into the subclavian artery and placement in the LV across the aortic valve.⁶ Abnormal thoracic anatomy (e.g., scoliosis), underlying congenital heart disease, and implantation performed by an inexperienced operator could be the predictors of misplaced pacing lead in the LV.⁷

Chest radiography and a 12-lead surface ECG are the sensitive markers for a misplaced pacing lead and are often the first reason for suspicion. TTE and TEE could clearly show a misplaced pacing lead and help to set up diagnosis directly. Chest CT scans and 3D images could also show the lead location accurately and help to differentiate misplaced leads in the coronary sinus, cardiac veins, and the LV.

Chest X-ray, that is routinely performed after device placement in order to rule out pneumothorax, assists in the localization of the misplaced lead. On postero-anterior view, a correctly positioned RV lead has a smooth right lateral course through the RA, with slight bowing at the RV apex giving it a "ballerina foot" like appearance.⁸ On the lateral projection, a correctly positioned RV lead shows that the tip of the lead is located anteriorly. In contrast, the tip of a misplaced LV lead is characteristically to the left and further superior on the postero-anterior view and farther posterior on the lateral view.

An RBBB pattern on a 12-lead surface ECG is a sensitive marker for a misplaced pacing lead in the LV and is often the first reason for suspicion. In our case, there was an RBBB appearance of the QRS complex before pacemaker implantation, while there was an RBBB in QRS both with pacing beats and non-pacing beats during exercise test after pacemaker implantation, which indicated a misplaced pacing lead in the LV.

In our case, however, the radiologist did not recognize the malposition suspicion in the routine chest X-ray and the physician did not mention the RBBB pattern in QRS with pacing beat during exercise test, which might be one of the reasons to delay the diagnosis of lead malposition.

TTE and TEE can also delineate the course of the lead accurately, although the acoustic shadowing may cause echo drop-outs.⁹ With clinical suspicion, TTE and/or TEE can be a very useful tool to distinguish the misplaced pacing lead.

Pacemaker interrogations in our patient also showed frequent occurrence of far field sensing of R wave and mode switch episodes. Far-field R-wave sensing has been identified as the most common cause of inappropriate mode switch in dual chamber pacemakers. However, whether the frequent occurrence of far field sensing of R wave in our case was related to left ventricular pacing is not determined.

A misplaced pacing lead in the LV can be complicated by thromboembolic events,¹⁰ endocarditis, and trauma to the LV wall and/or mitral valve. In our patient, the recurrent TIA was most likely the result of embolism of microthrombi, either formed around the misplaced pacing lead, or coming from the venous circulation and passing through the PFO which most likely was kept more open by the lead passing through it. The patient has not had any new TIA episodes since the lead extraction. Direct oral anticoagulants can potentially be attractive alternatives to warfarin to treat LA and LV thrombosis because of their potential efficacy and safety, their ease of administration, lack of requirement for INR monitoring or dietary restrictions and overall improvement in quality of life.⁴ In our case, dabigatran was used and seemed efficient protection against thromboembolic events and hence enabled extraction of the misplaced LV lead. The choice of dabigatran was made in order to provide the possibility of rapid total reversibility of anticoagulant effect, in the case of bleeding complications during the extraction procedure.

Transvenous lead extraction can be considered because it is a definitive solution for the problem with less trauma. However, perioperative prevention of the thromboembolic event is of critical importance. There may be a risk of dislodging or stripping off thrombotic material from lead manipulation, especially with sheaths advanced over the lead into the left heart chambers during transvenous extraction.^{11,12} In our case, dabigatran treatment pre- and post-operation; immediate preoperative TEE to rule out thrombosis; lowering the head side and giving heparin during operation; and no extraction sheath over the atrial septum to the left heart side, may have contributed the successful transvenous lead extraction without complications. If the pacing lead in the LV has been in place for a long time and a mechanical extraction sheath is needed to get into the left heart, we suggest an arterial cerebral protection system should be used.^{2,3,13}

Lessons we learned from this case are (a) the clinician should correctly recognize the suspicion of lead malposition in the routine chest X-ray after pacemaker implantation and on the ECG with an RBBB pattern in QRS during pacing; (b) if neurologic symptoms present after a device implantation, the case should be screened for proper lead placement; (c) in case that chest X-ray and/or an ECG could not rule out the suspicion of malposition, cardiac CT, TTE and/or TEE should be performed to delineate the course of the lead.

In conclusion, misplacement of RV pacing lead in the LV via a PFO is a rare but possible complication of pacemaker implantation. Dabigatran treatment pre- and post-operation, and no extraction sheath over the atrial septum to the left side, may be essential factors contributing to our successful transvenous LV lead extraction without complications.

ACKNOWLEDGEMENT

The study was partially supported by funding from Eva and Carl-Eric Larsson foundation.

CONFLICT OF INTERESTS

The authors report no conflicts of interest.

ORCID

Lingwei Wang MD, PhD  <https://orcid.org/0000-0003-2014-117X>

REFERENCES

1. Van Gelder BM, Bracke FA, Oto A, et al. Diagnosis and management of inadvertently placed pacing and ICD leads in the left ventricle: a multi-center experience and review of the literature. *Pacing Clin Electrophysiol.* 2000;23:877-883.
2. Kutarski A, Pietura R, Tomaszewski A, Czajkowski M, Boczar K. Transvenous extraction of an eight-year-old ventricular lead accidentally implanted into the left ventricle. *Kardiol Pol.* 2013;71:1317-1321.
3. Bahadorani JN, Schrick AA, Pretorius VG, Birgersdotter-Green U, Dominguez A, Mahmud E. Percutaneous extraction of inadvertently placed left-sided pacemaker leads with complete cerebral embolic protection. *Catheter Cardiovasc Interv.* 2015;86:777-785.
4. Cruz Rodriguez JB, Okajima K, Greenberg BH. Management of left ventricular thrombus: a narrative review. *Ann Transl Med.* 2021;9:520.
5. Stillman MT, Richards AM. Perforation of the interventricular septum by transvenous pacemaker catheter. Diagnosis by change in pattern of depolarization on the electrocardiogram. *Am J Cardiol.* 1969;24:269-273.

6. Hinojos A, Ilg K. Removal of misplaced left ventricular single lead pacemaker in a patient presenting with recurrent transient ischemic attacks. *Spartan Med Res J*. 2017;2:6068.
7. Ohlow MA, Roos M, Lauer B, Von Korn H, Geller JC. Incidence, predictors, and outcome of inadvertent malposition of transvenous pacing or defibrillation lead in the left heart. *Europace*. 2016;18:1049-1054.
8. Singh N, Madan H, Arora YK, et al. Malplacement of endocardial pacemaker lead in the left ventricle. *Med J Armed Forces India*. 2014;70:76-78.
9. Luke P, Shepherd E, Irvine T, Duncan R. Echocardiographic diagnosis of permanent pacemaker lead malposition in the left ventricle: a case study. *Echocardiography*. 2020;37:2163-2167.
10. Osman A, Ahmad A. Saved by anticoagulants: incidental discovery of a misplaced defibrillator lead 6 years after implantation. Inadvertent lead placement inside the left ventricular cavity. *Clin Case Rep*. 2021;9:2445-2448.
11. Anastacio MM, Castillo-Sang M, Lawton JS. Laser extraction of pacemaker lead traversing a patent foramen ovale and the mitral valve. *Ann Thorac Surg*. 2012;94:2125-2127.
12. Arnar DO, Kerber RE. Cerebral embolism resulting from a transvenous pacemaker catheter inadvertently placed in the left ventricle: a report of two cases confirmed by echocardiography. *Echocardiography*. 2001;18:681-684.
13. Harrison JL, Patel R, Jogiya R, Redwood S, Rinaldi CA. Use of a cerebral protection device for the laser extraction of a pacemaker lead traversing a patent foramen ovale. *HeartRhythm Case Rep*. 2017;3:447-449.

How to cite this article: Farouq M, Borgquist R, Brandt J, Mörtzell D, Wang L. Successful percutaneous extraction of malpositioned pacemaker lead in the left ventricle after proper dabigatran treatment. *Pacing Clin Electrophysiol*. 2022;45:1101-1105. <https://doi.org/10.1111/pace.14491>