



## Case report

## A rare case of fibrostenotic endobronchial tuberculosis of trachea



Cassiopia Cary\*, Manjit Jhaggi, John Cinicola, Richard Evans, Pramil Cheriya, Venaka Gorepatti

Pinnacle Health Hospital, USA

## HIGHLIGHTS

- This is the only case of ETBT reported in the US.
- How to diagnose a unusual case of tracheal obstruction.
- How to treat a case of fibrostenotic endobronchial tuberculosis by repeated balloon dilation, and follow up.

## ARTICLE INFO

## Article history:

Received 13 August 2015

Received in revised form

29 September 2015

Accepted 7 October 2015

## Keywords:

Endobronchial tuberculosis

Endotracheal tuberculosis

Pulmonary tuberculosis

Tracheal stenosis

Tracheal web

Stridor

## ABSTRACT

Endobronchial tuberculosis (EBTB) is a sequelae of pulmonary tuberculosis (TB) that extends to the endobronchial or endotracheal wall causing inflammation, edema, ulceration, granulation or fibrosis of mucosa and submucosa. This case depicts a 20 year old foreign-born woman with a history of active pulmonary TB on anti-TB chemotherapy, who presented with worsening stridor, dyspnea, cough and weight loss. The disease state was diagnosed with multiple modalities including, spirometry, CT scan of the neck, and bronchoscopy. The biopsies of the tracheal web revealed fibrotic tissue without any granulomas or malignancy establishing the diagnosis of EBTB. Serial balloon dilations and anti-neoplastic therapy with Mitomycin C was used to accomplish sufficient airway patency to relieve her symptoms. ETBT is a rare consequence of TB, which although has a low incidence in the United States, so physicians should have a high clinical suspicion based on the need for prompt intervention.

© 2015 The Authors. Published by Elsevier Ltd on behalf of IJS Publishing Group Limited. This is an open access article under the CC BY-NC-ND license (<http://creativecommons.org/licenses/by-nc-nd/4.0/>).

## 1. Introduction

Tuberculosis (TB) is relatively a rare disease in the United States with the rate of reported cases of 3.0 cases per 100,000 persons in 2013, which represents a decline of 4.3% compared to 2012. According to Centers of Disease Control and Prevention, 65% of the reported TB cases occurred among foreign-borne persons. Although there have been many case reports and studies in Japan, Korea and India of endobronchial tuberculosis (EBTB), the prevalence of EBTB in the United States is extremely low and no reported cases were discovered upon the literature review. We report a case of EBTB in a young female with active pulmonary TB on antituberculosis chemotherapy who presented with shortness of breath and stridor.

## 2. Case report

A 20 year old Vietnamese female presented to the emergency department (ED) with shortness of breath, cough, hoarseness, and significant weight loss. She was recently diagnosed with active pulmonary TB four months ago, and was started on anti-TB therapy, including Rifampin, Pyridoxine, Pyrazinamide, Isoniazid and Ethambutol. Despite being compliant with the therapy, she frequently presented to ED with dyspnea and was treated with bronchodilators and a short course of steroids for the presumptive diagnosis of reactive airway disease secondary to anxiety (“anxiety asthma”).

On her current presentation, she was afebrile with stable blood pressure of 129/84 mmHg, pulse of 102 beats per min, respiratory rate of 18 breaths per min with 96% saturation on room air. Her physical examination was remarkable for tachycardia. The lung examination revealed labored breathing with the use of accessory muscles, biphasic stridor, diminished breath sounds and mild expiratory wheezes in all lung fields. Laboratory evaluation was unremarkable with normal white blood cell count. Chest X-ray showed focal rounded airspace opacity in the left upper lobe

\* Corresponding author. Pinnacle Health Hospital, 111 S. Front Street, Harrisburg, PA 17101, USA.

E-mail address: [ccary@pinnaclehealth.org](mailto:ccary@pinnaclehealth.org) (C. Cary).

consistent with the previous evaluations. CT-scan of neck revealed previous cavitating lesions in the left apex but no suspicious neck abnormality, mass, collection or adenopathy in the neck soft tissues (Fig. 1). Initially in the ED, she was treated with intravenous methylprednisolone and was placed on albuterol 10 mg/h continuous nebulizer treatments.

She was admitted for an upper airway obstruction secondary to laryngeal edema or vocal cord dysfunction. She was placed on bronchodilator nebulizing treatments as needed and humidified oxygen along with a dose of racemic epinephrine with minimal improvement in her symptoms. Consequently, a direct laryngoscopy was done that was negative for any focal spasm, polyps, edema or vocal cord malfunction. A trial of lorazepam was given to rule out psychogenic stridor caused by emotional stress, that failed to relieve her symptoms. Bronchoscopy revealed 90% occlusion of the trachea with a small pin hole opening and tracheal web approximately 3 cm below the vocal cords (Fig. 3). CT-scan performed at the admission was re-evaluated, which showed the tracheal stenosis that was missed at the initial reading (Fig. 1). Cardiothoracic surgery was consulted at this point for balloon dilation. The biopsies of the tracheal web showed fibrosis but no granulomas or malignant tissue. Following the procedure, she was discharged home two days later in a stable condition with outpatient otorhinolaryngology and cardiothoracic surgery follow up appointments.

Three months later, she presented to the emergency department with similar symptoms associated with fever and chills. Along with antibiotics, a repeat balloon dilation was performed for tracheal stenosis, and she was discharged upon resolution of her symptoms after two days.

Three months after repeat tracheal balloon dilation, she was noticed to have labored breathing associated with chest tightness on her regular otorhinolaryngology follow up visit. The decision was made to perform suspension micro-laryngoscopy with CO<sub>2</sub> laser incision of the tracheal stenosis. Also Mitomycin C, an anti-neoplastic agent, was applied to the area to prevent re-stenosis. She was discharged home in a stable condition after observation and did not have a recurrence of the symptoms again. The biopsy of the tracheal web revealed the same findings. The patient has not returned to the hospital for repeat dilations in twelve months.

### 3. Discussion

In a large prospective study done outside the United States, Jung et al. reported that among the patients with active pulmonary tuberculosis, 50% or more have EBTB [4]. However, our literature search we were unable to find any cases documented in the United States. Due to the rarity of EBTB, and the paucity of the reported cases in the United States, EBTB cases are commonly misdiagnosed as one of the complications of tuberculosis as obstructive pneumonia, obstructive airway disease, such as bronchial asthma [5], or lung cancer [6]. Furthermore, the diagnosis is frequently delayed due to low suspicion of EBTB, since the tracheal stenosis in adult

population in the United States is commonly due to trauma (i.e. intubation), malignancy, lymphadenopathy, or granulation tissue. Lee et al. reported that the incidence of tracheobronchial stenosis is 68% in the first 4–6 months and may rise further if the course of disease is elongated. Also, Jung et al. concluded that the main predictors of concomitant EBTB are female gender and symptom duration of more than 4 weeks. Although the reasons for the female predominance are unclear, some studies have pointed that since females have thinner tracheobronchial lumens, they have weaker expectoration capacity than males, which may make females prone to direct implantation of *Mycobacterium tuberculosis* within the expectorated phlegm from pulmonary focus [16]. Furthermore, Jung et al. reported that the severe bronchostenosis (luminal narrowing of one to two thirds) is more frequent in females than males (37.3% vs 20.7%;  $p = 0.009$ ). These findings are consistent with our case.

The clinical presentation of EBTB is nondistinctive as the common chief complaints include cough, expectoration, hemoptysis, wheezing, fever and feeling short of breath [3]. Our patient presented with dyspnea and stridor, which could be explained by the site of involvement of EBTB. The previous studies have shown that the most common sites for EBTB are right upper lobe and right main bronchus [9], but our patient had a rare presentation of tracheal fibrostenosis, which explains the unique presentation of stridor. Systemic symptoms related to TB such as anorexia, weight loss, and night sweats might not be prominent in EBTB [10]. Pulmonary examination usually shows diminished breath sounds, rhonchi and localized moist rales [3]. The white blood cell count is usually normal as seen in our patient; though lymphocytes might be increased. Some studies have suggested that C-reactive protein is significantly increased and is related to the severity of the disease [11]. Previous case reports and studies have shown that about 10–20% of patients with EBTB have normal chest radiological findings [3]. CT scan may reveal the extent of tracheobronchial lesions, and the location of stenosis, although limited to the expert's ability and experience as seen in our case. This again reinforces the value of maintaining a high index of suspicion for EBTB in a patient with history of pulmonary tuberculosis presenting with obstructive signs and symptoms.

Based to the different classifications of EBTB, patients can have an active sub-type or a fibrotic disease. Both the active form and the fibrostenotic EBTB have markedly different CT findings. Patients with active disease show irregular bronchial luminal narrowing with wall thickening, and enlarged adjacent mediastinal lymph nodes due to hyperplastic changes and inflammatory edema. In contrast, the fibrostenotic subtype of EBTB shows smooth narrowing of the tracheal or bronchial lumen with minimal wall thickening. They also do not have the enlarged adjacent lymph nodes, as seen in our patient. Since the clinical presentation is often misdiagnosed as obstructive phenomenon, previous studies have suggested spirometry to evaluate patient's lung function. The flow-volume loop shows (fixed) blunting of the inspiratory and

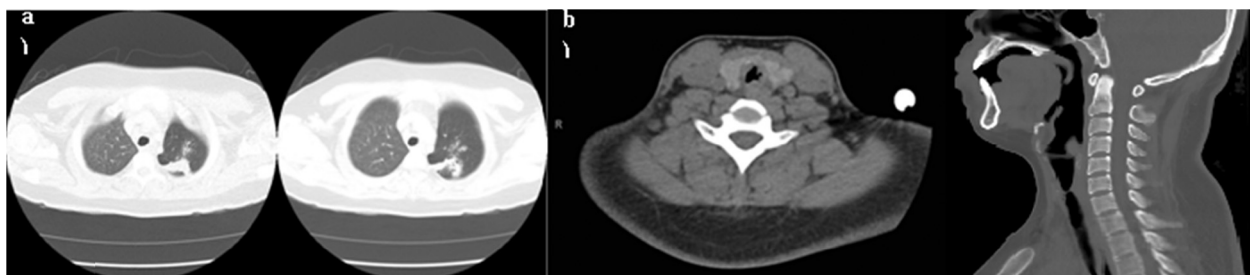
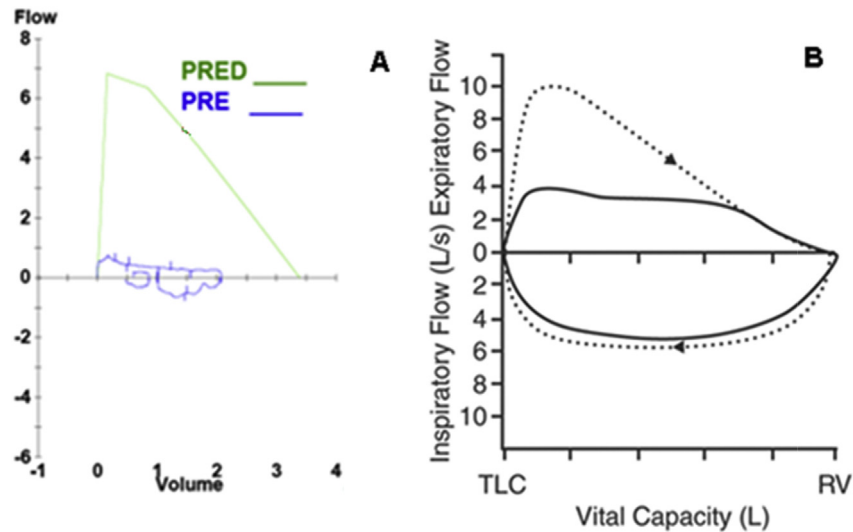
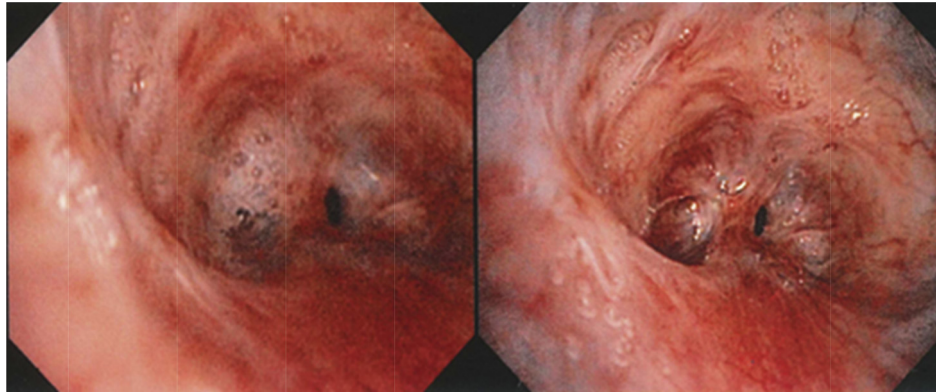


Fig. 1. a) CT-scan of chest showing micro-cavitations in the left upper and lower lobes. b) CT scan of neck showing tracheal narrowing.



**Fig. 2.** A) Spirometry results of our patient showing blunting of both inspiratory and expiratory flow due to fixed tracheal stenosis and poor pulmonary effort. Results showed reduced FVC, FEV1, and FEF 25–75%. B) Flow volume loop showing the typical flattening during inspiration and expiration (solid line) vs the normal flow volume loop (dashed line).



**Fig. 3.** Bronchoscopic appearance of tracheal mucosa. Tracheal mucosa is edematous and hyperemic. Narrowed lumen can be seen with water drop appearance opening and fibrotic tracheal web covering the lumen.

expiratory flow due to a large fixed central airway obstruction as seen in our patient (Fig. 2).

Due to the variability of clinical features associated with the site, extent of involvement, and the stage of the disease, bronchoscopy is the main stay to diagnose and classify the disease. According to Chung classification, EBTB is classified into 7 subtypes by bronchoscopy findings: actively caseating, edematous-hyperemic, fibrostenotic, tumorous, granular, ulcerative, and nonspecific bronchitic. Bronchoscopy findings in our patient showed marked narrowing of tracheal lumen with fibrosis [1]. As Chung et al. study showed EBTB lesions usually does not involve the bronchial mucosa circularly. The normal mucosa is partly spared, which gives the appearance of a “crushed water drop shape” as seen in our patient. Furthermore, demonstrating the presumptive natural course of the disease and the predictive value of this classification after the treatment, the prospective study concluded that once the diagnosis of EBTB is established, bronchoscopy should be performed every month for the first 2 to 3 months of treatment since one subtype may transform into another. Previous studies have shown that fibrostenotic stage is preceded by the formation of granulation tissue [12], and severe stenosis is inevitable despite efficacious antituberculosis chemotherapy once fibrostenosis is developed [7,8]. The tracheal web biopsies didn't reveal any granulation tissue

in our case, which indicates that the disease had progressed to an advanced irreversible stage of fibrosis that may only respond to aggressive interventional modalities such as balloon dilation, electrocautery, stent insertion or laser therapy [13]. Stenotic lesions often require repeated dilations [10]. In addition to serial balloon dilations, anti-neoplastic agents were required in our case. This is consistent with the recent research studies that showed an increased activity of matrix metalloproteinases-1, interferon-gamma and transforming growth factor-beta within the EBTB lesions that may favour the development of fibrostenosis [14,15].

#### 4. Conclusion

Due to the declining incidence of tuberculosis in the United States, physicians may be reluctant to entertain the diagnosis of EBTB initially. The significant morbidity and potential mortality associated with the irreversible fibrostenotic stage of the disease requires early diagnosis and treatment. It is well established that the single most important component to the diagnosis of EBTB is a high index of suspicion and prompt performance of bronchoscopy. A closer attention needs to be devoted to identify EBTB in TB non-endemic regions when a foreign-borne person presents with obstructive symptoms and concomitant history of pulmonary

tuberculosis.

### Ethical approval

None.

### Sources of funding

None.

### Author contribution

All listed as authors.

### Conflicts of interest

None.

### Guarantor

Cassiochia Cary, MD.

### References

- [1] J.H. Lee, S.S. Park, D.H. Lee, et al., Endobronchial tuberculosis. Clinical and bronchoscopic features in 121 cases, *Chest* 102 (4) (1992) 990–994.
- [2] Q. Xue, N. Wang, X. Xue, et al., Endobronchial tuberculosis: an overview, *Eur. J. Clin. Microbiol. Infect. Dis.* 30 (2011) 1039–1044.
- [3] S.S. Jung, H.S. Park, J.U. Kim, et al., Incidence and clinical predictors of endobronchial tuberculosis in patients with pulmonary tuberculosis, *Respirology* 20 (2015) 488–495.
- [4] D.J. Williams, E.L. York, E.J. Nobert, et al., Endobronchial tuberculosis presenting as asthma, *Chest* 93 (1988) 836–838.
- [5] H.S. Chung, J.H. Lee, Bronchoscopic assessment of the evolution of endobronchial tuberculosis, *Chest* 117 (2000) 385–392.
- [6] G. Hoheisel, B.K. Chan, C.H. Chan, et al., Endobronchial tuberculosis: diagnostic features and therapeutic outcome, *Respir. Med.* 88 (1994) 593–597.
- [7] J.W. Park, B.W. Choi, S.H. Hue, Prospective study of corticosteroid as an adjunct in the treatment of endobronchial tuberculosis in adults, *Respirology* 2 (1997) 275–281.
- [8] A. Aneja, U.M. Krishnaswamy, V. Thyagaraj, et al., Endobronchial Tuberculosis: Two Case Reports And Review of The Literature. *Case Reports in Pulmonology*, 2014, pp. 1–4. Article ID 283972.
- [9] P.M. Van den Brande, F. Van de Mierop, E.K. Verbeken, et al., Clinical spectrum of endobronchial tuberculosis in elderly patients, *Arch. Intern. Med.* 150 (1990) 2105–2108.
- [10] A. Omer, A. Metin, S. Leyla, et al., The diagnostic value of bronchoscopy in smear negative cases with pulmonary tuberculosis, *Tuberk. Toraks.* 56 (2008) 150–157.
- [11] L.S. Smith, R.F. Schillaci, R.F. Sarlin, Endobronchial tuberculosis: serial fiberoptic bronchoscopy and natural history, *Chest* (1987) 91644–91647.
- [12] S. Sawada, Y. Fujiwara, S. Furui, et al., Treatment of tuberculosis bronchial stents with expandable metallic stents, *Acta Radiol.* 34 (1993) 263–265.
- [13] H.P. Kuo, Y.M. Wang, C.H. Wang, et al., Matrix metalloproteinase-1 polymorphism in Taiwanese patients with endobronchial tuberculosis, *Tuberculosis* 88 (2008) 262–267.
- [14] Y. Kim, K. Kim, J. Joe, et al., Changes in the levels of interferon-gamma and transforming growth factors-beta influence bronchial stenosis during the treatment of endobronchial tuberculosis, *Repression* 74 (2007) 202–207.
- [15] H.C. Kim, H.S. Kim, S.J. Lee, et al., Endobronchial tuberculosis presenting as right middle lobe syndrome: clinical characteristics and bronchoscopic findings in 22 cases, *Korean J. Med.* 49 (2008) 615–619.