

Short paper

Open Access

## Lymphadenovarix in the axilla – an unusual presentation of filariasis

Adhish Basu\*<sup>1</sup>, Sarath Chandra Sistla<sup>†1</sup>, Surendra Kumar Verma<sup>†2</sup> and S Jagdish<sup>†1</sup>

Address: <sup>1</sup>Department of Surgery, Jawaharlal Institute of Postgraduate Medical Education and Research, Pondicherry, India and <sup>2</sup>Department of Pathology, Jawaharlal Institute of Postgraduate Medical Education and Research, Pondicherry, India

Email: Adhish Basu\* - adhishbasu@rediffmail.com; Sarath Chandra Sistla - sarathsistla@hotmail.com; Surendra Kumar Verma - skverma60@satyam.net.in; S Jagdish - sjagdishjipmer@yahoo.co.in

\* Corresponding author †Equal contributors

Published: 30 July 2006

Received: 17 October 2004

Filaria Journal 2006, 5:9 doi:10.1186/1475-2883-5-9

Accepted: 30 July 2006

This article is available from: <http://www.filariajournal.com/content/5/1/9>

© 2006 Basu et al; licensee BioMed Central Ltd.

This is an Open Access article distributed under the terms of the Creative Commons Attribution License (<http://creativecommons.org/licenses/by/2.0>), which permits unrestricted use, distribution, and reproduction in any medium, provided the original work is properly cited.

### Abstract

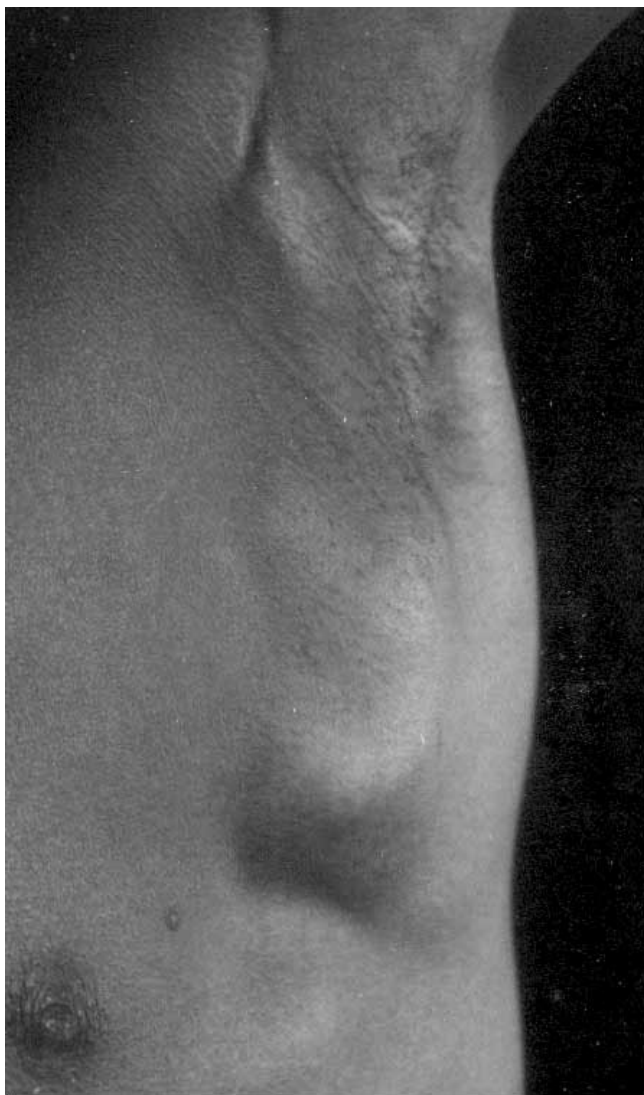Clinical manifestations of lymphatic filariasis depend on the area of lymphatic involvement and the duration of infection. A 21 year old man, resident in a filariasis endemic region, presented with multiple matted lymph nodes with cystic areas forming a large mass in his left axilla. An ultrasound scan of the axilla using a 7.5 MHz transducer revealed grossly dilated lymphatics but no filarial dance sign. Fine needle (21 G) aspiration cytology (FNAC) from the dilated lymphatics and solid areas in the lymph node mass revealed multiple microfilariae in a background of reactive lymphoid cells. Peripheral blood smears revealed microfilaremia with significant eosinophilia. Diagnosis of left axillary *Bancroftian lymphadenovarix* was made. On the administration of oral diethylcarbamazine, the diameter of the lymphatic vessels in the lymphadenovarix reduced considerably in size and microfilaremia disappeared. We report this case because axillary lymphadenovarix is a rare presentation of filariasis. This case is also unique since microfilariae were demonstrated in the fluid aspirated from the dilated lymphatics of the lymphadenovarix in the absence of live adult worms.

### Introduction

Lymphatic filariasis is a major health problem in India especially in its southern provinces. A majority of the infected individuals in filariasis endemic communities are asymptomatic. Adult worms in the lymphatics cause progressive lymphatic vascular dilation and dysfunction [1]. Progressive lymphatic dysfunction usually presents as lower limb lymphoedema, hydrocele, chyluria or rarely groin lymphadenovarix [2]. Axillary lymphadenovarix is an extremely uncommon presentation of filariasis even in endemic communities. We thus present a case of filarial lymphadenovarix of the axilla which was successfully treated with diethylcarbamazine.

### Case report

A 21 year old presented in July 2004 complaining of a large painless lump in the left arm pit which he reported as a problem of six months duration. He was a manual laborer working from Tamil Nadu, India. He had no history of episodic fever, cough, weight loss, swelling of the left upper extremity or any lumps elsewhere in the body. Clinical examination revealed a mobile and non-tender mass of matted lymph nodes measuring 5 cm × 5 cm with heterogeneous (soft to firm) consistency with some cystic areas, in the central part of the left axilla (Figure 1). No other lymph node groups were significantly enlarged. External genitalia were normal. General examination revealed no other abnormalities. A clinical diagnosis of tubercular axillary lymphadenitis was entertained.



**Figure 1**  
Left axillary mass at presentation.

A chest x-ray was unremarkable. There was no evidence of leucocytosis, eosinophilia or parasites in his venous blood, sampled during the day. Routine and microscopic examination of the urine was within normal limits. Fine needle (21 G) aspiration cytology from the axillary mass revealed a scanty aspirate, smears from which showed features suggestive of reactive lymphoid hyperplasia.

An ultrasound scan of the left axilla in real-time B-mode and M-mode was carried out by an experienced sonologist in the presence of one of the authors (AB) with a Toshiba (Justvision 400) ultrasound machine (Toshiba Medical System Corporation, Togichi, Japan) and a 7.5 MHz linear phased array transducer. The scan revealed a lobulated heterogeneous soft tissue mass of size 5.5 cm × 4.5 cm ×

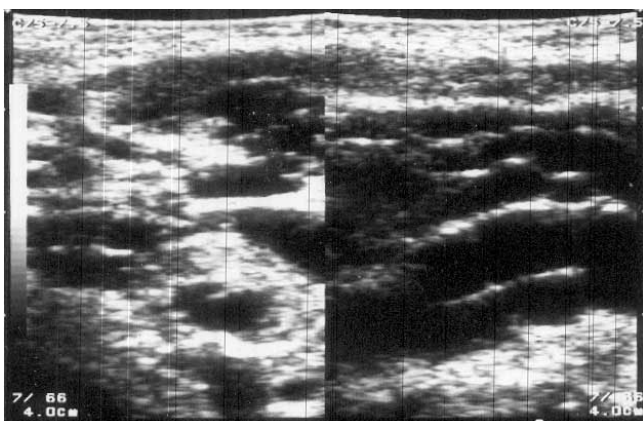
5.0 cm. The mass consisted of solid hypoechoic areas (each 2 cm × 1 cm) with multiple dilated tortuous anechoic channels (suggestive of grossly dilated lymphatics) of varying diameter (7 mm to 10 mm). There was no evidence of calcification or the typical filarial dance sign of *Wuchereria bancrofti* inside the dilated channels (Figure 2). A sonographic diagnosis of the left axillary lymphadenopathy with lymphangiectasia was made. Fine needle aspiration cytology from the dilated lymphatics and the solid areas was then performed and microscopic examination of which revealed multiple microfilariae of *Wuchereria bancrofti* in a background of reactive lymphoid cells (Figure 3). A scrotal ultrasound scan was not done as the external genitalia were normal.

A nocturnal venous blood smear examination (three weeks after presentation) showed eosinophilia but failed to show any microfilaria. The absolute eosinophil count was 2520/mm<sup>3</sup>. A thick venous blood smear examination taken one hour after the administration of 100 mg oral diethylcarbamazine (in the daytime) (DEC provocation test) revealed numerous typical microfilariae of *Wuchereria bancrofti* (Figure 4). The microfilarial density however, was not determined.

The patient then received oral diethylcarbamazine (100 mg q8 h) for 3 weeks. In October 2004 the size of the axillary mass and diameter of the lymphatic vessels had reduced in size considerably. This was confirmed by a repeat ultrasound examination of the left axilla (performed by the same sonologist using the same ultrasound machine), which revealed a heterogeneous soft tissue mass of 3.0 cm × 3.0 cm × 4.5 cm with dilated tortuous lymphatic channels, diameter less than 5 mm (Figure 5). The patient had no other symptoms or signs attributable to filariasis. No scrotal nodules developed during the period of treatment. Repeated microscopic examinations of thick smears of the patient's venous blood taken at night yielded no microfilaria. Membrane filtration concentration technique for detection of microfilaria was not used.

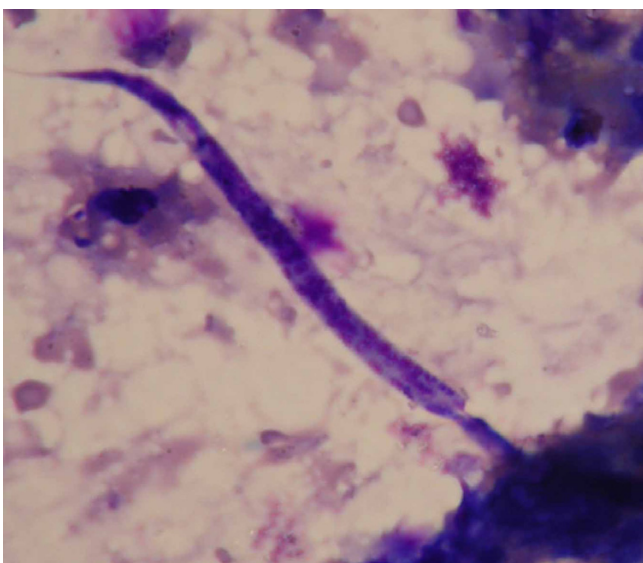
## Discussion

Lymphatic filariasis is a major health problem in India with most infections caused by *Wuchereria bancrofti*. The presence of adult worms of *Wuchereria bancrofti* in the infected individuals is confirmed by detecting microfilariae or filarial antigens in the patient's blood [3]. Ultrasound scans (B-mode and M-mode) with or without colour Doppler or pulse wave Doppler have been used to detect living adult *W. bancrofti* (filarial dance sign) in dilated intrascrotal juxtatesticular lymphatics (worm nests) of approximately 80% of microfilaremic but asymptomatic men residing in endemic areas [4]. In individuals from endemic regions, with no sonologically

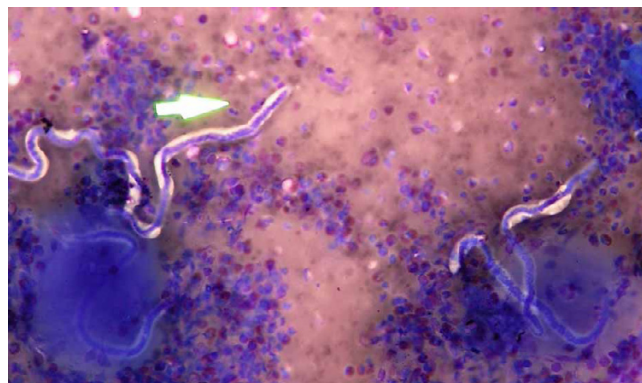


**Figure 2**  
 Ultrasound scan of axilla at presentation showing grossly distended lymphatics (in longitudinal and transverse axis).

detectable worms or microfilariaemia, the presence of dilated lymphatics in the scrotum has been shown to be due to occult adult worms in those lymphatics [1]. In these individuals treatment with diethylcarbamazine has led to the formation of scrotal nodules, histological examination revealing dead adult worms [3]. Microscopic examination of fine needle aspirates from dilated lymphatics harboring adult worms in symptomatic patients has also revealed microfilariae [5]. Similarly, microscopic examination of lymph node biopsies revealed microfilaria with an adult worm in the same lymphatic vessel in



**Figure 3**  
 FNAC showing microfilariae of *Wuchereria bancrofti* in a background of reactive lymphoid cells.

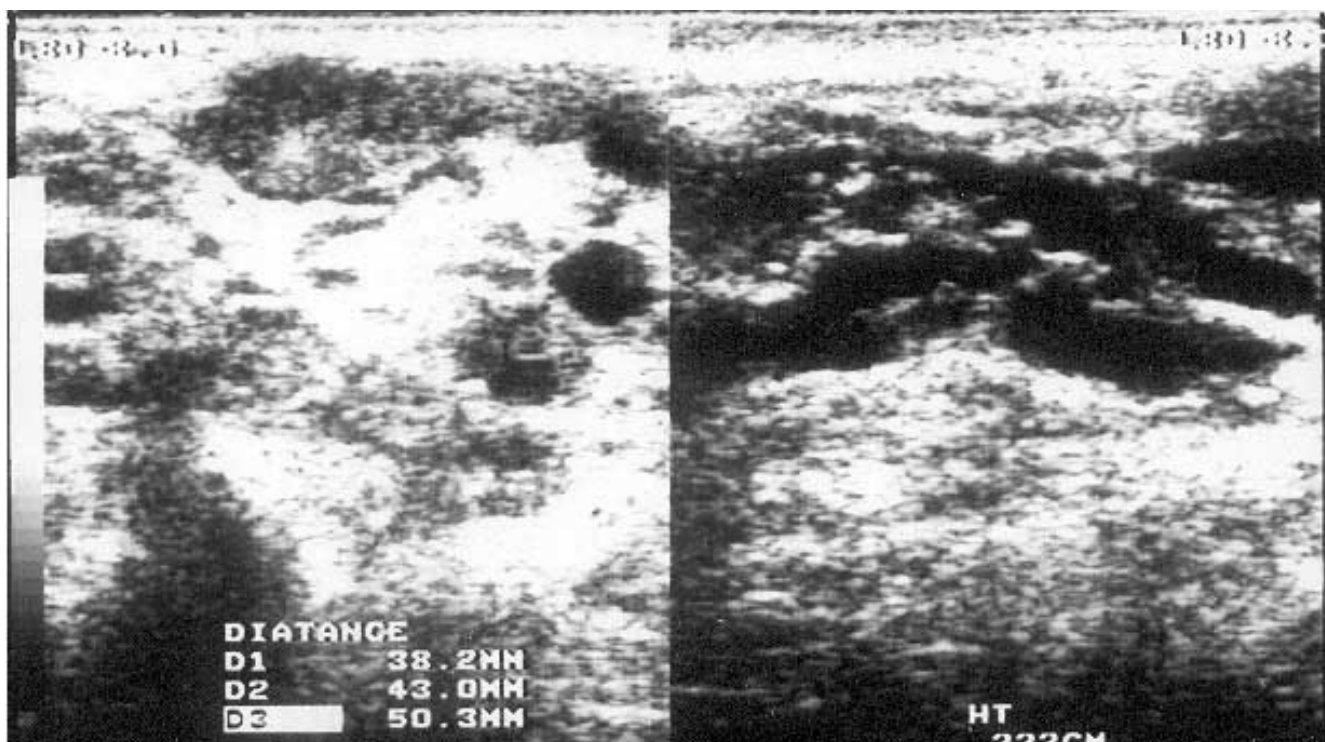


**Figure 4**  
 Peripheral blood smear showing microfilariaemia and eosinophilia.

one case [6]. However, to the best of our knowledge there are no reports of fine needle aspirates from dilated lymphatics without detectable adult worms revealing microfilariae on microscopy.

The diagnosis of a filarial infection can also be made by detecting microfilariae on microscopic examination of fine needle aspirates from lymph nodes [7,8]. Fine needle aspiration cytology from breast mass, thyroid mass, hydrocoele fluid, pericardial fluid, pleural fluid, ascitic fluid, and cytology of cervicovaginal smears, bronchial aspirates, urine, nipple secretion, bone marrow and joint fluid aspirates have also been reported to yield microfilariae [9,10]. Moreover, in these patients the peripheral smears rarely revealed microfilariaemia or eosinophilia [9,10].

Our case appears unique for a number of reasons. Firstly, filarial lymphangiectasia presenting as a visible lump (lymphadenovarix) in the axilla is rare. Secondly, the ultrasound scan of the lump did not identify any adult worm(s) in the axilla in spite of significant lymphangiectasia. The absence of worms in the lymphatics on the ultrasound does not, however, rule out their presence in the deeper lymphatics of the axilla. Interestingly, the filarial dance sign has not been detected in the axillary lymphatics of asymptomatic amicrofilaraemic individuals residing in a filariasis endemic region of South India [11]. Thirdly, ultrasound guided aspiration from the dilated lymphatics in the lymphadenovarix yielded microfilariae indicating the presence of adult gravid female worms in nearby lymphatics. Finally, the diameter of the lymphatic vessels reduced significantly and microfilariae disappeared from the blood following treatment with diethylcarbamazine. The effects of diethylcarbamazine on adult worms has been assessed by the absence of microfilariaemia and the filarial dance sign on the scrotal ultrasound [5].



**Figure 5**  
Ultrasound scan of axilla after therapy showing collapsed lymphatics (in longitudinal and transverse axis).

Lymphatic vessel dilation however, is not reported to regress after death of the adult worms [1] but in this patient a dramatic reduction in the size of the lymphatics was observed following treatment.

In conclusion, although scrotal lymphatics are the preferred location for adult *W. bancrofti*, axillary lymphatics may also be affected. The host-parasite interaction in these lymphatics may be different from those in the scrotal lymphatics. This may explain the formation of a lymphadenovarix in the axilla and also the dramatic response to diethylcarbamazine in our patient. The authors recommend an ultrasound guided aspiration of fluid from dilated lymphatics of similar lesions in microfilaremic patients from filariasis endemic areas.

#### Competing interests

The author(s) declare that they have no competing interests.

#### Authors' contributions

AB drafted the manuscript with the help of SCS, SKV and SJ. AB, SCS and SJ conceived and designed the study. AB, SCS and SKV were involved in the acquisition of the data. All authors were involved in analysis and interpretation of the data. All authors read and approved the final manuscript.

#### Acknowledgements

The authors would like to acknowledge Dr. G. Jayaraman, Department of Radiology, JIPMER for providing them with the ultrasound images.

#### References

1. Dreyer G, Addiss D, Roberts J, Noroes J: **Progression of lymphatic vessel dilatation in the presence of living adult *Wuchereria bancrofti*.** *Trans R Soc Trop Med Hyg* 2002, **96**:157-161.
2. Sen SB, Chatterjee H, Ramaprasad S: **Chylous manifestations of filariasis: A clinical and lymphographic study. Part II. Lymphadenovarix, chylocele and chylous scrotum.** *Ind Jour Med Res* 1969, **57**:1738-1744.
3. Dreyer G, Santos A, Noroes J, Addiss D: **Proposed panel of diagnostic criteria, including the use of ultrasound, to refine the concept of 'endemic normals' in lymphatic filariasis.** *Tropical Medicine and International Health* 1999, **4**:575-579.
4. Noroes J, Addiss D, Amaral F, Coutinho A, Medeiros Z, Dreyer G: **Occurrence of adult *Wuchereria bancrofti* in the scrotal area of men with microfilaremia.** *Trans R Soc Trop Med Hyg* 1996, **90**:55-56.
5. Chaubal NG, Pradhan GM, Chaubal JN, Ramani SK: **Dance of live adult Filarial worms is a reliable sign of scrotal Filarial infection.** *J Ultrasound Med* 2003, **22**:765-769.
6. Jungmann P, Figueredo-Silva J, Dreyer G: **Bancroftian lymphadenopathy: a histopathologic study of fifty-eight cases from northeastern Brazil.** *Am J Trop Med Hyg* 1991, **45**:325-31.
7. Dey P, Radhika S, Jain A: **Microfilariae of *Wuchereria bancrofti* in a lymph node aspirate. A case report.** *Acta Cytol* 1993, **37**:745-746.
8. Kapila K, Verma K: **Diagnosis of parasites in fine needle breast aspirates.** *Acta Cytol* 1996, **40**:653-656.
9. Varghese TR, Raghuvver CV, Pai MR, Bansal R: **Microfilariae in Cytologic Smears. A Report of Six Cases.** *Acta Cytol* 1996, **40**:299-301.
10. Walter A, Hemalatha K, Cariappa A: **Microfilariae of *Wuchereria bancrofti* in cytologic smears.** *Acta Cytol* 1983, **4**:432-436.

11. Reddy GS, Das LK, Pani SP: **The preferential site of adult *Wuchereria bancrofti*: an ultrasound study of male asymptomatic microfilaria carriers in Pondicherry, India.** *Natl Med J India* 2004, **17**:195-196.

Publish with **BioMed Central** and every scientist can read your work free of charge

*"BioMed Central will be the most significant development for disseminating the results of biomedical research in our lifetime."*

Sir Paul Nurse, Cancer Research UK

Your research papers will be:

- available free of charge to the entire biomedical community
- peer reviewed and published immediately upon acceptance
- cited in PubMed and archived on PubMed Central
- yours — you keep the copyright

Submit your manuscript here:  
[http://www.biomedcentral.com/info/publishing\\_adv.asp](http://www.biomedcentral.com/info/publishing_adv.asp)

