

**Received:** 2012.05.12  
**Accepted:** 2012.06.13  
**Published:** 2012.07.10

## Right upper lobe atelectasis after tracheal extubation in a morbidly obese patient

**Sinan Uzman, Mehmet Toptaş, Tumay Uludag Yanaral**

Department of Anesthesiology and Reanimation, Haseki Training and Research Hospital, Istanbul, Turkey

### Summary

**Background:**

Acute lobar collapse caused by a reflex bronchoconstriction was previously reported to occur during the induction of anesthesia, however there are no reports on its occurrence during the emergence period.

**Case Report:**

A 56-year-old morbidly obese woman was scheduled for surgery due to a gastric ulcer perforation. Anesthesia was induced with thiopental 500 mg, fentanyl and rocuronium, and maintained with sevoflurane in a N<sub>2</sub>O/O<sub>2</sub> mixture. The operative procedure and anesthesia were uneventful; however, the patient developed a sudden decrease in SaO<sub>2</sub> and blurring of consciousness after extubation. She was re-intubated and ventilated with 100% O<sub>2</sub>. Arterial blood gas analysis at that time showed respiratory acidosis and hypoxemia. Further work-up revealed a bronchospasm-induced right upper lobe atelectasis, which occurred immediately after tracheal extubation. The patient was successfully treated using mechanical ventilation and bronchodilators.

**Conclusions:**

Bronchospasm may cause acute lobar atelectasis immediately after tracheal extubation. Morbid obesity and the use of 100% oxygen may facilitate atelectasis formation during emergence from anesthesia.

**key words:**

postoperative pulmonary atelectasis • bronchial spasm • anesthesia/general • obesity/morbid

**Full-text PDF:**

<http://www.amjcaserep.com/fulltxt.php?ICID=883243>

**Word count:**

1078

**Tables:**

–

**Figures:**

2

**References:**

10

**Author's address:**

Sinan Uzman, Ali Nihat Tarlan C. No: 50/C Da: 21 Bostanci, Istanbul, Turkey, e-mail: drsinanuzman@yahoo.com

## BACKGROUND

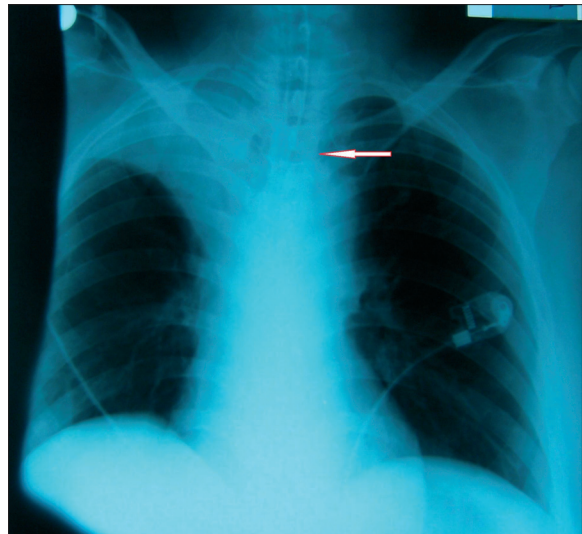
Stimulation of the airways by an endotracheal tube, suction catheter or secretion may trigger a reflex bronchoconstriction that can result in atelectasis. Acute lobar collapse due to reflex bronchoconstriction is a rare entity, and although its development during induction of anesthesia has been reported previously, there are no reports on its occurrence during emergence from anesthesia [1–3]. In this report we present a morbidly obese patient with right upper lobe (RUL) atelectasis, which developed immediately after tracheal extubation in an emergency laparotomy procedure.

## CASE REPORT

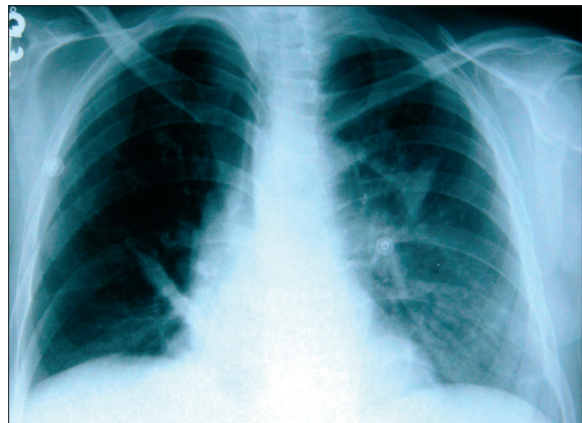
A 56-year-old woman with BMI=41 (160 cm height and 105 kg weight) was diagnosed with gastric ulcer perforation and was scheduled for emergency surgery. There were no pathologic findings on physical examination except for tenderness with guarding and rebound at the upper abdomen. She had no history of asthma or drug allergies. Routine laboratory investigations were performed. Leukocyte count was 16,000 1/mL. Other investigations including blood count, coagulation and biochemical tests were within normal limits. ECG was normal, and chest radiograph demonstrated free gas under both hemidiaphragms.

Anesthesia was induced with 500 mg thiopental, 100 µg fentanyl, and 60 mg rocuronium. Intubation was performed with a 7.5 mm cuffed endotracheal tube, secured between the lips at 20 cm. Equal breathing sounds were auscultated in both lung fields. Anesthesia was maintained using sevoflurane with end-tidal of 1.5–2% in a N<sub>2</sub>O/oxygen mixture and inspired oxygen fraction at 0.4. The operation and anesthesia were uneventful. At the end of the surgical procedure, inhalation anesthetics were stopped and the patient was ventilated manually with 100% O<sub>2</sub> for 3 minutes. Neuromuscular recovery was facilitated with intravenous injection of 2.5 mg neostigmine and 1.25 mg atropine. The patient was extubated with endotracheal suctioning when her spontaneous breathing was sufficient.

A few minutes after extubation, the SaO<sub>2</sub> decreased from 100% to 82% and the right side of the chest ceased to rise with inspiration. Breath sounds on auscultation were diminished on the right side of the chest, and wheezing was heard. Because of the sudden decrease in SaO<sub>2</sub> and blurring of consciousness, she was re-intubated and ventilated 100% O<sub>2</sub>. Arterial blood gas analysis taken at this time revealed respiratory acidosis and hypoxemia (pH: 7.27, Pco<sub>2</sub>: 50 mm Hg, Po<sub>2</sub>: 62 mm Hg, SaO<sub>2</sub>: 87%, HCO<sub>3</sub>: 21 mmol/L, base excess: –3.2 mmol/L). Bronchospasm was diagnosed and the patient was transferred to the intensive care unit (ICU). Pressure-controlled ventilation with PEEP (8 cm H<sub>2</sub>O) was started. Aerosolized salbutamol was administered by inhalation, and 150 mg of methylprednisolone and 100 mg of aminophylline were given intravenously, followed by intravenous aminophylline infusion at 0.2 mg/kg/min. Chest roentgenogram showed right upper lobe atelectasis (Figure 1). Fiberoptic bronchoscopy showed that the tracheobronchial tree had no mucous or foreign body obstructions. Repeat chest X-ray taken 1 hour later revealed full re-expansion of the collapsed RUL (Figure 2), and the patient was subsequently extubated. Her arterial blood gas



**Figure 1.** Right upper lobe atelectasis (arrow: the tip of tracheal tube).



**Figure 2.** After the treatment.

values and breathing sounds returned to normal. The patient was discharged from the ICU on the following day without any complications.

## DISCUSSION

Atelectasis is a major cause of impaired oxygenation in patients under anesthesia, and may occur during induction or maintenance. One of the mechanisms of atelectasis is the obstruction of a bronchus by excessive mucus, aspiration, or bronchoconstriction. After complete airway occlusion, a pocket of gas is trapped in the lung unit distal to the obstruction, and absorption of gas behind the occluded airway may result in a pulmonary collapse [4]. Fiberoptic bronchoscopy in our patient did not show any mucous plugs, obstruction or foreign bodies in the trachea or the right and left endobronchial system.

Stimulation of the airways may cause vagally-induced bronchoconstriction with subsequent reflex atelectasis. This is characterized by a rapid onset, absence of intrabronchial obstruction, and signs of parasympathetic stimulation. There are only a few reports on collapse of the RUL after bronchospasm, and these have occurred during the induction or maintenance of anesthesia [2,3,5,6]. In our patient,

however, atelectasis developed immediately after extubation. Reflex bronchospasm can be triggered by inadvertent extubation and tracheal aspiration, or by the presence of excessive secretion in the airways. Bronchospasm is more frequent during induction or maintenance compared to the emergence and recovery from anesthesia because of various factors such as induction agents [1]. This may also explain in part why reflex atelectasis develops more frequently during this period.

Review of the literature shows that acute lobar collapse associated with bronchospasm mostly involves the RUL in anesthetized patients [2,3,6]. It has been postulated that the relatively straight right mainstem bronchus and an almost 90° take-off in the RUL bronchus may create a favorable condition for the Bernoulli effect around the opening of the RUL bronchus [7]. As seen in this patient, increased airway resistance related to the bronchospasm might have caused rapid laminar flow in the trachea, and therefore directed the airflow toward the right lower and middle lobes, bypassing the RUL bronchus. Previous case reports also suggest this mechanism [2,3].

It has been shown that morbidly obese patients (MO) have a greater risk of atelectasis during general anesthesia than nonobese patients [8]. This is related to more marked reduction in respiratory system compliance and functional residual capacity, and increased airway resistance [9]. Eichenberger et al. [8] have demonstrated that the percentage of pulmonary atelectasis was significantly higher in morbidly obese patients than in nonobese patients before anesthesia induction and after tracheal extubation. In addition, atelectasis persisted in the postoperative period for at least 24 hours in MO patients. In our patient, morbid obesity might have contributed to development of acute RUL atelectasis by increasing airway resistance.

Benoit et al. [10] showed that the use of 100% oxygen at the end of general anesthesia facilitates postoperative atelectasis formation. Inspired oxygen fraction of 1.0 is associated with an increased rate of gas absorption from the unventilated alveoli and decreased time to alveolar collapse. In our case, we believe that the presence of a high alveolar oxygen tension due to ventilation with 100% oxygen before

tracheal extubation might have facilitated bronchospasm-induced atelectasis.

## CONCLUSIONS

In conclusion, morbidly obese patients may develop bronchospasm-associated acute RUL atelectasis immediately after tracheal extubation, and the use of 100% oxygen may facilitate atelectasis formation. Reflex atelectasis can be effectively treated with mechanical ventilation and bronchodilators. Fiberoptic bronchoscopy is necessary to identify the pathogenesis of bronchoconstriction. Anesthesiologists must be cautious about reflex atelectasis of the RUL immediately after tracheal extubation.

## Acknowledgement

We thank Dr. Serdar Tuncer for the translation of the manuscript from Turkish to English.

## REFERENCES:

- Westhorpe RN, Ludbrook GL, Helps SC: Crisis management during anaesthesia: bronchospasm. *Qual Saf Health Care*, 2005; 14(3): e7
- Sprung J, Schoenwald PK, Hayden J: Bronchospasm and "reflex right upper lobe atelectasis". *Anesthesiology*, 1998; 89(3): 803
- Yoo KY, Kim SJ, Jeong CW et al: Recurrent attacks of post-intubation right upper lobe atelectasis. *Acta Anaesthesiol Taiwan*, 2009; 47(4): 212-15
- Duggan M, Kavanagh BP: Atelectasis in the perioperative patient. *Curr Opin Anaesthesiol*, 2007; 20(1): 37-42
- Liu M, Schellenberg AG, Patterson T et al: Intraoperative bronchospasm induced by stimulation of the vagus nerve. *Anesthesiology*, 1998; 88(6): 1675-77
- Kucukguclu S, Gökmen N, Yilmaz F: Right lung atelectasis during general anesthesia with laryngeal mask airway. *Pediatr Anaesth*, 2006; 16(1): 93-95
- Moylan FMB, Shannon DC: Preferential distribution of lobar emphysema and atelectasis in bronchopulmonary dysplasia. *Pediatrics*, 1979; 63(1): 130-34
- Eichenberger A, Proietti S, Wicky S et al: Morbid obesity and postoperative pulmonary atelectasis: an underestimated problem. *Anesth Analg*, 2002; 95(6): 1788-92
- Pelosi P, Croci M, Ravagnan I et al: Total respiratory system, lung, and chest wall mechanics in sedated-paralyzed postoperative morbidly obese patients. *Chest*, 1996; 109(1): 144-51
- Benoit Z, Wicky S, Fischer JF et al: The effect of increased FIO(2) before tracheal extubation on postoperative atelectasis. *Anesth Analg*, 2002; 95(6): 1777-81