





ORIGINAL RESEARCH

Application of posterior canal skin flap for the repair of large tympanic membrane perforations

Mohammad Faramarzi MD^{1,2}  | Fateme Bagheri MD³  |
Sareh Roosta MSc, MA²  | Reza Jahangiri MD^{1,2} 

¹Department of Otorhinolaryngology Head & Neck surgery, Shiraz University of Medical Sciences, Shiraz, Iran

²Otolaryngology Research Center, Shiraz University of Medical Sciences, Shiraz, Iran

³Student Research Committee, Shiraz University of Medical Sciences, Shiraz, Iran

Correspondence

Reza Jahangiri, Otolaryngology Research Center, Khalili Hospital, Shiraz University of Medical Sciences, Khalili Street, Shiraz, Iran.
Email: rjahangiri62@gmail.com

Abstract

Objective: Many methods have been described for the repair of the tympanic membrane, but there is no general consensus as to the standard method. The aim of this study was to evaluate the effect of the inferior base posterior canal skin flap on the graft success rate in large tympanic membrane perforations.

Methods: After the post-auricular incision, the posterior canal skin flap with inferior pedicle was created by two vertical and one horizontal incisions. Then the flap was rotated over the temporalis fascia graft. The graft success rate and postoperation hearing test results were evaluated in 52 patients who suffered from large tympanic membrane perforations.

Results: We achieved a 92.3% total graft success rate with about 9 dB improvement in speech reception threshold (SRT).

Conclusion: The rotational inferior base posterior canal skin flap tympanoplasty technique is simple, fast, safe, and effective for the repair of subtotal tympanic membrane perforations.

KEYWORDS

external auditory canal flap, large tympanic membrane perforation, tympanoplasty

1 | INTRODUCTION

Multiple tympanoplasty procedures have been described with the final goal of achieving an intact tympanic membrane with a normal middle ear function.¹ Achieving this goal in an ear with a large tympanic membrane perforation is not satisfactory compared to small perforations. Moreover, the inability to observe the anterior part of the tympanic membrane and less blood supply are other important factors that make the tympanic membrane-less amenable to successful repair.²

In an excellent systematic review on surgical methods for the repair of anterior tympanic membrane perforations by Visvanathan et al.,² they concluded that the superiority of one method over

another has not been proven yet. Efforts have been made to improve tympanoplasty results in large and/or anterior tympanic membrane perforations. Some of these methods include the use of cartilage as a graft,³ anterior anchoring techniques,^{1,4} lateral graft tympanoplasty,⁵ hammock tympanoplasty,⁶ Felix tympanoplasty,⁷ combined mediolateral graft,⁸ butterfly technique,⁹ and window shadow method.¹⁰ In addition, the literature review shows that several rotational external auditory skin flaps are designed.¹¹⁻¹⁵ Considering the limited number of studies done to evaluate the use of canal skin flap for the repair of large perforations, especially with underlay technique, we decided to evaluate this novel method to recognize the side effects and benefits of using posterior canal flap with inferior pedicle.

This is an open access article under the terms of the Creative Commons Attribution-NonCommercial-NoDerivs License, which permits use and distribution in any medium, provided the original work is properly cited, the use is non-commercial and no modifications or adaptations are made.

© 2022 The Authors. *Laryngoscope Investigative Otolaryngology* published by Wiley Periodicals LLC on behalf of The Triological Society.

In view of the advantage of local flaps, we have also tried to use a new modified posterior external auditory canal skin flap method to increase the success rate of tympanoplasty surgeries in ears with large tympanic membrane perforations.

2 | MATERIALS AND METHODS

In this pretest–posttest quasi-experimental study that was conducted in Dena Private Hospital and Dastgheib Hospital, affiliated with Shiraz University of Medical Sciences, from January 2019 to March 2020, 55 patients underwent tympanoplasty operations. Before initiating the study, Institutional Review Board (IRB) approval was obtained (No. IR.SUMS.MED.REC.1399.353). An informed consent form was obtained from each patient. All surgeries were done by the senior author.

2.1 | Inclusion and exclusion criteria

All patients who suffered from chronic otitis media with large tympanic membrane perforations (more than 90%) with a minimum of 1 mm anterior remnant of the tympanic membrane were included in this study. The operations comprised tympanoplasty with or without intact canal mastoidectomy. On the other hand, patients with cholesteatoma and granulation tissue and in whom canal wall down tympanomastoidectomy was performed were excluded from this study.

2.2 | Outcomes

The primary outcome was the graft success rate. All patients were recalled for follow-up microscopic examination to observe the graft at 3 weeks and then 1, 3, and 6 months after the operation. The secondary outcomes included hearing test results and air-bone gap (ABG) closure rate. Hearing results were assessed by pure tone audiometry at frequencies of 0.25, 0.5, 1, 2, and 4 kHz 1 week preoperatively and 3, and 6 months postoperatively. As we usually do not evaluate the 3-kHz frequency in our center, we used the mean of 2 and 4 kHz frequencies instead of the 3-kHz frequency. Bone conduction (BC), air conduction (AC), ABG, and speech reception thresholds (SRT) of 1 week before and 6 months after operation were analyzed. In this study, successful ABG closure was defined as postoperative ABG of ≤ 25 dB or more than 10 dB improvement.¹ In addition, postoperative air conduction (AC) threshold of ≤ 30 dB was determined as functional hearing.

2.3 | Surgical procedure

All patients were operated under general anesthesia by post-auricular approach. After refreshing the edge of the perforation, tympanomeatal flap was elevated. Then a vertical incision was made

at 12 o'clock position from the previous horizontal canal incision next to the annular ligament. After that, the annulus was cut by a Bellucci scissor. Following this, an inferior vertical incision was made at 6 o'clock position, 5 mm lateral to the annulus (Figure 1A). Then this posterior canal skin flap was elevated anteriorly (Figure 1B). Subsequently, temporalis fascia was used as an underlay technique medial to the handle of the malleus and the remnant of the tympanic membrane perforation (Figure 1C). Then, the created flap was rotated over the graft as far as possible up to the posterior part of the handle of the malleus (Figure 1D). If the malleus was absent, the posterior canal wall skin flap could be advanced as nearest as possible to the remnant of the anterior tympanic membrane perforation. In the end, the middle ear cavity and ear canal were packed with Gelfoam, and the post-auricular incision was closed with vicryl 4-0 stitches.

2.4 | Statistical analysis

The SPSS software (IBM SPSS Statistics for Windows, Version 24.0, IBM Corporation, Armonk, NY) was utilized for the statistical analysis. Categorical variables were analyzed using the chi-square test. Paired *t* test or Wilcoxon test was used for the preoperative and postoperative comparison of the audiometric variables. T-test or Mann-Whitney test was used for the evaluation of audiometric variables regarding ossicular chain status. *P*-values less than 0.05 were considered statistically significant.

3 | RESULTS

Initially, 55 patients were recruited. Three patients were excluded from the study due to inadequate follow-up. Data from 52 patients were analyzed. Twenty-three ears belonged to male patients (44.2%) and 29 belonged to female patients (55.8%). The average age of the patients was 44.5 years (SD: 13.0, range: 19–66 years). Tympanoplasty was performed in 39 ears (75.0%) and intact canal wall mastoidectomy in 13 ears (25.0%). The operation was primary in 42 ears (80.8%) and revision in 10 ears (19.2%). Regarding the condition of the middle ear mucosa, the most common finding was normal mucosa in 21 ears (40.4%). As shown in Table 1, the other most common intraoperative pathologies were hypertrophic mucosa in 10 ears (19.2%), myringosclerotic plaque in 8 ears (15.4%), and tympanosclerotic plaque in 7 ears (13.5%). Regarding the ossicular status, 65.4% of the ears had normal ossicular chain (34 ears) and the stapes were normal in all ears, 52 (100%). Necrosis of the long process of incus was the most common abnormal ossicular finding which was seen in 14 ears (26.9%).

We obtained graft success rate (GSR) in 48 ears (92.3%) and graft failure in 4 ears (7.7%). All of these 4 ears had normal ossicles status but three of them had an intraoperative pathological issue (one hypertrophic mucosa, one granulation tissue, and one tympanosclerotic plaque). GSR in the ears with normal ossicles was 88.2% (30 ears) and in the ears with abnormal ossicles was 100% (52 ears) and the

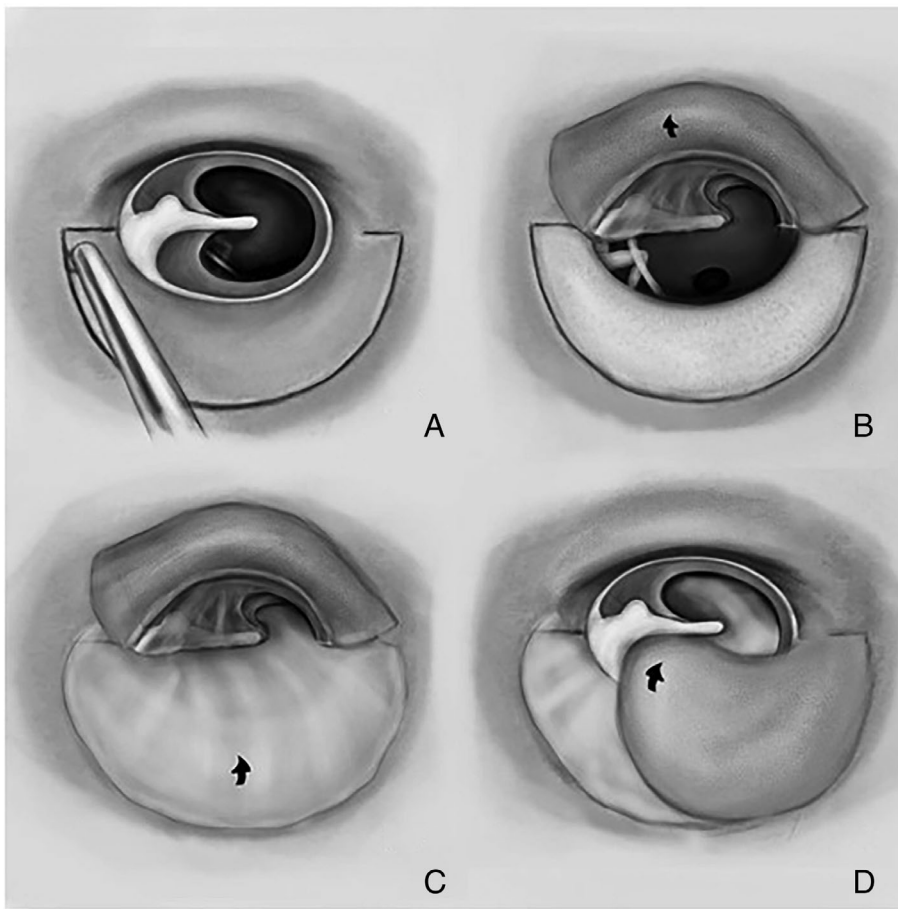


FIGURE 1 Creation of the inferior base rotational flap by preserving at least 5 mm of pedicle at 6 o'clock position and rotating the inferior base canal skin flap over the temporalis fascia

TABLE 1 Type of intraoperative pathology

Intraoperative pathology	N (%)
Normal	21 (40.4)
Hypertrophic mucosa	10 (19.2)
Myringosclerotic plaque	8 (15.4)
Typanosclerotic plaque	7 (13.5)
Granulation tissue	2 (3.9)
Cholesteatoma	1 (1.9)
Cholesterol granuloma	1 (1.9)
Cholesteatoma + typanosclerotic plaque	1 (1.9)
Hypertrophic mucosa + typanosclerotic plaque	1 (1.9)

difference was not significant ($P = .285$). Regarding intraoperative pathology, GSR in normal ears was 95.2% (20 ears) and 90.3% (28 ears) in pathological ears. The difference was not statistically significant ($P = .639$). GSR in the ears within the primary operation group was 92.9% (39 ears) and 90% (9 ears) in the ears within revision surgery group. The difference was not significant ($P \cong 1$).

As to the postoperative outcomes, AC and ABG in measured frequencies as well as SRT improved significantly ($P < .05$), but BC and speech discrimination scores (SDS) did not show any significant improvements ($P > .05$) (Tables 2 and 3). Moreover, we analyzed audiometric variables with respect to the ossicular chain status.

As shown in Table 3, considering the presence of normal stapes bone in all patients, postoperative hearing improvement was not affected by the condition of other ossicles and hearing improvement in ears with normal ossicles was not significantly different from ears with ossicular destruction.

Successful ABG closure was observed in 88.5% of ears (46 ears). The difference between successful ABG closure in ears with and without normal ossicular chain was not significant (88.2% vs. 83.3%, $P = .682$). We achieved a functional hearing rate in 29 ears (55.8%).

No postoperative complications such as wound infection, external otitis, and sensorineural hearing loss were observed. However, in the follow-up period, small granulation tissue in the external canal was seen in one ear 4 weeks after surgery which was removed and cauterized with trichloroacetic acid 25%. According to postoperative microscopic otoscopy, the appearance of the tympanic membrane was similar to normal tympanic membranes.

4 | DISCUSSION

In our study, the posterior canal skin flap tympanoplasty technique was shown to have a 93% graft success rate in the primary cases and 90% success rate in the revision myringoplasty group in the ears with large tympanic membrane perforations. The aim and strategy of rotating the posterior canal wall skin flap were to decrease the size of the

TABLE 2 Preoperative, postoperative, and gain of AC, BC, and ABG (dB) in each frequency and frequencies of 0.5–3 kHz

	250 Hz	500 Hz	1000 Hz	2000 Hz	3000 Hz	4000 Hz	500–3000 Hz
Preoperative AC (dB)							
Mean	48.9	44.9	39.9	37.3	41.3	47.4	40.8
SD	(11.1)	(15.9)	(15.8)	(15.1)	(15.7)	(19.2)	(13.9)
Postoperative AC (dB)							
Mean	37.9	32.9	33.2	32.3	36.4	42.0	33.7
SD	(15.3)	(15.1)	(16.9)	(16.3)	(16.5)	(20.7)	(15.0)
AC gain (dB)							
Mean	11.1	12.0	6.7	5.0	4.9	5.4	7.1
SD	(14.7)	(12.0)	(13.0)	(11.2)	(13.5)	(16.2)	(10.2)
P-value	<.0001	<.0001	.004	.007	.029	.012	<.0001
Preoperative BC (dB)							
Mean	5.8	11.0	9.5	15.1	16.2	18.6	13.0
SD	(7.8)	(7.1)	(9.2)	(10.6)	(12.6)	(15.1)	(9.1)
Postoperative BC (dB)							
Mean	6.0	10.7	11.9	16.3	18.5	20.7	14.3
SD	(6.7)	(8.9)	(10.6)	(11.1)	(12.0)	(14.2)	(9.9)
BC gain (dB)							
Mean	−0.1	0.2	−2.4	−1.2	−2.3	−2.1	−1.4
SD	(8.9)	(7.6)	(8.1)	(8.0)	(7.9)	(7.6)	(6.9)
P-value	.977	.832	.062	.273	.065	.053	.258
Preoperative ABG (dB)							
Mean	43.1	33.9	30.4	22.1	25.1	28.8	27.9
SD	(12.0)	(13.8)	(13.2)	(9.5)	(9.8)	(9.8)	(9.2)
Postoperative ABG (dB)							
Mean	31.9	22.1	21.3	16.0	18.0	21.3	19.3
SD	(12.9)	(11.4)	(11.1)	(9.1)	(9.6)	(13.0)	(9.1)
ABG gain (dB)							
Mean	11.2	11.8	9.0	6.2	7.1	7.5	8.5
SD	(13.8)	(11.6)	(13.1)	(11.3)	(12.2)	(14.9)	(9.5)
P-value	<.0001	<.0001	<.0001	.002	.001	.002	<.0001

Abbreviations: ABG, air-bone gap; AC, air conduction; BC, bone conduction.

perforation. This technique reduces the size of the perforation to about half of its original size. In addition, the rationale for creating this flap is that it lends the excess epithelium as near as possible to the anterior remnant of the tympanic membrane from the canal skin to the remnant of the tympanic membrane for faster and better re-epithelialization so that the process would be accelerated over a smaller area of temporalis fascia graft. We used a canal skin flap with the inferior base pedicle. Postoperative examinations and follow-ups showed that the inferior base flap has enough blood supply as the superior base flap. Moreover, the rotation of the inferior base flap is easier for the coverage of the anterior tympanic membrane graft. As mentioned before, when the malleus is absent, the surgeon can advance the flap more near to the anterior tympanic membrane remnant.

The use of the canal flap was first introduced by Sooy¹² in 1956. In Sooy's technique,¹² after cauterization of the edges of the perforation, the flap covered the entire surface of the perforation itself,

without any graft material. He believed that the basic idea of using a canal flap is for the good blood supply, resistance to ear infections, and "local tissue immunity."¹² A few years later, in 1964, by combining a vein graft, as an overlay graft, with a local flap, he achieved greater success in repairing the tympanic membrane perforation; 92% versus 75%.¹⁵ In 1966, Robinson¹¹ achieved a 92.6% success rate in 53 patients by using the canal skin flap. In Robinson's method,¹¹ after removal of the epithelium from the edge of the perforation and skeletonizing the malleus bone, a U-shape incision was done in the canal with preservation of the posterior superior as pedicle and annulus were cut in the inferior position. Then vein graft was inserted underlay and the flap was rotated to cover the entire perforation (edge to edge). In 2000, Raghavan et al.¹³ achieved a graft success rate of 91.2% in 34 ears with large perforations by using the temporalis fascia and the canal skin flap. They named their technique sandwich graft tympanoplasty. After freshening the edge of the perforation,

TABLE 3 Preoperative, postoperative, and gain of audiometric outcomes regarding ossicular chain status

Outcome	Ossicular chain status	Preoperative	Postoperative	Gain	P-value ^c
AC (dB) ^b	Normal	39.3 (13.4) ^a	31.3 (14.0)	8.0 (9.5)	.001
	Abnormal	43.6 (14.9)	36.4 (16.8)	7.1 (12.0)	.070
	Total	40.8 (13.9)	33.7 (15.0)	7.1 (10.2)	<.0001
	P-value ^d			.768	
BC (dB) ^b	Normal	13.7 (9.7)	13.3 (10.0)	0.4 (6.5)	.702
	Abnormal	12.1 (8.0)	15.4 (11.7)	-3.2 (8.5)	.147
	Total	13.0 (9.1)	14.3 (9.9)	-1.4 (6.9)	.258
	P-value ^d			0.094	
ABG (dB) ^b	Normal	25.7 (8.3)	18.5 (8.4)	7.2 (9.2)	.001
	Abnormal	31.4 (9.9)	21.1 (11.1)	10.4 (10.5)	.009
	Total	27.9 (9.2)	19.3 (9.1)	8.5 (9.5)	<.0001
	P-value ^d			.261	
SRT (dB)	Normal	37.6 (12.1)	30.2 (14.6)	7.4 (11.2)	.003
	Abnormal	41.8 (16.2)	30.4 (15.4)	11.4 (10.4)	.005
	Total	39.2 (13.5)	30.2 (14.5)	8.9 (10.9)	<.0001
	P-value ^d			.215	
SDS (%)	Normal	94.3 (17.5)	96.2 (5.9)	-1.9 (14.5)	.726
	Abnormal	96.6 (5.4)	96.6 (5.8)	0.0 (3.5)	1.000
	Total	95.1 (14.3)	96.3 (5.8)	-1.2 (11.8)	.693
	P-value ^d			.588	

Abbreviations: ABG, air-bone gap; AC, air conduction; BC, bone conduction; SDS, speech discrimination scores; SRT, speech reception thresholds.

^aValues are mean (SD).

^bFrequencies of 0.5–3 kHz.

^cComparison between preoperation and postoperation.

^dComparison between normal and abnormal ossicular chain.

temporalis fascia was applied as an overlay graft, and posterosuperior meatal flap was rotated over the graft. Despite the high graft success rate in primary cases, they achieved a 77% graft success rate in the revision cases in comparison to 90% in our study. In 2014, Memari and Hassannia¹⁴ reported a 96% success rate in 50 ears with the rotational canal skin flap and temporalis fascia. In this technique, a counter-clockwise horizontal incision was made from 11 o'clock to 3 o'clock. The annulus was cut at the site of the eustachian tube. After application of the temporalis fascia under the malleus bone, the posterior base flap was rotated over the graft. So, in this method, the annulus was displaced in near-total length medially. Overall, usage of local flaps leads to faster epithelialization, better graft support, and provide sufficient blood supply.^{11–15}

A limitation of Sooy¹² and Robinson's methods¹¹ is that the flap should be large enough to cover the entire perforation. Also, in these methods, medial and lateral surface of the malleus should be skeletonized and de-epithelialized, because the flap covers the malleus bone and the remaining epithelium has the potential risk of developing iatrogenic cholesteatoma. By the way, it is well known that the epithelium and vessels over the malleus contribute to graft re-epithelialization. However, in our method, there is no need for malleus manipulation, because the rotational flap is advanced just to the posterior edge of the handle of the malleus.

In Memari and Hassannia's method,¹⁴ they displaced the anterior annulus to repair the anterior tympanic membrane perforation which is beneficial for graft success. Yet, it is hard to tell that postoperative anterior blunting may not develop with this method.

The strength of our study was that all surgeries were performed by the first author, so the level of experience is not a possible confounding factor. We are well aware that our research has one inherent limitation which is lack of a control group. Nevertheless, we have shown in this study that the application of inferior base posterior canal wall skin flap is a useful technique for large tympanic membrane perforations.

5 | CONCLUSION

The result of this study supports the view that the inferior base external auditory skin flap is a simple, fast, and effective method for the repair of large tympanic membrane perforations.

ACKNOWLEDGMENTS

The authors wish to thank Dr Abdolali Zolghadr, for his invaluable assistance in editing this manuscript. The article is extracted from a thesis presented in partial fulfillment of the requirements for the

degree of medical doctorate by Fateme Bagheri, MD. The authors declared that this study has received no financial support.

CONFLICT OF INTEREST

The authors have declared no conflicts of interest for this article.

ORCID

Mohammad Faramarzi  <https://orcid.org/0000-0002-6903-3252>

Fateme Bagheri  <https://orcid.org/0000-0003-3444-0090>

Sareh Roosta  <https://orcid.org/0000-0002-3927-0812>

Reza Jahangiri  <https://orcid.org/0000-0002-3408-9635>

REFERENCES

1. Faramarzi A, Hashemi SB, Rajaei A. "Mucosal pocket" myringoplasty: a modification of underlay technique for anterior or subtotal perforations. *Am J Otolaryngol*. 2012;33(6):708-713.
2. Visvanathan V, Vallamkonda V, Bhimrao SK. Achieving a successful closure of an anterior tympanic membrane perforation: evidence-based systematic review. *Otolaryngol Head Neck Surg*. 2018;158(6):1011-1015.
3. Aidonis I, Robertson TC, Sismanis A. Cartilage shield tympanoplasty: a reliable technique. *Otol Neurotol*. 2005;26(5):838-841.
4. Harris JP, Wong YT, Yang TH, Miller M. How I do it: Anterior pull-through tympanoplasty for anterior eardrum perforations. *Acta Otolaryngol*. 2016;136(4):414-419. doi:10.3109/00016489.2016.1139744
5. Angeli SI, Kulak JL, Guzmán J. Lateral tympanoplasty for total or near-total perforation: prognostic factors. *Laryngoscope*. 2006;116(9):1594-1599.
6. Peng R, Lalwani AK. Efficacy of "hammock" tympanoplasty in the treatment of anterior perforations. *Laryngoscope*. 2013;123(5):1236-1240. doi:10.1002/lary.23747
7. Castelli ML, Vitiello R, Ponzo S, Evangelista A. Ten years' experience with Felix tympanoplasty: analysis of anatomical and functional results. *J Laryngol Otol*. 2015;129(11):1064-1068.
8. Jung TT, Park SK. Mediolateral graft tympanoplasty for anterior or subtotal tympanic membrane perforation. *Otolaryngol Head Neck Surg*. 2005;132(4):532-536.
9. Alain H, Esmat NH, Ohad H, Yona V, Nageris BI. Butterfly myringoplasty for total, subtotal, and annular perforations. *Laryngoscope*. 2016;126(11):2565-2568.
10. Schraff S, Dash N, Strasnick B. "Window shade" tympanoplasty for anterior marginal perforations. *Laryngoscope*. 2005;115(9):1655-1659. doi:10.1097/01.mlg.0000175067.19744.27
11. Robinson M. Tympanoplasty: pedicled canal skin graft with annulus transposition. *Laryngoscope*. 1966;76(9):1572-1581.
12. Sooy FA. A method of repairing a large marginal tympanic perforation. *Ann Otol Rhinol Laryngol*. 1956;65(4):911-914.
13. Raghavan U, Malki DS, Mahmoud NA. Myringoplasty: update on onlay pedicle skin flap and temporalis fascia sandwich graft. *J Laryngol Otol*. 2000;114(3):174-177.
14. Memari F, Hassannia F. Myringoplasty using rotation flap of canal skin for total tympanic membrane perforation. *Auris Nasus Larynx*. 2014;41(5):413-416.
15. Sooy FA. Clinical and laboratory evaluation of tympanoplasty utilizing canal wall pedicle skin grafts. *Laryngoscope*. 1964;74:979-984. doi:10.1288/00005537-196407000-00006

How to cite this article: Faramarzi M, Bagheri F, Roosta S, Jahangiri R. Application of posterior canal skin flap for the repair of large tympanic membrane perforations. *Laryngoscope Investigative Otolaryngology*. 2022;7(2):578-583. doi:10.1002/lio2.756