

Original article

Towards understanding the phenotypes of myocardial involvement in the presence of self-limiting and sustained systemic inflammation: a magnetic resonance imaging study

Valentina O. Puntmann^{1,2}, Peter C. Taylor³, Andrew Barr³,
Bernhard Schnackenburg¹, Cosima Jahnke¹ and Ingo Paetsch¹

Abstract

Objective. To investigate the patterns of myocardial involvement in the presence of self-limiting and sustained systemic inflammation, using MRI.

Methods. Ninety-four subjects, with a clinical diagnosis of myocarditis ($n = 36$), RA ($n = 24$) and apparently healthy subjects ($n = 34$, control group), underwent standardized cardiac MRI protocol for the assessment of global and regional morphology and systolic function using balanced steady-state free precession sequences, T2-weighted images and late gadolinium enhancement (LGE) studies.

Results. The three groups were well matched for age, gender and cardiovascular risk factors. The RA group showed markedly increased end-diastolic volumes and reduced ejection fraction ($P < 0.05$). Antero/inferolateral wall thickness was greater in the myocarditis group and reduced in RA, associated with reduced radial and longitudinal thickening ($P < 0.01$), and markedly raised T2-oedema ratio and global LGE scores ($P < 0.05$).

Conclusions. Our results may signify the phenotypic features of myocardial plasticity and deformation in response to self-limiting and sustained inflammatory injury.

Key words: Cardiovascular, Systemic inflammation, Rheumatoid arthritis, Biomarkers, Magnetic resonance imaging.

Introduction

Cardiovascular (CV) disease is a major cause of morbidity and mortality in patients with systemic inflammatory conditions, including RA, SLE and also chronic infections with associated persistent inflammatory responses [1–6]. Available evidence suggests that these conditions are associated with vascular dysfunction, as a consequence

of the inflammatory state and that this is linked to increased CV risk [7–11]. Inflammatory involvement of the myocardium in the presence of systemic inflammation remains less well recognized [12]. While studies in viral myocarditides indicate the presence of inflammatory features, discernable by means of contemporary imaging [13–16], it is unclear whether these changes evolve in the presence of sustained systemic inflammation.

Cardiac MRI is emerging as a sensitive tool in the evaluation of the structure and function of the heart, in a variety of conditions, such as tumours, complex congenital malformations, myocarditis, cardiomyopathy and myocardial ischaemia [17]. In this study, we investigate the patterns of myocardial response in the presence of self-limiting myocardial inflammation, in the context of myocarditis and sustained systemic inflammation in patients with RA, by means of multiparametric cardiac MRI.

¹Department of Cardiology and Internal medicine, The German Heart Institute Berlin, Berlin, Germany, ²Cardiovascular Section, Department of Experimental Medicine, Division of Investigative Sciences and ³The Kennedy Institute of Rheumatology, Imperial College London, London, UK.

Submitted 22 July 2009; revised version accepted 16 November 2009.

Correspondence to: Valentina O. Puntmann, Cardiovascular Section, Division of Investigative Sciences, Department of Experimental Medicine, Imperial College London, Hammersmith Campus, Burlington Danes Building, 5th Floor, Du Cane Road, London W12 0NN, UK.
E-mail: v.puntmann@imperial.ac.uk

Methods

Study population

The study population consisted of adult subjects (aged > 16 years) drawn from the following participating centres in this study: the Rheumatology Departments of Hammersmith, Charing Cross and Northwick Park Hospitals in the UK and the Cardiology Department, The German Heart Institute, Berlin, Germany. The study was reviewed and approved by the respective institutional ethics committees (Charité University School of Medicine and Charing Cross and Queen Charlotte National Research Ethics Committee). Informed written consent was obtained from all participants in the study according to the Declaration of Helsinki.

Group 1—patients with clinical criteria for myocarditis. Diagnosis of myocarditis was based on the presence of cardiac symptoms in the context of flu-like illness (chest pain, shortness of breath and palpitations), evidence of myocardial involvement (ECG abnormalities and elevated cardiac enzymes—creatinase, troponin I or T) and raised inflammatory biomarkers, e.g. CRP [14, 15]. Patients were recruited within the first 3 months of the original presentation.

Group 2—patients with chronic RA and evidence of sustained inflammatory response. Chronic, active RA was defined by classification criteria for positive, poor-prognosis disease of > 10 years' duration, positive RF, positive for anti-cyclic citrullinated peptide (anti-CCP) antibodies, persistently raised disease activity score (DAS-28 > 7) and inflammatory biomarkers (CRP), meeting the British Society for Rheumatology criteria for highly active RA [18], and refractory to conventional DMARDs and steroids, waiting to commence biologic therapies. None of the patients was receiving biologic therapies at the time of imaging.

Group 3—control group. Control groups consisted of age-, gender-, BMI-, body surface area (BSA)-matched apparently healthy subjects, recruited through advertisement, with no evidence of systemic inflammatory response, such as raised CRP or permanent anti-inflammatory medication (aspirin, NSAIDs, corticosteroids, anti-histamines, etc.).

In addition, criteria of exclusion for all subjects were previously known coronary artery disease, myocardial infarction, heart failure, evidence of chronic myocarditis (> 3 months) and known contraindications to MRI. The presence or absence of anti-hypertensive or cholesterol-lowering medications was not used as a selection criterion.

Clinical data

Standard clinical 'meta-data' were recorded for all subjects, including demographics (age, gender, duration of illness, smoking, diabetes, cholesterol level, etc.). All subjects underwent a routine blood test for clinical

haematology and biochemistry, 12-lead ECG and blood pressure (BP) measurement.

Multiparametric MRI

All participants underwent a standardized cardiac MRI protocol (1.5T MRI Achieva; Philips Medical Systems, The Netherlands) with subjects in supine position and a five element-phased array cardiac coil, as previously described [19, 20]. All subjects were in sinus rhythm to allow accurate triggering and good quality image acquisition. Preparation scans included breath-held general survey and two rapid heart axis survey scans [pseudo-right, anterior oblique- and pseudo-four chamber (CH) views].

Investigation into cardiac volumes and output. Volumetric cavity assessment was obtained by whole-heart coverage of gapless short-axis (SAX) slices using a balanced steady-state free precession (bSSFP) sequence [echo time (TE)/repetition time (TR)/flip angle 1.7°/3.4°/60°, spatial resolution 1.8 × 1.8 × 8 mm and 50 heart phases] with typical 10–14 heartbeats used for image acquisition. Investigation into myocardial plasticity and deformation was assessed by two-, three- and four-chamber and SAX slices with a bSSFP (as above). Maximal and regional left ventricular wall thickness (LVWT) were obtained in three SAX slices (basal, equatorial and apical) in a 16-segment analysis model. Investigation into LV tissue is characterized by dual-inversion recovery T2-weighted spin-echo sequences performed in three analogous SAX slice acquisitions; matrix size 384 × 384; slice thickness 8 mm; echo time = 90 ms; relaxation time 1500 ms; and TR (beats) = 2. Calculation of oedema ratio (ER) was performed as previously described [13–15]. Late gadolinium enhancement (LGE) was performed using a diastolic-triggered inversion-prepared 3D spoiled gradient echo sequence (TE/TR/flip = 1.7 ms, 3.5 ms, 15 dg; spatial resolution 1.8 × 2 × 10 mm reconstructed to 1.8 × 1.8 × 5 mm, with patient-adapted pre-pulse delay) for 10 min following contrast injection (gadolinium-diethylenetriamine penta-acetic acid, dose of 0.2 mmol/kg body weight).

Data analysis

Data analysis was performed using dedicated cardiac software (ViewForum, Version 5.1; Philips Medical Systems, The Netherlands) and Excel-based post-processing macros, developed in-house. Myocardial deformation was assessed by the calculation of radial and longitudinal strains, as a percentage of change of thickness of radial segments and lengths of longitudinal walls [21, 22]. Quantitative analysis of LGE for the presence of global (total LV volume) and regional (corresponding three SAX slices for segmental analysis) enhancement (percentage of enhanced volume = enhanced volume/non-enhanced volume) was done with the manual selection of normal area, appearing as maximally suppressed myocardium anywhere within the 3D volume. To avoid confounding for artefacts, a conservative threshold for

enhancement level was employed at 6 s.d. from the normal area [13–15].

Calculation of BMI, BSA and LV wall stress was performed using validated formulas [23–26]. Statistical analysis was performed using SPSS software (version 15.0; SPSS, Chicago, IL, USA). For comparison of two and more than two normally distributed variables, Student's *t*-test, one-way analysis of variance (ANOVA, with Bonferroni's *post-hoc* test) and the chi-square test were employed as appropriate. Correlations were assessed using Pearson's correlation coefficient for normally distributed variables and Spearman's correlation coefficient for non-parametric data. Data are expressed as mean (1 s.d.); $P < 0.05$ was considered statistically significant.

Results

Clinical characteristics

Table 1 provides the characteristics of the study population. Participants were well matched for BSA/BMI, age and gender, with predominance of females in all groups. The groups were also well matched for traditional CV risk factors with no significant difference in BP, smoking, total cholesterol levels among groups; none of the subjects was diagnosed with either impaired glucose tolerance or overt diabetes. Table 2 summarizes the medications taken by the study groups, indicating the greater share of CV medication in the RA group.

In the myocarditis group, the average duration between the onset of cardiac symptoms and MRI was 44.9 (19.8) days. The majority of patients presented with acute onset of chest pain (78%), shortness of breath (28%) and palpitations (30%). Tiredness was noted in three patients as the presenting symptom. ECG-wise, 28 patients showed significant changes in ST-segment (depression, elevation, negative T waves in ≥ 2 leads). In addition, eight patients had a documented supraventricular tachyarrhythmia and five paroxysmal atrial fibrillation. Half of the patients showed persistently raised inflammatory biomarkers (Table 1). In terms of cardiac markers, 20 patients had raised creatine kinase (CK) levels

[198.3 (134.26) ng/ml] with positive CK-MB fraction [42.3 (26.3) ng/ml] and 13 had a detectable troponin rise [2.5 (0.22) ng/ml] at the time of presentation. In addition, 12 patients showed concomitant presence of small pericardial effusion (Fig. 1A). On clinical examination, none of the subjects exhibited signs of heart failure. None of these subjects took any cardiotoxic medication or an excessive amount of alcohol before this episode.

In the RA group, patients had had condition for an average of 12.3 (5.4) years, had detectable titres of RF and anti-CCP antibodies and evidence of persistently raised inflammatory markers, such as CRP. All patients had a routine measurement of CK and troponin I at enrolment, none of them reaching the positive threshold as per local hospital reference (>0.032 ng/ml). There were no significant ECG changes either in duration of intervals or significant ST changes. These patients took a variety of DMARDs and NSAIDs (Table 2). None of the patients took gold preparations.

Global cardiac functional performance

While both inflammatory groups exhibited reduced ejection fraction (EF), the RA group showed markedly increased end-diastolic volume (EDV) and to a lesser

TABLE 2 Medication of the study population

Medication	Normal (<i>n</i> = 34), <i>n</i> (%)	Myocarditis (<i>n</i> = 36), <i>n</i> (%)	RA (<i>n</i> = 24), <i>n</i> (%)
CV			
β-Blockers	2 (6)	0 (0)	3 (12.5)
Amlodipine	6 (17.6)	5 (13.9)	8 (33.3)
RAS inhibitors	8 (23.5)	7 (19.4)	9 (37.5)
Statins	15 (44.1)	14 (38.8)	10 (41.7)
Anti-rheumatic			
Prednisolone	–	–	22 (91.7)
SSZ	–	–	24 (100)
MTX	–	–	22 (91.7)
HQC	–	–	23 (95.8)
NSAIDs	–	11 (30.6)	21 (87.5)

RAS: renin–angiotensin system.

TABLE 1 Characteristics of the study population

	Normal, <i>n</i> = 34	Myocarditis, <i>n</i> = 36	RA, <i>n</i> = 24	<i>P</i> -value
Age, mean (s.d.), years	42.2 (12.1)	40.6 (14.9)	46.1 (9.1)	0.12
Gender (males), <i>n</i> (%)	11 (32)	12 (33)	8 (33.3)	0.85
BP systolic, mean (s.d.), mmHg	121.1 (10.7)	122.5 (13.3)	128 (15.1)	0.27
BP diastolic, mean (s.d.), mmHg	78.7 (7.8)	79.1 (9.7)	84.5 (9.9)	0.21
BMI, mean (s.d.), kg/m ²	24.5 (3)	25.2 (4.3)	25.6 (5)	0.97
BSA, mean (s.d.), m ²	1.7 (0.3)	1.7 (0.3)	1.7 (0.3)	0.94
Total cholesterol, mean (s.d.), mmol/l	4.6 (2.4)	4.7 (1.2)	5.2 (3.1)	0.35
Smoking, <i>n</i> (%)	2 (6)	3 (8)	1 (4)	0.54
CRP, mean (s.d.), mg/l	4.7 (3.1)	32.3 (6.3)	48.3 (26.5)	$F = 3.9, P = 0.01^{*†}$

*Normal vs myocarditis. †Normal vs RA. $P < 0.05$ is considered significant.

Fig. 1 Representative images of a patient with myocarditis (A) and RA (B). In (A), cine frames at end-diastole (ED) and end-systole (ES) in SAX indicate increased wall thickness (1-ED and 1-ES), reduced contractility and the presence of a small pericardial effusion (yellow arrow). In (B), there is cavity enlargement, wall thinning and reduced thickening (2-ED and 2-ES). T2-weighted (T2W) and LGE images show evenly distributed signal intensity and absence of focal fibrosis in both cases.

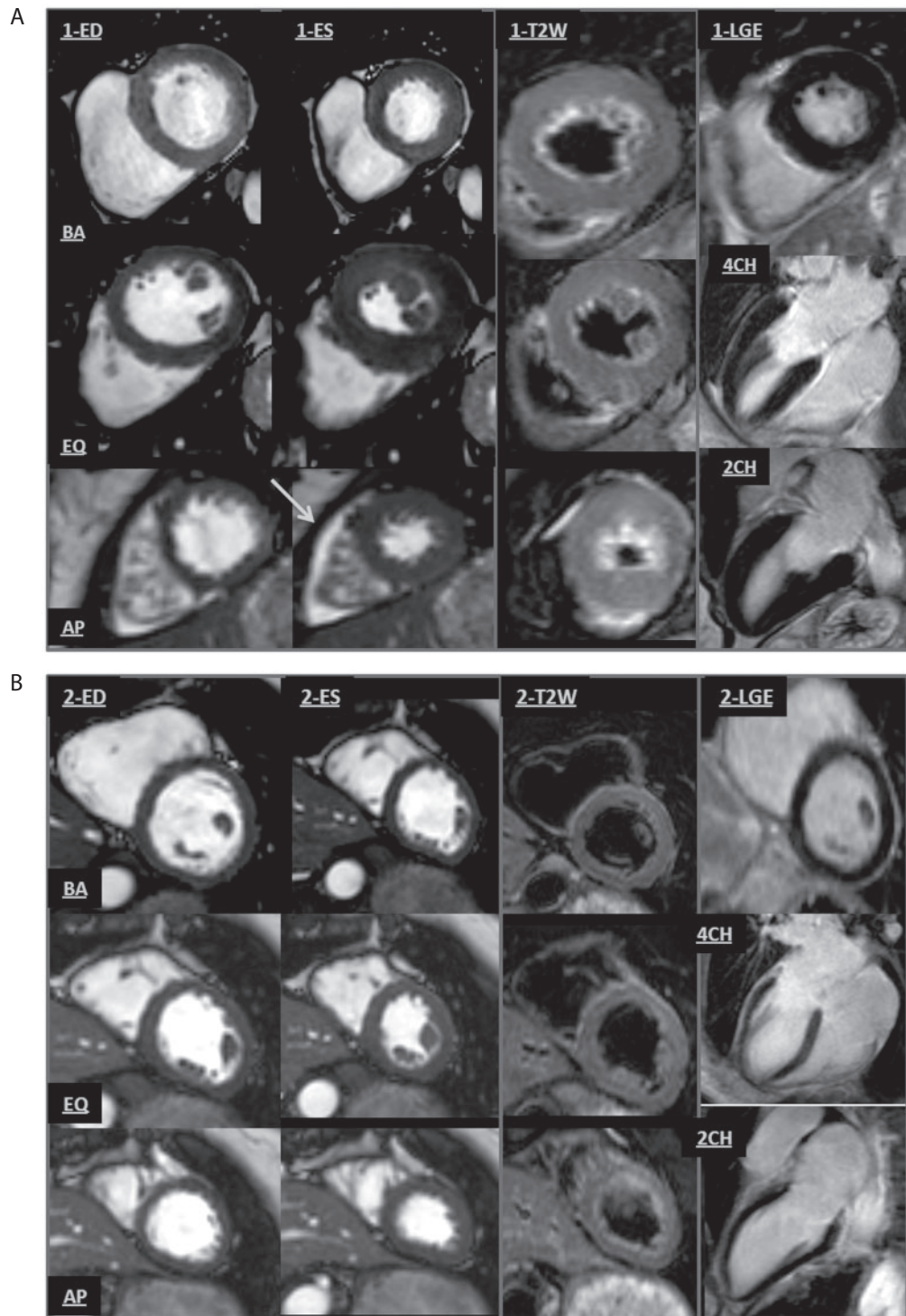


TABLE 3 Measures of LV cardiac function and morphology

	Normal (<i>n</i> = 34), mean (s.d.)	Myocarditis (<i>n</i> = 36), mean (s.d.)	RA (<i>n</i> = 24), mean (s.d.)	<i>P</i> -value
LV mass, g	87.7 (31.6)	88.1 (27.2)	80.5 (21.5)	0.48
LV mass index, g/m ²	59.8 (17.2)	57.7 (18)	64.1 (23.5)	0.85
Heart rate, b.p.m.	75.3 (9.1)	67.6 (12.4)	72.1 (6.0)	0.35
LV wall stress, dynes/cm ²	146.0 (31.3)	146.1 (31.1)	146.6 (34.7)	0.66
Interventricular septum, mm	9.1 (2.1)	9.4 (2.5)	8.2 (2.1)	0.62
Posterior wall thickness, mm	8.9 (1.8)	7.9 (1.9)	7.5 (2)	0.17
EF, %	62.2 (6.5)	53.4 (6.3)	45.8 (8.8)	<i>F</i> = 3.1, 0.05*
EDV, ml	123.1 (15.3)	133.5 (24.8)	150.2 (31.8)	<i>F</i> = 3.1, 0.05*
ESV, ml	65.6 (25.7)	70.4 (22.3)	76.2 (26.5)	0.1
Stroke volume, ml	58.3 (13.3)	63.1 (11.7)	59.2 (15.1)	<i>F</i> = 2.1, 0.09
Cardiac output, l/min	4.8 (1.3)	4.3 (1.1)	4.8 (1.1)	0.12
Left atrium, cm ²	23.2 (5.8)	24.9 (5.3)	26.2 (5.2)	<i>F</i> = 3.1, 0.05*
Right atrium, cm ²	22 (2.9)	22.8 (4.6)	23.2 (4.8)	0.66

*Normal vs RA. *P* < 0.05 is considered significant. LV: left ventricle.

TABLE 4 Radial and longitudinal regional systolic deformation

Systolic strain	Normal (<i>n</i> = 34), mean (s.d.)	Myocarditis (<i>n</i> = 36), mean (s.d.)	RA (<i>n</i> = 24), mean (s.d.)	<i>P</i> -value
Radial				
Total	21 (9.2)	20.5 (8.8)	22.2 (8.4)	0.38
Apical	22.7 (11.5)	26.3 (14.3)	26.8 (12.7)	0.13
Equatorial	20.2 (12.3)	20.9 (10.3)	24.4 (11.5)	0.5
Basal	18.3 (6.8)	14.2 (7.2)	16.8 (4.6)	0.7
Longitudinal				
Total	19 (3.4)	18.3 (3.5)	16.1 (7.8)	<i>F</i> = 3.1, <i>P</i> = 0.05* [†]
Anterior	18 (5)	18.4 (6.2)	21.4 (6.1)	0.52
Anteroseptal	18.7 (5)	19.4 (6.7)	19.3 (4.3)	0.22
Inferoseptal	22.2 (6.6)	19.6 (5)	17.5 (4.6)	<i>F</i> = 3.1, 0.05*
Inferior	20.2 (5.9)	17.6 (7.2)	17.3 (5.6)	<i>F</i> = 3.1, 0.05* [‡]
Inferolateral	20.2 (5.9)	17.2 (7.5)	16.2 (6.8)	<i>F</i> = 3.4, 0.02* [‡]
Anterolateral	20.7 (13.7)	17.6 (7.2)	16.1 (5.9)	<i>F</i> = 3.2, 0.04 [†] [‡]
RV free wall	24.2 (6.8)	26.2 (7)	27.6 (8.3)	0.57

*Normal vs RA. [†]Myocarditis vs RA. [‡]Normal vs myocarditis; *P* < 0.05 is considered significant.

extent end-systolic volume (ESV) in comparison with the normal group. Difficulty in functional assessment in RA patients due to the problems in mobility notwithstanding, none of the patients exhibited symptoms or signs of overt heart failure at rest. Given the lower EF finding in the RA group, some patients may have been in the New York Heart Association (NYHA) I/II class (Table 3).

Regional LV plasticity and deformation

Patients with myocarditis and RA displayed changes in LVWT, particularly in the lateral segments, in opposing directions: antero/inferolateral wall thickness was greater in the myocarditis group and reduced in RA, in all three SAX levels. These findings were associated with reduced radial and longitudinal systolic strains (*P* < 0.01; Table 4) and little change in radial strains in either patient group.

Tissue characterization – T2-ER and LGE

Although regional oedema was not visually detectable on T2-weighted MRI images, the global-T2-ER was raised in both inflammatory conditions [global ER: normal 2.5 (3.9); myocarditis 4.9 (3.2); RA 3.7 (3.2); *F* = 3.1; *P* = 0.05] (Fig. 1A and B). LGE revealed no evidence of myocardial scar suggestive of previous infarct in epicardial coronary territory in any of the three groups. Global LGE score was raised mildly in only the myocarditis group [6.8 (6.2)], and significantly in the RA group [10.5 (5.2)] when compared with the control level [2.3 (3.9); *F* = 5.3; *P* = 0.01].

Analysis of the relationship between imaging measurements and inflammatory biomarkers showed, in the myocarditis group, a trend of association between CRP and T2-ER (*r* = 0.8; *P* = 0.07) and a significant correlation between CRP and anterolateral longitudinal strain

($r = -0.6$; $P = 0.008$). In the RA group, the following associations with inflammatory markers were noted: (i) CRP levels inversely correlated with SV ($r = -0.6$; $P = 0.02$) and cardiac output ($r = -0.6$; $P = 0.007$); (ii) RF titres correlated with global T2-ER score ($r = 0.7$; $P = 0.04$); and (iii) anti-CCP titres correlated with EF ($r = -0.7$; $P = 0.02$) and global T2-ER score ($r = 0.6$; $P = 0.05$). Moreover, global LGE score displayed a significant association with EDV ($r = -0.5$; $P = 0.01$). There was no association between inflammatory biomarkers and CV risk factors (BP, cholesterol level or smoking status), even when controlling for the presence of CV medication.

Discussion

We demonstrate, using multiparametric cardiac MRI, the presence of a myocardial inflammatory response occurring in the context of self-limiting and sustained inflammatory injury. Both conditions reveal global systolic impairment, in line with globally raised tissue characteristic scores. While myocardial response to self-limiting injury is by wall thickening, the presence of incessant inflammatory harm is characterized by thinned myocardium and enlarged cavities. Of note, in both conditions, the lateral segments appear to be central to this response, displaying the peak of inflammatory change in plasticity and deformation. To the best of our knowledge, this study is the first to examine myocardial function and structure in the presence of sustained systemic inflammation in RA, and to compare and contrast it with a recognized phenotypic model of myocardial inflammation and with healthy control subjects.

Myocarditis represents an inflammation of myocardial tissue, and is likely to be under-diagnosed. In most patients, it develops in the context of infectious disease (via direct viral infection or post-viral immune-mediated reaction), however, myocardial injury via environmental exposure, such as drug- or alcohol-related toxicity, has also been described as a trigger of myocardial inflammation [27, 28]. Pathogenesis includes myocyte injury, local and systemic cytokine-mediated immune responses and cell activation with subsequent cellular infiltration, oedema and necrosis. Fibrotic scarring is also a common feature [28]. Various characteristics observed on imaging have been described, including ventricular failure, wall thickening, regional oedema and fibrosis. Of note, no single clinical or imaging finding confirms the diagnosis of myocarditis with pathognomonic certainty [14, 27].

Our myocarditic cohort exhibits features consistent with these previous observations, including reduced systolic function, increased wall thickness and impaired longitudinal strains, particularly affecting the lateral segments. Reduced systolic performance is likely due to myocardial oedema, which is diffusely spread in the sub-acute phase. Previous findings [29] identified a greater likelihood of lateral wall involvement, indicating the potential presence of a feeble myocardial region, sensitive to inflammatory injury. Our findings are further supported by the link between CRP and regional longitudinal strain.

Previously, no correlation was found between inflammatory biomarkers and tissue characterization measures; this finding is reproduced in our study [15]. Absence of a firm association between CRP and T2-ER score may emphasize the intricacy of subtle tissue changes and likely a need for a greater sample size.

The contemporary view holds CV disease as a dynamic and progressive pathology arising from the combination of endothelial dysfunction, oxidative stress and insulin resistance, with inflammation acting as the common denominator in these processes. Indeed, patients with RA have a two to five times increased risk of developing severe and premature CV disease with shorter life expectancy by 5–10 years, even when matched for traditional CV risk factors [1–8]. The link between increased CV risk and inflammation is supported by a host of vascular evidence (endothelial dysfunction, reduced arterial elasticity and compressibility and increased atherosclerotic burden) [9–11].

Raised levels of inflammatory mediators, such as TNF- α , IL-1, -6 and increased activity of proteolytic enzymes (MMPs), have been implicated in inflammatory tissue injury, such as joint destruction and destabilization of vulnerable plaques [30–33]. It is, therefore, conceivable that the association of elevated inflammatory cytokine levels may also lead to concomitant myocardial tissue injury. Previous studies investigated the role of a pro-inflammatory cytokine profile in the development of LV dysfunction and cardiomyopathy in an animal model and humans subjects [34–37]. Persistently raised and pathophysiologically relevant circulating concentrations of TNF- α lead to deleterious changes in LV structure and function, with time-dependent depression in LV function, cardiac myocyte shortening and LV dilation. These mechanisms appear to involve simultaneous increase in fibrillar content and activation of collagenolytic enzymes, MMPs [38]. Progressive degradation of fibrillar collagen facilitates mural realignment of myofibrillar bundles and leads to increased LV wall thinning and LV dilation [39].

The findings in our RA cohort correspond well to these postulations and provide an important insight into myocardial responses in the presence of sustained systemic inflammation. Ongoing inflammatory injury and persistence of tissue oedema in RA myocardium is reflected in increased T2-ER. Wall thinning and cavity dilation with reduced global systolic performance reveal globally affected myocardial tissue. Globally raised LGE score may correspond to diffuse myocardial fibrosis [16, 37]. Moreover, despite the absence of overt symptoms, the greater share of CV medication in the RA group reflects the degree of disease progression, which may, in line with the finding of lower EF, further suggest that some of these patients may have been in NYHA I/II class. Significant associations between inflammatory markers and functional imaging measurements thus support the hypothesis that these changes reflect sustained inflammatory myocardial injury and potentially signify the phenotypic features of myocardial plasticity in response to sustained inflammatory injury.

Clinical perspective

Addressing CV risk in the RA population remains an important priority. A distinctive myocardial inflammatory phenotype, discernable by means of non-invasive imaging, may provide a bio-signature of the sequelae of systemic inflammatory responses affecting the heart muscle. The findings of this study may provide the basis for a future randomized controlled clinical trial, addressing CV endpoints, CV prevention strategies as well as proving useful in assessments of any CV benefit/harm of existing and emerging therapeutic intervention in this susceptible population.

Limitations

Few limitations apply to our study. Assessment of regional strain values in this study was performed by employing the physiological principles and validated formulas previously described [21, 22]; however, measurements in this study have been made on the cine images. The choice of this approach over other described methodologies of assessment of deformation with MRI offers higher temporal resolution, 16-segment analysis, fast post-processing analysis and potential for use in routine clinical application. Next, involvement of skeletal muscle in systemic inflammation may limit the sensitivity of a signal intensity analysis normalized to skeletal muscle [14, 16] and should be taken into consideration in patients with evidence of skeletal muscle inflammation. Lastly, this study aimed to establish physiological relationships in sub-acute and chronic inflammatory phenotypes, identifying RA patients comparable with those encountered in the more studied myocarditis population. Future studies are needed to translate the present findings to the general rheumatoid population.

Conclusions

Taken together, the present findings may signify the phenotypic features of myocardial plasticity and deformation in response to self-limiting and sustained inflammatory injury.

Rheumatology key messages

- Self-limiting and sustained inflammatory injury may have phenotypic features of myocardial plasticity and deformation.
- A potential phenotypic myocardial signature may have utility in CV prevention strategies in susceptible populations.

Acknowledgements

We would like to acknowledge the following for their contribution: Janina Rebakowski, Corinna Else and Gudrun Grosser at the German Heart Institute; Dr Philippe Pouliot in post-processing analysis; rheumatology nurses Maria Lukacs and Angela Smith; staff of the clinical research facilities of the Robert-Steiner Unit

and Sir John McMichael Centre at the Hammersmith Hospital, London.

Funding: This study was supported by Hammersmith Hospitals Trustees Award (to V.O.P.). Funding to pay the Open Access publication charges for this article was provided by Imperial College London.

Disclosure statement: The authors have declared no conflicts of interest.

References

- 1 Libby P. Inflammation in atherosclerosis. *Nature* 2002;420: 868–74.
- 2 Szmítko PE, Wang CH, Weisel RD *et al.* New markers of inflammation and endothelial cell activation. Part I. *Circulation* 2003;108:1917–23.
- 3 Van Leuven SI, Franssen R, Kastelein JJ, Levi M, Stroes ES, Tak PP. Systemic inflammation as a risk factor for atherothrombosis. *Rheumatology* 2008;47:3–7.
- 4 Goodson NJ, Wiles NJ, Lunt M, Barrett EM, Silman AJ, Symmons DP. Mortality in early inflammatory polyarthritis: cardiovascular mortality is increased in seropositive patients. *Arthritis Rheum* 2002;46:2010–9.
- 5 Roman MJ, Shanker BA, Davis A *et al.* Prevalence and correlates of accelerated atherosclerosis in systemic lupus erythematosus. *N Engl J Med* 2003;349:2399–406.
- 6 Tonetti MS, D'Aiuto F, Nibali L *et al.* Treatment of periodontitis and endothelial function. *N Engl J Med* 2007; 356:911–20.
- 7 Tousoulis D, Charakida M, Stefanadis C. Endothelial function and inflammation in coronary artery disease. *Heart* 2006;92:441–4.
- 8 Douglas KMJ, Pace AV, Treharne GJ *et al.* Excess recurrent cardiac events in rheumatoid arthritis patients with acute coronary syndrome. *Ann Rheum Dis* 2006;65: 348–53.
- 9 Hurlimann D, Forster A, Noll G *et al.* Anti-tumor necrosis factor- α treatment improves endothelial function in patients with rheumatoid arthritis. *Circulation* 2002;106: 2184–7.
- 10 Park YB, Ahn CW, Choi HK *et al.* Atherosclerosis in rheumatoid arthritis: morphologic evidence obtained by carotid ultrasound. *Arthritis Rheum* 2002;46:1714–9.
- 11 Kumeda Y, Inaba M, Goto H *et al.* Increased thickness of the arterial intima-media detected by ultrasonography in patients with rheumatoid arthritis. *Arthritis Rheum* 2002; 46:1489–97.
- 12 Giles JT, Fernandes V, Lima JAC, Bathon JM. Myocardial dysfunction in rheumatoid arthritis: epidemiology and pathogenesis. *Arthritis Res Ther* 2005;7:195–207.
- 13 Friedrich MG, Strohm O, Schulz-Menger J, Marciniak H, Luft FC, Dietz R. Contrast media-enhanced magnetic resonance imaging visualizes myocardial changes in the course of viral myocarditis. *Circulation* 1998;97:1802–9.
- 14 Friedrich MG, Sechtem U, Schulz-Menger J *et al.* International consensus group on cardiovascular magnetic resonance in myocarditis. Cardiovascular magnetic resonance in myocarditis: a JACC White Paper. *J Am Coll Cardiol* 2009;53:1475–87.

- 15 Abdel-Aty H, Boyé P, Zagrosek A *et al.* Diagnostic performance of cardiovascular magnetic resonance in patients with suspected acute myocarditis: comparison of different approaches. *J Am Coll Cardiol* 2005;45: 1815–22.
- 16 Abdel-Aty H, Simonetti O, Friedrich MG. T2-weighted cardiovascular magnetic resonance imaging. *J Magn Reson Imaging* 2007;26:452–9.
- 17 Neubauer S. Cardiac physiology investigated by new methods of imaging. *Clin Med* 2007;7:189–91.
- 18 Luqmani R, Hennell S, Estrach C *et al.* British Society for Rheumatology, British Health Professionals in Rheumatology Standards, Guidelines and Audit Working Group. British Society for Rheumatology and British Health Professionals in Rheumatology guideline for the management of rheumatoid arthritis (after the first 2 years). *Rheumatology* 2009;48:436–9.
- 19 Paetsch I, Jahnke C, Fleck E, Nagel E. Current clinical applications of stress wall motion analysis with cardiac magnetic resonance imaging. *Eur J Echocardiogr* 2005;6:317–26.
- 20 Gebker R, Jahnke C, Manka R *et al.* Additional value of myocardial perfusion imaging during dobutamine stress magnetic resonance for the assessment of coronary artery disease. *Circ Cardiovasc Imaging* 2008;1:122–30.
- 21 Kowalski M, Kukulski T, Jamal F *et al.* Can natural strain and strain rate quantify regional myocardial deformation? A study in healthy subjects. *Ultrasound Med Biol* 2001;27: 1087–97.
- 22 Herbots L, Maes F, D'hooge J *et al.* Quantifying myocardial deformation throughout the cardiac cycle: a comparison of ultrasound strain rate, grey-scale M-mode and magnetic resonance imaging. *Ultrasound Med Biol* 2004;30:591–8.
- 23 WHO. Physical status: the use and interpretation of anthropometry. Report of a WHO Expert Committee. WHO Technical Report Series 854. Geneva: World Health Organization, 1995.
- 24 Haycock GB, Schwartz GJ, Wisotsky DH. Geometric method for measuring body surface area: a height-weight formula validated in infants, children and adults. *J Pediatr* 1978;93:62–6.
- 25 Grossman W, Braunwald E, Mann T, McLaurin LP, Green LH. Contractile state of the left ventricle in man as evaluated from end-systolic pressure-volume relations. *Circulation* 1977;56:845.
- 26 Reichek N, Wilson J, St John Sutton M, Plappert TA, Goldberg S, Hirshfeld JW. Noninvasive determination of left ventricular end-systolic stress: validation of the method and initial application. *Circulation* 1982;65: 99–108.
- 27 Maisch B, Portig I, Ristic A, Hufnagel G, Pankuweit S. Definition of inflammatory cardiomyopathy (myocarditis): on the way to consensus. A status report. *Herz* 2000;25: 200–9.
- 28 Liu PP, Mason JW. Advances in the understanding of myocarditis. *Circulation* 2001;104:1076–82.
- 29 Mahrholdt H, Goedecke C, Wagner A *et al.* Cardiovascular magnetic resonance assessment of human myocarditis: a comparison to histology and molecular pathology. *Circulation* 2004;109:1250–8.
- 30 Lombardo A, Biasucci LM, Lanza GA *et al.* Inflammation as a possible link between coronary and carotid plaque instability. *Circulation* 2004;109:3158–63.
- 31 Liuzzo G, Goronzy JJ, Yang H *et al.* Monoclonal T-cell proliferation and plaque instability in acute coronary syndromes. *Circulation* 2000;101:2883–8.
- 32 Biasucci LM, Liuzzo G, Colizzi C, Maseri A. The role of cytokines in unstable angina. *Expert Opin Investig Drugs* 1998;7:1667–72.
- 33 Gonzalez-Juanatey C, Testa A, Garcia-Castelo A *et al.* Echocardiographic and Doppler findings in long-term treated rheumatoid arthritis patients without clinically evident cardiovascular disease. *Semin Arthritis Rheum* 2004;33:231–8.
- 34 Anker SD, Coats AJ. How to RECOVER from RENAISSANCE? The significance of the results of RECOVER, RENAISSANCE, RENEWAL and ATTACH. *Int J Cardiol* 2002;86:123–30.
- 35 Sharma R, Coats AJS, Anker SD. The role of inflammatory mediators in chronic heart failure: cytokines, nitric oxide, and endothelin-1. *Int J Cardiol* 2000;72:175–86.
- 36 Hegewisch S, Weh HJ, Hossfeld DK. TNF-induced cardiomyopathy. *Lancet* 1990;2:294–5.
- 37 Bozkurt B, Kribbs S, Clubb FJ Jr *et al.* Pathophysiologically relevant concentrations of tumor necrosis factor- α promote progressive left ventricular dysfunction and remodeling in rats. *Circulation* 1998;97:1382–91.
- 38 Weber KT. Cardiac interstitium in health and disease: the fibrillar collagen network. *J Am Coll Cardiol* 1989;13: 1637–52.
- 39 Spinale FG, Coker ML, Krombach SR *et al.* Matrix metalloproteinase inhibition during the development of congestive heart failure: effects on left ventricular dimensions and function. *Circ Res* 1999;85: 364–76.