

Treatment of pancreatic head cancer with obstructive jaundice by endoscopy ultrasonography-guided gastrojejunostomy

A case report and literature review

Zhaohua Shen, MD, Li Tian, MD, Xiaoyan Wang, MD*

Abstract

Rationale: Ultrasonography-guided gastrojejunostomy (EUS-GJ) might be a safe, innovative and minimally invasive interventional treatment for patients with gastric outlet obstruction (GOO) as an alternative to the surgical approach. To date, few cases have been reported in the literature.

Patient concerns: A case of pancreatic head carcinoma with obstructive jaundice occurred in a 78-year-old man with a prior history of pancreatic head cancer. Biliary stent placement was conducted 1 year earlier.

Diagnoses: The patient was diagnosed with pancreatic cancer, pulmonary infection, pyloric obstruction, and biliary stent implantation.

Interventions: EUS-GJ was performed. The wire and a double-balloon catheter reached the position of stenosis, then a double mushroom head bracket was released under EUS. The position was confirmed via X-ray.

Outcomes: The symptoms of obstruction were alleviated. No recurrence of obstruction, bleeding, perforation, and other complications occurred for the following 1.5 months while he died because of whole body spread of pancreatic cancer.

Lessons: EUS-GJ may be reliable and effective for patients with GOO.

Abbreviations: CT = computed tomography, ES = enteral stenting, EUS-GJ = ultrasonography-guided gastrojejunostomy, GOO = gastric outlet obstruction, Lap-GJ = laparoscopic gastrojejunostomy.

Keywords: endoscopic ultrasonography, gastric outlet obstruction, gastrojejunostomy, obstructive jaundice, pancreatic head cancer

1. Introduction

Pancreatic cancer is one of the deadliest malignant tumors with a median survival time of only 6 months.^[1] This is because most

pancreatic cancers have a high tendency to metastasize.^[2] Pancreatic cancer display no obvious clinical signs at an early phase and is usually diagnosed at an advanced phase with limited response to treatment.^[3] Pancreatic head cancer is not common, but the degree of malignancy is extremely high. The condition develops rapidly, and the 5-year survival rate of patients with resectable tumors is only <5%, resulting in a serious threat to peoples' lives.

Gastric outlet obstruction (GOO) is frequently seen in patients with periampullary cancers. Obstructive jaundice is a common clinical manifestation of pancreatic cancers, especially in patients with malignant tumors of the head and neck of the pancreas.^[4] It can lead to GOO, which causes nausea, vomiting, difficulty eating, and so on and seriously decreases the quality of life of patients. Surgery is the first choice to relieve obstruction, but some patients lose the chance of surgery at the time of treatment. Therefore, patients who cannot tolerate surgery usually need to undergo endoscopic placement of a metal stent to ease obstruction. Stents include fully covered metal stents and noncovered metal stents. Noncovered metal stents are often blocked by nascent tumor tissues as tumors progress. In addition, covered metal stents are easily displaced for long periods of time. Both stents cannot relieve the symptoms long term and need to be repeatedly dredged or replaced. Therefore, there is an urgent need for a new technology that not only improves symptoms of obstruction chronically but also has the characteristics of small trauma. A new treatment method has

Editor: N/A.

Zhaohua Shen and Li Tian contributed equally to this work.

The case report was finished and approved by Ethics Committee of The Third Xiangya Hospital of Central South University. The personal information of the patient was maintained anonymously. Informed consent form was signed by the patient.

This research was funded by grants from the National Natural Science Foundation of China (81670504 and 81472287).

The authors have no conflicts of interest to disclose.

Department of Gastroenterology, Third Xiangya Hospital, Central South University, Changsha, Hunan, China.

* Correspondence: Xiaoyan Wang, Department of Gastroenterology, Third Xiangya Hospital, Central South University, 138 Tongzipo Road, Yuelu District, Changsha, Hunan 410013, China (e-mails: wangxiaoyan2913@163.com, wxy20011@163.com).

Copyright © 2018 the Author(s). Published by Wolters Kluwer Health, Inc. This is an open access article distributed under the terms of the Creative Commons Attribution-Non Commercial-No Derivatives License 4.0 (CCBY-NC-ND), where it is permissible to download and share the work provided it is properly cited. The work cannot be changed in any way or used commercially without permission from the journal.

Medicine (2018) 97:28(e11476)

Received: 22 March 2018 / Accepted: 18 June 2018

<http://dx.doi.org/10.1097/MD.0000000000011476>

recently appeared in the world, namely, endoscopic ultrasonography-guided gastrojejunostomy (EUS-GJ).^[5-7] This method causes less trauma, less complications, and has definite

curative effects. While there are few case reports, our institution completed one case of EUS-GJ recently. The operation is summarized as follows.

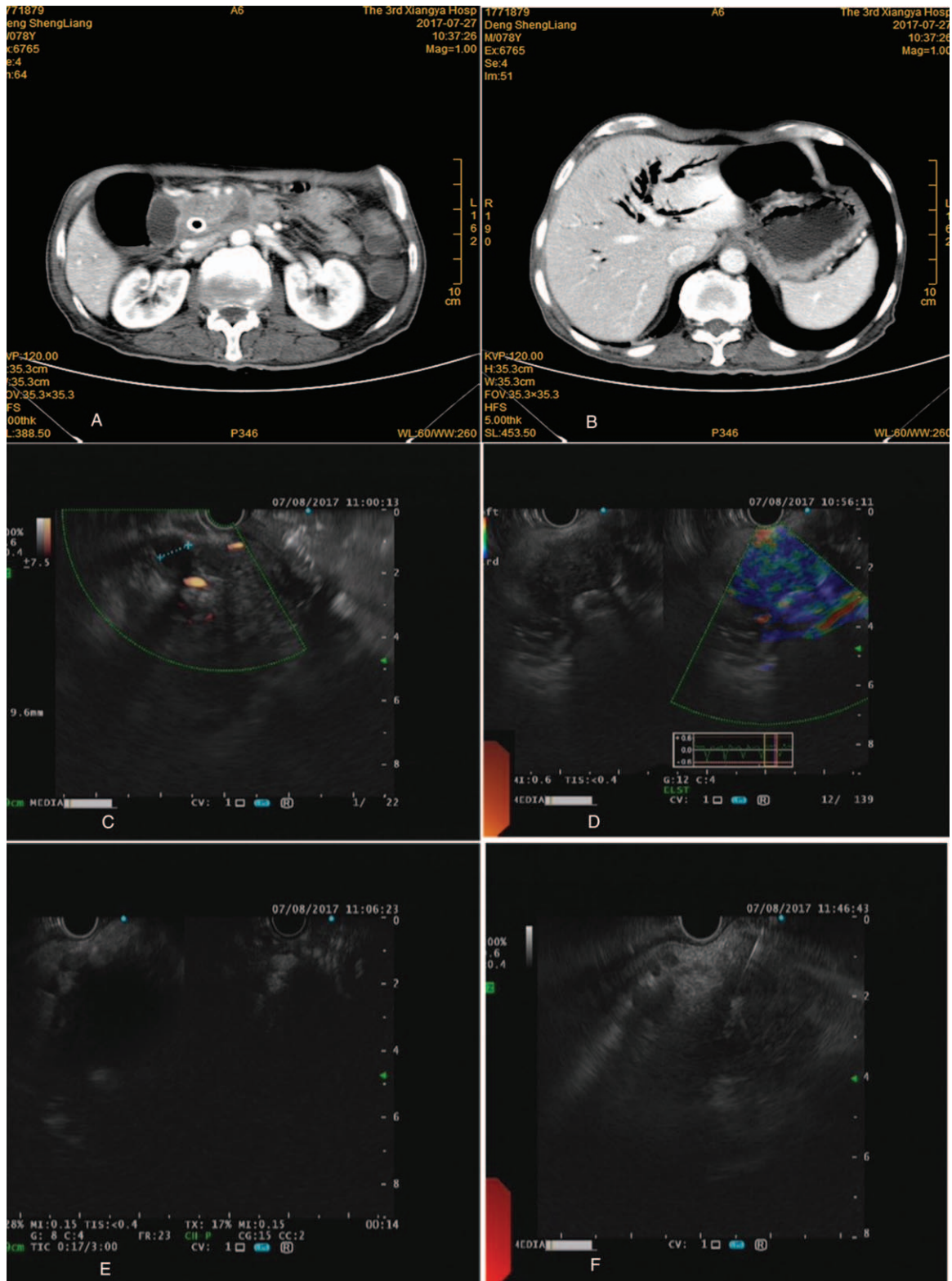


Figure 1. Abdominal computed tomography and ultrasound gastroscopy results before ultrasonography-guided gastrojejunostomy. (A) Pancreatic head mass secondary to dilatation of extrahepatic bile duct. (B) Expansion of main pancreatic duct. (C) Pancreatic head mass and common bile duct. (D) Endoscopic ultrasound elastography. (E) Contrast enhanced endoscopic ultrasound. (F) Endoscopic ultrasonography-guided fine-needle aspiration.

2. Case report

A 78-year-old man was admitted to our hospital because of vomiting after eating for more than 1 month in 2017. He had been diagnosed with “pancreatic cancer” in our hospital in 2016 according to the results of computed tomography (CT) scan and magnetic resonance imaging, and biliary stent placement was undertaken; the patient was discharged after the symptoms improved. The patient had a history of “diabetes” and “cerebral infarction.” Physical examination showed that the patient suffered from extreme weight loss and severe malnutrition. There were no signs of skin and scleral jaundice. Laboratory tests indicated the following: hemoglobin, 117 g/L (norm: 130–175 g/L); albumin, 27.2 g/L (norm: 40–55 g/L); total bilirubin, 40.4 $\mu\text{mol/L}$ (norm: 3.42–20.5 $\mu\text{mol/L}$); direct bilirubin, 24.4 $\mu\text{mol/L}$ (norm: 0–6.84 $\mu\text{mol/L}$); and CA199, 2503 U/mL (norm: 0–27 U/mL). The preliminary diagnoses were pancreatic cancer, pulmonary infection, pyloric obstruction, and biliary stent implantation. Symptomatic and supportive treatment was initiated. Chest CT scan indicated that the right lung was infected. Total digestive angiography indicated that the lesion was considered a space occupying lesion of pancreatic uncinata, which repressed the descending segment of the duodenum. Abdominal CT showed the changes in the biliary stent implant and the space occupying lesion of the pancreatic head occupied by the lesion, with progression of the obstruction and expansion of the main pancreatic duct (Fig. 1A,B). The results of the ultrasound gastroscopy showed that the pancreatic head mass had invaded the common bile duct, and postoperative duodenum endoscopic ultrasonography-guided fine-needle aspiration (EUS-FNA) showed that the mass might be cancer. Compression by the duodenal mass caused lumen stenosis and gastric retention (Fig. 1C–F). From the smear of the pancreatic head, we could see tumor cells, which were considered a sign of a poorly differentiated cancer. The biopsy indicated that there were extremely few glandular epithelium and scattered abnormal cells in the inflammatory exudate of the pancreatic head mass, which might be indicative of a malignant tumor. Intestinal mucosa biopsy of the lower segment showed erosion and lymphocytic infiltration in the interstitial tissue. Symptomatic and supportive treatment was initiated.

The patient was malnourished. The pancreatic head compressed the duodenum. To relieve the obstruction, EUS-GJ was conducted. The patient signed the informed consent form, and the surgery was approved by the Institutional Review Board. The surgery was performed under general anesthesia administered via endotracheal intubation. Under the guidance of the X-ray, the wire was passed through the stenosis and arrived distal to the ligament of Treitz. A double-balloon catheter was passed through the region of stenosis along with the guidewire. Meglumine diatrizoate was injected as a contrast agent, and the image was developed under X-ray. The position of the double balloon was confirmed with EUS. Saline was injected between the double balloon-enclosed jejunum. Then, a double mushroom head bracket was released under EUS (Olympus ME, Tokyo, Japan) guidance, and the position was verified via X-ray. Methylene blue was poured into the jejunum through the catheter, and it overflowed from the cavities of the stomach of the double mushroom head (Fig. 2). The operation went smoothly. The patient recovered well after surgery. Gastrointestinal angiography showed that the stomach wiggled slowly. The tension was acceptable. The contour was still regular. Obvious signs of disruption and collection were not seen, and there were no apparent niche and filling defects. Development could be seen in the intrahepatic bile duct, hepatocystic duct stent, and gastro-jejunosotomy stent. Abdomen CT illustrated that the volume of the pancreatic head cancer had increased compared to previous observations. Involvement of the duodenum occurred, with the possibility of mesenteric vein tumor thrombus. Peritoneal metastasis and ascites may have occurred. The degree of pancreaticobiliary expansion and obstruction were roughly the same as before. Postoperative changes of EUS-GJ have been seen (Fig. 3). Ultrasound gastroscopy showed that the gastric cavity was significantly reduced to normal levels, indicating a good stent position. The intestinal mucosa was visible through the double mushroom head stent. The obstruction symptom of the patient was relieved. No postprocedural bleeding, peritonitis, perforation, and other complications happened and he was discharged. No recurrence of obstructive symptoms or other adverse

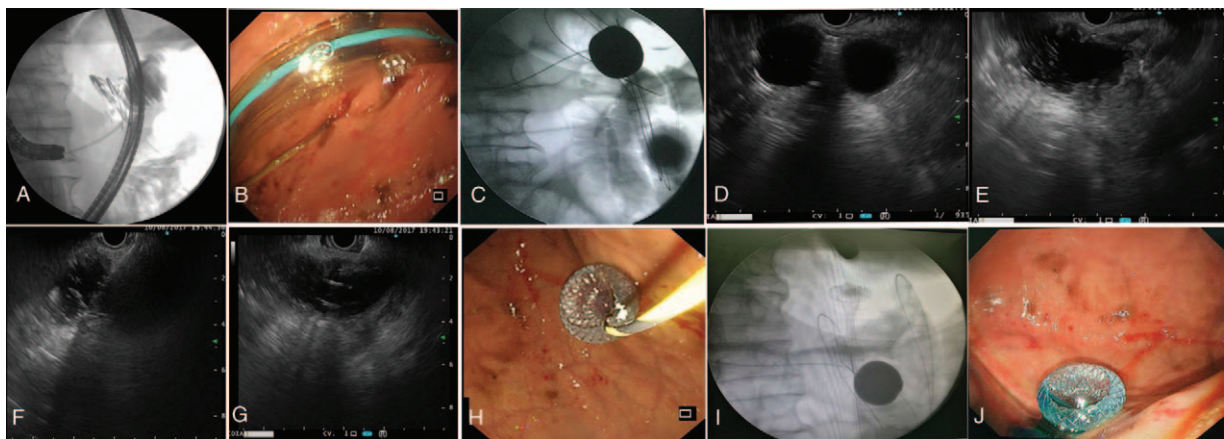


Figure 2. Surgical methods of ultrasonography-guided gastrojejunostomy. (A) The guidewire transited past the stenosis and reached the distal ligament of Treitz. (B) Double-balloon catheter went through the stenosis along with the guidewire. (C) Meglumine diatrizoate was injected into the double-balloon catheter. (D) The position of the double-balloon catheter was confirmed under endoscopic ultrasonography (EUS). (E) Saline was used to fully fill the region between the double balloon-enclosed jejunum. (F) Puncture of the jejunal lumen between the double balloon under EUS. (G, H) Release of the double-mushroom head bracket under EUS. (I) Localization of the mushroom head bracket via X-ray. (J) Infusion of methylene blue into the jejunum.

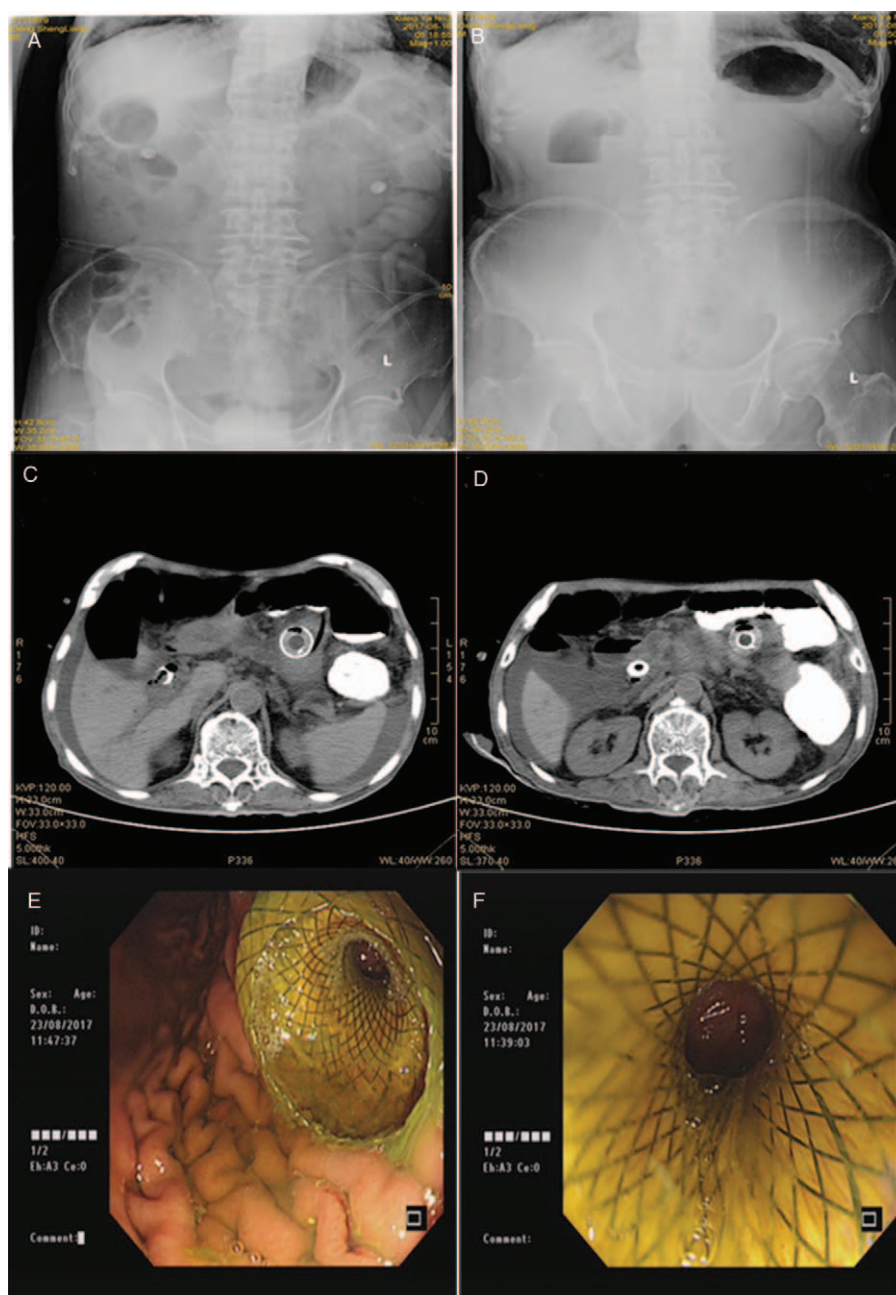


Figure 3. Postoperative results. (A, B) Erect abdominal plain film and organic iodine solution radiography. (C, D) Postoperative abdominal computed tomography. (E, F) Postoperative gastroscopy.

reactions occurred in the following 1.5 months, while he died because of whole body spread of pancreatic cancer.

3. Discussion

In recent years, with the continuous development and replacement of endoscopic techniques and various instrument accessories, endoscopy has played an increasingly vital role in the diagnosis and treatment of various diseases of the digestive system. The continuous innovation of minimally invasive endoscopic surgery provides the option of a new mini-invasive therapy for many patients with gastrointestinal and biliary and pancreatic diseases who cannot or are not willing to be operated on.

The EUS-GJ involves puncturing the proximal small intestine via the stomach guided by an EUS; then, a guidewire is placed, and a large diameter full stent is laid through the wire to open up a passage between the stomach and small intestine. That is also done to recreate a new path between the stomach and the small intestine, solving the problem of duodenal obstruction. Double endoscopic bypass, namely EUS-GJ and EUS-guided biliary drainage, is also effective for patients who suffer from GOO.^[8] Compared with previous laparotomies, EUS-GJ causes little trauma and has a shorter operative time, less pain, and fast recovery, which fully reflects the advantages of minimally invasive endoscopic procedures. Compared with endoscopic enteral stenting (ES), the recurrence and reintervention rates of

EUS-GJ were significantly reduced.^[9] Compared with laparoscopic gastrojejunostomy (Lap-GJ), the technical and clinical success rates of EUS-GJ are comparable, and the complications and costs are significantly lower than those of surgery.^[10] Therefore, after consulting with the patient, we decided to choose EUS-GJ. There have been few reports on the treatment of malignant GOO using EUS-GJ since 2012.^[11-14] Its main advantage is that the anastomotic site is far away from the primary tumor and is not easily blocked. It can be maintained with patency for a long time, and multiple endoscopic interventions are not needed. It has its own unique advantages for the palliative treatment of malignant GOO. The first important step of EUS-GJ is to select the appropriate puncture site, which should be as far away from the tumor as possible. The second technical difficulty is related to the successful puncturing of the proximal jejunum. The activity of the jejunum is great, the location is not fixed, and it frequently squirms. Accurately puncturing the proximal jejunum is a very challenging problem. We use a special double-balloon catheter to solve this problem. Two balloons are expanded before and after the puncture site. Then, saline is injected into the middle of the 2 balloons to expand the bowel region to be punctured, which is similar to the method reported in the literature.^[5]

Adverse events of EUS-GJ include stent displacement, intestinal fistula, and bleeding. Irani et al^[15] described 5 various techniques to conduct EUS-GJ and found stent displacement was the most common relevant adverse reaction. The emergence of the new double-mushroom head stent reduced the stent shift in different endoscopic anastomosis surgeries. A number of studies have adopted the double-mushroom head metal stent, and stent displacement did not occur in an animal model of EUS-GJ.^[6,16] Since then, this type of stent has also been successfully used in many patients.^[11-12] The appearance of an intestinal fistula is mainly related to the operation process. Gastrointestinal perforation might happen in the process of puncturing. However, as long as the stent can be advanced smoothly, the design of the double-mushroom head full-thickness membrane can block the perforation site and effectively prevent further development of an intestinal fistula. Therefore, shortening the time interval between puncture and stent implantation can effectively reduce the incidence of an intestinal fistula.

Combined with the literature and our experience, EUS-GJ holds obvious advantages such as short operation time, no hemorrhage during operation, quick recovery after operation, resuming a regular diet on the 3rd day after operation, and no serious postoperative complications. In the short-term follow-up, EUS-GJ combines the advantages of both surgery and ES, while its long-term effects still require further studies. With the development of this technology and the improvement of stent-puncture release systems, EUS-GJ will be not only used for the treatment of patients with malignant GOO but also for the treatment of benign GOO, which requires surgical treatment beforehand. It might also be used in gastrointestinal shortcut operations.

4. Conclusion

The EUS has undergone a transition from a simple diagnostic technique to a treatment approach. We hope that EUS will guide more therapeutic operations in the future such as ablation technique,^[17] injection technique,^[18] digestive tract anastomosis,^[19] and so on. EUS will also be increasingly widely used in pancreatic neoplastic diseases. However, it is still in its infancy.

Doctors should strictly review the indications and cautiously select the treatment.

Author contributions

ZS wrote the article. LT collected the clinical data. XW revised the manuscript. All the authors read and approved the final version.

Conceptualization: Li Tian.

Data curation: Li Tian.

Resources: Li Tian.

Writing – original draft: Zhaohua Shen.

Writing – review & editing: Xiaoyan Wang.

References

- Viale A, Pettazoni P, Lyssiotis CA, et al. Oncogene ablation-resistant pancreatic cancer cells depend on mitochondrial function. *Nature* 2014;514:628–32.
- Whittle MC, Izeradjene K, Rani PG, et al. RUNX3 controls a metastatic switch in pancreatic ductal adenocarcinoma. *Cell* 2015;161:1345–60.
- Boj SF, Hwang CI, Baker LA, et al. Organoid models of human and mouse ductal pancreatic cancer. *Cell* 2015;160:324–38.
- De La Cruz MS, Young AP, Ruffin MT. Diagnosis and management of pancreatic cancer. *Am Fam Physician* 2014;89:626–32.
- Itoi T, Itokawa F, Uraoka T, et al. Novel EUS-guided gastro-jejunostomy technique using a new double-balloon enteric tube and lumen-apposing metal stent (with videos). *Gastrointest Endosc* 2013;78:934–9.
- Khashab MA, Kumbhari V, Grimm IS, et al. EUS-guided gastroenterostomy: the first U.S. clinical experience (with video). *Gastrointest Endosc* 2015;82:932–8.
- Rimbas M, Larghi A, Costamagna G. Endoscopic ultrasound-guided gastroenterostomy: are we ready for prime time? *Endosc Ultrasound* 2017;6:235–40.
- Brewer Gutierrez OI, Nieto J, Irani S, et al. Double endoscopic bypass for gastric outlet obstruction and biliary obstruction. *Endosc Int Open* 2017;5:E893–9.
- Chen YI, Itoi T, Baron TH, et al. EUS-guided gastroenterostomy is comparable to enteral stenting with fewer re-interventions in malignant gastric outlet obstruction. *Surg Endosc* 2017;31:2946–52.
- Perez-Miranda M, Tyberg A, Poletto D, et al. EUS-guided gastro-jejunostomy versus laparoscopic gastrojejunostomy an international collaborative study. *J Clin Gastroenterol* 2017;51:896–9.
- Khashab MA, Tieu AH, Azola A, et al. EUS-guided gastro-jejunostomy for management of complete gastric outlet obstruction. *Gastrointest Endosc* 2015;82:745.
- Itoi T, Tsuchiya T, Tonozuka R, et al. Novel EUS-guided double-balloon-occluded gastrojejunostomy bypass. *Gastrointest Endosc* 2016;83:461–2.
- Itoi T, Ishii K, Ikeuchi N, et al. Prospective evaluation of endoscopic ultrasonography guided double-balloon-occluded gastrojejunostomy bypass (EPASS) for malignant gastric outlet obstruction. *Gut* 2016;65:193–5.
- Tyberg A, Perez-Miranda M, Sanchez-Ocaña R, et al. Endoscopic ultrasound-guided gastrojejunostomy with a lumen-apposing metal stent: a multicenter, international experience. *Endosc Int Open* 2016;4:E276–81.
- Irani S, Baron TH, Itoi T, et al. Endoscopic gastroenterostomy: techniques and review. *Curr Opin Gastroenterol* 2017;33:320–9.
- Binmoeller KF, Shah JN. Endoscopic ultrasound-guided gastroenterostomy using novel tools designed for transluminal therapy: a porcine study. *Endoscopy* 2012;44:499–503.
- Arcidiacono PG, Carrara S, Reni M, et al. Feasibility and safety of EUS-guided cryothermal ablation in patients with locally advanced pancreatic cancer. *Gastrointest Endosc* 2012;76:1142–51.
- Matsumoto K, Yamao K, Okubo K, et al. Endoscopic ultrasound-guided ethanol injection in the pancreas in a porcine model: a preliminary study. *J Gastroenterol Hepatol* 2008;23((pt 2)):e1–6.
- Artifon EL, Frazão MS, Wodak S, et al. Endoscopic ultrasound-guided choledochoduodenostomy and duodenal stenting in patients with unresectable periampullary cancer: one-step procedure by using linear echoendoscopy. *Scand J Gastroenterol* 2013;48:374–9.