

A novel endoscopic imaging system for quantitative evaluation of colonic mucosal inflammation in patients with quiescent ulcerative colitis



Authors

Yusuke Honzawa¹, Minoru Matsuura¹, Hirokazu Higuchi², Takaki Sakurai³, Hiroshi Seno¹, Hiroshi Nakase⁴

Institutions

- 1 Department of Gastroenterology and Hepatology, Kyoto University Hospital, Kyoto, Japan
- 2 Department of Medical Supply, Kyoto University Hospital, Kyoto, Japan
- 3 Laboratory of Anatomic Pathology, Kyoto University Hospital, Kyoto, Japan
- 4 Department of Gastroenterology and Hepatology, Sapporo Medical University School of Medicine, Sapporo, Japan

submitted 2.3.2019

accepted after revision 5.7.2019

Bibliography

DOI <https://doi.org/10.1055/a-0990-9375> |
Endoscopy International Open 2020; 08: E41–E49
© Georg Thieme Verlag KG Stuttgart · New York
eISSN 2196-9736

Corresponding author

Minoru Matsuura, MD PhD, Department of Gastroenterology and Hepatology, Graduate School of Medicine, Kyoto University, 54 Shogoin Kawahara-cho, Sakyo-ku, Kyoto 606-8507, Japan
Fax: +81-75-7514303
minomats@kuhp.kyoto-u.ac.jp

ABSTRACT

Background and study aims Mucosal healing (MH) is associated with clinical outcome in ulcerative colitis (UC) patients. In most clinical trials, a Mayo endoscopic subscore (MES) of 0 or 1 is defined as MH. However, several recent studies have reported that clinical outcome is different between UC patients with MES 0 and those with MES 1. In addition, the MES is subjective and may differ among endoscopists. Therefore, a repeatable and objective scoring system is required to distinguish MES 0 from MES 1, even in clinically quiescent UC. Here, we assessed the usefulness of new image-enhancing endoscopic technology, the i-scan TE-c, to quantitatively evaluate colonic inflammation in patients with quiescent UC.

Methods We retrospectively reviewed the data from 52 UC patients in clinical remission who had undergone routine colonoscopy with standard white light. The white-light images were reassessed using the new system, and the degree of colonic mucosal inflammation was quantified according to the MAGIC (Mucosal Analysis of Inflammatory Gravity by i-scan TE-c Image) score. We used the i-scan TE-c system to investigate the association among the MAGIC score, MES, and histologic activity (Geboes score).

Results The MAGIC score was significantly higher in the MES 1 group than in the MES 0 group ($P=0.0034$). The MAGIC score significantly correlated with the Geboes score ($P=0.015$).

Conclusions Our novel image-enhancing endoscopic system was useful for objective and quantitative evaluation of MH in patients with quiescent UC. Further clinical studies using this imaging system are required to confirm its clinical benefit for the management of UC patients.

Introduction

Ulcerative colitis (UC) is characterized by relapsing and remitting intestinal inflammation of unknown etiology [1, 2]. Mucosal healing (MH) has emerged as a therapeutic goal in the management of patients with UC because of increasing evidence that MH is associated with a better clinical outcome, such as

sustained clinical remission, lower hospitalization rates, and reduced colectomy rates [3–5]. Among the endoscopic indices for monitoring UC disease activity, the Mayo endoscopic subscore (MES) of 0 or 1 is often used as the definition of MH in clinical trials; however, several studies have indicated a distinct difference in the relapse rate between clinically quiescent UC patients with MES 0 versus MES 1. One reason for the difference

is that assessment of MES 0 or 1 varies widely between endoscopists [6–9]. In addition, other studies have indicated that endoscopic MH does not necessarily reflect quiescent microscopic UC disease activity [10, 11]. Bryant et al. reported that microscopic inflammation persists in 25% of patients with endoscopic MH [12]. Moreover, persistent microscopic inflammation in the colonic mucosa is associated with a higher relapse rate [13]. Histologic evaluation with endoscopic biopsies enables detailed assessments of colonic inflammation in UC patients [14, 15]; however, mucosal biopsy is an invasive method with a potential risk of complications, such as perforation, which may increase costs and delay treatment for patients who require immediate therapeutic intervention. Therefore, a noninvasive, repeatable, and objective scoring system for evaluating mucosal inflammation needs to be established.

The recent development of advanced endoscopic imaging modalities, including both virtual chromoendoscopy and magnification endoscopy, enables endoscopists to visualize and interpret the mucosal details of the colon [16, 17]. Among them, the i-scan is a newly developed image-enhancing endoscopic technique from HOYA/PENTAX (Tokyo, Japan) [18]. The i-scan TE-c is a digital transmission method available for the HOYA/PENTAX EPK-i system in conjunction with the EC38-i10M video colonoscope. This system provides image-enhancing technology to emphasize the mucosal microvasculature and vascular changes, which allows for early detection of several gastrointestinal tumors and dysplastic lesions in inflammatory bowel disease (IBD) [18, 19]. In addition, previous studies reported that vascular images of colonic mucosa using the new advanced high definition (HD) endoscopic techniques including i-scan are associated with disease prognosis in UC patients [20–22]. Iacucci et al. showed that subtle histological abnormalities underlying the healed mucosa of the colon in UC patients could be detected using HD colonoscopy with i-scan [23]. Neumann et al. reported that mucosal vascular changes in the colon visualized using virtual chromoendoscopy with the i-scan predicts the severity and extent of mucosal inflammation in patients with IBD compared with those imaged with conventional white-light endoscopy [24]; however, the assessment of those modalities was subjective and not quantitative.

The aim of this study, therefore, is to assess the usefulness of a new endoscopic imaging system using the i-scan TE-c in the objective evaluation of colonic mucosal inflammation in clinically quiescent UC patients with MES 0 or 1.

Material and methods

Patients

From January 2011 through August 2016, we retrospectively reviewed the data from 52 UC patients in clinical remission who underwent routine colonoscopy using a colonoscope (EC38i10M; HOYA, Tokyo, Japan) at Kyoto University Hospital. In this study, clinical remission was defined as a partial Mayo score ≤ 2 . Colonic mucosal activity was assigned a MES on the basis of colonoscopic findings (► **Supplementary Table 1**) [25]. Informed consent was obtained from all patients, and the experimental design using these samples was approved by the Kyoto

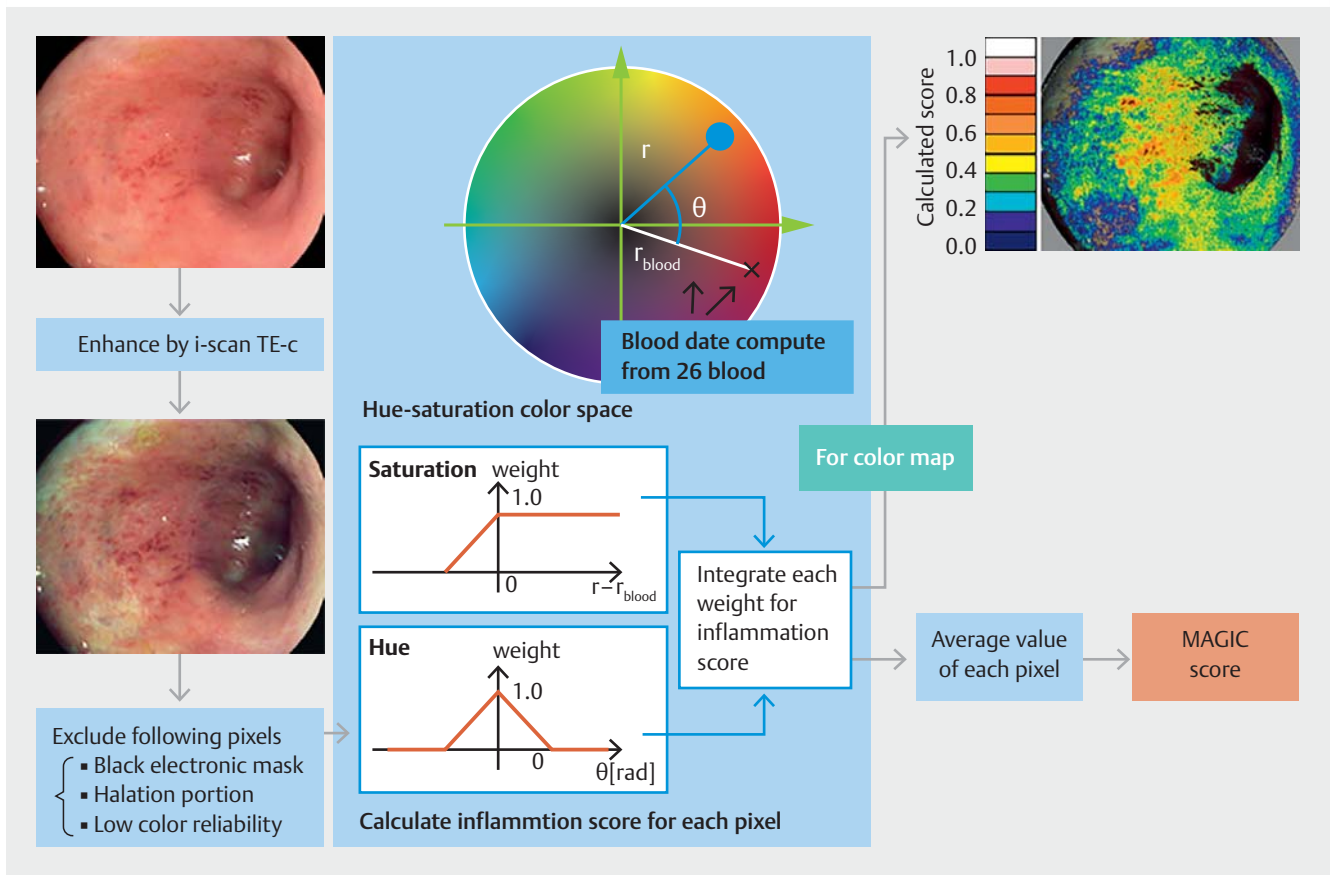
University Hospital Ethics Committee (number: 2017-R1104). All endoscopic examinations were performed by three of the authors (Y.H., M.M., H.N.) who were board certified specialists of the Japan Gastroenterological Endoscopy Society. The three endoscopists independently evaluated the endoscopic images and determined the MES values. In the case of a disagreement among them with regard to the MES values, a final score was recorded based on agreement after discussion among them. Before reviewing this study, the three endoscopists were trained using a training set of 20 endoscopic images from colonoscopy; during this training exercise, they independently determined the MES for the 20 endoscopic images, and consensus was sought with regard to the scoring among them to enhance the agreement in their scoring to compensate for insufficient inter-observer agreement.

Image recording devices

A colonoscope and a still image recorder (MV-10XD; TEAC, Tokyo, Japan) were connected to a video processor (EPK-i; HOYA), which operated the colonoscope, and the endoscopic images were saved to the still image recorder as tiff images. Normal and TE-c enhanced images were simultaneously recorded using EPK-i's Twin Mode. Biopsies of significantly red portions were obtained from patients with UC in this study and tissue inflammation was pathologically confirmed. We attempted to quantify the degree of inflammation because the red areas in the TE-c enhanced images indicated inflammation. The data were converted to a hue/saturation/brightness color space values (HSV model). The hue and saturation values were used to evaluate the inflammation, but the brightness value was not used for quantification because it was largely affected by the image recording conditions.

Procedure for calculating the MAGIC (Mucosal Analysis of Inflammatory Gravity by i-scan TE-c Image) score

Total colonoscopy and routine observation were performed to determine the MES and define the target area, which was the most severely inflamed area in the segment. In the TE-c enhanced images of normal or inflamed colonic mucosa with improved color contrast, the degree of inflammation was quantified for the entire screen by correlating the value with the reference value for each pixel in the HSV color space. The MAGIC (Mucosal Analysis of Inflammatory Gravity by i-scan TE-c Image) score was defined as the mean value of the quantified values for each pixel. Electric mask and halation portions, and the areas of low reliability in the dark portions, were excluded from the MAGIC score. Reference data were obtained by randomly sampling 26 cases whose images revealed apparent bleeding, and then sampling the blood data from the bleeding portions shown in the images. The distribution of inflammation was shown by coloring the correlating value of each pixel. The main calculation procedure to obtain the MAGIC score was converting RGB to the HSV color space. The HSV color space is an index that provides three elements of color: hue, saturation, and brightness. Hue indicates a color as an angle, saturation indicates the vividness, and brightness indicates luminance. The



► **Fig. 1** The level of inflammation was calculated with a weighting function from the differences between references after excluding the low-reliability pixels in the TE-c enhanced image. Coloring each pixel according to the level of inflammation creates a visual image of the MAGIC score as a color map. The MAGIC score was defined as the mean inflammation score of all of the pixels.

MAGIC score was calculated from the hue and saturation to reduce the negative influence of the lighting conditions. The pixels were scored with a function defined by the difference between the pixel of interest and the reference pixel. The difference in hue was defined as θ and the difference in saturation was defined as $r - r_{\text{blood}}$. The inflammation score was defined as the sum of the two subscores. A similar process was applied to all pixels, and the mean value was considered to be the MAGIC score. The actual MAGIC score was calculated to four significant digits. The MAGIC score ranged from 0 to 10 000. ► **Fig. 1** shows the processing flow.

Histologic evaluation

We evaluated histologic inflammation in the colonic tissues obtained from biopsy specimens according to the Geboes score [15]. The Geboes score has six grades: architectural change, chronic inflammatory infiltrate, lamina propria neutrophils and eosinophils, neutrophils in epithelium, crypt destruction, and erosion or ulceration. The Geboes score ranges from 0.0 (normal mucosa) to 5.4 (severe inflammation with ulcers and granulation).

Assessment

To investigate the usefulness of this new endoscopic imaging system on objective distinction between MES 0 and MES 1 in UC, we compared the MAGIC score in clinically quiescent UC patients with MES (0 or 1). Evaluation was performed at each portion of the colorectum (cecum to ascending colon, transverse colon, descending colon, sigmoid colon, and rectum), and the most severe lesions in the colorectum of each patient were used for analysis.

Statistical analysis

All numerical data are expressed as median \pm standard deviation (SD). The differences in the MAGIC score between the MES 0 and MES 1 groups were analyzed using the Mann–Whitney *U* test. The correlation between the MAGIC score, the MES and the Geboes score was estimated using the Kendall coefficient of concordance. The comparison between correlation coefficient of the MAGIC score and the MES with the Geboes score was conducted using Meng’s *z*-coefficient. The correlation between the MAGIC score and blood hemoglobin (Hb) concentration was estimated using Pearson’s correlation coefficient. All calculations were performed with SPSS (IBM SPSS Statistics for Windows, Version 24, IBM Corp., Armonk, NY, United States). A *P* value < 0.05 was considered to be statistically significant.

► **Table 1** Patient characteristics.

Parameter	Value
Number of patients	52
Sex (men/women)	38/14
Median age (range), years	50 (18–80)
Median disease duration (range), months	120 (12–420)
Extent of disease	
▪ Total colitis/left-sided/proctitis	26/16/10
Mayo Endoscopic Subscore (MES)	
▪ MES 0/1/2/3	27/23/2/0
Treatment, n (%)	
▪ No therapy	1 (1.9)
▪ 5-Aminosalicylic acid (5-ASA)	50 (96.2)
▪ Thiopurines	4 (7.7)
▪ Biologics	3 (5.8)
▪ Tacrolimus	1 (1.9)

Results

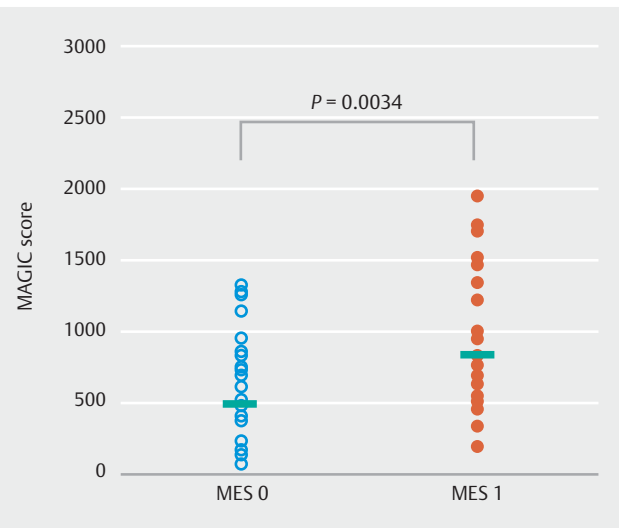
Patient characteristics

The patient characteristics are summarized in ► **Table 1**. In total, 52 UC patients in clinical remission underwent colonoscopy and the MES values of those patients were evaluated. Of the 52 UC patients, 27 were classified into the MES 0 group and 23 were classified into the MES 1 group based on the MES value. The patient characteristics of each group are summarized in ► **Table 2**. In this study, there was no difference in patient characteristics between the MES 0 and the MES 1 group.

► **Table 2** Patient characteristics between MES 0 and MES 1.

	MES 0 (n = 27)	MES 1 (n = 23)	P value
Sex (men/women)	22/5	15/8	0.191
Median age (year, range)	59 (18–80)	49 (18–82)	0.490
Median disease duration (months, range)	120 (12–396)	132 (12–420)	0.992
Extent of disease			
▪ Total colitis/left-sided/proctitis	14/8/5	11/8/4	0.927
Treatment, n (%)			
▪ No therapy	1 (7.4)	0 (0)	0.351
▪ 5-Aminosalicylic acid (5-ASA)	25 (92.6)	23 (100)	0.183
▪ Thiopurines	8 (29.6)	1 (4.3)	0.020
▪ Biologics	2 (7.4)	0 (0)	0.182
▪ Tacrolimus	2 (7.4)	1 (4.3)	0.650

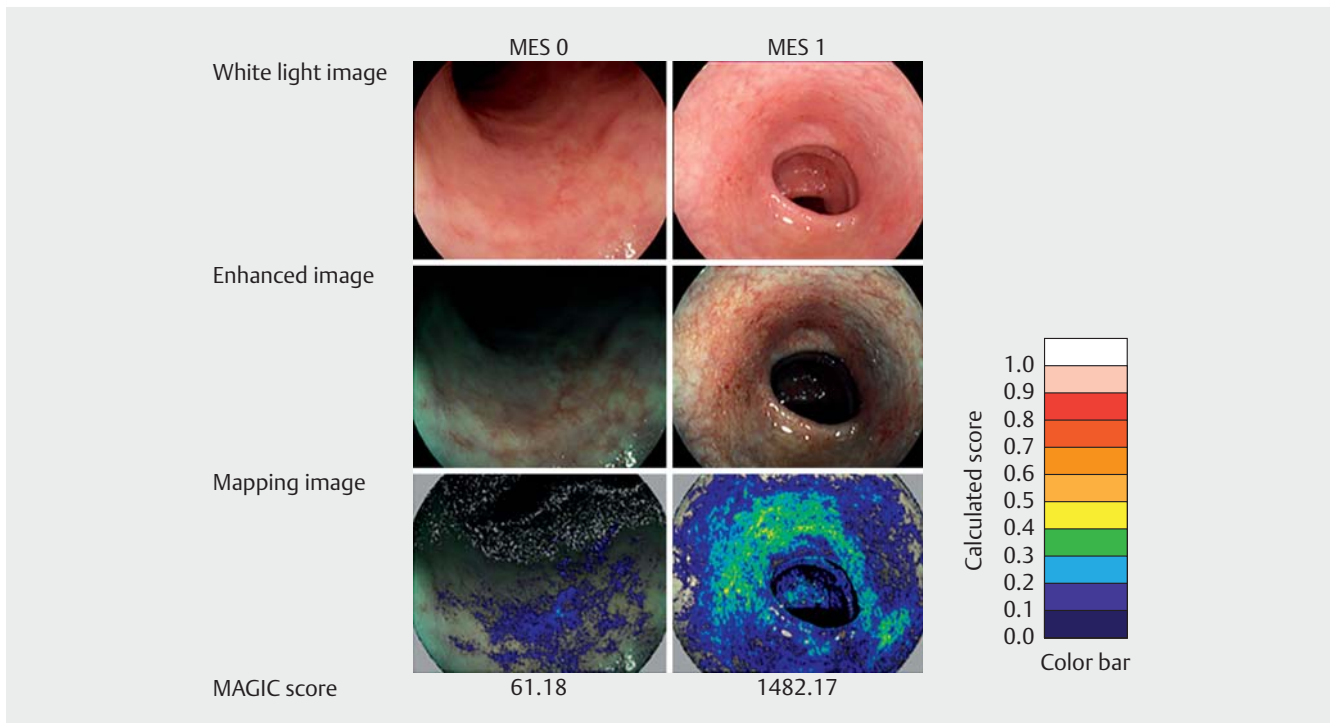
MES, Mayo Endoscopic Subscore.



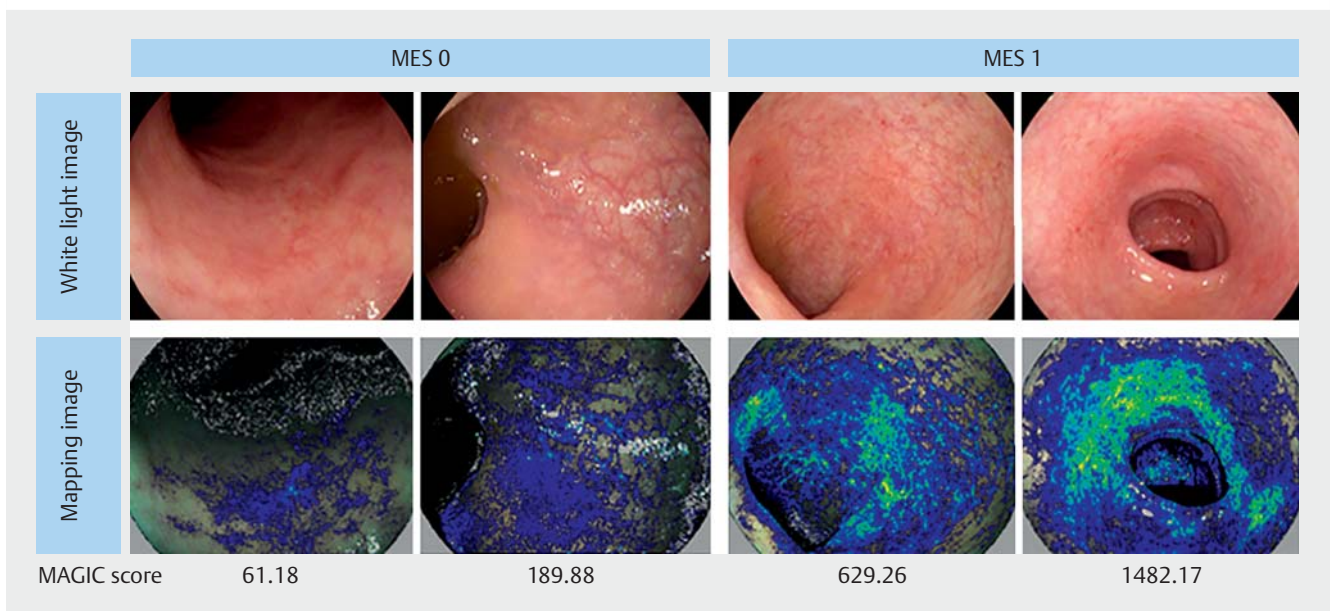
► **Fig. 2** Relationship between the MAGIC score and MES 0 or 1. The MAGIC score of the MES 0 group was significantly lower than that of the MES 1 group (MES 0: 487.2 ± 378.2 ; MES 1: 779.8 ± 488.4 , $P=0.0034$). Data were analyzed by Mann–Whitney *U* test.

Correlation between the MAGIC score and MES in patients with quiescent UC

The median MAGIC score for all of the UC patients was 691.9 ± 474.5 . The MAGIC score of the MES 1 group was significantly higher than that of the MES 0 group (779.8 ± 488.4 vs. 487.2 ± 378.2 , $P=0.0034$; ► **Fig. 2**). The MAGIC score of the mapping image clearly increased depending on the degree of endoscopic disease activity determined by colonoscopy (► **Fig. 3**). There were wide variations in the MAGIC score among some patients with the same MES of 0 or 1 (► **Fig. 4**).



► **Fig. 3** Representative examples of MAGIC scores in the MES 0 or 1 groups. As the degree of inflammation increased, the calculated score of the mapping image increased.

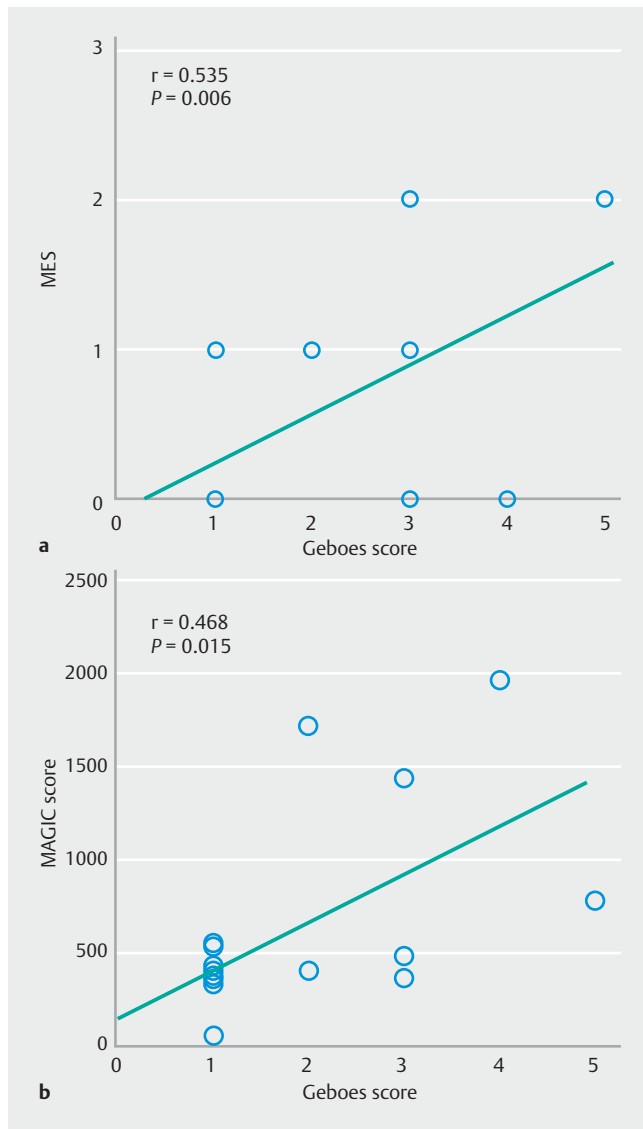


► **Fig. 4** Some patients in the MES groups (0 or 1) had widely ranging MAGIC scores.

Correlation between the MAGIC score, the MES, and Geboes score

We examined the correlation between the MAGIC score, the MES, and histologic activity. In this study, we obtained biopsy specimens from 15 patients who agreed to biopsy and their characteristics are summarized in ► **Supplementary Table 2**. Of these 15 UC patients, eight patients were categorized into

Geboes score grade 1, two patients were categorized into Geboes score grade 2, three patients were categorized into Geboes score grade 3, one patient was categorized into Geboes score grade 4, and one patient was categorized into Geboes score grade 5. Our data indicated the positive correlation between the MES and Geboes score ($r=0.535$, $P=0.006$; ► **Fig. 5a**). Moreover, we found that the MAGIC score also significantly cor-

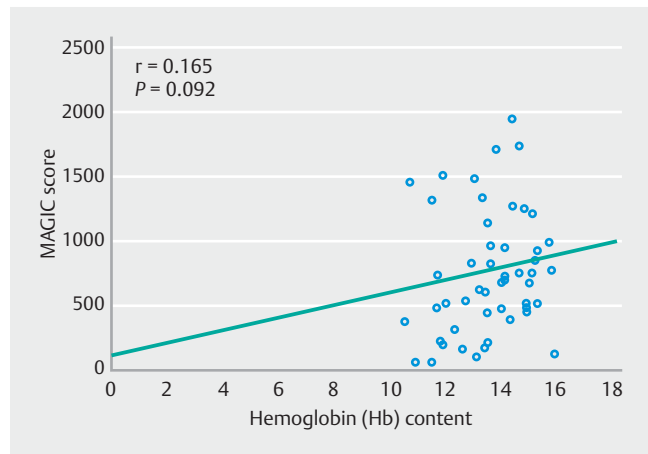


► **Fig. 5 a** Correlation between MES and Geboes score. The MES and Geboes score were significantly correlated ($r=0.535$, $P=0.006$). **b** Correlation between the MAGIC score and Geboes score. The MAGIC score and Geboes score were significantly correlated ($r=0.468$, $P=0.015$).

related with the Geboes score ($r=0.468$, $P=0.015$; ► **Fig. 5b**). When comparing the degree of correlation between these endoscopic scores and the Geboes score, the MAGIC score showed a similar degree of correlation with the Geboes score, compared to MES (Meng's $z=0.271$, $P=0.393$).

Correlation between the MAGIC score and blood Hb concentration

We investigated the possible influence of the Hb concentration on the MAGIC score in all UC patients, because the MAGIC score was calculated using data from images showing apparent bleeding. The MAGIC score was not significantly correlated with the blood Hb concentration ($r=0.165$, $P=0.17$; ► **Fig. 6**).



► **Fig. 6** Correlation between the MAGIC score and blood Hb concentration. The MAGIC score did not correlate with the blood Hb concentration ($r=0.165$, $P=0.092$).

Discussion

We developed a new endoscopic imaging system using the i-scan TE-c to quantify the assessment of colonic mucosal inflammation in patients with quiescent UC. This system could distinguish between MES 0 and MES 1 more clearly compared to conventional white-light endoscopy. Moreover, the MAGIC score enables more objective assessment of histologic inflammation than MES. Our novel imaging-enhanced endoscopic system with MAGIC score could become one of the non-invasive, objective and quantitative modalities for detailed evaluation of MH in patients with UC.

Recently, endoscopic evaluation of UC disease activity has become more important and essential because the treatment goal for UC has shifted from controlling symptoms during clinical remission to achieving endoscopic remission, i. e. MH [26]; however, the term MH is considered ambiguous because there is no validated definition of MH in UC patients for either endoscopic or histologic examinations. MES is widely used to evaluate endoscopic disease activity in clinical practice and trials, because it is easy to assess, and an MES of 0 or 1 is often defined as MH; however, several studies have demonstrated a wide difference in the UC relapse rate between patients with MES 0 and those with MES 1 [7, 8]. Indeed, Boal Carvalho et al. reported that patients with MES 1 have a higher risk of relapse than those with MES 0 [26]. Iacucci et al. also mentioned that current endoscopic scoring systems, such as MES, cannot detect mild, patchy inflammatory mucosal changes and differentiate clearly between quiescent and mild activity of the UC [22]. Therefore, an objective method is needed to assess mucosal inflammation and which can distinguish more clearly between MES 0 and MES 1 in clinically quiescent UC.

In this study, the MAGIC score of the MES 1 group was significantly higher than that of the MES 0 group. This indicates that our scoring system may reflect the degree of colonic inflammation more clearly than MES; however, the MAGIC score in UC patients with MES 0 and 1 ranged widely from 62.0 to 1320.0, and from 184.9 to 1951.3, respectively. We examined the influence

of the blood Hb concentration on the MAGIC score because the MAGIC score was calculated by a scoring system based on the blood data of the colonic mucosa; however, the MAGIC score was not correlated with the blood Hb concentration. One of the reasons for these wide variations in MAGIC score may be derived from the improvement or exacerbation of colonic inflammation during the disease course of UC characterized by remitting or relapsing. Furthermore, current novel endoscopic techniques with high definition images, optical and digital enhancement could evaluate vascular details of colonic mucosa in UC patients, and assess subtle inflammatory changes of them [27,28]. For example, Iacucci et al. performed an excellent study to assess the intestinal mucosa using i-scan technology and showed that nearly one-third of patients with a MES of 0 had an abnormal mucosal pattern and two-thirds had an abnormal vascular pattern on virtual chromoendoscopy. This could be another reason for the wide variations in MAGIC score found in our study. In addition, the MAGIC score with TE-c was influenced not only by the brightness of the endoscope screen but also by the degree of inflation of the intestinal tract due to air insufflations. This might also be one of the reasons for the wide variations found in MAGIC scores.

Next, we investigated the correlation between the MAGIC score and histologic activity. Several previous studies have already reported the significant correlation between the MES and histologic activity, including the Geboes score [29,30]. In our study, the MAGIC score showed a similar degree of correlation with histologic activity, the Geboes score, as well as the MES. Therefore, the MAGIC score could reflect histologic activity, although the sample size of biopsy cases in this study was very small. Moreover, it is of great importance that our endoscopic MAGIC score could predict the smoldering histologic inflammation of the colonic mucosa, even in quiescent UC patients with MES 0 or 1, while previous reports showed the correlation between endoscopic and histologic evaluations for mild to severe inflammation of colonic mucosa in patients with active UC [16,29]. Iacucci et al. also reported that the measurement of an abnormal vascular pattern by endoscopic scoring systems using i-scan correlated with histologic activity, which supports our result [19,23]. In addition, this system could assess the entire colonic mucosa and evaluate diffuse mucosal inflammation, whereas histologic assessment using biopsy samples cannot assess the entire colonic mucosa because biopsy specimens are obtained from only a small part of the colonic mucosa. Moreover, histologic evaluation using biopsy specimens is invasive and is associated with the risks of complications, such as perforation. Therefore, our novel quantitative endoscopic system has the potential to assess complete remission, i.e., histologic healing in addition to endoscopic mucosal healing [31]. The positive correlation between the MAGIC score and histologic activity could overcome the limitations of MES, although we could not investigate the patients with discordant scores of MES and MAGIC scores because this was a retrospective analysis. Thus, further prospective studies with larger samples are required to confirm these findings.

From these data, this novel endoscopic system is expected to be useful for objective and quantitative evaluation of colonic

inflammation in patients with quiescent UC. However, there are several limitations with regard to this system and our study as follows: (1) specialized software is needed to analyze the MAGIC score; (2) on-site calculation of the MAGIC score during colonoscopic examination is difficult because the system requires recorded conventional data; (3) the number of patients enrolled in the study was relatively small. In particular, the number of biopsy samples of colonic mucosa was too small to discuss the details; (4) the study lacks data with regard to the correlation of MAGIC score with clinical outcome, such as clinical relapse and colectomy rate; (5) the cutoff level of the MAGIC score to define MH has not yet been validated.

In conclusion, our data strongly indicated that this novel endoscopic system is useful to distinguish objectively between MES 0 and 1. The system is easy to use and valuable for objectively and quantitatively evaluating colonic inflammation in patients with quiescent UC. To confirm the usefulness and clinical significance of this system for the management of patients with UC will require further studies with a larger number of patients in a prospective trial.

Acknowledgments

This work was partly supported by Health and Labour Sciences Research Grants for research on intractable diseases from the Ministry of Health, Labour and Welfare of Japan (Investigation and Research for Intractable Inflammatory Bowel Disease), and Japan Society for the Promotion of Science (JSPS) Grants-in-Aid for Scientific Research (KAKENHI) Grant Number JP18H02799 and 18K07969. The authors wish to thank Y. Ikemoto (HOYA Corp.) for providing image processing algorithm and foundations.

Competing interests

The following author disclosed financial relationships relevant to this publication: H. Nakase, M. Matsuura, Y. Honzawa: Consultants for HOYA Corp. Research support for this study was provided by HOYA Corp. for supplying image processing algorithm. All other authors disclose no financial relationships relevant to this publication.

References

- [1] Baumgart DC, Sandborn WJ. Inflammatory bowel disease: clinical aspects and established and evolving therapies. *Lancet* 2007; 369: 1641–1657
- [2] Abraham C, Cho JH. Inflammatory bowel disease. *NEJM* 2009; 361: 2066–2078
- [3] Froslie KF, Jahnsen J, Moum BA et al. Mucosal healing in inflammatory bowel disease: results from a Norwegian population-based cohort. *Gastroenterology* 2007; 133: 412–422
- [4] Colombel JF, Rutgeers P, Reinisch W et al. Early mucosal healing with infliximab is associated with improved long-term clinical outcomes in ulcerative colitis. *Gastroenterology* 2011; 141: 1194–1201

- [5] Dulai PS, Levesque BG, Feagan BG et al. Assessment of mucosal healing in inflammatory bowel disease: review. *Gastrointest Endosc* 2015; 82: 246–255
- [6] Schoeder KW, Tremaine WJ, Ilstrup DM et al. Coated oral 5-aminosalicylic acid therapy for mildly to moderately active ulcerative colitis. A randomized study. *NEJM* 1987; 317: 1625–1629
- [7] Meucci G, Fasoli R, Saibeni S et al. Prognostic significance of endoscopic remission in patients with active ulcerative colitis treated with oral and topical mesalazine: a prospective, multicenter study. *Inflamm Bowel Dis* 2012; 18: 1006–1010
- [8] Samaan MA, Mosli MH, Sandborn WJ et al. A systematic review of the measurement of endoscopic healing in ulcerative colitis clinical trials: recommendations and implications for future research. *Inflamm Bowel Dis* 2014; 20: 1465–1471
- [9] Barreiro-de Acosta M, Vallejo N, de la Iglesia D et al. Evaluation of the risk of relapse in ulcerative colitis according to the degree of mucosal healing (Mayo 0 vs 1): A longitudinal cohort study. *J Crohns Colitis* 2016; 10: 13–19
- [10] Fiorino G, Cesarini M, Indriolo A et al. Mucosal healing in ulcerative colitis: where do we stand? *Curr Drug Targets* 2011; 12: 1417–1423
- [11] Peyrin-Biroulet L, Ferrante M, Magro F et al. Impact of mucosal healing on the course of inflammatory bowel disease. *J Crohns Colitis* 2011; 5: 477–483
- [12] Bryant RV, Burger DC, Delo J et al. Beyond endoscopic mucosal healing in UC: histological remission better predicts corticosteroid use and hospitalisation over 6 years of follow-up. *Gut* 2016; 65: 408–414
- [13] Bitton A, Peppercorn MA, Antonioli DA et al. Clinical, biological, and histologic parameters as predictors of relapse in ulcerative colitis. *Gastroenterology* 2001; 120: 13–20
- [14] Riley SA, Mani V, Goodman MJ et al. Microscopic activity in ulcerative colitis: what does it mean? *Gut* 1991; 32: 174–178
- [15] Geboes K, Riddell R, Ost A et al. A reproducible grading scale for histological assessment of inflammation in ulcerative colitis. *Gut* 2000; 47: 404–409
- [16] Kunihiro M, Tanaka S, Sumii M et al. Magnifying colonoscopic features of ulcerative colitis reflect histologic inflammation. *Inflamm Bowel Dis* 2004; 10: 737–744
- [17] Sanduleanu S, Kaltenbach T, Barkun A et al. A roadmap to the implementation of chromoendoscopy in inflammatory bowel disease colonoscopy surveillance practice. *Gastrointest Endosc* 2016; 83: 213–222
- [18] Kodashima S, Fujishiro M. Novel image-enhanced endoscopy with i-scan technology. *World J Gastroenterol* 2010; 16: 1043–1049
- [19] Iacucci M, Daperno M, Lazarev M et al. Development and reliability of the new endoscopic virtual chromoendoscopy score: the PICaSSO (Paddington International Virtual ChromoendoScopy ScOre) in ulcerative colitis. *Gastrointest Endosc* 2017; 86: 1118–1127
- [20] Tontini GE, Vecchi M, Neurath MF et al. Review article: newer optical and digital chromoendoscopy techniques vs. dye-based chromoendoscopy for diagnosis and surveillance in inflammatory bowel disease. *Aliment Pharmacol Ther* 2013; 38: 1198–1208
- [21] Maeda Y, Ohtsuka K, Kudo SE et al. Endocytoscopic narrow-band imaging efficiency for evaluation of inflammatory activity in ulcerative colitis. *World J Gastroenterol* 2015; 21: 2108–2115
- [22] Iacucci M, Furfaro F, Matsumoto T et al. Advanced endoscopic techniques in the assessment of inflammatory bowel disease: new technology, new era. *Gut* 2019; 68: 562–572
- [23] Iacucci M, Fort Gasia M, Hassan C et al. Complete mucosal healing defined by endoscopic Mayo subscore still demonstrates abnormalities by novel high definition colonoscopy and refined histological gradings. *Endoscopy* 2015; 47: 726–734
- [24] Neumann H, Vieth M, Günther C et al. Virtual chromoendoscopy for prediction of severity and disease extent in patients with inflammatory bowel disease: a randomized controlled study. *Inflamm Bowel Dis* 2013; 19: 1935–1942
- [25] Schroeder KW, Tremaine WJ, Ilstrup DM. Coated oral 5-aminosalicylic acid therapy for mildly to moderately active ulcerative colitis: a randomized study. *NEJM* 1987; 317: 1625–1629
- [26] Boal Carvalho P, Dias de Castro F, Rosa B et al. Mucosal healing in ulcerative colitis – When zero is better. *J Crohns Colitis* 2016; 10: 20–25
- [27] Sasanuma S, Ohtsuka K, Kudo SE et al. Narrow band imaging efficiency in evaluation of mucosal healing/relapse of ulcerative colitis. *Endosc Int Open* 2018; 6: E518–E523
- [28] Iacucci M, Kiesslich R, Gui X et al. Beyond white light: optical enhancement in conjunction with magnification colonoscopy for the assessment of mucosal healing in ulcerative colitis. *Endoscopy* 2017; 49: 553–559
- [29] Lemmens B, Arijis I, Van Assche G et al. Correlation between the endoscopic and histologic score in assessing the activity of ulcerative colitis. *Inflamm Bowel Dis* 2013; 19: 1194–1201
- [30] Jauregui-Amezaga A, Geerits A, Das Y et al. A simplified Geboes score for ulcerative colitis. *J Crohns Colitis* 2017; 11: 305–313
- [31] Bryant RV, Burger DC, Delo J et al. Beyond endoscopic mucosal healing in UC: histological remission better predicts corticosteroid use and hospitalisation over 6 years of follow-up. *Gut* 2016; 65: 408–414

► **Supplementary Table 1** Mayo Endoscopic Subscore.

0	Normal or inactive disease
1	Mild disease: erythema, decreased vascular pattern, mild friability
2	Moderate disease: marked erythema, absent vascular pattern, friability, erosion
3	Severe disease: spontaneous bleeding, ulceration

► **Supplementary Table 2** Patient characteristics in biopsy cases.

Parameter	Value
Number of patients	15
Sex (men/women)	9/6
Median age (range), years	51 (18–71)
Median disease duration (range), months	120 (36–396)
Extent of disease	
▪ Total colitis/left-sided/proctitis	8/4/3
Mayo Endoscopic Subscore (MES)	
▪ MES 0/1/2/3	9/4/2/0
Treatment, n (%)	
▪ No therapy	1 (6.7)
▪ 5-Aminosalicylic acid (5-ASA)	13 (86.7)
▪ Thiopurines	3 (20)
▪ Biologics	3 (20)
▪ Tacrolimus	2 (13)