

Electrical Burn Causing a Unique Pattern of Neurological Injury

Nathan R. Schaefer, BExSc,
MBBS (Hons)*
Julian P. Yaxley, BMSc,
MBBS†
Peter O'Donohue, BSc,
MBBS, MCE‡
Carl Lisec, BAppSc (Medical
Science), BAppSc (Hons),
MBBS, FRACSS§
Eshwarshanker Jeyarajan,
BSc, MBBS*

Summary: Neurological involvement is not uncommon in patients who sustain electrical injury. The exact mechanism of nervous system damage following electrical trauma is not fully understood. The gamut of possible neurologic manifestations following electrical injury is diverse. This case report describes a young man with a unique pattern of neurological injury following an electrical burn. The combination of brachial plexopathy, partial Horner's syndrome, and phrenic nerve palsy secondary to electrical injury has not been previously described in the literature. (*Plast Reconstr Surg Glob Open* 2015;3:e378; doi: 10.1097/GOX.0000000000000344; Published online 20 April 2015.)

Electrical injuries are relatively common and account for approximately 3% of all burn injuries.¹ Both the direct effect of electrical current and its conversion from electric to thermal energy can result in tissue damage. The extent of damage from electrical injury ranges from mild superficial skin burns to severe multiple organ dysfunction and death. Neurologic impairment is not unusual and may be highly variable in clinical presentation. Sequelae can be immediate or delayed and vary in severity from insignificant and transient to disabling and permanent. Common presenting features include loss of consciousness, altered mentation, and peripheral neuropathy.²

From the *Department of Surgery, Gold Coast University Hospital, Southport, Queensland, Australia; †Department of Surgery, Redcliffe Hospital, Redcliffe, Queensland, Australia; ‡Emergency Department, Cairns Hospital, Queensland, Australia; and §Department of Plastic and Reconstructive Surgery, Royal Brisbane and Women's Hospital, Brisbane, Queensland, Australia.

Received for publication January 19, 2015; accepted March 2, 2015.

This article adheres to the principles outlined by the Helsinki Declaration.

Copyright © 2015 The Authors. Published by Wolters Kluwer Health, Inc. on behalf of The American Society of Plastic Surgeons. All rights reserved. This is an open-access article distributed under the terms of the Creative Commons Attribution-NonCommercial-NoDerivatives 3.0 License, where it is permissible to download and share the work provided it is properly cited. The work cannot be changed in any way or used commercially.

DOI: 10.1097/GOX.0000000000000344

CASE REPORT

A 27-year-old man was brought by ambulance to a large metropolitan Australian hospital after being found unconscious at home with electrical burns. On arrival, the patient had regained consciousness, but he was drowsy and had difficulty in recollecting the events surrounding the time of injury. The mechanism of injury was unknown but was presumed to be from a domestic power source.

On examination, there were cutaneous burns to the patient's right hand, right axilla, and central forehead, totaling 1% of total body surface area. The hand and axilla burns were superficial partial thickness, whereas the forehead burn was middermal (Fig. 1). The patient had a right upper lid ptosis and right pupil miosis (Fig. 1). Soft tissue of the right shoulder was oedematous and tender, with flaccid paralysis of the right upper limb. Magnetic resonance imaging showed significant damage to the right brachial plexus.

On day 3 of admission, the patient had an oxygen saturation of 91% on room air. Two liters per minute of supplemental oxygen via nasal prongs was commenced. The patient had a continuing oxygen requirement on day 6 postinjury. Chest radiograph revealed an elevated right hemidiaphragm (Fig. 2). Dynamic fluoroscopy of the right hemidiaphragm showed no movement with respiration, confirming a right phrenic nerve palsy. The patient was successfully

Disclosure: The authors have no financial interest to declare in relation to the content of this article. The Article Processing Charge was paid for by the authors.

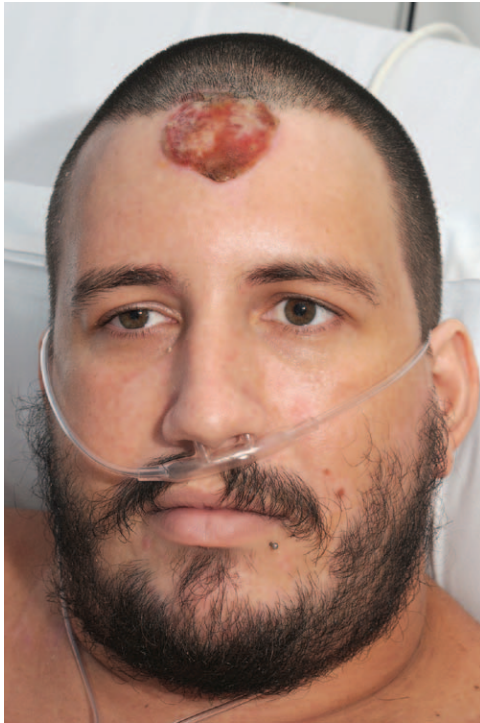

Fig. 1. Partial thickness electrical burn to the central forehead with a right-sided ptosis and pupillary miosis.

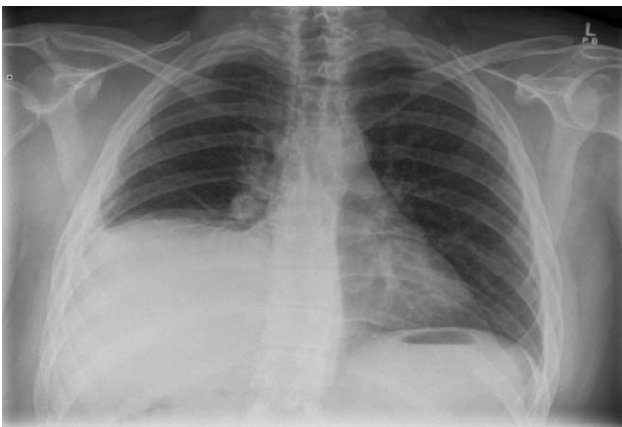


Fig. 2. Chest radiograph showing elevation of the right hemidiaphragm.

weaned from supplemental oxygen over the course of his inpatient admission, and chest radiograph depicted symmetrical hemidiaphragms on day 17 postinjury. He was discharged from hospital on day 18 postinjury. The right upper limb paresis and eyelid ptosis were unchanged on discharge. Unfortunately, the patient failed to attend follow-up.

DISCUSSION

The type and severity of electrical burns depend on the amperage, duration, and path of electric cur-

rent through the body.³ Electrical injury can induce tissue damage via both the direct effect of electrical current and the transformation of electrical energy to heat.^{4,5} Joule heating from electrical current causes tissue protein denaturation sufficient to result in thermal burns.⁶ The mechanism of trauma from direct effects of electricity is more complex. Organization of the cellular lipid bilayer is partly driven by electric fields, and cell membrane proteins carry with them electrically charged amino acids. Consequently, when electrical forces of large enough magnitude act across the cell membrane, the integrity of its macromolecules is disrupted and cell lysis results.^{5,6}

Electric current has specific implications for the nervous system. Electricity favors the path of least resistance, with nerves having a lower resistance compared with bone and muscle. This explains the relatively high frequency of neurological findings.⁷ Furthermore, electricity causes myelin degeneration not only directly and through thermal energy but also via vascular endothelial damage.⁸ Medial damage is thrombogenic, with microvascular occlusion impairing arterial blood supply to nerve cells resulting in intraneural fibrosis.^{2,9–11} Histopathology following electric neurological injury illustrates focal petechial hemorrhage, dilatation of perivascular space, peripheral nerve fragmentation, and myelin sheath ballooning.¹¹

Any level of the neurological system can be damaged from an electrical burn. Manifestations range from cerebral syndromes (eg, hemiplegia and cognitive impairment) to spinal syndromes (eg, limb paralysis) to peripheral motor-sensory neuropathies.¹² Approximately 50% of patients suffering low-voltage burns have some degree of neurologic symptoms, compared with 67% after sustaining high-voltage burns.¹³ High voltage is defined as an electrical trauma greater than 1000 volts.² The most common reported neurological symptom is loss of consciousness, with a prevalence of 21–67%.¹¹ Peripheral neuropathy is also common, occurring in approximately 17% of cases.¹⁴ Permanent cerebral damage is uncommon, sometimes emerging as only mild cognitive impairment or behavioral change.

The constellation of findings in this case report is unique to the literature, as a brachial plexus injury, phrenic nerve palsy, and partial Horner's syndrome have not previously been reported. Electric current damage to the brachial plexus is exceptional, and only a handful of examples have been discussed in the literature.^{15,16} Although iatrogenic phrenic nerve injury has been widely reported, accidental damage secondary to an environmental electrical source is rare.^{17,18} There have been no

prior cases of phrenic nerve damage subsequent to electrical trauma described in the literature. The phrenic nerve palsy in this case study was temporary and resolved spontaneously. It also demonstrated a delayed onset of several days. Horner's syndrome too is an infrequent manifestation of electrical injury. In this case, the patient had a partial syndrome with only pupil miosis and upper lid ptosis, indicating disruption of his ipsilateral ascending sympathetic chain.

Two interesting phenomena are raised in this case report: the tendency for neurological sequelae to self-resolve and the possibility of either immediate or delayed presentation. Neurologic signs typically recover over the course of days to weeks, although occasionally deficits become progressive and permanent.^{14,19} Recovery is hypothesized to take place via neural tract collateralization.²⁰ The fastest example is loss of consciousness, which characteristically resolves before patients reach hospital.¹³ Recovery of nervous system function in the current case was exemplified both by return to consciousness and improvement of the phrenic nerve palsy. The second point of interest in this case report was the late onset of the phrenic nerve syndrome. Delayed neurological damage from electric shock is a well-recognized phenomenon although the mechanism is elusive. One article postulates that delayed neurologic features occur due to a combination of gradual nerve ischemia secondary to surrounding vascular insults and cumulative damage from free radical release caused by hyperstimulation of glutamatergic neurons.²¹ Late-onset signs are less likely to improve than immediate neurological lesions, although if permanent the deficit is generally mild.¹³

CONCLUSIONS

Electricity is ubiquitous in modern life, and burn injuries remain a widespread problem. Neurological impairment comprises a substantial portion of the morbidity associated with electrical burns. A wide range of symptoms are possible, which may be either immediate or delayed, and transient or permanent. This case presents a unique pattern of neurological injury following electrical trauma comprising a brachial plexopathy, phrenic nerve palsy, and partial Horner's syndrome.

Julian P. Yaxley, BMSc, MBBS

Department of Surgery
Redcliffe Hospital, Anzac Avenue
Redcliffe, Queensland
4020, Australia
E-mail: julianyaxley@yahoo.com.au

PATIENT CONSENT

Patient provided written consent for the use of his images.

REFERENCES

- Anastassios C, Koumbourlis M. Electrical injuries. *Crit Care Med.* 2002;30:424–430.
- Grube BJ, Heimbach DM, Engrav LH, et al. Neurologic consequences of electrical burns. *J Trauma.* 1990;30:254–258.
- Kumar V, Abbas A, Fausto N. *Robbins and Cotran Pathologic Basis of Disease.* 8th ed. Philadelphia, Pa.: Elsevier Saunders; 2009.
- Lee RC, Kolodney MS. Electrical injury mechanisms: electrical breakdown of cell membranes. *Plast Reconstr Surg.* 1987;80:672–679.
- Lee R, Dougherty W. Electrical injury: mechanisms, manifestations and therapy. *Trans Dielectr Electr Insul.* 2003;10:810–819.
- Lee RC, Zhang D, Hannig J. Biophysical injury mechanisms in electrical shock trauma. *Annu Rev Biomed Eng.* 2000;2:477–509.
- Duff K, McCaffrey RJ. Electrical injury and lightning injury: a review of their mechanisms and neuropsychological, psychiatric, and neurological sequelae. *Neuropsychol Rev.* 2001;11:101–116.
- Silversides J. The neurological sequelae of electrical injury. *Can Med Assoc J.* 1964;91:195–204.
- Hunt JL, McManus WF, Haney WP, et al. Vascular lesions in acute electric injuries. *J Trauma.* 1974;14:461–473.
- Lee R. *Current Problems in Surgery.* Chicago, Ill.: Mosby Incorporated; 1997.
- Bariar LM, Ahmad I, Aggarwal A, et al. Myelopathy following high voltage electrical injury: a case report. *Burns* 2002;28:699–700.
- Scholz T, Rippmann V, Wojtecki L, et al. Severe brain damage by current flow after electrical burn injury. *J Burn Care Res.* 2006;27:917–922.
- Ko SH, Chun W, Kim HC. Delayed spinal cord injury following electrical burns: a 7-year experience. *Burns* 2004;30:691–695.
- Ratnayake B, Emmanuel ER, Walker CC. Neurological sequelae following a high voltage electrical burn. *Burns* 1996;22:574–577.
- Suematsu N, Matsuura J, Atsuta Y. Brachial plexus injury caused by electric current through the ulnar nerve. Case report and review of the literature. *Arch Orthop Trauma Surg.* 1989;108:400–402.
- Solem L, Fischer RP, Strate RG. The natural history of electrical injury. *J Trauma.* 1977;17:487–492.
- Sacher F, Monahan KH, Thomas SP, et al. Phrenic nerve injury after atrial fibrillation catheter ablation: characterization and outcome in a multicenter study. *J Am Coll Cardiol.* 2006;47:2498–2503.
- Gibson GJ. Diaphragmatic paresis: pathophysiology, clinical features, and investigation. *Thorax.* 1989;44:960–970.
- Deveci M, Bozkurt M, Sengezer M. Clonus: an unusual delayed neurological complication in electrical burn injury. *Burns* 2001;27:647–651.
- Christensen JA, Sherman RT, Balis GA, et al. Delayed neurologic injury secondary to high-voltage current, with recovery. *J Trauma.* 1980;20:166–168.
- Reisner AD. Possible mechanisms for delayed neurological damage in lightning and electrical injury. *Brain Inj.* 2013;27:565–569.