



ELSEVIER

Contents lists available at [ScienceDirect](https://www.sciencedirect.com)

# Trauma Case Reports

journal homepage: [www.elsevier.com/locate/tcr](http://www.elsevier.com/locate/tcr)

## Case Report

# What is the impact of vasospasm on traumatic subarachnoid hemorrhage: Two cases of report

Shoko Merrit Yamada<sup>\*</sup>, Yusuke Tomita, Ririko Takeda, Makoto Nakane

Department of Neurosurgery, Teikyo University Mizonokuchi Hospital, 5-1-1 Futago, Takatsu-ku, Kawasaki, Kanagawa 213-8507, Japan

## ARTICLE INFO

### Keywords:

Head trauma  
Subarachnoid hemorrhage  
Vasospasm  
Glasgow Coma Scale  
Elder

## ABSTRACT

It is difficult to predict that vasospasm would occur in traumatic subarachnoid hemorrhage (SAH) patients. Younger age, a lower score of Glasgow coma scale (GCS $\leq$ 8) on admission, and greater cisternal blood volume are considered to correlate with post-traumatic vasospasm.

We present two cases of traumatic SAH with post-traumatic vasospasm; one was a 74-year-old man and the other was a 72-year-old woman. They were alert without any neurological deficits on admission, although the SAH was focally thick as if caused by an aneurysmal rupture. The thick SAH was still identified on follow-up CT performed in a few days. The patients demonstrated cognitive dysfunction at the 4th and 5th day of admission, respectively, and imaging studies revealed vasospasm at the artery in the thick SAH. After treatments, the vasospasm resolved and both patients recovered from the disorientation completely in three weeks. The authors considered that focally thick traumatic SAH with poor clearance is the most influential factor to post-traumatic vasospasm independent of age or a GCS score. A low GCS score in head trauma patients might be mainly associated with existence of brain contusion, intracerebral hemorrhage, epidural, or subdural hemorrhages, which are frequently associated with traumatic SAH. If the traumatic SAH is focally thick with poor clearance, it might be better to initiate prompt treatments for vasospasm within 3 days after trauma. The delay in treatments for vasospasm contributes to poor outcomes.

## Introduction

The incidence of vasospasm in traumatic subarachnoid hemorrhage (SAH) is 27% to 65% [1–6]. In most cases, the vasospasm occurs within 3 days after head injury and lasts for 12 hours to 3 weeks [3,5]. The presence of vasospasms is associated with poor functional outcomes causing ischemic brain damage. The treatments for vasospasm caused by aneurysmal SAH include triple-H therapy (induced hypertension, hypervolemia, and hemodilution), administration of a calcium blocker, and intra-arterial administration of papaverine [7,8]. These treatments are not always favorable for vasospasm following traumatic brain injury [6]. Without prophylactic treatments, prediction and early detection of post-traumatic vasospasm are key points for better prognosis of the patients.

<sup>\*</sup> Corresponding author.

E-mail address: [smyamada@med.teikyo-u.ac.jp](mailto:smyamada@med.teikyo-u.ac.jp) (S.M. Yamada).

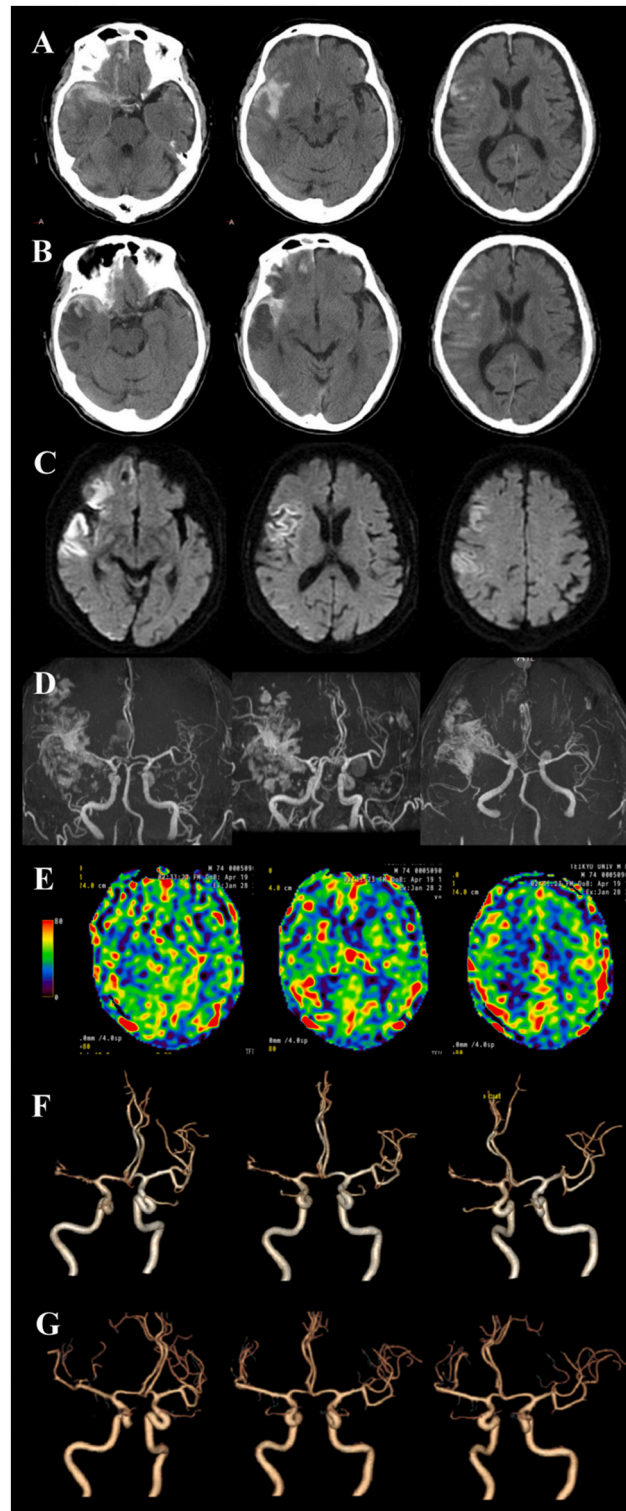
<https://doi.org/10.1016/j.tcr.2021.100543>

Accepted 13 October 2021

Available online 16 October 2021

2352-6440/© 2021 Published by Elsevier Ltd. This is an open access article under the CC BY-NC-ND license

(<http://creativecommons.org/licenses/by-nc-nd/4.0/>).



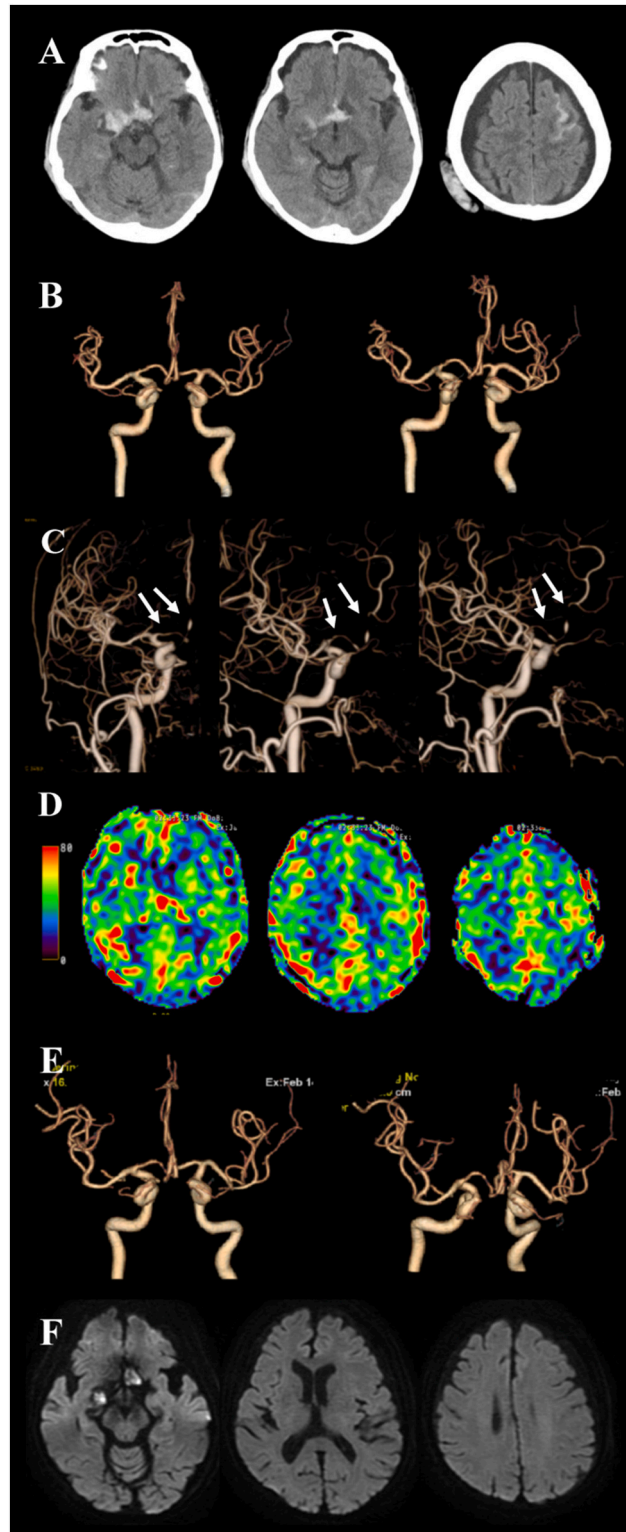
**Fig. 1.** In Case 1.

- A. CT on admission: Thick SAH was identified in the right Sylvian fissure and small brain contusions in the right frontal base and the temporal tip.  
 B. CT on day 4: Residual SAH was identified in the right Sylvian fissure and low-density areas were demonstrated in the right temporal and frontal lobes.  
 C. DWI of MRI on day 5: DWI showed high signal areas in the right temporal and frontal lobes.  
 D. MRA on day 5: MRA displayed narrowing of the M1 portion in the right MCA.

E. ASL on day 5: No decrease of CBF was identified on ASL.

F. 3D-CTA on day 10: 3D-CTA demonstrated vasospasm in the right M1 portion, and the M2 to M4 portions were not recognized.

G. 3D-CTA on day 27: This image shows the improvement in vasospasm in the right MCA; no aneurysms were identified.



**Fig. 2.** In Case 2.

- A. CT on admission: Thick local SAH was recognized at the suprasellar cistern. A subcutaneous hemorrhage by head trauma was identified in the right parietal.
- B. 3D-CTA on admission: The image revealed no aneurysms in the anterior circulation.
- C. Angiography on day 6: Angiography demonstrated severe vasospasm in the right A1 to A2 portion of the right ACA, and the A3 and A4 portions were extremely narrow.
- D. ASL on day 6: ASL of MRI showed no reduction in CBF at the ACA territories.
- E. MRA on day 21: Although the right A1 portion was mildly spastic, the right A2 to A4 portion of the ACA was well identified.
- F: MRI on day 21: DWI revealed no ischemic lesions. The high signal lesions at the base were recognized as residual hematomas.
- 

**Case presentation***Case 1*

A 74-year-old man was transferred to our hospital because of head trauma. He was alert but did not remember the head trauma. A computed tomography (CT) demonstrated focal SAH in the right Sylvian fissure (Fig. 1A). Four days after admission, the patient became disoriented, and a follow-up CT showed low-density areas in the right frontal and temporal lobes with poor clearance of SAH (Fig. 1B). Magnetic resonance imaging (MRI) and MR angiography (MRA) demonstrated ischemic changes in the right temporal and frontal lobes on diffusion weighted imaging (DWI) (Fig. 1C) with vasospasm of the right middle cerebral artery (MCA) (Fig. 1D). A decrease in cerebral blood flow (CBF) was identified using anatomical spin labeling (ASL) (Fig. 1E). Administration of Low molecular dextran-L and fasudil hydrochloride hydrate were initiated. On the 10th day of admission, three-dimension CT angiography (3D-CTA) showed severe spasm in the right M1 portion, but not in the right M3 to M4 portions (Fig. 1F). On the 21th day, the patient completely recovered from disorientation, the follow-up 3D-CTA at day 27 showed the right M3 to M4 portion clearly without any aneurysms (Fig. 1G). The patient was discharged without any neurological deficits 29 days after admission.

*Case 2*

A 72-year-old woman was transferred to our emergency room because she fell to the ground and hit her head. On arrival, she was alert and complained of a headache. A CT demonstrated focal SAH in the basal cistern (Fig. 2A), but no aneurysms were identified on 3D-CTA (Fig. 2B). Residual SAH was still identified at the right basal cistern on follow-up CT. On the 5th day after admission, her cognitive function rapidly deteriorated. Angiography on Day 6 showed severe vasospasm in the right A1 to A2 portion of the anterior cerebral artery (ACA) (Fig. 2C), but ASL did not reveal a decrease of CBF (Fig. 2D). Low-molecular-dextran-L and fasudil hydrochloride hydrate were administered, and the patient became asymptomatic at 20 days after admission. MRA displayed mild vasospasm at the right A1 portion on day 21 (Fig. 2E), but no cerebral infarctions were identified on DWI (Fig. 2F). The patient was discharged on day 27 following admission.

**Discussion**

Risk factors for vasospasm following traumatic brain injury include younger age, a low GCS score on admission, and greater cisternal blood volume [2,6,9,10]. Oertel et al. concluded that younger and severe head trauma ( $\leq 8$ ) were indicators to develop vasospasm in head injury patients [6]. In the report of Zubkov et al., no post-traumatic vasospasms were identified in patients with higher GCS score ( $\geq 12$ ) [10]. Our two cases were over 70's and were alert on admission without any neurological deficits. The authors considered that a focally thick traumatic SAH with poor clearance strongly contributes to vasospasm independent of severity of head trauma. Taneda et al. mentioned that severe vasospasm was identified in relationship with the site of major subarachnoid blood [9]. A low GCS score in head trauma patients might be mainly associated with existence of brain contusion, intracerebral hemorrhage, or epidural or subdural hemorrhages, which are frequently associated with traumatic SAH; however, only SAH was significantly related to the development of vasospasm [6]. It is considered that spasmogenic and neuroinflammatory substances generated from lysis of SAH could produce vasospasm [11], although pathophysiology of cerebral vasospasm in head trauma has not been clarified yet. In elders, especially in older than 70 years, the thickness of traumatic SAH might be greater on CT than younger people because of wider subarachnoid space due to brain atrophy as reported in aneurysmal SAH patients [12,13]. If the traumatic SAH is focally thick with poor clearance on CT looks like aneurysmal SAH, vasospasm might occur regardless of consciousness level of the patient.

Both our cases were alert on admission, and it was not difficult to suspect vasospasm when they became disoriented after a few days. It is reported that the onset of vasospasm is observed after 3 days of injury in most patients with traumatic SAH [5,6]. However, in symptomatic head trauma patients, it is difficult to ascertain that the worsening of the symptoms is due to the vasospasm or brain edema. Angiography is still gold standard for diagnosis of post-traumatic vasospasm, and CT perfusion and MRI ASL can measure CBF [1]. Transcranial Doppler (TCD) ultrasonography might be useful for early detection of vasospasm by measuring the mean blood flow velocity in brain injury patients [2–5,10]. Although TCD was not applied in our cases, frequent TCD study is recommended as serial non-invasive monitoring for vasospasm for a patient with focally thick traumatic SAH. If necessary, MRA or 3D-CTA should be performed for more detail evaluation of vasospasm [4]. Different from aneurysmal SAH, prophylactic treatments for vasospasm are not necessary in traumatic SAH, because triple-H therapy can worsen brain edema [4]. But prompt treatments are required for the vasospasm. The delay in detection and treatments for vasospasm contribute to poor outcomes in head trauma patients.

## Acknowledgements

We thank Nia Cason, PhD, from Edanz Group (<https://en-author-services.edanzgroup.com/ac>) for editing a draft of this manuscript.

## References

- [1] F. Al-Mufti, K. Amuluru, A. Changa, et al., Traumatic brain injury and intracranial hemorrhage-induced cerebral vasospasm: a systematic review, *Neurosurg. Focus.* 43 (2017) E14.
- [2] B. Aminmansour, A. Ghorbani, D. Sharifi, H. Shemshaki, A. Ahmadi, Cerebral vasospasm following traumatic subarachnoid hemorrhage 14 (2009) 343–348.
- [3] J.S. Compton, P.J. Teddy, Cerebral arterial vasospasm following severe head injury: a transcranial doppler study, *Br. J. Neurosurg.* 1 (1987) 435–439.
- [4] D.R. Kramer, J.L. Winer, B.A. Pease, A.P. Amar, W.J. Mack, Cerebral vasospasm in traumatic brain injury 2013 (2013), 415813.
- [5] N.A. Martin, C. Doberstein, C. Zane, M.J. Caron, K. Thomas, D.P. Becker, Posttraumatic cerebral arterial spasm: transcranial Doppler ultrasound, cerebral blood flow, and angiographic findings, *J. Neurosurg.* 77 (1992) 575–583.
- [6] M. Oertel, W.J. Boscardin, W.D. Obrist, et al., Posttraumatic vasospasm: the epidemiology, severity, and time course of an underestimated phenomenon: a prospective study performed in 299 patients, *J. Neurosurg.* 103 (2005) 812–824.
- [7] M.K. Morgan, B. Jonker, S. Finfer, T. Harrington, N.W. Dorsch, *J. Clin. Neurosci.* 7 (2000) 305–308.
- [8] R.W. Crowley, R. Medel, N.F. Kassell, A.S. Dumont, New insights into the causes and therapy of cerebral vasospasm following subarachnoid hemorrhage, *Drug Discov. Today* 13 (2008) 254–260.
- [9] M. Taneda, K. Kataoka, F. Akai, T. Asai, I. Sakata, Traumatic subarachnoid hemorrhage as a predictable indicator of delayed ischemic symptoms, *J. Neurosurg.* 84 (1996) 762–768.
- [10] A.Y. Zubkov, A.I. Lewis, F.A. Raila, J. Zhang, A.D. Parent, Risk factors for the development of post-traumatic cerebral vasospasm, *Surg. Neurol.* 53 (2000) 126–130.
- [11] J.J. Provencio, N. Vora, Subarachnoid hemorrhage and inflammation: bench to bedside and back, *Semin. Neurol.* 25 (2005) 435–444.
- [12] T. Inagawa, M. Yamamoto, K. Kamiya, H. Ogasawara, Management of elderly patients with aneurysmal subarachnoid hemorrhage, *J. Neurosurg.* 69 (1988) 332–339.
- [13] G. Lanzino, N.F. Kassell, T.P. Germanson, G.L. Kongable, L.L. Truskowski, J.C. Torner, J.A. Jane, Age and outcome after aneurysmal subarachnoid hemorrhage: why do older patients fare worse? *J. Neurosurg.* 85 (1996) 410–418.