

Case Report

Major Durable Response of Pembrolizumab in Chemotherapy Refractory Small Cell Bladder Cancer: A Case Report

Olav Toai Duc Nguyen^{a, b} Stein Harald Sundstrøm^{a, b}
Ganna Surzhykova Westvik^a Ane Karoline Stræte Røttereng^a
Mona Røli Melhus^a Cecilie Bergseth^a Elisabeth Kvelstad Hallem^a
Oluf Dimitri Røe^{a, b}

^aDepartment of Oncology, Levanger Hospital, Nord-Trøndelag Hospital Trust, Levanger, Norway; ^bDepartment of Clinical Research and Molecular Medicine, Norwegian University of Science and Technology, Trondheim, Norway

Keywords

Immunotherapy · Small cell bladder carcinoma · Small cell carcinoma · Liver metastasis · Biomarkers

Abstract

Small cell carcinoma of the urinary bladder is a rare subtype (incidence of 1–9/1,000,000), characterized by an aggressive behavior with early metastasis and poor prognosis. Chemotherapy, radiation, and surgery are the usual treatment options, but to date, no accepted standard treatment exists. Since small cell bladder cancer shares similar clinicopathological features with small cell lung cancer, the same type of chemotherapy has been used. Recently, immune checkpoint inhibitors have shown effect in small cell lung cancer, but data regarding small cell bladder cancer is insufficient. Here we present a case where a 73-year-old male with chemorefractory metastatic small cell bladder cancer received a successful treatment with immune checkpoint inhibitor pembrolizumab resulting in a major durable response and no side effects. To our knowledge, this is the second case report on successful treatment of the rare subtype of small cell bladder cancer with an immune checkpoint inhibitor, supporting the use of pembrolizumab as a therapeutic option for small cell bladder cancer. Serum neuron-specific enolase was a useful biomarker both for chemo- and immunotherapy response.

© 2020 The Author(s).
Published by S. Karger AG, Basel

Olav Toai Duc
Nguyen Department of Oncology, Levanger Hospital, Nord-Trøndelag Hospital Trust
Kirkegate 2
NO–7600 Levanger (Norway)
olav.t.d.nguyen@ntnu.no

Introduction

Small cell carcinoma of the urinary bladder is a rare subtype with a frequency ranging between 0.35 and 1.8% of all bladder cancers with an incidence of 1–9/1,000,000 [1]. It is characterized by a more aggressive behavior with early metastasis and poor prognosis [1, 2]. Patients frequently present with advanced disease; median survival without treatment is about 4–5 months [3]. Studies on this tumor type are small and scarce; there are only retrospective studies except one prospective phase II study, but no randomized clinical trials [1]. Chemotherapy, radiation, and cystectomy are the usual treatment options, but so far, no accepted standard treatment exists [2]. Since the tumor type shares many clinicopathological features with small cell carcinoma of the lung [4], most of the treatment options are extrapolated from small cell lung cancer [1]. The choice of palliative chemotherapy treatment is similar to the treatment of small cell lung cancer; with cisplatin or carboplatin in combination with etoposide in first line, and topotecan or the combination doxorubicin, cyclophosphamide, and vincristine (ACO) in second line. Recently, immune checkpoint inhibitors (ICI) have been proposed as a new promising therapeutic option after a report in 2016 of a successful treatment of a metastatic small cell bladder patient with the ICI pembrolizumab [3]. As a result of this, a phase II study (NCT03430895) on checkpoint therapies in patients with rare bladder cancer subtypes including small cell carcinoma was initiated [2]. Our case will be the second reported case with successful treatment of metastatic small cell bladder carcinoma with ICI, thereby supporting pembrolizumab as a therapeutic option for small cell bladder cancer.

Case Report

A 73-year-old male, ex-smoker in good general health condition, complained in June 2018 of 6 months of intermittent gross hematuria. A contrast-enhanced computed tomography (CT) was performed revealing a tumor lesion in the bladder, hepatomegaly, and multiple suspected lesions in the liver, suggesting invasive bladder cancer with liver metastasis. Serum level of the tumor marker neuron-specific enolase (NSE) was also elevated to 169 (normal range 0–16 µg/L) at the time, indicating small cell bladder cancer as a possible diagnosis. The patient underwent transurethral bladder resection (TURB), and the histopathological analysis revealed muscle-invasive small cell carcinoma (shown in Fig. 1A–D). Biopsy

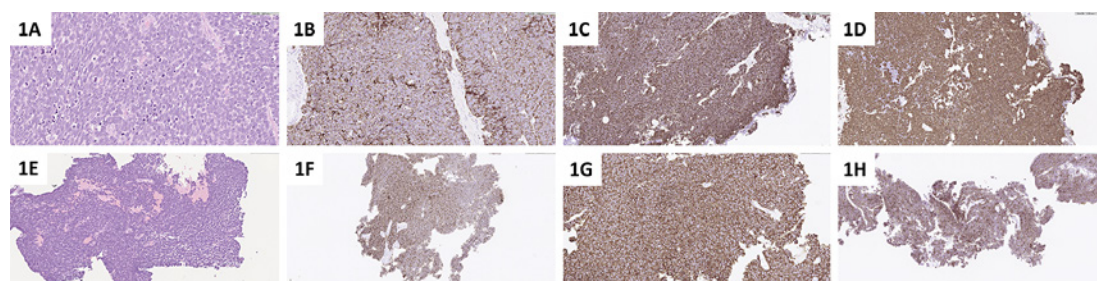


Fig. 1. A–D Pathology of bladder tumor. E–H Pathology of liver metastasis. A, E Hematoxylin and eosin staining of the biopsy specimen shows typical histopathological pattern with small epithelial cells and hyperchromatic nuclei. The cells grow in sheets with no specific structures. This pattern along with the immunohistochemical profile is typical for small cell carcinoma, independent of location and organ. B Immunostaining: cytokeratin AE1/AE3-antibody-positive bladder tumor cells. C Immunostaining: synaptophysin-antibody-positive bladder tumor cells. D Immunostaining: thyroid transcription factor 1 (TTF-1)-antibody-positive bladder tumor cells. F Immunostaining: cytokeratin AE1/AE3-antibody-positive tumor cells. G Immunostaining: synaptophysin-antibody-positive tumor cells. H Immunostaining: chromogranin-antibody-positive tumor cells.

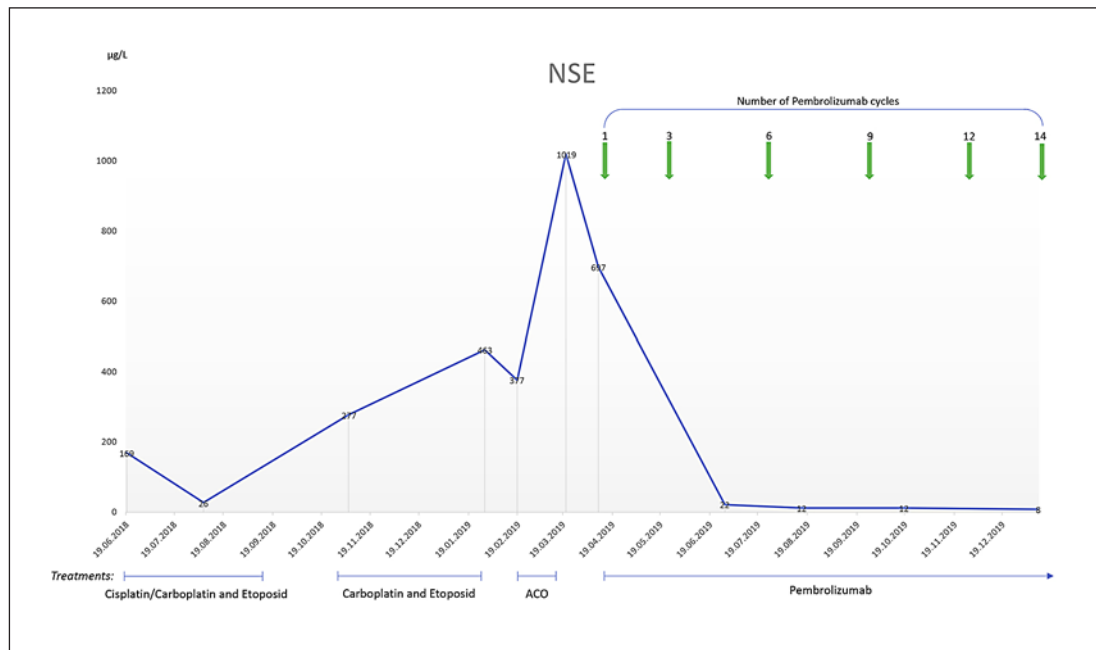


Fig. 2. Serum levels of tumor marker NSE pre- and post-pembrolizumab treatment. NSE normal range 0–16 µg/L. NSE, neuron-specific enolase; ACO, doxorubicin, cyclophosphamide, and vincristine.

from one of the liver lesions was also performed, confirming small cell carcinoma metastasis (shown in Fig. 1E, F). Microsatellite instability (MSI) analysis (MSI Analysis System, Promega) was performed in the biopsies of the bladder tumor as well as liver metastasis, but no MSI was detected. Furthermore, immunohistochemical analysis of DNA mismatch repair (MMR) genes MLH1, MSH2, MSH6, and PMS2 was also performed, but no deficiency was observed on these MMR genes. Programmed death ligand 1 (PD-L1) analysis was not performed due to non-validated method.

Initially the patient was treated with two cycles of cisplatin 75 mg/m² and etoposide 100 mg/m², but due to gradually reduced kidney function with increasing creatinine, cisplatin was replaced by carboplatin (AUC = 5). A total of six cycles of carboplatin and etoposide were administered every 3 weeks. CT and biochemical evaluation after the first four cycles of platinum-based chemotherapy showed disease regression with radiographic reduced tumor volume in the liver and decreased level of NSE from 169 to 26 (shown in Fig. 2). Due to these results, a pause in the treatment was initiated, but 8 weeks later, four more cycles were administered due to progression. After eight cycles, the progression of the disease was observed, both in the primary tumor and the liver as well as a rapid increase in NSE (shown in Fig. 2). However, the patient was still in good performance status (ECOG 0) and was highly motivated for more palliative treatment; therefore, second-line chemotherapy with ACO (doxorubicin 35 mg/m², cyclophosphamide 700 mg/m², and vincristine 2 mg/m²) was initiated from February 2019. This was terminated just after two cycles due to adverse events with neutropenia grade 3 (CTCAE) and thrombocytopenia grade 4 (CTCAE), the latter leading to gross hematuria, hospitalization, and need of several blood transfusions in March 2019. The patient recovered from it after 2 weeks of hospitalization, but due to the high risk of new hematological adverse effects, further palliative chemotherapy was not given. The disease was progressive with increasing numbers and size of liver metastasis; the patient had hepatomegaly and elevated and increasing serum level of liver enzymes in early April 2019.

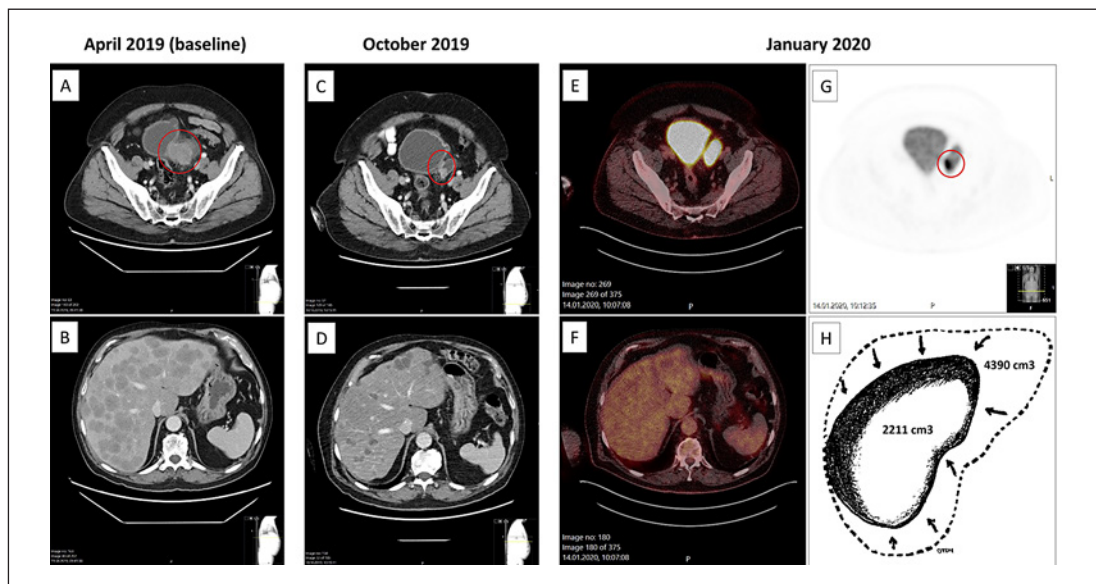


Fig. 3. A–G Radiographic response to pembrolizumab. Red circle indicates area of bladder tumor. **A, B** April 2019: baseline computed tomography scan (CT) prior to therapy. **C, D** October 2019: response after 6 months of pembrolizumab treatment. **E, F, G** January 2020: PET-CT response 9 months after pembrolizumab treatment was initiated. **H** Illustration of the response in the liver by volume reduction of $>2,000$ cm³ from April 2019 to January 2020; the liver volumes (measured in cm³) are measured based on the CT images from April 2019 and PET-CT from January 2020 by the use of PACS Sectras’s Volume Measurement Tool and General Electric’s AW Software, respectively.

Furthermore, the serum level of the tumor marker NSE was increasing and was as high as $>1,000$ (shown in Fig. 2), but the patient was still in good performance status (ECOG 1) and was highly motivated for further treatment. Based on the US Food and Drug Administration (FDA) approval of the ICI atezolizumab in combination with chemotherapy frontline in small cell lung cancer [5], and existing studies (phase II study KEYNOTE-158 and Ib study KEYNOTE-028) supporting the use of the ICI pembrolizumab alone in small cell lung cancer, as well as a former case report of successful treatment of small cell bladder cancer with pembrolizumab [3], immunotherapy was considered as an option in our patient. After informed consent and approval from the hospital, off-label treatment with pembrolizumab (200 mg given every 3 weeks) was initiated in April 2019.

Four days after the first cycle of pembrolizumab, the patient got hospitalized due to a proximal humerus fracture on the right arm after attempting to lift a light vacuum cleaner at home. He underwent surgery and fixation of the fracture. Histopathological analyzes of bone biopsy from the humerus confirmed small cell carcinoma metastasis to the bone. Adjuvant radiotherapy 4 Gy x 5 was given 4 weeks after the fixation of the pathological fracture. Bone scintigraphy was performed and showed no other bone metastases. The fracture was not considered as an adverse effect of the immunotherapy, since it occurred just 4 days after the initiation of immunotherapy. The pembrolizumab treatment was therefore continued and no discontinuation occurred during the period of fracture and radiotherapy. The treatment has been well tolerated; no adverse events have been reported so far. CT evaluation after 4, 6, and 9 cycles of pembrolizumab showed a dramatic decrease in the size of the primary tumor in the bladder (from 4.9 to 1.4 cm) as well as the metastatic disease in the liver. The liver metastases seemed to have disappeared, resulting in multiple empty cavities in the liver seen on

the CT images (shown in Fig. 3) and volume reduction of the liver by $>2,000\text{ cm}^3$ from April 2019 to January 2020 (shown in Fig. 3). The patient no longer has hepatomegaly and all the liver enzymes are now normalized. The serum level of the tumor marker NSE decreased rapidly after the first cycles of pembrolizumab and was normalized after 4 cycles of treatments and continues to be in the normal range (shown in Fig. 2). As of January 2020, 9 months after introducing pembrolizumab, there was an ongoing decrease of tumor volume in the bladder (1 cm) and there was complete response (CR) in the liver evaluated by CT and by positron emission tomography (PET), the only fluorodeoxyglucose-positive area left was in the bladder tumor (shown in Fig. 3). Due to these results, the case was discussed in the regional multidisciplinary team meeting in January 2020, concluding that resection of the residual tumor in the bladder is now possible and recommendable. The patient underwent successfully surgery by TURB on February 18, 2020. During the TURB, reddish mucosa was observed in part of the bladder; these regions were therefore biopsied. The histopathological analyses of the resected bladder tumor revealed muscle-invasive high-grade papillary urothelial carcinoma with partly small cell differentiation, while the analyses of the reddish mucosa of the bladder showed high-grade papillary urothelial carcinoma with infiltration in lamina propria but not in muscle. Both subtypes, small cell carcinoma and urothelial carcinoma, were probably present in the tumor initially – with the small cell carcinoma as the major part of the tumor and liver metastasis, resulting the major tumor response on ICI, but with a residual tumor in the bladder. Furthermore, the regional multidisciplinary team recommended on February 25, 2020, postoperative radiotherapy of the bladder. The patient underwent radiotherapy 42 Gy in 2.8 Gy fractions from the end of March 2020, and at the same time continued receiving pembrolizumab treatment. So far, the patient has received 19 cycles of pembrolizumab and is still receiving the treatment, but the dosing schedule of pembrolizumab has been changed from 200 mg every 3 weeks to 400 mg every 6 weeks after the sixteenth cycle of pembrolizumab. The tolerability of pembrolizumab treatment has been excellent; no side effects have been observed or reported, with excellent performance status (ECOG 0) and reported quality of life. The pembrolizumab treatment is continued after the resection of the residual bladder tumor and radiotherapy of the bladder, but the duration has yet to be decided. Based on the evidence of immunotherapy in other cancer types and duration of the treatment, like in metastatic melanoma [6], it is likely that the immunotherapy of our patient will be continued at least for a total of 24 months and thereafter follow-up with CT and NSE every 8–12 weeks. As of June 2020, 13 months after the introduction of pembrolizumab and 2 months after the postoperative radiotherapy of the bladder, one has achieved CR in the liver as well as in the bladder evaluated by CT.

The patient has given his written informed consent to publish his case including publication of images after reading the final version of the manuscript.

Discussion/Conclusion

Small cell bladder cancer is a rare and aggressive malignancy; the median survival time has been reported to be from 12 to 24 months with treatment and only 4–5 months without treatment [7]. Twenty-four months after the detection of a large bladder tumor and massive liver metastases and 15 months after progression on chemotherapy, our patient is still alive. He has to date no symptoms, ongoing CR in the liver and bladder, and is still receiving pembrolizumab monotherapy.

No standard treatment exists for small cell bladder cancer, but since it shares many clinicopathological features with small cell lung cancer [4], it is reasonable to expect a similar response of an ICI as found in small cell lung cancer. In Keynote-158, a total of 107 advanced

small cell lung cancer patients were included receiving pembrolizumab 200 mg every 3 weeks, all had received one or more prior treatments. At a median follow-up of 9.3 months (range, 0.5–22.3), three patients had CR, 17 had partial response, and 12 with stable disease, resulting in an overall response rate of 18.7% (95% CI, 11.8–27.4) [8]. In Keynote-028, twenty-four patients with metastatic small cell lung cancer were enrolled receiving pembrolizumab 10 mg/kg every 2 weeks, all had received two or more prior lines of chemotherapy [8]. At a median follow-up of 9.8 months (range, 0.5–24), results showed an overall response rate of 33% (95% CI, 16–55), including one patient with CR, seven patients with partial response, and one with stable disease for <6 months [8]. A pooled analysis of the two clinical trials Keynote-158 (phase II) and Keynote-028 (phase Ib) showed promising results on the ICI pembrolizumab in patients with advanced small cell lung cancer after two or more prior lines of treatment [9]. Based on the findings from these two cohorts, pembrolizumab was granted accelerated approval by the FDA in June 2019 for treatment of patients with metastatic small cell lung cancer with disease progression on or after platinum-based chemotherapy and at least one other prior line of therapy.

In our case, the tumor was initially sensitive of platinum-based therapy. Prior effect of platinum-based chemotherapy might be an indicator of better effect of immunotherapy compared to platinum-resistant disease [10]. Furthermore, platinum-based chemotherapy has also shown immunological effects [11]. Clinical activities on combinational regimens of ICI and platinum-based chemotherapeutic drugs have been observed in small cell lung cancer patients [12].

There are a few more additional factors that could have influenced the response in our patient. Firstly, the patient received two cycles of ACO, which includes cyclophosphamide and doxorubicin, before commencing the immunotherapy. Cyclophosphamide as well as doxorubicin have been reported to have the capacity to increase tumor cell immunogenicity by inducing immunogenic cell death [13], and thereby might have the potential to enhance the response of immunotherapy. Secondly, the patient received radiotherapy of his right humerus due to a pathological fracture between the first and second cycle of pembrolizumab. Radiation therapy may have an off-target effect in potentiating immunotherapy [14], and this could have played a role in this case. Finally, both the primary bladder tumor as well as the liver metastasis were MSI negative, indicating that it might be other molecular mechanisms that play a more profound role in this major response. In the recent results from Keynote-158, none of the 107 (0%) advanced small cell lung cancer patients included were MSI high [8], supporting that other molecular factors probably are of greater importance to immunotherapy response in small cell carcinoma. Tumor mutational burden has been proposed to be a predictive biomarker in small cell lung cancer for immunotherapy response [15], but this was not analyzed in our case. Given the meager knowledge on biomarkers, molecular profiling of the responding and non-responding tumors should be a prioritized area of research.

Serum NSE is a known tumor marker and prognostic factor in small cell lung cancer as well as in small cell bladder cancer [4], and can be used to monitor response. In our patient, the serum level of NSE decreased rapidly after the first cycles of pembrolizumab and continues to be very low. The serum biomarker NSE can therefore be useful to monitor response of ICI in small cell bladder cancer.

Since small cell bladder cancer is a rare subtype of bladder cancer, it will probably be difficult to get level A evidence through phase III clinical studies. Therefore, based on the former case report from Wilde et al. from 2016 [3] and now our case report, pembrolizumab should be considered as rescue therapy in chemorefractory small cell bladder cancer.

Furthermore, given the findings from the phase III trial IMPower133 [12], the FDA approved the ICI atezolizumab in combination with chemotherapy frontline in extensive-stage small cell lung cancer [5]. Due to the similarity of clinicopathological features between

small cell bladder cancer and small cell lung cancer [4], a combination of ICI and platinum-based chemotherapy might also improve the outcome of patients with small cell bladder cancer and should be considered in the future.

To our knowledge this is the second case report on successful treatment of the rare subtype of small cell bladder cancer with the ICI pembrolizumab, supporting that immunotherapy has a place in the treatment of this disease. Serum NSE seems to be a useful biomarker for response both for chemotherapy and immunotherapy.

Acknowledgement

We want to thank Senior Consultant Øystein Olsen at the Department of Radiology, Levanger Hospital, Levanger, Norway for providing the radiology images and Senior Consultant Trond Viset at the Department of Pathology, St. Olavs Hospital, Trondheim, Norway for the pathology service and images.

Statement of Ethics

Our patient has signed informed consent for publication of his medical history after reading the final version of the manuscript. We confirm that the manuscript has been read and approved by all the named authors.

Conflict of Interest Statement

The authors have no conflicts of interest to declare.

Funding Sources

Not applicable.

Author Contributions

Olav Toai Duc Nguyen: treating and following up the patient, initiated the chemotherapy treatment; substantial contribution to the conception of the work; analysis and interpretation of the data, writing and finalizing the manuscript; revising the final work critically before approval for publishing.

Stein Harald Sundstrøm: treating and following up the patient, revising the final work critically before approval for publishing.

Ganna Surzhykova Westvik: treating and following up the patient; revising the final work critically before approval for publishing.

Ane Karoline Stræte Røttereng: treating and following up the patient; revising the final work critically before approval for publishing.

Mona Røli Melhus: treating and following up the patient; revising the final work critically before approval for publishing.

Cecilie Bergseth: treating and following up the patient; revising the final work critically before approval for publishing.

Elisabeth Kvelstad Hallem: treating and following up the patient; revising the final work critically before approval for publishing.

Oluf Dimitri Røe: treating and following up the patient, initiated the pembrolizumab treatment; substantial contribution to the conception of the work; analysis and interpretation of the data; writing the manuscript and revising the final work critically before approval for publishing.

References

- Ismaili N. A rare bladder cancer– small cell carcinoma: review and update. *Orphanet J Rare Dis*. 2011;6:75.
- Mandelkow T, Blessin NC, Lueerss E, Pott L, Simon R, Li W, et al. Immune Exclusion Is Frequent in Small-Cell Carcinoma of the Bladder. *Dis Markers*. 2019;2019:2532518.
- Wilde L, Ali SM, Solomides CC, Ross JS, Trabulsi E, Hoffman-Censits J, et al. Response to Pembrolizumab in a Patient With Chemotherapy Refractory Bladder Cancer With Small Cell Variant Histology: A Case Report and Review of the Literature. *Clin Genitourin Cancer*. 2017;15(3):e521–e4.
- Naito A, Taguchi S, Nakagawa T, Matsumoto A, Nagase Y, Tabata M, et al. Prognostic significance of serum neuron-specific enolase in small cell carcinoma of the urinary bladder. *World J Urol*. 2017;35(1):97–103.
- Administration . [FDA approves atezolizumab for extensive-stage small cell lung cancer. U.S. 2019](https://www.fda.gov/drugs/drug-approvals-and-databases/fda-approves-atezolizumab-extensive-stage-small-cell-lung-cancer) [cited 2019 March 19]. <https://www.fda.gov/drugs/drug-approvals-and-databases/fda-approves-atezolizumab-extensive-stage-small-cell-lung-cancer>.
- Robert C, Ribas A, Schachter J, Arance A, Grob JJ, Mortier L, et al. Pembrolizumab versus ipilimumab in advanced melanoma (KEYNOTE-006): post-hoc 5-year results from an open-label, multicentre, randomised, controlled, phase 3 study. *Lancet Oncol*. 2019;20(9):1239–51.
- Koay EJ, Teh BS, Paulino AC, Butler EB. A Surveillance, Epidemiology, and End Results analysis of small cell carcinoma of the bladder: epidemiology, prognostic variables, and treatment trends. *Cancer*. 2011;117(23):5325–33.
- Columbus G. [Pembrolizumab granted FDA's priority review for advanced SCLC. U.S. 2019](https://www.targetedonc.com/view/pembrolizumab-granted-fdas-priority-review-for-advanced-sclc) [cited 2019 February 20]. <https://www.targetedonc.com/view/pembrolizumab-granted-fdas-priority-review-for-advanced-sclc>.
- Chung HC, Piha-Paul SA, Lopez-Martin J, Schellens JHM, Kao S, Miller WH, Jr., et al. Pembrolizumab After Two or More Lines of Previous Therapy in Patients With Recurrent or Metastatic SCLC: Results From the KEYNOTE-028 and KEYNOTE-158 Studies. *J Thorac Oncol*. 2020;15(4):618–27.
- Liu YL, Zhou Q, Iasonos A, Emengo VN, Friedman C, Konner JA, et al. Subsequent therapies and survival after immunotherapy in recurrent ovarian cancer. *Gynecol Oncol*. 2019;155(1):51–7.
- Hato SV, Khong A, de Vries IJ, Lesterhuis WJ. Molecular pathways: the immunogenic effects of platinum-based chemotherapeutics. *Clin Cancer Res*. 2014;20(11):2831–7.
- Horn L, Mansfield AS, Szczyńska A, Havel L, Krzakowski M, Hochmair MJ, et al. First-Line Atezolizumab plus Chemotherapy in Extensive-Stage Small-Cell Lung Cancer. *N Engl J Med*. 2018;379(23):2220–9.
- Wu J, Waxman DJ. Immunogenic chemotherapy: Dose and schedule dependence and combination with immunotherapy. *Cancer Lett*. 2018;419:210–21.
- Ko EC, Formenti SC. Radiation therapy to enhance tumor immunotherapy: a novel application for an established modality. *Int J Radiat Biol*. 2019;95(7):936–9.
- Hellmann MD, Callahan MK, Awad MM, Calvo E, Ascierto PA, Atmaca A, et al. Tumor Mutational Burden and Efficacy of Nivolumab Monotherapy and in Combination with Ipilimumab in Small-Cell Lung Cancer. *Cancer Cell*. 2018;33(5):853–61.e4.