

Usefulness of hyperintense acute reperfusion marker sign in patients with transient neurologic symptom

Jihoon Kang, MD^a, Hyuksool Kwon, MD^{b,*}, Cheol Kyu Jung, MD, PhD^c, Hee-Joon Bae, MD, PhD^a, Moon-Ku Han, MD, PhD^a, Beom Joon Kim, MD^a, You Hwan Jo, MD, PhD^b

Abstract

It aimed to investigate the incidence and final diagnosis of hyperintense acute reperfusion marker (HARM) signs in patients initially suspected of having a transient ischemic attack (TIA).

In retrospective manner, a series of consecutive series of patients who arrived at the emergency department and was initially assessed as TIA within 12 hours of symptom onset between July 2015 and December 2016 were enrolled. Conventional magnetic resonance imaging protocol including diffusion-weighted imaging (DWI) and pre- and post-contrast fluid attenuation inversion recovery imaging (FLAIR) was conducted to evaluate the ischemic lesion and prognosis. Through the review of medical records and imaging studies, their final diagnosis and its association with HARM signs on post-contrast FLAIR were investigated.

A total of 174 subjects were enrolled (mean age, 64.0 ± 12.9 years old; male, 54.6%; DWI lesion, 17.8%). HARM signs were observed in 18 (10%) patients, and their final diagnoses were classified as true TIA (n = 11, 61%), seizure (2, 11%), posterior reversible encephalopathy (2, 11%), reversible cerebral vascular constriction (1, 6%) and unclassified encephalopathy (2, 11%). The co-occurrence of HARM and DWI lesions were observed in 7 subjects which were 6 subjects of true TIA (ischemic stroke) and 1 subject with RCVS related ischemic stroke.

The observation of HARM sign would be helpful to confirm the ischemic insult and distinguish the other disease.

Abbreviations: CSF = cerebrospinal fluid, DWI = diffusion-weighted imaging, ED = emergency department, FLAIR = fluid attenuation inversion recovery imaging, HARM = hyperintense acute reperfusion marker, IQR = interquartile range, MRI = magnetic resonance imaging, PRES = posterior reversible encephalopathy, RCVS = reversible cerebral vasoconstriction syndrome, SD = standard deviation, TIA = transient ischemic attack, TNS = transient neurologic symptom.

Keywords: fluid attenuation inversion recovery imaging, HARM signs, hyperintense acute reperfusion marker, magnetic resonance imaging, MRI, TIA, transient ischemic attack

1. Introduction

Patients with transient neurologic symptoms (TNS) are usually checked based on physicians' assumptions in the emergency

setting; these patients are usually diagnosed with a transient ischemic attack (TIA).^[1–3] However, the conventional process has a risk of misdiagnosis and could even delay the exact diagnosis and prompt management of other neurologic diseases.^[4,5] The 10% to 49% of patients changed the final diagnosis as having other TIA mimic diseases, such as seizure, posterior reversible encephalopathy (PRES) and reversible cerebral vasoconstriction syndrome (RCVS).^[2,3]

There have been attempts to improve the accuracy of diagnosis of true TIA and other mimic diseases. Some studies tried to determine the feasibility of adopting the ABCD^[2] score that was originally developed to predict recurrence risk, and others tried to identify important stroke risk factors, such as steno-occlusion of the cerebral artery and cardioembolic risk factors.^[2,4,5] Imaging studies also have been used to exclude alternative non-ischemic origins and to gain additional information about the prognosis.^[6] The various imaging tools, such as computed tomography, diffusion weighted imaging (DWI), perfusion weighted imaging (PWI) and angiographic examination, has been tested; however, they are still deficient for differentiating other neurologic diseases.^[7,8]

Traditionally, contrast extravasation phenomenon has been termed hyperintense acute injury marker (HARM) sign which denoted the radiologic finding of the hyperintense signal within the cerebrospinal fluid (CSF) spaces visualized on postcontrast fluid-attenuated inversion recovery (FLAIR) image.^[9] It has been

Editor: Marco Onofri.

The authors declare that the research was conducted in the absence of any commercial or financial relationships that could be construed as a potential conflict of interest.

Supplemental Digital Content is available for this article.

^aDepartment of Neurology, Seoul National University Bundang Hospital, Bundang-gu, Seongnam-si, ^bDepartment of Emergency Medicine, Seoul National University Bundang Hospital, Bundang-gu, Seongnam-si, Gyeonggi-do, ^cDepartment of Radiology, Seoul National University Bundang Hospital, Bundang-gu, Seongnam-si, Republic of Korea.

*Correspondence: Hyuksool Kwon, Seoul National University Bundang Hospital, Seongnam-si, Gyeonggi-do Korea, Republic of Korea (e-mail: jinuking3g@naver.com).

Copyright © 2019 the Author(s). Published by Wolters Kluwer Health, Inc. This is an open access article distributed under the terms of the Creative Commons Attribution-Non Commercial License 4.0 (CCBY-NC), where it is permissible to download, share, remix, transform, and buildup the work provided it is properly cited. The work cannot be used commercially without permission from the journal.

Medicine (2019) 98:19(e15494)

Received: 30 August 2018 / Received in final form: 5 April 2019 / Accepted: 10 April 2019

<http://dx.doi.org/10.1097/MD.00000000000015494>

hypothesized that HARM represents contrast leakage into the subpial space due to blood-brain barrier (BBB) disruption (Supplemental Figure 1, <http://links.lww.com/MD/C968>).^[7] In ischemic stroke, HARM signs are associated with reperfusion injury and hemorrhagic transformation.^[10,11] In other hand, HARM signs are observed in other disease affecting the BBB, such as subarachnoid hemorrhage, traumatic brain injury, seizure, PRES, and RCVS,^[12–17] it was expected to have the diagnostic role.

This study aimed to investigate the incidence and clinical significance of HARM signs in patients initially suspected of having TIA using the prospective stroke and TIA registry, which involves conducting the routine magnetic resonance imaging (MRI) protocol including DWI, PWI, angiography and pre- and post-contrast FLAIR in an early time window.

2. Methods

2.1. Study design and setting

Patients who presented to the emergency department (ED) between July 2015 and December 2016 were consecutively enrolled. Ethical approval for the study was obtained from the local Institutional Review Board with a waiver of informed consent considering the retrospective and observational study design and minimal risk of harm.

2.2. Selection of participants

The study was conducted at an academic hospital located in Seongnam, Republic of Korea, with more than 90,000 visits to the ED each year. All patients who presented to the ED with TNS on arrival at the triage unit of the ED were eligible for enrollment. Among them, patients who arrived within 12 hours of symptom onset and evaluated the brain MRI study under suspicious TIA by neurologist inspection according to the institutional stroke clinical pathway were consecutively identified (Supplemental Figure 2, <http://links.lww.com/MD/C968>). The research staff retrospectively searched the patient's electronic medical records and imaging storage to obtain clinical and laboratory information. The demographic variables (age, sex), stroke information (time to onset to arrival, stroke severity at baseline and discharge, history of stroke and modified Rankin Scale (mRS)), clinical factors (hypertension, diabetes mellitus, dyslipidemia, atrial fibrillation) were gathered.

2.3. Brain imaging protocol and MRI technique

The uniform MRI protocol was composed of diffusion weighted imaging (DWI, TR/TE, 3800–5000/45–60; b=1000 s/mm²), axial gradient-recalled echo imaging (TR/TE, 690–1100/15–24), time-of-flight MR angiography, dynamic susceptibility perfusion-weighted imaging (PWI) with administration of contrast material, axial contrast-enhanced T1-weighted imaging (TR/TE, 4000–600/9–12), and non-contrast and axial contrast-enhanced FLAIR imaging. Contrast-enhanced FLAIR images were obtained using a turbo spin-echo sequence with the following parameters: TR/TE, 11,000/120–140; inversion time, 2500 ms; echo-train length, 26; ip angle, 90°; FOV, 216 × 240 mm; acquisition matrix, 256 × 162; and slice thickness, 5 mm. FLAIR images were obtained approximately 5 minutes after IV administration of 15 mL of contrast material (gadobutrol; Gadovist, Bayer HealthCare). MRI was completed on either a

1.5-T Avanto (Siemens Healthineers, Erlangen, Germany) or a 1.5-T and 3-T Achieva (Philips Healthcare, Best, the Netherlands).^[17]

2.4. Image analysis

Two readers reviewed all examinations. Both readers were blinded to clinical and laboratory information as well as the diagnosis and indication for the examination. They corroborated lesion identification of HARM on abnormal cortical and sulcal enhancements of FLAIR images with a review of other sequence images; finally, lesion identification was confirmed in consensus by neuroradiologists. DWI positive was defined as b values corresponding to the diffusion-sensitizing gradient were 0 and 1000 s/mm² on automatically derived the apparent diffusion coefficient maps, which presented the acute cerebral infarction in case of ADC values of less than 580×10^{-6} mm²/s.^[18,19]

2.5. Outcomes and review process

The study outcome was the causative disease of HARM, which was finally ascertained by reviewing the institutional electric health recording including the inpatient and outpatient clinic. Based on reviewing the electric health information and results of imaging analysis, we ascertained the final diagnosis of the presence of HARM or not (HARM positive versus HARM negative). In case of HARM positive, presumed the causative disease were classified into

- (1) true TIA with either DWI positive or DWI negative,
- (2) seizure related,
- (3) PRES,
- (4) RCVS,
- (5) leptomeningeal malignancy,
- (6) trauma brain injury or
- (7) unclassified encephalopathy.

The unclassified encephalopathy denoted the HARM positive without any presumed causative disease and surveyed the possible condition as like heart failure and cardiomyopathy.

In patients with HARM positive and true TIA, the presence of symptomatic vascular lesions, location, and degree of the stenotic lesion and perfusion defect were additionally investigated.

2.6. Statistical analysis

The baseline characteristics and imaging findings of study subjects were summarized in frequency (percentage) for categorical binary variable, median (interquartile range, IQR) for non-parametric variables, such as time from onset to arrival and NIHSS score (National Institute of Health Stroke Scale) and mean ± standard deviation (SD) for parametric variable (age). Then, baseline characteristics were compared according to the presence of HARM or not (HARM positive versus HARM negative) using the Pearson chi-square test for a binary variable, Whitney Mann *U* test for non-parametric variables or *t* test for a parametric variable.

In patients with HARM positive, investigated causative diseases were summarized. The location and degree of symptomatic steno-occlusion of cerebral artery were investigated in patients with HARM positive and true TIA. SPSS software was used for analysis (SPSS version 18.0, IBM corp., USA), and a *P* value of less than .05 was set for statistical significance.

3. Results

3.1. Baseline characteristics of study subjects

A total of 174 consecutive subjects became the study subjects. Baseline characteristics of the study subjects were summarized (Table 1). The mean age was 64.0 ± 12.9 years old, and males made up 54.6%. It took a median of 2.2 hours (1.0–4.2 h) from the onset of neurologic symptoms to hospital arrival. On initial imaging study, 17.8% of study subjects presented DWI lesions.

3.2. Burden of HARM and clinical associations

On the enhanced FLAIR images, 18 (10.3%) subjects showed HARM signs (HARM positive). The presence of HARM did not show statistical differences in baseline characteristics (Table 1). The demographic and vascular risk factors did not show significantly different characteristics according to the HARM positive and HARM negative. Also, the presence of HARM was significantly associated with the presence of DWI lesion ($P = .002$), not with favorable outcome ($P = .223$).

Among patients had HARM positive, 61.1% were determined to be the TIA. Another causative disease of HARM positive were seizures, PRES, RCVS and unclassified encephalopathy. Two unclassified encephalopathies had dilated cardiomyopathy. In HARM positive, DWI lesions were observed in 7 subjects which were dichotomized into 6 patients of true TIA and one patient of RCVS (Table 2).

In patients with TIA and HARM positive ($n = 11$), the presence of DWI lesion was not significantly associated with time interval from symptom onset to MR examination (P by Whitney Mann U test = .762), which were estimated by median 4.3 hours (IQR, 2.6–4.9 h) in DWI lesion positive and 3.1 hours (IQR, 1.2–5.2 h) in DWI lesion negative, respectively.

In the case of both HARM positive and DWI lesion positive, it sometimes gave more information about the distribution of reperfusion injury and recanalization that cannot be determined from the distribution of the DWI lesion and angiography study (Fig. 1).

In patients adjudicated as true TIA with HARM, most of them had the symptomatic steno-occlusion lesion of a cerebral artery (Supplemental Table 1, <http://links.lww.com/MD/C968>). Of them, 2 subjects with true TIA had recent procedures of carotid

Table 2

Classification of hyperintensity acute reperfusion markers (n = 18).

Category	Frequency (percentage)
TIA	11 (61.1%)
DWI lesion +	6 (33.3%)
DWI lesion –	5 (27.8%)
Seizure	2 (11.1%)
PRES	2 (11.1%)
RCVS	1 (5.6%)
DWI lesion +	1 (5.6%)
Unclassified encephalopathy	2 (11.1%)

Values are the number of patients (percentage). TIA was abbreviated for transient ischemic attack, DWI for diffusion weighted imaging, PRES for posterior reversible encephalopathy syndrome and RCVS for reversible cerebral vasoconstriction syndrome.

artery stenting and diagnostic digital subtraction angiography examination.

A patient with RCVS showed HARM signs at the bilateral temporal-occipital area on enhanced FLAIR but not on the non-enhanced FLAIR. Her complaint was transient language disturbance with preceding sudden onset headache 2 days before hospital arrival and suspicions of aphasia for less than 10 minutes. Initial MRA showed multifocal stenosis segments at distal branches of the middle and posterior cerebral arteries that were resolved during the follow-up study (Fig. 2).

4. Discussion

This study showed that patients who visited as a result of TNS have approximately 10% of HARM signs in their initial MRI study that are helpful in revealing their true neurologic disease.

Since the patients' clinical symptoms were transient or rapidly improved, the diagnosis was dependent on clinical decision based on the patients' history, risk factors, and conventional imaging studies, such as computed tomography and DWI. However, they usually had similar features (Table 1), they may be misdiagnosed with true TIA if enhanced FLAIR had not been used. Our findings suggested that this MRI sequence may have the chance to improve the diagnosis of less prevalent neurologic diseases. Moreover, HARM signs were not affected by the other patient's underlying conditions, such as demographic and vascular risk

Table 1

Baseline characteristics of study subjects and their comparisons by HARM signs.

Variables	Total subjects (n = 174)	HARM positive (n = 18)	HARM negative (n = 156)	P
Male	95 (54.6%)	8 (44.4%)	87 (55.8%)	.361
Age, yr, mean \pm SD	64.0 ± 12.9	65.0 ± 15.5	63.9 ± 12.6	.724
Time from onset to arrival, h, median (IQR)	2.2 (1.0 – 4.2)	2.4 (1.2 – 4.0)	2.2 (1.0 – 4.4)	.876
Baseline NIHSS score, median (IQR)	0 (0–1)	0 (0–1)	0 (0–1)	.562
NIHSS score at discharge, median (IQR)	0 (0–0)	0 (0–0)	0 (0–0)	.419
History of stroke	32 (17.4%)	30 (19.2%)	2 (1.1%)	.400
Hypertension	107 (61.5%)	10 (55.6%)	97 (62.2%)	.584
Diabetes mellitus	44 (25.3%)	2 (11.1%)	42 (26.9%)	.144
Dyslipidemia	79 (45.4%)	6 (33.3%)	73 (46.8%)	.277
Atrial fibrillation	20 (11.5%)	2 (11.1%)	18 (11.5%)	.957
DWI lesion	30 (17.2%)	7 (38.9%)	23 (14.7%)	.002
Favorable outcome (mRS, 0–2)	162 (93.1%)	18 (100.0%)	144 (92.3%)	.223

Values are the number of patients (percentage) except for specific description. HARM was abbreviated for hyperintense acute reperfusion marker, IQR for interquartile range, mRS for modified Rankin Scale, and SD was abbreviated for standard deviation. P values were estimated by Pearson chi-square test, Whitney Mann U test or t test as appropriate.

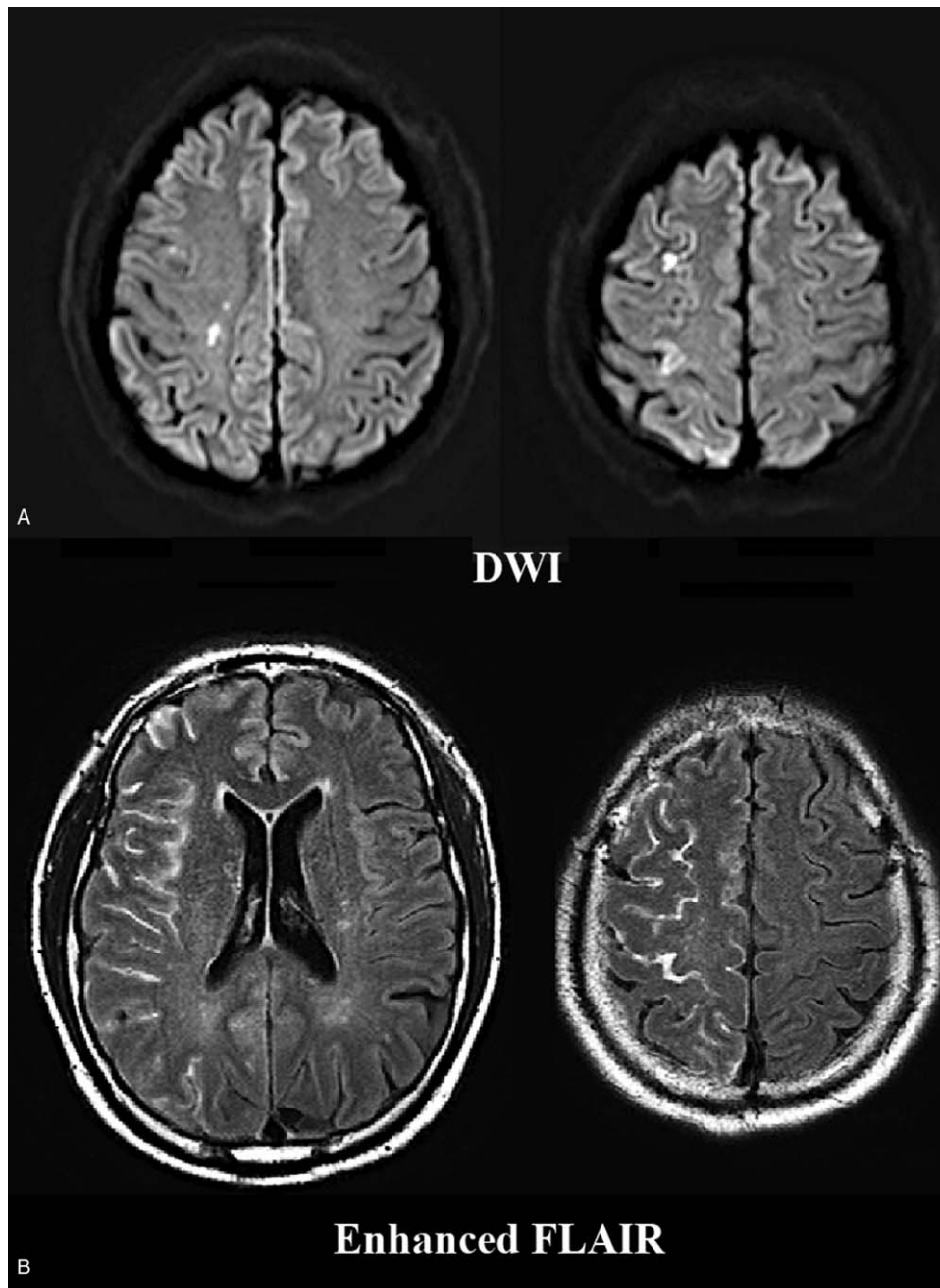


Figure 1. Ischemic lesion and HARM signs of patients with transient left hemiparesis. DWI images of upper row (A) showed multiple small-sized ischemic lesions (arrow). The enhanced FLAIR images of lower row (B) presented diffuse HARM signs in the sulci of hemispheric cortex at right middle cerebral arterial territory (arrowhead).

factors, which was the peculiar marker presenting the pial leakage to CSF space.^[20]

HARM on FLAIR sequence has been described as a sign of early blood-brain barrier (BBB) breakdown in various clinical conditions, typically ischemic stroke, and especially the recanalization state after endovascular treatment that is related to reperfusion injury and delayed gadolinium contrast enhancement in the subarachnoid space with and without hemorrhagic event.^[9–11,17,21] Also, subarachnoid hemorrhage, traumatic brain injury, seizure, PRES, and RCVS would cause HARM to FLAIR MRI sequences.^[15,14,22]

The RCVS can cause the BBB breakdown by sympathetic over-activity and dysregulation of vascular tone and cause many neurologic complications, such as PRES, subarachnoid or intracerebral hemorrhage and even sudden death.^[23] Early diagnosis of RCVS is difficult because of the dynamic nature of the disease course and limitations of current non-invasive angiography modalities.^[24] Enhanced FLAIR can determine the BBB breakdown and is helpful for early detection.^[15]

HARM signs also supported determination of ischemic injury even in the transient state.^[25] This study showed that about half of the patients with HARM resulting from ischemic injury had no

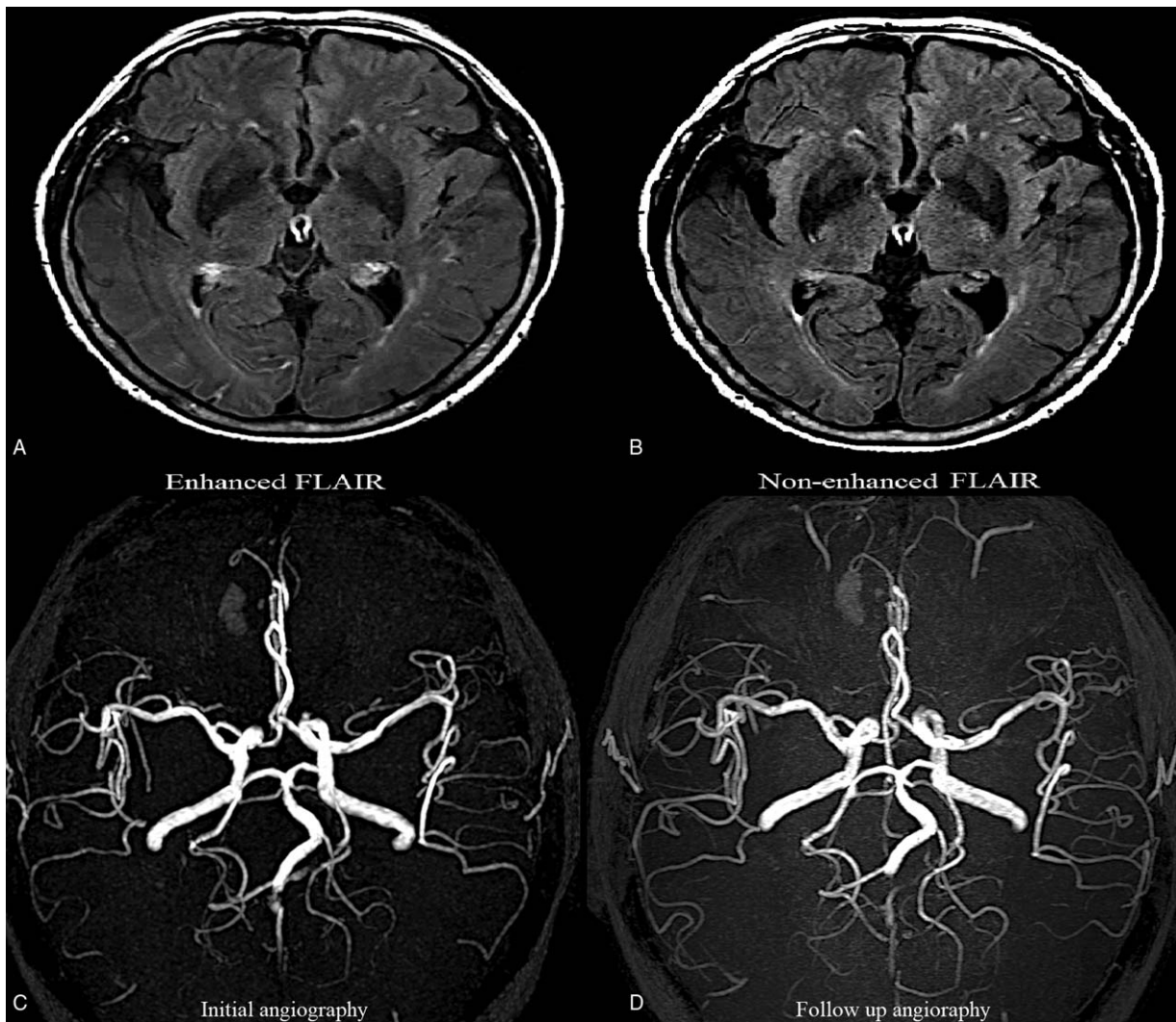


Figure 2. HARM sign in a patient with RCVS. The enhanced FLAIR image (A) showed the cortical HARM sign (arrow) in the bilateral temporal-occipital lobes compared to the non-enhanced FLAIR (B). A 67-year-old female visited as a result of a transient language problem (impairment of comprehension) and right arm weakness with preceding thunderclap headache 2 days ago. Initial MR angiography (C) showed multifocal stenosis through distal branches of the left middle cerebral artery and posterior cerebral artery that were improved in the follow-up angiography (D).

definite DWI lesion. Since short-duration and sudden hemodynamic instability would cause BBB breakdown without a permanent infarct, the prognosis itself would be favorable.^[26] Focus had to be the situation of HARM signs that provoked hemodynamic instability. As noted, 1 event was followed by recent carotid artery stenting. The HARM signs of 2 subjects with unclassified encephalopathy were possibly related to dilated cardiomyopathy which may be the cause of hemodynamic instability.

This study had several limitations. First, it was a retrospective, single-center study with a small cohort that had a risk of selection bias. Though it enrolled consecutive subjects, prospectively confirming the research would give more concrete evidence. Second, we did not analyze the severity of HARM to discern if there is a gradation of injury that may further correlate with the final diagnosis. Correlations between the severity of HARM and diagnosis could possibly exist. Third, MR protocols were set up to innovate and improve the hospital's system under a multidisciplinary effort that might require a higher burden of resources.

Our study reported that HARM signs in those with TNS are noted, and the investigation of their characteristics would help to reveal their final diagnosis. In patients with the true TIA, the HARM signs would give more information, such as extent and location of ischemic insult in addition to the conventional images. In the TIA mimics, it may give evidence of cerebral involvement.

Author contributions

Conceptualization: Jihoon Kang, Hyuksool Kwon, Cheol Kyu Jung, Hee-Joon Bae, Moon-Ku Han, Beom Joon Kim, You Hwan Jo.

Data curation: Jihoon Kang, Hyuksool Kwon.

Formal analysis: Jihoon Kang, Hyuksool Kwon.

Investigation: Jihoon Kang, Hee-Joon Bae, Moon-Ku Han, Beom Joon Kim.

Methodology: Hyuksool Kwon.

Resources: Cheol Kyu Jung.

Writing – original draft: Jihoon Kang.

Writing – review & editing: Jihoon Kang, Hyuksool Kwon, Cheol Kyu Jung, You Hwan Jo.
 Jihoon Kang orcid: 0000-0001-5715-6610.

References

- [1] Kothari RU, Brott T, Broderick JP, et al. Emergency physicians. Accuracy in the diagnosis of stroke. *Stroke* 1995;26:2238–41.
- [2] Josephson SA, Sidney S, Pham TN, et al. Higher ABCD2 score predicts patients most likely to have true transient ischemic attack. *Stroke* 2008;39:3096–8.
- [3] Amort M, Fluri F, Schäfer J, et al. Transient ischemic attack versus transient ischemic attack mimics: frequency, clinical characteristics and outcome. *Cerebrovasc Dis* 2011;32:57–64.
- [4] Quinn TJ, Cameron AC, Dawson J, et al. ABCD2 scores and prediction of noncerebrovascular diagnoses in an outpatient population: a case-control study. *Stroke* 2009;40:749–53.
- [5] Chang JY, Kim DH, Chung J-H, et al. Hospital-based prospective registration of acute transient ischemic attack and noncerebrovascular events in Korea. *J Stroke Cerebrovasc Dis* 2015;24:1803–10.
- [6] Easton JD, Saver JL, Albers GW, et al. Definition and Evaluation of Transient Ischemic Attack: A Scientific Statement for Healthcare Professionals From the American Heart Association/American Stroke Association Stroke Council; Council on Cardiovascular Surgery and Anesthesia; Council on Cardiovascular Radiology and Intervention; Council on Cardiovascular Nursing; and the Interdisciplinary Council on Peripheral Vascular Disease: The American Academy of Neurology affirms the value of this statement as an educational tool for neurologists. *Stroke* 2009;40:2276–93.
- [7] Restrepo L, Jacobs MA, Barker PB, et al. Assessment of transient ischemic attack with diffusion- and perfusion-weighted imaging. *AJNR Am J Neuroradiol* 2004;25:1645–52.
- [8] Ay H, Oliveira-Filho J, Buonanno FS, et al. Footprints” of transient ischemic attacks: a diffusion-weighted MRI study. *Cerebrovasc Dis* 2002;14:177–86.
- [9] Latour LL, Kang D-W, Ezzeddine MA, et al. Early blood-brain barrier disruption in human focal brain ischemia. *Ann Neurol* 2004;56:468–77.
- [10] Warach S, Latour LL. Evidence of reperfusion injury, exacerbated by thrombolytic therapy, in human focal brain ischemia using a novel imaging marker of early blood-brain barrier disruption. *Stroke* 2004;35 (11 Suppl 1):2659–61.
- [11] Hayakawa M. Reperfusion-related intracerebral hemorrhage. *Front Neurol Neurosci* 2015;37:62–77.
- [12] Gupta R, Sun C-HJ, Rochestie D, et al. Presence of the hyperintense acute reperfusion marker on MRI after mechanical thrombectomy for large vessel occlusion is associated with worse early neurological recovery. *J NeuroInterv Surg* 2017;9:641–3.
- [13] Simpkins AN, Dias C, Leigh R. National institutes of health natural history of stroke investigators. Identification of reversible disruption of the human blood-brain barrier following acute ischemia. *Stroke* 2016;47:2405–8.
- [14] Kastrup O, Schlamann M, Moeninghoff C, et al. Posterior reversible encephalopathy syndrome: the spectrum of MR imaging patterns. *Clin Neuroradiol* 2015;25:161–71.
- [15] Lee MJ, Cha J, Choi HA, et al. Blood-brain barrier breakdown in reversible cerebral vasoconstriction syndrome: implications for pathophysiology and diagnosis. *Ann Neurol* 2017;81:454–66.
- [16] Kim DM, Lee IH, Song CJ. Uremic encephalopathy: MR imaging findings and clinical correlation. *Am J Neuroradiol* 2016;37:1604–9.
- [17] Lee KM, Kim JH, Kim E, et al. Early stage of hyperintense acute reperfusion marker on contrast-enhanced FLAIR images in patients with acute stroke. *Am J Roentgenol Am Roentgen Ray Soc* 2016.
- [18] Sacco RL, Kasner SE, Broderick JP, et al. An updated definition of stroke for the 21st century: a statement for healthcare professionals from the American Heart Association/American Stroke Association. *Stroke* 2013;44:2064–89.
- [19] Röhl L, Ostergaard L, Simonsen CZ, et al. Viability thresholds of ischemic penumbra of hyperacute stroke defined by perfusion-weighted MRI and apparent diffusion coefficient. *Stroke* 2001;32:1140–6.
- [20] Ostwaldt A-C, Rozanski M, Schmidt W U, et al. Early time course of FLAIR signal intensity differs between acute ischemic stroke patients with and without hyperintense acute reperfusion marker. *Cerebrovasc Dis* 2014;37:141–6.
- [21] Köhrmann M, Struffert T, Frenzel T, et al. The hyperintense acute reperfusion marker on fluid-attenuated inversion recovery magnetic resonance imaging is caused by gadolinium in the cerebrospinal fluid. *Stroke* 2012;43:259–61.
- [22] Kim DW, Moon Y, Gee Noh H, et al. Blood-brain barrier disruption is involved in seizure and hemianopsia in nonketotic hyperglycemia. *Neurologist* 2011;17:164–6.
- [23] Calabrese LH, Dodick DW, Schwedt TJ, et al. Narrative review: reversible cerebral vasoconstriction syndromes. *Ann Intern Med* 2007;146:34–44.
- [24] Miller TR, Shivashankar R, Mossa-Basha M, et al. Reversible cerebral vasoconstriction syndrome, Part 2: diagnostic work-up, imaging evaluation, and differential diagnosis. *AJNR Am J Neuroradiol Am J Neuroradiol* 2015;36:1580–8.
- [25] Förster A, Wenz H, Groden C. Hyperintense acute reperfusion marker on FLAIR in a patient with transient ischemic attack. *Case Rep Radiol* 2016;2016:9829823.
- [26] Lee H, Kim E, Lee KM, et al. Clinical implications of sulcal enhancement on postcontrast fluid attenuated inversion recovery images in patients with acute stroke symptoms. *Korean J Radiol* 2015;16:906–13.