

# Clinical Outcomes and Management Strategies for Capitellum and Trochlea Fractures: A Systematic Review

Ali Lari <sup>1</sup>, Yasmen Alrumaidhi<sup>1</sup>, Diego Martinez<sup>2</sup>, Amaar Ahmad<sup>1</sup>, Hamad Aljuwaied<sup>1</sup>,  
Mohammad Alherz<sup>3</sup>, Carlos Prada <sup>4</sup>

<sup>1</sup>Department of Orthopedic Surgery, AlRazi National Orthopedic Hospital, Kuwait City, Kuwait; <sup>2</sup>Hospital of the Worker of Santiago: Hospital del Trabajador de Santiago, Santiago, Chile; <sup>3</sup>Department of Anatomy, Trinity College Dublin, Dublin, Ireland; <sup>4</sup>St Joseph's Health Care, Hand and Upper Limb Centre, University of Western Ontario, London, Ontario, Canada

Correspondence: Ali Lari, Email Dr.alilari@gmail.com

**Purpose:** Capitellum and trochlea fractures, also referred to as coronal shear fractures of the distal humerus, are infrequent yet challenging intra-articular fractures of the elbow. There are a variety of surgical approaches and fixation methods with often variable outcomes. This systematic review investigates interventions, outcomes and complications of capitellum and trochlea fractures.

**Methods:** A systematic review of studies published in MEDLINE, EMBASE, Web of Science and Cumulative Index to Nursing and Allied Health literature (CINAHL) was conducted to assess the clinical outcomes of capitellum and trochlea fractures managed surgically. Data on patient demographics, surgical approach, implant usage, postoperative outcomes and complications were compiled.

**Results:** Forty-one studies met the inclusion criteria with a total of 700 patients. Surgical interventions primarily utilized either the lateral (79%) or antero-lateral (15%) approaches with headless compression screws as the most common fixation method (68%). Clinical outcomes were measured using the Mayo Elbow Performance Index (MEPI) with a mean score of 89.9 ( $\pm 2.6$ ) and the DASH score with a mean of 16.9 ( $\pm 7.3$ ). Elbow range of motion showed a mean flexion of 126.3° ( $\pm 19.4$ ), extension of 5.71° ( $\pm 11.8$ ), pronation of 75.23° ( $\pm 12.2$ ), and supination of 76.6° ( $\pm 9.8$ ). The mean flexion-extension arc was 113.7° ( $\pm 16.9$ ), and the mean pronation-supination arc was 165.31° ( $\pm 9.41$ ). Complications occurred in 19.8% of cases, with re-interventions required in 8.3% of cases, mainly due to symptomatic implants and elbow stiffness requiring surgical release. Other complications included implant removal (10.4%), overall reported stiff elbows (6%), nerve palsies (2%), non-union (1.5%), and infection (1.2%).

**Conclusion:** The treatment of capitellum and trochlea fractures yields satisfactory outcomes but has a considerable rate of complications and reoperations primarily due to symptomatic implants and elbow stiffness. There is noteworthy variability in the achieved range of motion, suggesting unpredictable outcomes. Deficits in functionality and range of motion are common after surgery, especially with more complex injury patterns.

**Keywords:** capitellum fractures, trochlea fractures, coronal shear fractures, outcomes, operative management, complications

## Introduction

Isolated capitellum and trochlear fractures, also referred to as coronal shear fractures of the distal humerus, although infrequent, carry substantial clinical importance. The critical role within the elbow joint was initially underscored by Morrey et al in 1985, who highlighted the intricate nature of these fractures and their potential for significant functional impairment.<sup>1</sup> In the ensuing years, several classifications have been proposed to help guide management. Two are frequently utilized in clinical practice and were established by Dubberley et al and Bryan and Morrey et al, with the latter being further modified by McKee et al to account for the presence of a trochlear fragment.<sup>2,3</sup> These classification systems have been instrumental in guiding treatment choices and prognostic considerations.

Recognizing the crucial role of articular congruence and early rehabilitation to improve outcomes, open reduction and internal fixation (ORIF) is widely considered the standard treatment modality.<sup>4</sup> However, the literature is abundant with

studies advocating for different techniques, implants, and approaches, creating a somewhat scattered landscape of data. Given the array of available techniques, the selection of the optimal approach remains controversial. Whether to opt for screw fixation, tension band wiring, or more contemporary methods involving plate fixation often depends on the surgeon's preference, influenced by their training and the available literature.

Despite advancements in surgical techniques and the variety of approaches and fixation methods available, the outcomes following these fractures remain variable. This inconsistency in outcomes is likely attributable to the inherent complexity of the elbow joint, the frequent postoperative stiffness, and the challenges associated with restoring articular congruence. In this systematic review, we aim to report on the overall operative interventions, their associated outcomes and complications linked with isolated capitellum and trochlea fractures.

## Methods

The search and selection process followed the Preferred Reporting Items for Systematic Reviews and Meta-Analyses (PRISMA) guidelines and was prospectively registered with PROSPERO (International Prospective Register of Systematic Reviews) (ID: CRD42022327859).

## Search Strategy

A systematic search of Medline, Embase, Web of Science and CINAHL (Cumulative Index to Nursing and Allied Health Literature) databases was performed using the following keywords: (Fractures) AND ((Capitellum) OR (capitellar) OR (Distal humerus) OR (Coronal Shear)). This strategy was undertaken to maximize the inclusion of all the potentially relevant articles with variation in terminology. Finally, reference lists of relevant articles were reviewed to identify additional articles that were potentially missed during the initial search.

## Eligibility Criteria

Studies that met the following criteria were included: 1) reporting outcomes of operatively treated capitellum or capitellar-trochlear fractures; 2) reporting outcomes of at least 5 patients and 3) patient age >18 years.

Studies were excluded if they met any of the following criteria: 1) review articles; 2) full text not available; 3) cadaveric or biomechanical studies; 4) studies that do not report the outcomes of patients with capitellum and/or trochlea fractures separately, if they included concomitant elbow injuries such as dislocations, extra-articular distal radius fractures, radial head fractures, coronoid fractures and olecranon fractures; 5) concomitant ipsilateral upper limb fractures.

## Study Screening

Titles and abstracts were independently screened for relevance by three authors using Covidence (Covidence systematic review software, Veritas Health Innovation, Melbourne, Australia. [www.covidence.org](http://www.covidence.org)). Potentially relevant articles underwent full-text screening, with any conflicts between the authors being resolved by discussion and consensus with the senior authors.

## Quality Assessment

Study quality assessment was conducted using the methodological index for non-randomized studies (MINORS) tool.<sup>5</sup> A score of 0, 1 or 2 is given for each of the 12 items on the MINORS checklist with a score of up to 16 for non-comparative studies and 24 for comparative studies. Methodological quality was categorized prior as follows: a score of 0–8 or 0–12 was considered poor quality, 9–12 or 13–18 was considered fair quality, and 13–16 or 19–24 was considered excellent quality, for non-comparative and comparative studies, respectively. For randomized controlled trials, the Cochrane risk of bias 2 (RoB-2) was used. Quality assessment was performed by two independent reviewers, with any conflicts between the authors being resolved by consensus with the senior authors.

## Data Extraction

Three authors independently extracted relevant data from the included studies to a previously piloted Microsoft Excel spreadsheet (Microsoft, Redmond, Washington, USA). These data included general article information (title, author, date of publication, journal, originating country and contact information), sample data and methodological information (study design, sample size, level of evidence, inclusion/exclusion criteria), patient demographic and surgical procedure details (age, gender, surgical approach, method of operative interventions), and relevant outcome measures (follow-up period, patient reported outcome scores, range of motion, complications and revision surgery). Scoring systems utilized included Disabilities of the Arm, Shoulder and Hand (DASH), quick DASH (Q-DASH) and the Mayo Elbow Performance index (MEPI).

## Data Analysis

Descriptive statistics including the mean, range and measures of variance (eg, standard deviations, 95% confidence intervals [CI]) were utilized where applicable. Data were synthesized into pooled demographics, treatment, and outcome measures. Due to the high heterogeneity of the interventions and included outcome measures, subgroup analysis was not possible. Measures of spread were calculated from each study if individual data were reported.

## Results

After the removal of duplicates from the initial search, a total of 6596 references were retrieved for title and abstract screening (Figure 1). A total of 6357 were excluded after the initial title/abstract screening. Next, 239 studies underwent full-text review. A total of 41 studies were included in the final analysis.

## Sample Data

The study designs and demographics of the pooled patients are detailed in Table 1. Apart from one randomized controlled trial comparing different surgical approaches, all studies were retrospective series and cohorts. A total of 700 patients were included with a female preponderance (57%). The mean age was 43.8 ( $\pm$  11.4) with a mean follow-up of 31 ( $\pm$ 20.2) months. The Dubberley and Bryan and Morrey classifications were the most commonly reported (Figures 2 and 3).

## Interventions

The surgical approach, types of implants used for fixation and screw configurations are displayed in Table 2. The most utilized approach was the lateral approach (L) (79%), followed by the antero-lateral (AL) (15%) and posterior approaches (5.5%). Variations of the lateral approach existed and were included in the table when they were reported in the studies. In a comparison of the AL and lateral approach, Yu et al reported comparable outcomes and shorter operative times in the AL approach.<sup>27</sup>

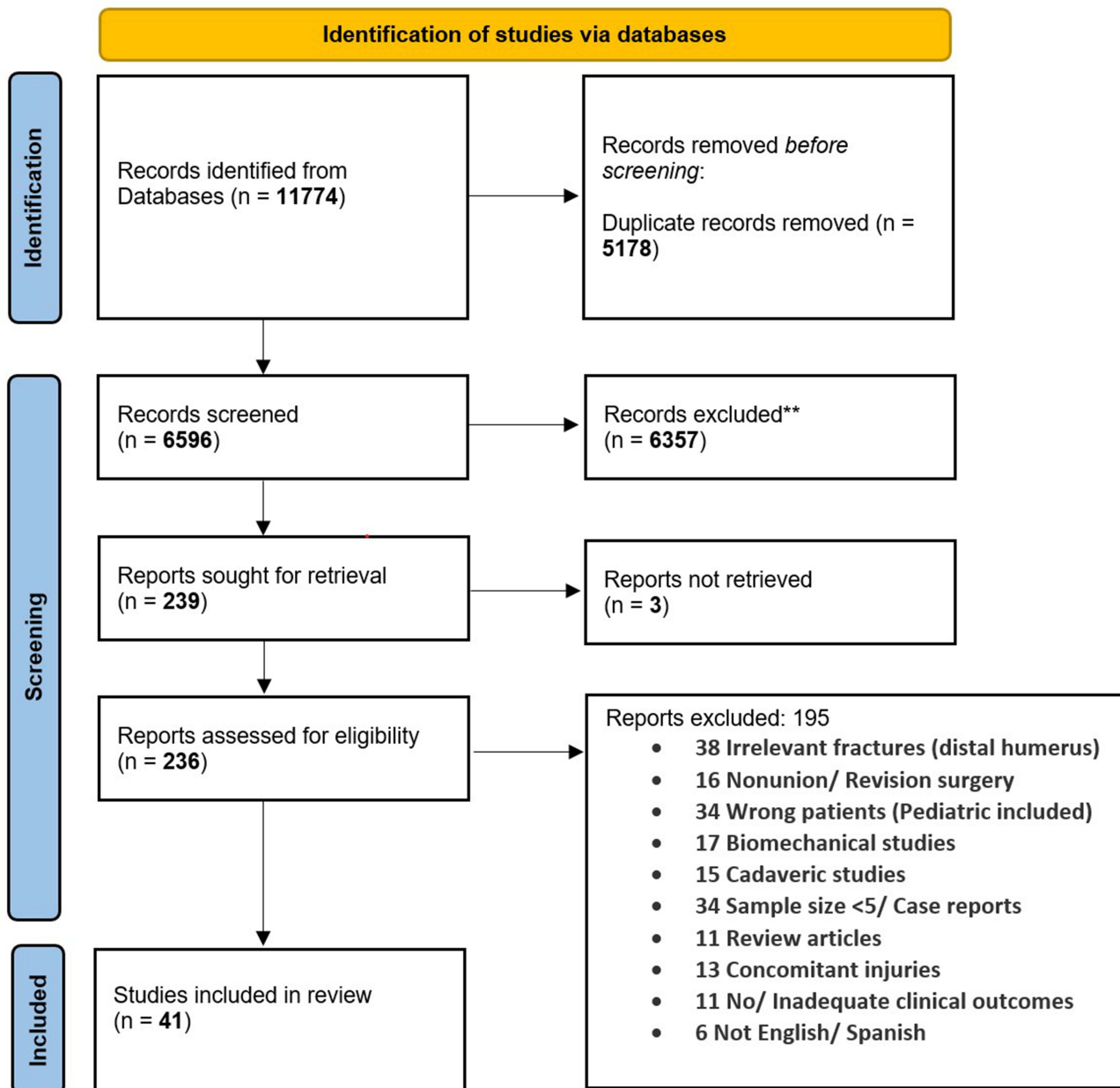
Headless compression screws were the preferred fixation method (68%). A combination of plates, screws and Kirschner wires (K-wires) was also common (19%). Plates alone were utilized in 7.5% of the patients, particularly when lateral and posterior wall comminution was present.<sup>21,23,27</sup> The most common screw trajectory was anterior to posterior (AP) in 79%, whereas posterior to anterior screws (PA) were used in 21%.

## Patient Reported Outcome Measures (PROMS)

The patient reported outcome measures are depicted in Table 3. The mean aggregate Mayo Elbow Performance Index (MEPI) score was 89.9 ( $\pm$  2.6) reported in 26 studies (n = 512). The mean aggregate DASH score was 16.9 ( $\pm$  7.3) reported in 5 studies (n = 74). Of note, Ravishankar et al reported worse MEPI outcome scores with Bryan and Morrey (BM) IV (76.3  $\pm$  16.1) compared to BM III (85.3  $\pm$  10.1).<sup>23</sup>

## Range of Motion (ROM)

The reported data on ROM in 37 studies is depicted in Table 3. The aggregate mean values for ROM in degrees included flexion 126.3° ( $\pm$ 19.4°) extension 5.7° ( $\pm$ 11.8°) pronation 75.2° ( $\pm$ 12.2°) and supination 76.6° ( $\pm$ 9.8°). The mean flexion-extension arc was 113.7° ( $\pm$ 13.9°), whereas the mean pronation-supination arc was 165.3° ( $\pm$ 9.4°).



**Figure 1** PRISMA flowchart depicting the process of study inclusion.

## Postoperative Protocol

The postoperative protocol varied between studies (Table 3). The majority of studies ( $n = 26$ ) utilized above elbow slabs for immobilization. The immobilization periods ranged from a few days up to 4 weeks. There was a trend towards shorter immobilization periods in more recent studies. Other postoperative protocols included hinged braces, removable static brace and postoperative arm slings. Physiotherapy was often started after splint removal, with some exceptions to immediate range of motion exercises being started postoperatively.

## Complications & Re-Interventions

The complications and re-interventions are summarized in Table 4. The total complication rate was 19.8% ( $n = 139$ ). The total re-intervention rate was 8.3% with the majority of these consisting of symptomatic implants that required removal. Other complications included; non-union (1.5%), infection (1.2%), stiffness (6%) and implant removal (10.4%). Nerve

**Table I** Patient Demographics and Characteristics

Study	Study type	MINORS	Sample Size Patients	Sex (N/ % Female)	Age: Mean (Range)	Follow Up Mean Months (Range)
Mosheiff 1991 <sup>6</sup>	Case series	4	5	4 (80%)	38 (20–70)	12.6 (9–18)
Hirvensalo 1993 <sup>7</sup>	Case series	5	8	8 (100%)	40 (17–68)	57 (NR)
McKee 1996 <sup>3</sup>	Cohort study	9	6	5 (83%)	38 (10–63)	22 (18–26)
Poynton 1998 <sup>8</sup>	Case control	9	12	10 (83%)	18 (12–40)	35 (NR)
Stamatis 2003 <sup>9</sup>	Case series	5	5	NR	NR (27–53)	NR (39–50)
Sano 2005 <sup>10</sup>	Cohort study	2	6	6 (100%)	51 (12–78)	6.6 (2.5–9.3)
Mahirogullari 2006 <sup>11</sup>	Case series	10	11	3 (27%)	27.5 (17–43)	23.4 (12–60)
Mighell 2010 <sup>12</sup>	Cohort	10	18	16 (84%)	45 (20–68)	25.5 (12–64)
Singh 2010 <sup>13</sup>	Case series	3	14	5 (35.7%)	33 (16–46)	57.6 (48–84)
Ashwood 2010 <sup>14</sup>	Case series	14	18	13 (50%)	44.8 (22–76)	47.72 (23–94)
Giannicola 2010 <sup>15</sup>	Case series	13	15	10 (66%)	47 (18–65)	29 (12–49)
Pavic 2012 <sup>16</sup>	Cohort	10	35	20 (57.1%)	38.6 (NR)	3 (NR)
Bilsel 2013 <sup>17</sup>	Case series	13	18	12 (67%)	45 (16–70)	44 (10–120)
Tarallo 2015 <sup>18</sup>	Case series	12	8	2 (25%)	50 (37–64)	30 (NR)
Lopiz 2016 <sup>19</sup>	Cohort	13	13	7 (53.8%)	70 (61–77)	48 (36–105)
Widhalm 2016 <sup>20</sup>	Cohort study	10	13	10 (76.9%)	48.7 (21–68)	118.5
Vaishya 2016 <sup>45</sup>	Case series	10	14	6 (37.5%)	32 (18–50)	27.6 (18–48)
Lu 2016 <sup>21</sup>	Case series	10	47	16 (34%)	56.4 (NR)	18.1 (12–24)
Sultan 2017 <sup>22</sup>	Cohort	9	13	10 (76.9%)	34.4 (20–48)	43.2 (18–72)
Ravishankar 2017 <sup>23</sup>	Cohort	10	30	11 (33.3%)	37.9 (12–70)	24.6 (12–47)
Tanwar 2018 <sup>24</sup>	Case series	10	10	7 (70%)	41 (18–60)	NR
Hussain 2018 <sup>25</sup>	Cohort	10	15	5 (33.3%)	27.4 (NR)	22.5 (6–43)
Yu 2018 <sup>26</sup>	Case series	9	15	9 (60%)	42 (19–64)	29 (24–36)
Yu 2019 <sup>27</sup>	RCT	*Some Concerns	26	15 (57.7%)	43	20.1
Wang 2019 <sup>28</sup>	Cohort	10	12	10 (83.3%)	43.6 (22–71)	32.5 (24–54)
Garg 2020 <sup>29</sup>	Case series	10	10	2 (20%)	29.3 (21–42)	13.8 (12–16)
Ballesteros-Betancourt 2020 <sup>30</sup>	Case series	4	8	4 (50%)	66 (53–76)	33 (24–60)
TanrÄ±verdi 2020 <sup>31</sup>	Case series	8	21	8 (38%)	39 (18–63)	45 (12–90)
Ali 2020 <sup>32</sup>	Cohort	5	12	4 (33.3%)	42 (15–75)	NR
Demir 2020 <sup>33</sup>	Case series	10	10	6 (60%)	43.8 (34–72)	59.6 (22–127)
Song 2020 <sup>34</sup>	Case series	12	52	35 (67.3%)	40.4 (23–62)	17.6 (12–24)

(Continued)

**Table I** (Continued).

Study	Study type	MINORS	Sample Size Patients	Sex (N/ % Female)	Age: Mean (Range)	Follow Up Mean Months (Range)
Teng 2020 <sup>35</sup>	Cohort	10	19	11 (58%)	44.6 (19–72)	18.1 (12–30)
Mukohara 2021 <sup>36</sup>	Case control	16	25	22 (88%)	57 (12–79)	15
Manav 2021 <sup>37</sup>	Case series	12	16	5 (31.25%)	38 (20–58)	36 (NR)
Almazouq 2021 <sup>38</sup>	Case series	11	12	9 (75%)	39.25 +- 10.48	8 (6–11)
Yoshida 2021 <sup>39</sup>	Cohort study	7	16	13 (81.2%)	49 (11–78)	23.5 (NR)
Tarallo 2021 <sup>40</sup>	Case series	10	24	NR	50.2 (18–71)	30 (24–40)
Bayam 2021 <sup>41</sup>	Case series	9	14	12 (85.7%)	56.6 (19–88)	34.5 (6–75)
Baydar 2022 <sup>42</sup>	Case series	12	21	12 (57.1%)	34.8 (16–62)	47.3 (6–63)
Tomori 2022 <sup>43</sup>	Cohort study	6	8	8 (100%)	76.3 (66–83)	23.6 (9–49)
Shergold 2022 <sup>44</sup>	Cohort study	12	45	31 (69%)	53 (19–86)	28 (12–93)
Aggregate			<b>Total: 700</b>	<b>Total: 402 (57.4%)</b>	<b>Mean: 43.8 SD: 11.4</b>	<b>Mean: 31.6 SD: 20.2</b>

**Abbreviations:** RCT, Randomized controlled trial; SD, Standard Deviation.

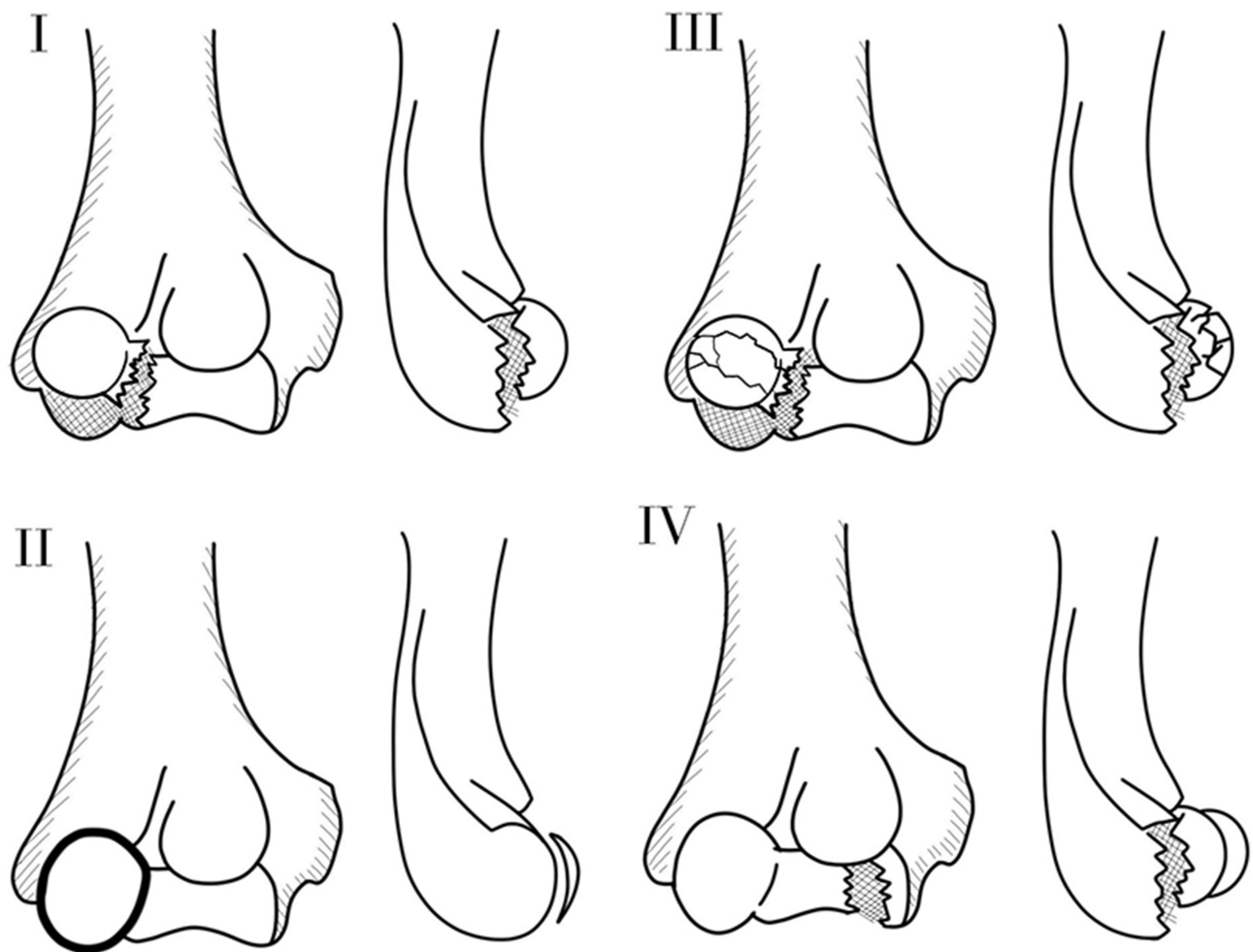
palsies were reported in 2% of the patient population, more commonly reported in the anterolateral approach.<sup>27,29,41</sup> There was poor reporting of osteoarthritis (OA) as a complication and whether or not these were symptomatic. Eighteen studies reported on OA radiographically detected. There were no details on long-term follow-up and symptoms due to OA. There was also poor reporting of re-interventions for release procedures following elbow stiffness.

## Discussion

Capitulum and trochlear fractures present unique management challenges due to the complexity of the elbow joint and the intricacies involved in restoring articular congruence while avoiding the risk of stiffness due to delayed rehabilitation. The findings from our review indicate that the current management strategies of this fracture yield acceptable, yet variable mid-long-term outcomes and are accompanied by a relatively high complication rate of (19.8%).

The surgical approaches adopted for these fractures encompassed variations of the lateral, anterolateral, and posterior approaches. The lateral approaches were utilized in almost 80% of the cases and are perhaps most useful for Bryan and Morrey types I–III in which visualization of the capitulum is sufficient to achieve reduction and perpendicular screw trajectories. It is important to note, however, that while the lateral approach allows for the potential repair of lateral collateral ligament (LCL) injuries, it also carries a risk of iatrogenic LCL damage. A thorough examination of stability should be performed to avoid neglecting an LCL injury, resulting in postoperative instability. Additionally, the lateral approach can be beneficial for cases with posterolateral wall comminution, providing direct access for visualization, PA screws and dorsolateral plates.<sup>23,28,36,39</sup>

Recently, the anterolateral approach has been gaining popularity in managing more medial trochlear fragments, specifically those of Bryan and Morrey type IV. This method offers direct visualization of both the capitulum and trochlea and facilitates a more perpendicular trajectory to the trochlea. It should be noted, though, that temporary nerve injuries were more prevalent in patients who underwent the anterolateral approach, attributable to the close proximity of the radial nerve during the procedure.<sup>20,24,38,45</sup> As such, identification of the radial nerve should be a priority and subsequently avoid rigorous retraction. While the anterolateral approach offers adequate medial and lateral fragment

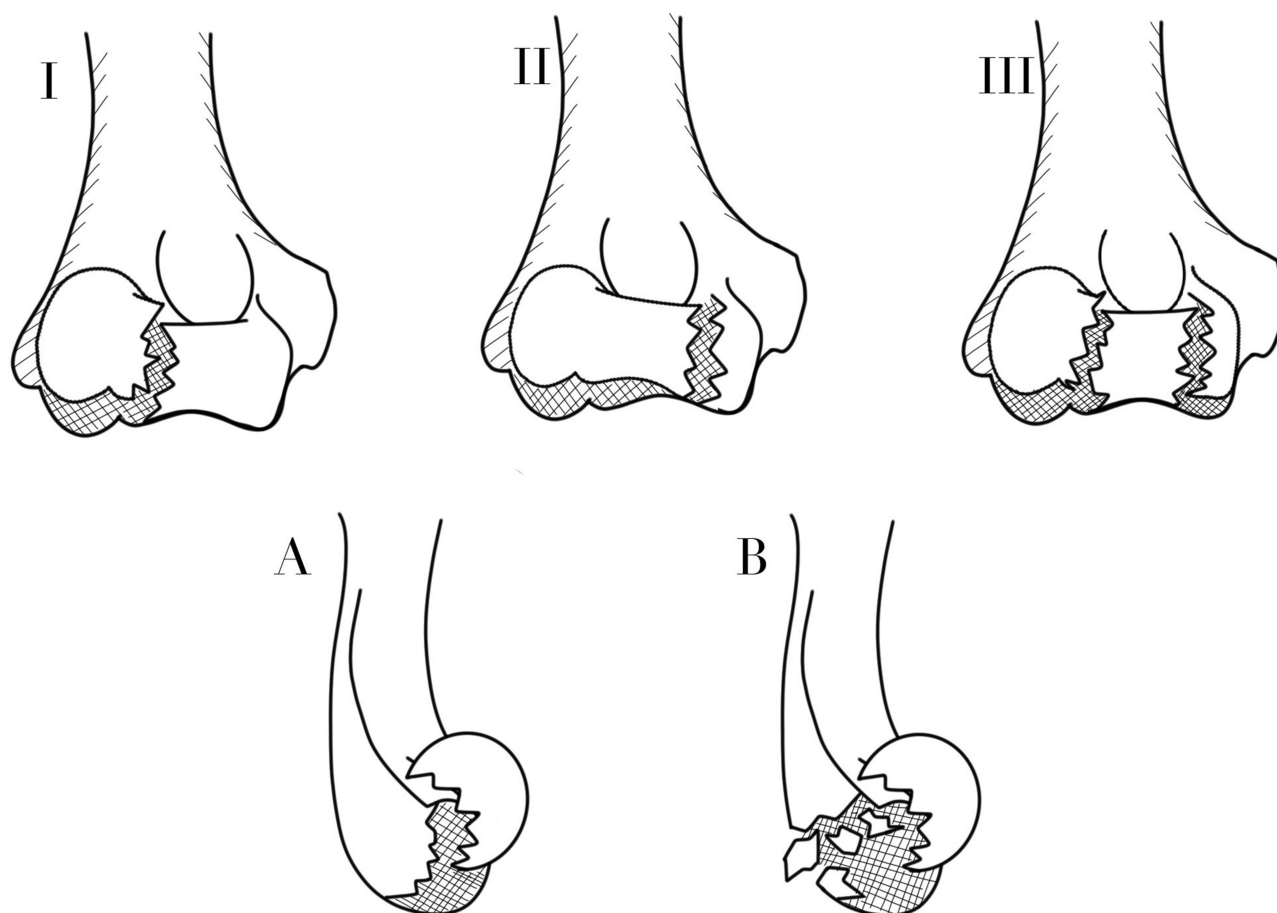


**Figure 2** Illustration of the Bryan and Morrey classification for capitellum fractures with the McKee modification. I: Large osseous capitellum piece, II: Shear fracture of the articular cartilage, III: Comminuted fracture of the capitellum, IV: McKee modification that includes a coronal shear of the capitellum and trochlea.

visualization, dual lateral and medial approaches have been utilized to address more medial fragments.<sup>31,35</sup> The use of arthroscopic-assisted fixation has recently been studied on cadavers with patient implementation in several case reports not included in this review. Although results seem promising, the application of the technique is still in its early stages.<sup>46</sup>

Headless compression screws remain the most utilized method of fixation (68%). Their popularity can be attributed to their ability to provide stable fixation while maintaining a low profile that minimally disrupts the articular surface. Further, combinations of plates, Kirschner wires and screws were also commonly utilized, particularly for lateral wall comminution when compression is not feasible or will lead to an improper fracture reduction. Headless screws must be adequately countersunk and not protrude through the articular cartilage. It is possible that with some degree of avascular necrosis or fracture collapse, the screws back out, resulting in impingement requiring implant removal.

The choice of screw direction was predominantly anterior to posterior (AP), employed in 79% of the cases, despite the theoretical risk of violating the articular cartilage. Comparatively, posterior to anterior (PA) screws were less frequently utilized. The inconsistent reporting of postoperative osteoarthritis (OA) makes it challenging to draw definitive conclusions on the comparative implications of AP versus PA screws. Nevertheless, there is currently no evidence to suggest that AP screws may lead to higher rates of OA, provided screws are appropriately countersunk to avoid intra-articular impingement. The advantages of AP screws are related with the ability to enhance the amounts of threads in the fractured-free fragment and better biomechanical stability.<sup>42</sup> The postoperative protocol often included some period of immobilization. Earlier studies appeared to use above elbow splints for longer periods of time.<sup>3,7,11</sup> More recent studies



**Figure 3** Illustration of the Dubberley classification for capitellar and trochlear fractures. Type I: fractures of the capitellum with/ without lateral trochlear ridge, type II: Fractures of the capitellum and trochlea as one piece, III: fractures of the capitellum and trochlea as separate fragments. In addition to (A) Without posterior wall comminution, (B) with posterior wall comminution.

have displayed a trend towards shorter periods of immobilization with a maximum time frame of 2 weeks.<sup>28,29,35,40,42</sup> In fractures amenable to rigid fixation, postoperative immobilization was not utilized, and earlier range of motion was allowed.<sup>16,41,44</sup>

When analyzing outcome scores, it is crucial to note that they reflect mild-to-moderate functional limitations, with more complex patterns such as in BM IV resulting in even more functional deficits. A discrepancy arises when studies group various fracture types together, possibly skewing results. Such a practice is not uncommon and may lead to a gap between expected recovery and the patient's actual experience. Many patients anticipate a complete return to their previous state, but instead, they often find themselves limited to just managing the basic activities of daily living. The variability in the range of motion across the studies is noteworthy, with a flexion-extension arc averaging  $113 \pm 13.9$  degrees. This variability suggests that a significant proportion of patients do not achieve a functional arc of motion post-surgery. Elbow stiffness appears to be a common problem based on these values, yet many of the included studies did not classify these cases as complications, and it is hard to determine how many of these patients avoid the surgical management of elbow stiffness and coped with their ROM deficits.

A high complication rate was observed across studies, with a cumulative incidence of 20%. Implant removal emerged as a frequent issue, accounting for 10% of complications, predominantly for symptomatic implants that had either migrated or become prominent. However, rates of non-union, infection, nerve palsies, and complex regional pain syndrome were low. The reporting of osteoarthritis across studies was inconsistent, precluding any sound conclusions about symptomatology, as no comparative analysis was made. Similarly, the clinical impact of avascular necrosis and heterotopic ossification remained unclear due to inconsistent reporting and lack of comparative data.



**Table 2** Summarizing Approaches, Implant Selection and Screw Trajectory

Study	Surgical Approach	Type of Fixation	Screw Configuration (AP/PA)
Mosheiff 1991 <sup>6</sup>	5 Lateral Approach (100%)	2 small fragment screws, 5 (100%)	5 PA
Hirvensalo 1993 <sup>7</sup>	8 Lateral Approach (100%)	Absorbable pins, 8 (100%)	NR
McKee 1996 <sup>3</sup>	6 Lateral approach (100%)	3 HCS, K-Wire 1 In situ, Plate 2	5 AP
Poynton 1998 <sup>8</sup>	NR	K-wires, 6 (50%), HCS, 6 (50%)	NR
Stamatis 2003 <sup>9</sup>	5 Lateral Kocher (100%)	4 HCS (80%), 1 Screw (20%)	2 PA 3 AP
Sano 2005 <sup>10</sup>	4 Kocher Lateral (67%), 2 Posterior (33%)	HCS, 6 (100%)	NR
Mahirogullari 2006 <sup>11</sup>	11 Lateral Kocher (100%)	HCS, 11 (100%)	11 PA
Mighell 2010 <sup>12</sup>	18 Lateral approach	2–3 HCS 18	18 AP
Singh 2010 <sup>13</sup>	14 Lateral Approach (100%)	2 HCS, 14 (100%)	14 PA
Ashwood 2010 <sup>14</sup>	Lateral 18, 100%	10 HCS (75.56%), 3 bioabsorbable rods (15.11%), 5 dorsal plate (10.6%)	NR
Giannicola 2010 <sup>15</sup>	Lateral Kocher, Posterior	11 HCS, 4 Lag + HCS	NR
Pavic 2012 <sup>16</sup>	34 Lateral	AO screws in 13, HCS 19, K-wires 10	AP / PA
Bilsel 2013 <sup>17</sup>	Lateral approach 16, Posterior approach 2	15 HCS, 3 Screws	15 AP 3 PA
Tarallo 2015 <sup>18</sup>	8 Kocher Lateral	8 HCS	8 AP
Lopiz 2016 <sup>19</sup>	10 Lateral approach	HCS (10)	11 AP / 9 PA
Widhalm 2016 <sup>20</sup>	Anterolateral (13)	15 Cannulated 3.5mm diameter screws	NR
Vaishya 2016 <sup>45</sup>	Anterolateral 16 (100%)	HCS 14 (100%)	NR
Lu 2016 <sup>21</sup>	Lateral Approach (100%)	47 Low profile Locking plate ± HCS ± K Wires in situ	AP
Sultan 2017 <sup>22</sup>	Extensile Lateral (100%)	10 HCS, 1 K-wires	AP 13 (93.3%)
Ravishankar 2017 <sup>23</sup>	Lateral 22, Posterior 6, Anterolateral 5	All 30 HCS, Plate with lateral condyle comminution (NR)	AP
Tanwar 2018 <sup>24</sup>	10 Anterolateral (100%)	10 (100%) HCS	AP
Hussain 2018 <sup>25</sup>	15 Lateral Kocher (100%)	15 HCS	13 PA
Yu 2018 <sup>26</sup>	15 Anterolateral (100%)	15 (100%) HCS	15 AP

(Continued)

Table 2 (Continued).

Study	Surgical Approach	Type of Fixation	Screw Configuration (AP/PA)
Yu 2019 <sup>27</sup>	14 Lateral (53.8%), 12 Anterolateral (46.1%)	26 (100%) HCS	26 AP
Wang 2019 <sup>28</sup>	Kocher extended Lateral (100%)	12 Dorsolateral Plate (80%), 3 Dorsolateral Plate + 3 HCS (20%)	PA (100%)
Garg 2020 <sup>29</sup>	Anterolateral 10 (100%)	10 HCS (100%)	AP
Ballesteros-Betancourt 2020 <sup>30</sup>	Anterior limited approach	8 HCS	AP
TanrÄ±verdi 2020 <sup>31</sup>	Lateral (16) Posterior (2) Lateral & medial (3)	21 HCS	AP / PA
Ali 2020 <sup>32</sup>	Anterolateral approach	12 HCS	AP
Demir 2020 <sup>33</sup>	Kocher approach	10 K-wires + HCS +Buttress plate	NR
Song 2020 <sup>34</sup>	Lateral approach	52 K-wires + Plate + HCS	AP
Teng 2020 <sup>35</sup>	Kocher (11), Posterior (2), Medial (6)	19 HCS / K-wire	NR
Mukohara 2021 <sup>36</sup>	3 Posterior + lateral, 12 lateral, 9 Posterior	HCS (25), LCP (6)	NR
Manav 2021 <sup>37</sup>	Lateral approach	5 K-Wires, 6 Cancellous screws, 5 HCS	NR
Almazouq 2021 <sup>38</sup>	Anterolateral	12 HCS	AP
Yoshida 2021 <sup>39</sup>	Lateral (12) anterolateral (2) Med-Lat (2)	10 HCS, 5 Locking plate for lateral condyle, 1 HCS + tension band	AP
Tarallo 2021 <sup>40</sup>	Lateral Kocher	24 HCS	PA
Bayam 2021 <sup>41</sup>	Anterolateral (5) Lateral (9)	14 HCS	13 AP IPA
Baydar 2022 <sup>42</sup>	Lateral	21 HCS	AP and PA
Tomori 2022 <sup>43</sup>	(5) Lateral (1) Anterolateral (2) Posterior	4 HCS +- LCP +- K-Wires in situ, 1 bioabsorbable pin, 2 lateral plates	NR
Shergold 2022 <sup>44</sup>	Lateral (25) Para-olecranon (13), Posterior (6)	HCS (13), LCP (22) +- Screws	AP (12) PA (1)
Aggregate	Total Lateral 457 Total Anterolateral 86 Total Posterior 32	1- <b>Screws</b> 478 (68.29%) 2- <b>Plates</b> 52 (7.43%) 3- <b>K-wires</b> 24 (3.43%) 4- <b>Combinations</b> 137 (19.57%) 5- <b>Others:</b> 11 (1.5%)	Total AP Trajectory N. 297 (79%) Total PA Trajectory N. 76 (21%)

**Abbreviations:** AP, Anteroposterior; PA, Postero-anterior; HCS, Headless compression screw; K-wire, Kirschner wires; NR, Not reported.

**Table 3** A Summary of Functional Outcomes, Union Time, and Range of Motion for the Included Studies

Study	Union Time Mean SD Weeks	PROMs (Mean SD)		Range of Motion (Mean SD)				Postoperative Protocol
		Outcome 1	Outcome 2	Flexion	Extension	Pronation	Supination	
Mosheiff 1991 <sup>6</sup>	NR	NR		45	180	NR	NR	NR
Hirvensalo 1993 <sup>7</sup>	NR	NR		NR				AES for 3 weeks. PT at 3 weeks
McKee 1996 <sup>3</sup>	NR	NR		F 141	30	P 83	S 84.1	Brace 4–6 weeks. + Immediate PT
Poynton 1998 <sup>8</sup>	NR	NR		NR				AES 2 weeks
Stamatis 2003 <sup>9</sup>	9	MEPI: 99		NR				NR
Sano 2005 <sup>10</sup>	NR	Grantham scoring system		F 139.2 ± 2.04	7.5 ± 9.87	NR	NR	AES 1–4 weeks + PT
Mahirogullari 2006 <sup>11</sup>	6 (4–8)	MEPI 93.6 ± 7.77		F-E Arc: 117		P-S Arc: 151		AES 4 weeks
Mighell 2010 <sup>12</sup>	By 1 year	BM 93.3 (57–100)	ASES 83.1 (21.3–100)	F-E Arc: 128° (83–155)		P-S Arc 176° (120–180)		AES 5–7 days PT at 4 weeks
Singh 2010 <sup>13</sup>	NR	NR		F: 132° (128–135)	7.5 0–20)			AES 4–6 days PT day 6
Ashwood 2010 <sup>14</sup>	NR	MEPI 90.28 (70–100)		F/CLS: 128.8/144	E/CLS: 4.1/0.9	P/CLS: 52.7/63.9	S/CLS 56.2/69.0	AES 2 weeks PT at 2 weeks
Giannicola 2010 <sup>15</sup>	NR	MEPI 98 (75–100)		F: 140 (110°-150°)	13 (0°-40°)	50	50	PT at day 2
Pavic 2012 <sup>16</sup>	NR	NR		F: 130 E: 5	5	90	90	No splint PT after 24 hours
Bilsel 2013 <sup>17</sup>	NR	MEPI 86.7 ± 15.2	DASH 15.3 ± 13.5	F: 132.8 ± (10)	8.9 ± 9.9	NR	NR	AES 1–2 weeks
Tarallo 2015 <sup>18</sup>	12 (6–16)	MEPI 92 ± 7.33		F: 125 ± 11.99	20.62 ± 8.82	67.5 ± 3.54	74.38 ± 4.64	AES 7 days PT + dynamic splint
Lopez 2016 <sup>19</sup>	NR	MEPI 92.7 ± 12.08 (60–100)	DASH 9.8 (0–75) ± (20.4)	F: 122 (100–135) ± 9.09	–8.5 (–30-0) ± 7.9	NR	NR	Splint average of 10 days – PT at 6 weeks
Widhalm 2016 <sup>20</sup>	NR	MEPI 92.7 ± 17.5:	ASES 37.8±27.3	F: 138.8°±7.6°	4.9°±10.4°	88.8°±4.0°	85.8°±7.3°	NR
Vaishya 2016 <sup>45</sup>	3.5m (2.5–5)	MEPI (10) excellent (6) Good		F 132 (110–135)	10 (0–25)	NR	NR	AES 1 week PT day 7

(Continued)

Table 3 (Continued).

Study	Union Time Mean SD Weeks	PROMs (Mean SD)		Range of Motion (Mean SD)				Postoperative Protocol
		Outcome 1	Outcome 2	Flexion	Extension	Pronation	Supination	
Lu 2016 <sup>21</sup>	11.4 (8–12)	<b>MEPI</b> 87.6 (60–100)		<b>F</b> 118 (90–130)	6 (0–10)	NR	NR	Brace 2–3 days PT day 2–4
Sultan 2017 <sup>22</sup>	12 (8–16)	<b>MEPI</b> : 92.3: ± 7.51		<b>F-E</b> 124.2° ± 11.4				AES 1 week
Ravishankar 2017 <sup>23</sup>	10.9 ± 3.2	<b>MEPI</b> 80.9 ± 13.9 BM I–III 85.3 ± 10.1 BM IV 76.3 ± 16.1		<b>Total</b> : F-E 132 (± 8°) P-S 151 (± 6.7°). <b>BM I–III</b> : F-E 135.5 (± 5.6°) P-S 154 (± 5.2) <b>B&amp;M IV</b> : F-E 129.3 (± 8.7) P-S 147.8 (± 6.8)				AES 2 weeks PT at 2 weeks
Tanwar 2018 <sup>24</sup>	10 (8–12)	<b>DASH</b> 24 ± 21.8		<b>F</b> 126.5	10.5	NR	NR	Sling 2 weeks
Hussain 2018 <sup>25</sup>	8.93	<b>MEPI</b> : 77.89		<b>F-E</b> 125 (90–145°) /		<b>P-S Arc</b> 170		AES 3 weeks
Yu 2018 <sup>26</sup>	NR	<b>MEPI</b> 93: ± 8 (75–100)		<b>F-E Arc</b> 134 (± 10°)		<b>P-S Arc</b> : 172 (± 11°)		AES 2 weeks
Yu 2019 <sup>27</sup>	NR	<b>MEPI</b> : Lateral 91.5 ± 8 Anterolateral 92 ± 7		<b>F-E Arc</b> 134		<b>P-S Arc</b> 169		AES 2 weeks
Wang 2019 <sup>28</sup>	NR	<b>MEPI</b> 89.1 ± 7.3	<b>DASH</b> 10.3 ± 3.9	<b>F</b> 123.3 (± 8.87)	11.25 (± 7.1)	80.8 (± 5.96)	77.9 (± 4.9)	AES 1 weeks + PT at 1 week
Garg 2020 <sup>29</sup>	NR	<b>MEPI</b> 96 ± 4		<b>F-E Arc</b> 136 (± 10)		<b>P-S Arc</b> 173 (± 11)		AES 5 days + PT
Ballesteros-Betancourt 2020 <sup>30</sup>	NR	NR		<b>F</b> 138	9	84	78	AES 2 weeks + PT
Tanrıverdi 2020 <sup>31</sup>	NR	<b>MEPI</b> 81.9 ± 13.7	<b>DASH</b> 25.1 ± 13.7 (4 to 57)	<b>F-E Arc</b> 102° (65° to 140°)		<b>P-S Arc</b> 165° (130° to 180°)		AES 4 weeks + PT
Ali 2020 <sup>32</sup>	NR	<b>MEPI</b> 93 ± 5.3		<b>F-E</b> 5 Deficit		<b>P-S</b> 8 Deficit		AES 2 weeks + PT
Demir 2020 <sup>33</sup>	NR	<b>MEPI</b> 95.5 ± 5.98		<b>F</b> 137.5°: ± 3 <b>F-E Arc</b> 119.6 ± 9.3	17.9°: ± 9.2	72.2° ± 2.6 <b>P-S Arc</b> 151.1 ± 5.4	78.9° ± 4.09	Brace 3 weeks + PT
Song 2020 <sup>34</sup>	NR	<b>MEPI</b> 90.6 (60–100)		<b>F</b> 136° (90–150)	3 (0–13)	NR	NR	Brace 2 weeks + PT
Teng 2020 <sup>35</sup>	8.8 wk	<b>MEPI</b> : 85.79 ± 8.54		<b>F-E arc</b> : 130.5 ± 10.5		<b>P-S Arc</b> 167.4 ± 6.1		Brace + PT day 2 postop
Mukohara 2021 <sup>36</sup>	NR	<b>MEPI</b> 96.3 (70–100)		<b>F</b> 130 (100–145) / <b>F-E Arc</b> 120.2 (80–45)	–10 (5–30)	NR	NR	AES 3–28 days PT at 6 weeks
Manav 2021 <sup>37</sup>	10.6	<b>MEPI</b> 87		<b>F-E Arc</b> 125° (115–135°)		<b>P-S Arc</b> : 170 (120–180)		AES/ Hinged Brace

Almazouq 2021 <sup>38</sup>	9.83 +- 1.9 wk	<b>MEPI</b> Excellent 66.7% Good 25% Satisfactory 8.3%	<b>F-E Arc</b> 118.8 (95 to 140)		<b>NR</b>	<b>NR</b>	NR
Yoshida 2021 <sup>39</sup>	NR	<b>MEPI</b> 83.8 (60–100)	NR				NR
Tarallo 2021 <sup>40</sup>	NR	<b>MEPI:</b> 92.1	<b>F-E Arc</b> 113.1°. 1A (123.7°); 1B (111.6°) 2A (115°); 2B (120°); 3A (110°); 3B (100°)		<b>NR</b>		AES 1 weeks + PT at 2 weeks
Bayam 2021 <sup>41</sup>	NR	<b>MEPI</b> Excellent = 7 pts Good = 3 pts Fair = 1pt	57% (14 pts) full flexion 140 or more, 1 pt had 10 degrees extension deformity				Splint based on fracture morphology
Baydar 2022 <sup>42</sup>	NR	<b>Broberg-Murray</b> 92.7 (77–100)	114 ± 15	6.6 ± 7	81.6 ± 7	78.8 ± 5	AES 1 week
Tomori 2022 <sup>43</sup>	NR	<b>MEPI</b> 78.8 ± 10.2 (70–100)	116.3 ± 12.7 (95–130)	-28.8 ± 14. (-50 to 0)	NR	NR	AES 2 weeks + PT
Shergold 2022 <sup>44</sup>	NR	<b>OES</b> 43 range (16–48)	125 (70–140)	10 (0–50)	NR	NR	No Splint – Immediate PT
Aggregate	<b>Mean: 13 Weeks</b>	<b>MEPI MEAN 89.90 ± 2.57 (26 studies)</b> <b>DASH Mean 16.9 ± 7.32 (5 studies)</b>	126.3 ± 19.43	5.71 ± 11.82	75.23 ± 12.2	76.6 ± 9.78	
			Mean ARC F/E 113.71 ± 13.9 –		Mean ARC P/S: 165.31 ± 9.41		

**Table 4** Complications, Problems and Re-Interventions Across the Included Studies

Study	Complications Overall N / %	Non union N / %	Infection N / %	Stiffness N / %	AVN N / %	Neuropathy N / %	Other N / %	Implant Removal N / %	Re-Interventions-
Mosheiff 1991 <sup>6</sup>	2 (40%)	0	0	0	0	0	0	2	2 Articular screws
Hirvensalo 1993 <sup>7</sup>	None	0	0	0	0	0	(2) OA	0	0
McKee 1996 <sup>3</sup>	1 (16%)	0	0	0	0	0	(1) OA	0	0
Poynton 1998 <sup>8</sup>	2 (16.6%)	0	1 (100%)	0	0	0	(1) OA	0	0
Stamatis 2003 <sup>9</sup>	2 (40%)	0	0	0	1 (20%)	0	(1) OA	0	0
Sano 2005 <sup>10</sup>	0	0	0	0	0	0	0	0	0
Mahirogullari 2006 <sup>11</sup>	0	0	0	0	0	0	0	0	0
Mighell 2010 <sup>12</sup>	2 (11.1%)	NR	1 Sup. abscess	1	3	0	(5) OA	0	0
Singh 2010 <sup>13</sup>	0	0	0	0	0	0	0	0	0
Ashwood 2010 <sup>14</sup>	8 (57%)	0	0	0	0	2 (7.5%)	2 (7.5%) CRPS	6	6 - Release & IR
Giannicola 2010 <sup>15</sup>	5 (35.7%)	1 (6.6%)	1 (6.6%) Sup.	2	0	1 RNP	3 OA	2	2 IR - Symptomatic
Pavic 2012 <sup>16</sup>	3 (8.5%)	0	0	3	0	0	0	0	0
Bilsel 2013 <sup>17</sup>	1 (5%)	0	0	1 (5%)	0	0	1 (5%) HO	0	0
Tarallo 2015 <sup>18</sup>	3 (37.5%)	0	0	1	0	0	1 HO, 1 LCL, 1 CRPS	0	1 LCL Repair - Instability
Lopiz 2016 <sup>19</sup>	11 (47.83%)	1 (4.3%)	NR	3 (15%)	1 (5%)	0	5 (25%)	1 (4.3%)	1 Revision implant failure
Widhalm 2016 <sup>20</sup>	4 (30.8%)	0	0	0	0	0	0	4 (30.8%)	3 IR - reduced ROM, 1 IR - Screw loosening
Vaishya 2016 <sup>45</sup>	2 (12%)	0	0	1 (Keloid)	0	PIN Palsy 1 (6.25%)	0	0	0
Lu 2016 <sup>21</sup>	3 (6.3%)	0	0	0	0	0	0	3 (6.3%)	(3) Symptomatic implant
Sultan 2017 <sup>22</sup>	2 (15%)	0	0	1 (6.6%)	0	0	1 (6.6%) OA	2 (15%)	2 IR Screw in olecranon fossa
Ravishankar 2017 <sup>23</sup>	13 (39.3%)	3 (9%) Delayed	2 (6%) superficial	8 FFD (24%)	2 (6%) AVN	0	1 HO (3%) 1 OA	0	Pt overlap explains total number

Tanwar 2018 <sup>24</sup>	2 (20%)	0	0	0	0	0	2 (20%) 1 HO 1 OA	0	0
Hussain 2018 <sup>25</sup>	4 (26.6%)	0	0	0	0	0	(4) HO (26.6%) (2) OA	0	0
Yu 2018 <sup>26</sup>	1 (6.6%)	0	0	0	0	1 RNP	0	0	0
Yu 2019 <sup>27</sup>	1 (3.8%)	0	0	0	0	1 PIN palsy in AL group	0	0	0
Wang 2019 <sup>28</sup>	3 (20%)	0	1	0	1	0	1 HO	1	1 IR for Infection
Garg 2020 <sup>29</sup>	1 (10%)	0	0	0	0	1 PIN Palsy	0	0	0
Ballesteros- Betancourt 2020 <sup>30</sup>	1 (12.5)	0	0	0	0	0	1 CRPS	0	0
TanrÄ±verdi 2020 <sup>31</sup>	4 (19.04%)	0	0	0	3	0	1	0	0
Ali 2020 <sup>32</sup>	2 (16.6%)	0	0	0	1	0	1 OA	0	0
Demir 2020 <sup>33</sup>	5 (50%)	0	0	0	2 AVN	0	2 OA	2 Non routine	(1) Resection capitellum and lateral release (1) Symptomatic implant
Song 2020 <sup>34</sup>	7 (13%)	0	0	2	0	0	3 OA	(17)	5 – IR, Symptomatic implant
Teng 2020 <sup>35</sup>	4 (21%)	0	0	0	0	0	3 OA / 1 HO	10 (52%)	0
Mukohara 2021 <sup>36</sup>	12 (48%)	1 (4%)	0	11 (44%)	0	0	0	11 (44%)	11 (44%) - Release & IR
Manav 2021 <sup>37</sup>	0	0	0	0	0	0	0	0	0
Almazouq 2021 <sup>38</sup>	0	0	0	0	0	0	0	0	0
Yoshida 2021 <sup>39</sup>	1 (6.25%)	0	0	1 (6.25%)	5 AVN	0	0	1 (6.25%)	1 Implant loosening
Tarallo 2021 <sup>40</sup>	4 (17%)	0	0	1	0	0	1 CRPS	1	1 – K-wire migration, 1 – Release, 1 - LCL revision
Bayam 2021 <sup>41</sup>	4 (28%)	0	0	1 FFD	0	1 RNP	0	2	1 Revision implant failure 1 screw removal (prominent)

(Continued)

**Table 4** (Continued).

Study	Complications Overall N / %	Non union N / %	Infection N / %	Stiffness N / %	AVN N / %	Neuropathy N / %	Other N / %	Implant Removal N / %	Re-Interventions-
Baydar 2022 <sup>42</sup>	2 (9%)	0	1	1 (FFD)	0	0	2 OA	0	1 Release
Tomori 2022 <sup>43</sup>	7 (87.5%)	1 collapse	0	4	2	0	0	3 non-routine	3 IR symptomatic implant
Shergold 2022 <sup>44</sup>	10 (27%)	4 (10%)	1 Deep infection	0	0	4 UN. paresthesia	0	5 non-routine	3 Release 2 Revision 2 UN decompression 1 Debridement (x3)
Aggregate	Total 139, 19.8%	Total N 11, 1.5%	Total N 8, 1%	Total N 42, 6%	Total N 21, 3%	Total N 14, 2%	Total N 51 7.3%	Total N 73 10.4%	Total 58 8.3%

**Abbreviations:** IR, implant removal; LCL, lateral collateral ligament; PIN, posterior interosseous nerve; AL, antero-lateral; CRPS, complex regional pain syndrome; UN, ulnar nerve; RNP, radial nerve palsy; FFD, fixed flexion deformity; Sup, superficial; HO, heterotopic ossification; OA, osteoarthritis.



## Limitations

This review is inherently limited by the predominance of retrospective studies, which typically represent a lower level of evidence. Moreover, many of the included studies did not distinguish outcomes and complications based on fracture patterns and classifications. It is reasonable to think that the different patterns and fracture subtypes will be associated with varied outcomes and have distinct challenges. Another potential factor overlooked in most studies is the time from injury to surgery, particularly relevant for fractures initially missed due to the difficulty of detection in plain radiographs. The true rate of complications may also be underestimated. If we redefine stiffness as a complication, specifically as an inability to achieve functional range of motion, the actual complication rate in our review would markedly increase. This issue extends beyond statistical representations, as it bears significant implications for clinical practice, especially when establishing realistic post-surgical expectations.<sup>47</sup>

## Conclusion

The treatment of capitellum and trochlea fractures yields acceptable outcomes with a relatively high rate of complications and reoperations primarily for symptomatic implants and elbow contracture release surgery. There is noteworthy variability in the achieved range of motion, suggesting unpredictable outcomes. Deficits in functionality and range of motion are common after surgery, especially with more complex injury patterns.

## Provenance and Peer Review

Not commissioned, externally peer-reviewed.

## Data Sharing Statement

Data will not be publicly available.

## Author Contributions

All authors made a significant contribution to the work reported, whether that is in the conception, study design, execution, acquisition of data, analysis and interpretation, or in all these areas; took part in drafting, revising or critically reviewing the article; gave final approval of the version to be published; have agreed on the journal to which the article has been submitted; and agree to be accountable for all aspects of the work.

## Disclosure

The authors report no conflicts of interest in this work.

---

## References

1. Bryan RS, Morrey BF. Fractures of the distal humerus. In: Morrey BF, editor. *The Elbow and Its Disorders*. 2nd ed. Philadelphia: WB Saunders; 1985:302–339.
2. Dubberley JH, Faber KJ, Macdermid JC, Patterson SD, King GJ. Outcome after open reduction and internal fixation of capitellar and trochlear fractures. *J Bone Joint Surg Am*. 2006;88(1):46–54. doi:10.2106/JBJS.D.02954
3. McKee MD, Jupiter JB, Bamberger HB. Coronal shear fractures of the distal end of the humerus. *J Bone Joint Surg Am*. 1996;78(1):49–54. doi:10.2106/00004623-199601000-00007
4. Ring D, Jupiter JB, Gulotta L. Articular fractures of the distal part of the humerus. *J Bone Joint Surg Am*. 2003;85(2):232–238. doi:10.2106/00004623-200302000-00008
5. Slim K, Nini E, Forestier D, Kwiatkowski F, Panis Y, Chipponi J. Methodological index for non-randomized studies (minors): development and validation of a new instrument. *ANZ J Surg*. 2003;73(9):712–716. doi:10.1046/j.1445-2197.2003.02748.x
6. Mosheiff R, Liebergall M, Elyashuv O, Mattan Y, Segal D. Surgical treatment of fractures of the capitellum in adults: a modified technique. *J of Orthop Trauma*. 1991;5(3):297–300. doi:10.1097/00005131-199109000-00007
7. Hirvensalo E, Böstman O, Partio E, Törmälä P, Rokkanen P. Fracture of the humeral capitellum fixed with absorbable polyglycolide pins. *Acta Orthop Scand*. 1993;64(1):85–86. doi:10.3109/17453679308994538
8. Poynton AR, Kelly IP, O'Rourke SK. Fractures of the capitellum—a comparison of two fixation methods. *Injury*. 1998;29(5):341–343. doi:10.1016/S0020-1383(97)00107-1
9. Stamatis E, Paxinos O. The treatment and functional outcome of type IV coronal shear fractures of the distal humerus: a retrospective review of five cases. *J of Orthop Trauma*. 2003;17(4):279–284. doi:10.1097/00005131-200304000-00006

10. Sano S, Rokkaku T, Saito S, Tokunaga S, Abe Y, Moriya H. Herbert screw fixation of capitellar fractures. *J Shoulder Elbow Surg.* 2005;14(3):307–311. doi:10.1016/j.jse.2004.09.005
11. Mahirogullari M, Kiral A, Solakoglu C, Pehlivan O, Akmaz I, Rodop O. Treatment of fractures of the humeral capitellum using Herbert screws. *J Hand Surg.* 2006;31(3):320–325. doi:10.1016/J.JHSB.2006.02.002
12. Mighell M, Virani NA, Shannon R, Echols EL Jr, Badman BL, Keating CJ. Large coronal shear fractures of the capitellum and trochlea treated with headless compression screws. *J Shoulder Elbow Surg.* 2010;19(1):38–45. doi:10.1016/j.jse.2009.05.012
13. Singh AP, Singh AP, Vaishya R, Jain A, Gulati D. Fractures of capitellum: a review of 14 cases treated by open reduction and internal fixation with Herbert screws. *Int Orthop.* 2010;34(6):897–901. PMID: 19894049; PMCID: PMC2989024. doi:10.1007/s00264-009-0896-9.
14. Ashwood N, Verma M, Hamlet M, Garlapati A, Fogg Q. Transarticular shear fractures of the distal humerus. *J Shoulder Elbow Surg.* 2010;19(1):46–52. PMID: 19884023. doi:10.1016/j.jse.2009.07.061.
15. Giannicola G, Sacchetti FM, Greco A, Gregori G, Postacchini F. Open reduction and internal fixation combined with hinged elbow fixator in capitellum and trochlea fractures. *Acta Orthop.* 2010;81(2):228–233. doi:10.3109/17453671003685475.
16. Pavić R, Malović M. Isolated capitellum humeri fractures in adults. *Coll Antropol.* 2012;36(1):187–194.
17. Bilsel K, Atalar AC, Erdil M, Elmadağ M, Sen C, Demirhan M. Coronal plane fractures of the distal humerus involving the capitellum and trochlea treated with open reduction internal fixation. *Arch Orthop Trauma Surg.* 2013;133(6):797–804. doi:10.1007/s00402-013-1718-5
18. Tarallo L, Mugnai R, Adani R, Zambianchi F, Costanzini CA, Catani F. Shear fractures of the distal humerus: is the use of intra-articular screws a safe treatment? *Musculoskelet Surg.* 2015;99(3):217–223. doi:10.1007/s12306-015-0386-8
19. Lopiz Y, Rodriguez-Gonzalez A, Garcia-Fernandez C, Marco F. Open reduction and internal fixation of coronal fractures of the capitellum in patients older than 65 years. *J Shoulder Elbow Surg.* 2016;25(3):369–375. doi:10.1016/j.jse.2015.12.004
20. Widhalm HK, Seemann R, Wagner FT, et al. Clinical outcome and osteoarthritic changes after surgical treatment of isolated capitulum humeri fractures with a minimum follow-up of five years. *Int Orthop.* 2016;40(12):2603–2610. doi:10.1007/s00264-016-3165-8
21. Lu Y, Wang Q, Hu B, et al. Surgical techniques and clinical efficacy of micro locking plate in the treatment of capitellar fractures. *Int J Clin Exp Med.* 2016;9(8):16061–16069.
22. Sultan A, Khurshed U, Bhat MR, Kotwal HA, Manzoor QW. Management of capitellar fractures with open reduction and internal fixation using Herbert screws. *Unus Trauma Acil Cerrahi Derg.* 2017;23(6):507–514. doi:10.5505/tjtes.2017.57142
23. Ravishankar MR, Kumar MN, Raut R. Choice of surgical approach for capitellar fractures based on pathoanatomy of fractures: outcomes of surgical management. *Eur J Orthop Surg Traumatol.* 2017;27(2):233–242. doi:10.1007/s00590-016-1877-5
24. Tanwar YS, Kharbanda Y, Jaiswal A, Birla V, Pandit R. Retrospective analysis of open reduction and internal fixation of coronal plane fractures of the capitellum and trochlea using the anterolateral approach. *SICOT J.* 2018;4:8. doi:10.1051/sicotj/2017063
25. Hussain S, Ali A, Tahir Yusuf M, Irfan Siddique RM. Humeral capitellar fractures fixation with Herbert screws. *Pakistan J Med Health Sci.* 2018;12:792–795.
26. Yu T, Tao H, Xu F, Hu Y, Zhang C, Zhou G. Management of isolated coronal shear fractures of the humeral capitellum with Herbert screw fixation through anterolateral approach. *BMC Musculoskelet Disord.* 2018;19(1):108. doi:10.1186/s12891-018-2024-8
27. Yu T, Tao H, Xu F, Hu Y, Zhang C, Zhou G. Comparison of lateral approach versus anterolateral approach with Herbert screw fixation for isolated coronal shear fractures of humeral capitellum. *J Orthop Surg Res.* 2019;14(1):230. doi:10.1186/s13018-019-1261-3
28. Wang P, Kandemir U, Zhang K, et al. Treatment of capitellar and trochlear fractures with posterior comminution: minimum 2-year follow-up. *J Shoulder Elbow Surg.* 2019;28(5):931–938. doi:10.1016/j.jse.2018.09.004
29. Garg S, Sain A, Sharma V, Farooque K, Rangaswamy N. Functional outcome of a coronal shear fracture of the capitellum managed by Herbert screw fixation using the anterolateral surgical approach. *Cureus.* 2020;12:e6578.
30. Ballesteros-Betancourt JR, Garcia-Tarrino R, Garcia-Elvira R, et al. The anterior limited approach of the elbow for the treatment of capitellum and trochlea fractures: surgical technique and clinical experience in eight cases. *Injury.* 2020;51(Suppl 1):S103–S111. doi:10.1016/j.injury.2020.02.008
31. Tanriverdi B, Kural C, Altun S. Capitellum fractures: treatment with headless screws and outcomes. *Jt Dis Relat Surg.* 2020;31(2):291–297. doi:10.5606/ehc.2020.72821
32. Maratib Ali, Siddiqui Irfan, Khaskheli, Javed et al. Management of Isolated Coronal Shear Humeral Capitellum Fracture - Fixation with Herbert Screws. *Pakistan Journal of Medical & Health Sciences.* 2020;09;14(3):. doi:
33. Demir MT, Ertan Birsel S, Salih M, Pirincci Y, Birsel O, Kesmezacar H. Outcome after the surgical treatment of the Dubberley type B distal humeral capitellar and trochlear fractures with a buttress plate. *Acta Orthop Traumatol Turc.* 2020;54(4):364–371. doi:10.5152/j.aott.2020.20092
34. Song Z, Wang Q, T. M, et al. Anti-sliding plate technique for coronal shear fractures of the distal humerus. *J Orthop Surg Res.* 2020;15(1):18. doi:10.1186/s13018-019-1466-5
35. Teng L, Zhong G. Surgical treatment of comminuted coronal shear fracture of distal humerus. *Orthop Surg.* 2020;12(5):1439–1447. doi:10.1111/os.12765
36. Mukohara S, Mifune Y, Inui A, et al. Effects of trochlear fragmentation on functional outcome in coronal shear fractures: a retrospective comparative study. *JSES Int.* 2021;5(3):571–577. doi:10.1016/j.jseint.2020.12.011
37. Manav A. Treatment of Type I and Type IV capitellar fractures by open reduction & internal fixation – a series of 16 cases. *Int J Pharm Clin Res.* 2021;13(3):363–367.
38. Almazouq AMA, Mohammed MO, Salem AAEA, El-Malt AES. Open reduction and internal fixation of capitellar fracture through anterolateral approach with headless double-threaded compression screws. *Eur J Mol Clin Med.* 2021;8(3):4097–4105.
39. Yoshida S, Sakai K, Nakama K, et al. Treatment of capitellum and trochlea fractures using headless compression screws and a combination of dorsolateral locking plates. *Cureus.* 2021;13:e13740.
40. Tarallo L, Novi M, Porcellini G, Giorgini A, Micheloni G, Catani F. Surgical tips and tricks for coronal shear fractures of the elbow. *Arch Orthop Trauma Surg.* 2021;141(2):261–270. doi:10.1007/s00402-020-03500-9
41. Bayam L. ‘A review of outcomes following surgical fixation of adult capitellum fractures: a six-year case series’. *Acta Orthop Belg.* 2020;86(3):8–13.
42. Baydar M, Aykut S, Mert M, Keskinbiçki MV, Akdeniz HE, Öztürk K. Isolated capitellar fracture fixation with headless screws in different configurations. *Acta Ortop Bras.* 2022;30(1):e244357. doi:10.1590/1413-785220223001e244357
43. Tomori Y, Nanno M, Sonoki K, Majima T. Surgical outcomes of coronal shear fracture of the distal humerus in elderly adults. *J Nippon Med Sch.* 2022;89(1):81–87. doi:10.1272/jnms.JNMS.2022\_89-202

44. Shergold S, Derias M, Moverley R, Murphy RJ, Guryel E, Phadnis J. Coronal shear fractures of the distal humerus managed according to the modified dubberley classification system. *J Shoulder Elbow Surg.* 2022;31(1):133–142. doi:10.1016/j.jse.2021.07.002
45. Vaishya R, Vijay V, Jha GK, Agarwal AK. Open reduction and internal fixation of capitellar fracture through anterolateral approach with headless double-threaded compression screws: a series of 16 patients. *J Shoulder Elbow Surg.* 2016;25(7):1182–1188. doi:10.1016/j.jse.2016.01.034
46. Fink Barnes LA, Parsons BO, Hausman M. Arthroscopic management of elbow fractures. *Hand Clin.* 2015;31(4):651–661. doi:10.1016/j.hcl.2015.06.011
47. Lari A, Alherz M, Jarragh A. Dissociating advances in orthopaedic trauma management from the climbing patient expectations. *Eur J Trauma Emerg Surg.* 2022;48(2):1487. doi:10.1007/s00068-021-01705-0

### Orthopedic Research and Reviews

Dovepress

### Publish your work in this journal

Orthopedic Research and Reviews is an international, peer-reviewed, open access journal that focusing on the patho-physiology of the musculoskeletal system, trauma, surgery and other corrective interventions to restore mobility and function. Advances in new technologies, materials, techniques and pharmacological agents are particularly welcome. The manuscript management system is completely online and includes a very quick and fair peer-review system, which is all easy to use. Visit <http://www.dovepress.com/testimonials.php> to read real quotes from published authors.

Submit your manuscript here: <https://www.dovepress.com/orthopedic-research-and-reviews-journal>