

# Early laparotomy and timely reconstruction for patients with abdominal electrical injury

## Five Case Reports and Literature Review

Pi-Hong Zhang, MD, PhD<sup>a</sup>, Zan Liu, MD<sup>a</sup>, Li-Cheng Ren, MD<sup>a</sup>, Ji-Zhang Zeng, MD<sup>a</sup>, Geng-Wen Huang, MD<sup>b</sup>, Mu-Zhang Xiao, MD<sup>a</sup>, Jie Zhou, MD<sup>a</sup>, Peng-Fei Liang, MD<sup>a</sup>, Ming-Hua Zhang, MD<sup>a,\*</sup>, Xiao-Yuan Huang, MD, PhD<sup>c,\*</sup>

### Abstract

**Introduction:** High-tension electricity can cause devastating injuries that may result in abdominal wall loss, visceral damage, and sometimes major threat to life. The visceral organ may be exposed after debridement and require flap cover, but the tensile strength of abdominal wall may be lack even if flap transplanted.

**Methods:** From April 2007 through May 2015, 5 patients with severe abdominal electrical injury were treated at our hospital. Exploratory laparotomy was performed based on their clinical manifestations and debridement findings of abdominal wall at early stage, and decision regarding technique for reconstruction of abdominal wall was based on an assessment of the location and extent of the defect. Medical records were reviewed for these data.

**Results:** Clinical evaluation and debridement findings of the abdomen revealed 4 patients with suspicious visceral damage. Laparotomy was performed in 4 cases, and revealed obvious lesion in 3 cases, including segmental necrosis of small intestine, partial necrosis of diaphragm, left liver and gastric wall, and greater omentum. Five patients underwent abdominal wall reconstruction using island retrograde latissimus dorsi myocutaneous flap or free/island composite anterolateral thigh myocutaneous flap. All flaps survived, abdominal bulging occurred in 3 cases after follow-up of 12 to 36 months.

**Conclusions:** The clinical manifestations and wound features of abdomen collectively suggest a possible requirement of laparotomy for severe abdominal electrical burns. Retrograde latissimus dorsi myocutaneous flap or composite anterolateral thigh myocutaneous flap is an effective option for reconstruction of abdominal wall loss, the long-term complication of abdominal bulging, however, remains a significant clinical challenge.

**Abbreviations:** ALT = anterolateral thigh, LD = latissimus dorsi, TFL = tensor fasciae latae.

**Keywords:** abdominal-wall defect, electrical injury, exploratory laparotomy, flap, reconstruction

## 1. Introduction

Electrical injuries on abdominal wall are uncommon, but associated with high mortality, especially delayed gastrointestinal perforation and peritonitis complicated after the visceral organ injury.<sup>[1,2]</sup> The prognosis of visceral organ injury is related to

early diagnosis and proper management, despite early recognition of the visceral damage is quite difficult.<sup>[3]</sup> Exploratory laparotomy can find ischemic or necrotic tissue, perforate hollow organ, and other damage, but sometimes no obvious lesion can be found after laparotomy,<sup>[4]</sup> the indication of exploratory laparotomy is still deserved to be investigated.

The basic principle of electrical burns, especially visceral organ exposed after debridement, is to repair the defect with a vascularized flap.<sup>[5-7]</sup> A series of free or pedicled anterolateral thigh (ALT) and/or tensor fasciae latae (TFL) flaps can be chosen for abdominal wall reconstruction depending on the size and location of the defect and the length of the vascular pedicle.<sup>[8-17]</sup> The benefits of flap cover in the acute stage are early wound coverage, preservation of vital viscera and digestive function, reduced invasive infection, and hospital stay.<sup>[18]</sup> But the tensile strength of abdominal wall may be lack even if flap transplanted, a flap with strong, vascularized fascia and/or innervated muscle can enhance the tensile strength of abdominal wall to avoid abdominal hernia formation.<sup>[3,10,15,19-20]</sup> Therefore, the reconstruction of large defects on the abdominal wall after electrical injury can be challenging. The purpose of this article is to retrospectively analyze the characteristics of abdominal electrical injury with visceral damage and to evaluate the outcome of early flap repair of large defects on the abdominal wall after electrical burns.

Editor: Goran Augustin.

M-hZ and X-yH contributed equally to the work and should be considered as cocorresponding authors.

The authors declare no conflicts of interest.

<sup>a</sup> Department of Burns and Reconstructive Surgery, <sup>b</sup> Department of General Surgery, <sup>c</sup> Institute of Burn Research, Xiangya Hospital, Central South University, Changsha, Hunan Province, P.R. China.

\* Correspondence: Ming-Hua Zhang, Department of Burns and Reconstructive Surgery, Xiangya Hospital, Central South University, Changsha, 410008 Hunan Province, P.R. China (e-mail: 13974829635@163.com); Xiao-Yuan Huang, Institute of Burn Research, Xiangya Hospital, Central South University, Changsha, 410008 Hunan Province, P.R. China (e-mail: huxzhongxy@163.com).

Copyright © 2017 the Author(s). Published by Wolters Kluwer Health, Inc. This is an open access article distributed under the Creative Commons Attribution License 4.0 (CCBY), which permits unrestricted use, distribution, and reproduction in any medium, provided the original work is properly cited.

Medicine (2017) 96:29(e7437)

Received: 20 January 2017 / Received in final form: 13 June 2017 / Accepted: 15 June 2017

<http://dx.doi.org/10.1097/MD.0000000000007437>

## 2. Patients and methods

### 2.1. Data of patients and consent

Five patients suffering from a high-voltage electrical injury to extensive abdominal wall were treated at our academic hospital from April 2007 to May 2015. All of the patients were male with an average age of 46 years (range, 35–54 years). The induced voltage of these patients was 1000 to 100,000 V and they were evaluated on admission between 16 and 24 hours (mean 19 hours) after burn injury. None of the patients had any chronic illnesses, such as diabetes or cardiovascular insufficiency, nor did they have cardiogenic or hypovolemic shock symptoms or experience other major trauma, such as an intracranial injury or a bone fracture. The majority of patients' limbs were injured or even damaged, and the calculated total burned body surface area of these patients ranged from 3% to 19% (mean 11.0%). The size of abdominal wall wound ranged from 360 to 700 cm<sup>2</sup> (mean 494.4 cm<sup>2</sup>). After admitted, meticulous symptom inquiry and detailed physical examination, if needed, serial accessory examination such as abdominocentesis, KUB, ultrasonographic examination, and so on were performed. Besides, 4000 to 6000 mL fluid was administrated for fluid replacement to maintain a clear hourly urine output to 50 to 75 mL/h.

Consents to conduct and report of this study were obtained from the Ethics Committee of Xiangya Hospital, Central South University. Written informed consent for publication of this case report and any accompanying images was obtained from the patient.

### 2.2. Debridement and laparotomy

Debridement was performed within 1 to 3 days after injured. Eschar and obvious devitalized muscle or other tissues were removed, the appearance of viable abdominal muscle, posterior rectus sheath, or peritoneum were noted and left as much as

possible during debridement. All patients were debrided for one time. According to the clinical manifestations mentioned above and debridement findings at early stage, laparotomy operations were performed for those under suspicion with internal organs injury. During laparotomy intestinal resection and anastomosis, or resection of necrotic tissues (eg, greater omentum and gastric, etc) and repair of visceral organ were performed, and the peritoneal cavity was closed with peritoneum or greater omentum.

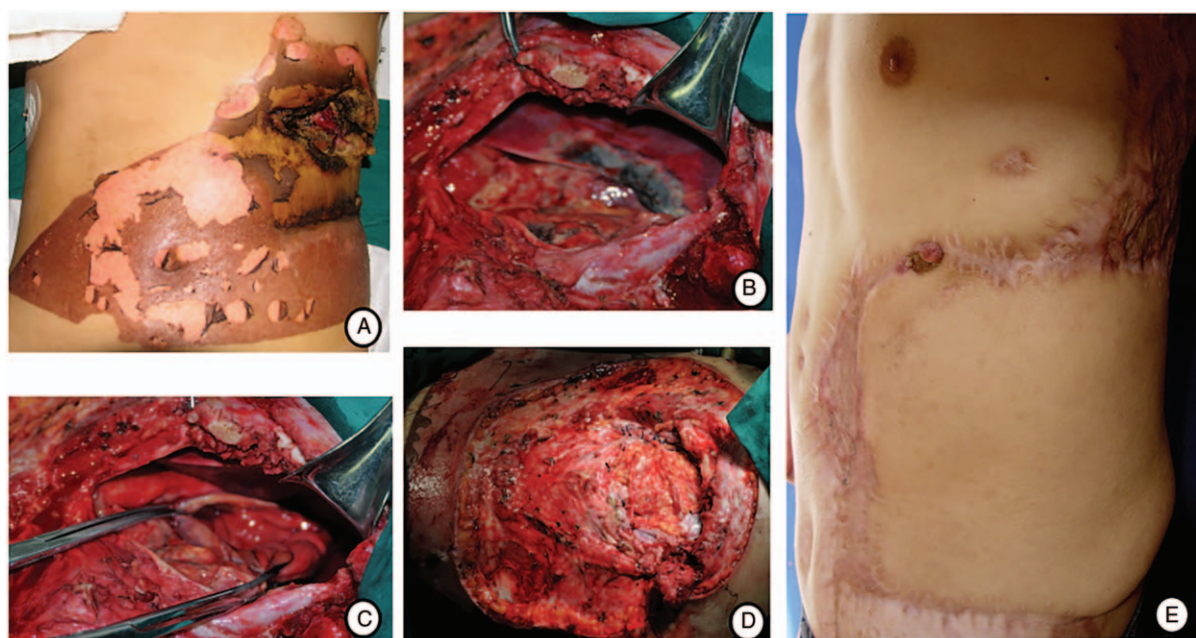
### 2.3. Flap transplantation and follow-up

After debridement and laparotomy, one-stage reconstruction followed. The defect of abdominal wall was repaired with island retrograde latissimus dorsi (LD) musculocutaneous flap, free, or island composite ALT musculocutaneous flap. The selection of flap for abdominal wall reconstruction was determined by the location and size of the defect. During harvest of the former perfused by lumbar artery and perforator intercostal vessels, a major perforator from the 10th intercostal vessels was secured. When harvesting of the latter perfused by the lateral circumflex system of femoral vessels, vastus lateralis, or rectus femoris and the femoral nerve of these muscle were carried if necessary. The deep inferior epigastric vessels were used as the recipients for end-to-end anastomoses during free-flap transplantation. To strengthen the abdominal wall, the carried vastus lateralis or rectus femoris was sutured with remnant rim of abdominal muscles including the remaining rectus abdominis using numerous strong prolene sutures, the fusion of fascia lata was fixed to the external oblique aponeurosis under suitable tension, and the femoral nerve of vastus lateralis muscle was coapted with the intercostal nerve when free transplanted. The immediate and long-term outcomes were assessed regarding the complications and sustainable strength of the abdominal wall. The patient characteristics are shown in Table 1.

**Table 1**

**Characteristics of 5 patients with electrical injury on abdomen.**

	Case 1	Case 2	Case 3	Case 4	Case 5
Sex/Age, y	M/42	M/54	M/47	M/54	M/35
Voltage, V	1000	100000	30000	100000	10000
Admission time postburn, h	24	20	18	19	16
Symptom					
Abdominal pain	No	No	Yes	No	Yes
Abdominal distention	No	No	Yes	No	Yes
Sign					
Tenderness	No	No	Yes	No	Yes
Rebound tenderness	No	No	No	No	No
Bowl sounds	Normal	Normal	Hypoactive	Hypoactive	Hypoactive
Abdominal wound					
Location	Left upper	Upper	Middle and lower	Middle and upper	Midline
Area, cm <sup>2</sup>	360 (18 × 20)	432 (18 × 24)	500 (20 × 25)	700 (25 × 30)	480 (16 × 25)
Depth	Muscle necrosis	Muscle necrosis	Muscle necrosis	Gut exposure	Muscle necrosis
Diagnostic examination					
Abdominocentesis	Normal	Not done	Clear yellowish fluid	Not done	Not done
KUB	Normal	Normal	Not done	Not done	Not done
B-us	Not done	Normal	Mild ascites	Not done	Normal
Diagnosis	3% (III°)	10% (III°)	19% (III°)	5% Gut exposure	18% (III°)
Internal organs injury	Suspicious	None	Suspicious	Suspicious	Suspicious
Time of 1st operation	3rd day	3rd day	2nd day	1st day	1st day
Repair methods	Retrograde LD	Free ALT	Island ALT	Bilateral free ALT	Island ALT
Immediate complication	None	None	None	None	None
Follow-up period, mon	12	32	36	35	15
Results of follow-up	Suture granuloma	Normal	Bulging and sagging	Bulging and sagging	Bulging



**Figure 1.** A, High-voltage electrical injury on the left upper quadrant of abdomen and lumbar region; (B–C) Necrosis of the diaphragm and anterior gastric wall was showed after laparotomy; (D) Abdominal wound before flap transplantation. E, Twelve months after repair with retrograde LD musculocutaneous flap, a suture granuloma was seen on the surgical incision.

### 3. Case presentation

#### 3.1. Case 1

On physical examination, an abdominal and lumbar burn wound of about 20 cm × 15 cm was detected, and we found a direct deep wound to the liver and stomach surface through the necrotic wound of the left 9th and 10th ribs, a 2 cm × 3 cm area of necrosis of the diaphragm, marginal necrosis of left liver and a necrotic pitting in the anterior wall of stomach with no obvious perforation during debridement. After resection and repair of injured diaphragm and gastric wall, we used retrograde LD musculocutaneous flap to cover the defect (Fig. 1).

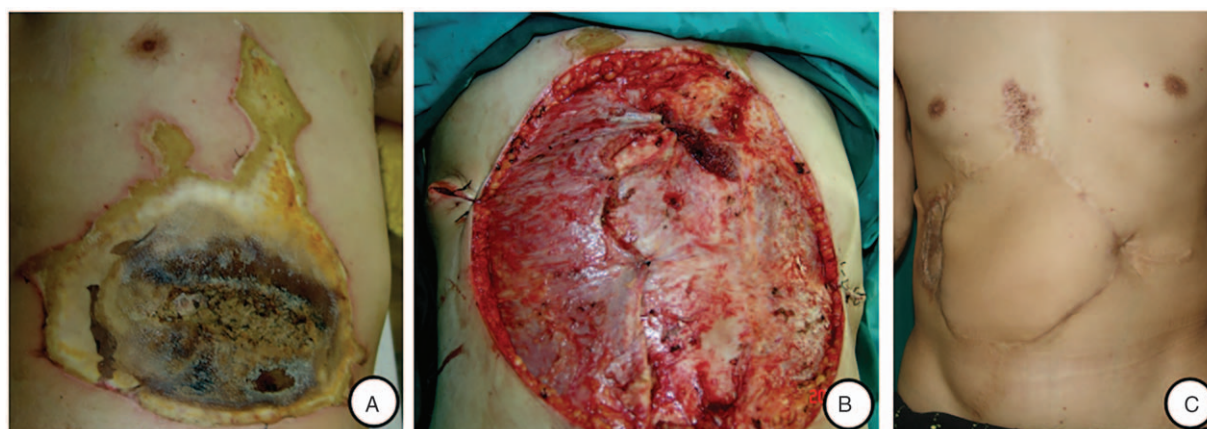
#### 3.2. Case 2

During the abdominal debridement of case 2, bilateral rectus abdominis necrosis was revealed, but posterior rectus sheath and

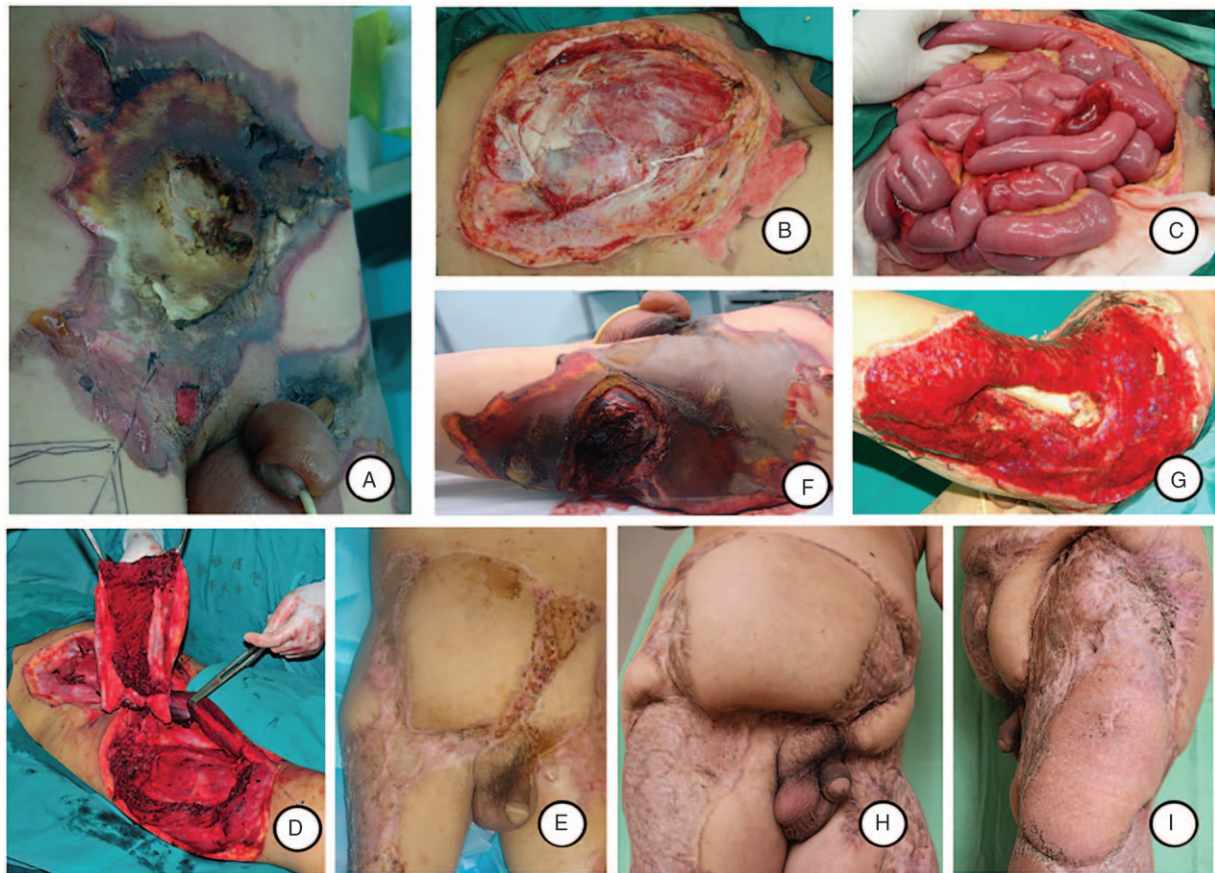
peritoneum however remained intact. To prevent secondary necrosis of the wound tissue, skin graft failure and hernia formation, free composite ALT flap with vastus lateralis was used to close the abdominal wall defect, the femoral nerve of vastus lateralis muscle was coapted with the intercostal nerve (Fig. 2).

#### 3.3. Case 3

In case 3, we found wide devitalized abdominal muscles with intact posterior sheaths of bilateral rectus abdominis and peritoneum after the emergency abdominal debridement. Laparotomy was still performed considering his positive abdominal signs and symptoms, and abdominal ascites confirmed by abdominal sonography and abdominocentesis before debridement. In spite of the peritoneal completeness, laparotomy revealed that 7 burn lesions in the range of 1.2 to 2.2 m below Treitz ligament were involved, 4 of which (1.2, 1.5, 2.1, and 2.2



**Figure 2.** A, Full-thickness injury of the abdominal wall after injury; (B) abdominal defect after debridement; and (C) 32 months after the reconstruction of the abdominal wall defect with free composite ALT musculocutaneous flap and split-thickness skin graft.



**Figure 3.** A, Abdominal lesions 18 hours after injury; (B) abdominal defect after debridement; (C) segmental intestinal devitalization during laparotomy; (D) harvest of island composite ALT musculocutaneous flap; (E) one and a half months after the flap has healed, the abdominal wall was stable; (F) wound on the left thigh and hip; (G) femur exposed after serial debridement and negative pressure wound therapy; (H-I) 36 months after the reconstruction of the abdominal wall and left thigh defect with island composite ALT musculocutaneous flap and free LD musculocutaneous flap.

m, respectively) presented with pitting and contracture of the intestine, and edema was noted in the remaining three sites. After the repair of the 3 edematous lesions, the necrotic intestines were resected and followed by enteroanastomosis. Right island composite ALT musculocutaneous flap was designed to close the abdominal defect. The abdominal wall was strengthened by suturing up the vastus lateralis with the rectus abdominis, and the fusion of fascia lata with the external oblique aponeurosis. The residual defects were covered by split-thickness skin grafts. On day 8 in hospital, the patient underwent amputation of the left forearm and the right arm, and debridement of the left thigh. On day 26 in hospital, free LD musculocutaneous flap was designed to cover the defect with bone exposure in the left thigh. Thirty-six months after repair, the reconstructed abdominal wall was bulging without herniation of intraperitoneal organs (Fig. 3).

#### 3.4. Case 4

To case 4, an emergency exploratory laparotomy was done owing to gut exposure after abdominal debridement. Although posterior sheath and peritoneum were necrotized, almost normal except partial greater omentum necrosis was found. Bilateral free composite ALT flap with a cuff of vastus lateralis was used to repair the defect of abdominal wall after necrotic omentum was resected. 35 months after repair, the reconstructed abdominal

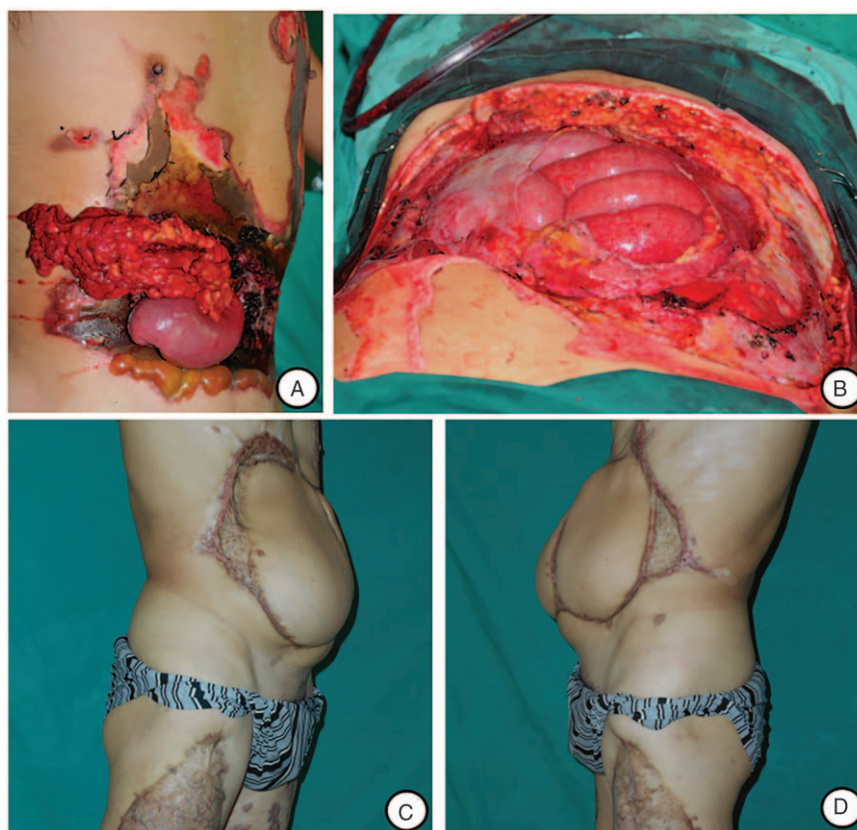
wall was bulging without herniation of intraperitoneal organs (Fig. 4).

#### 3.5. Case 5

We found wide devitalized abdominal muscles with intact posterior sheaths of bilateral rectus abdominis and peritoneum after the emergency abdominal debridement and only flatulence after laparotomy. A giant composite ALT flap with innervated rectus femoris was transplanted to cover the abdominal wall after manual exhaust and decompression. (Fig. 5)

## 4. Results

Exploratory laparotomy was performed in 4 cases, and revealed small pieces of necrosis on the diaphragm, left liver and the anterior wall of stomach in 1 case, segmental necrosis of small intestine in 1 case, partial greater omentum necrosis in 1 case, and no obvious lesion except large intestine distension in 1 case. All patients underwent abdominal wall reconstruction using retrograde LD musculocutaneous flap or composite ALT musculocutaneous flap, pedicled in 3 cases and free in 2 cases. Complete flap survival was achieved without partial necrosis or thrombosis. The contraction forces of quadriceps femoris muscle was mildly reduced in case 2, 3, and 5; clinical evaluation of the abdomen revealed 2 patients without anomalies, 3 cases of abdominal



**Figure 4.** A, Abdominal wound and gut exposure after injury; (B) abdominal defect after debridement; (C–D) 35 months after the reconstruction of the abdominal wall defect with bilateral free composite ALT flap.

bulging and sagging without functional discomfort but needing to wear an abdominal lap belt in 2 cases, and 1 case of suture granuloma.

## 5. Discussion

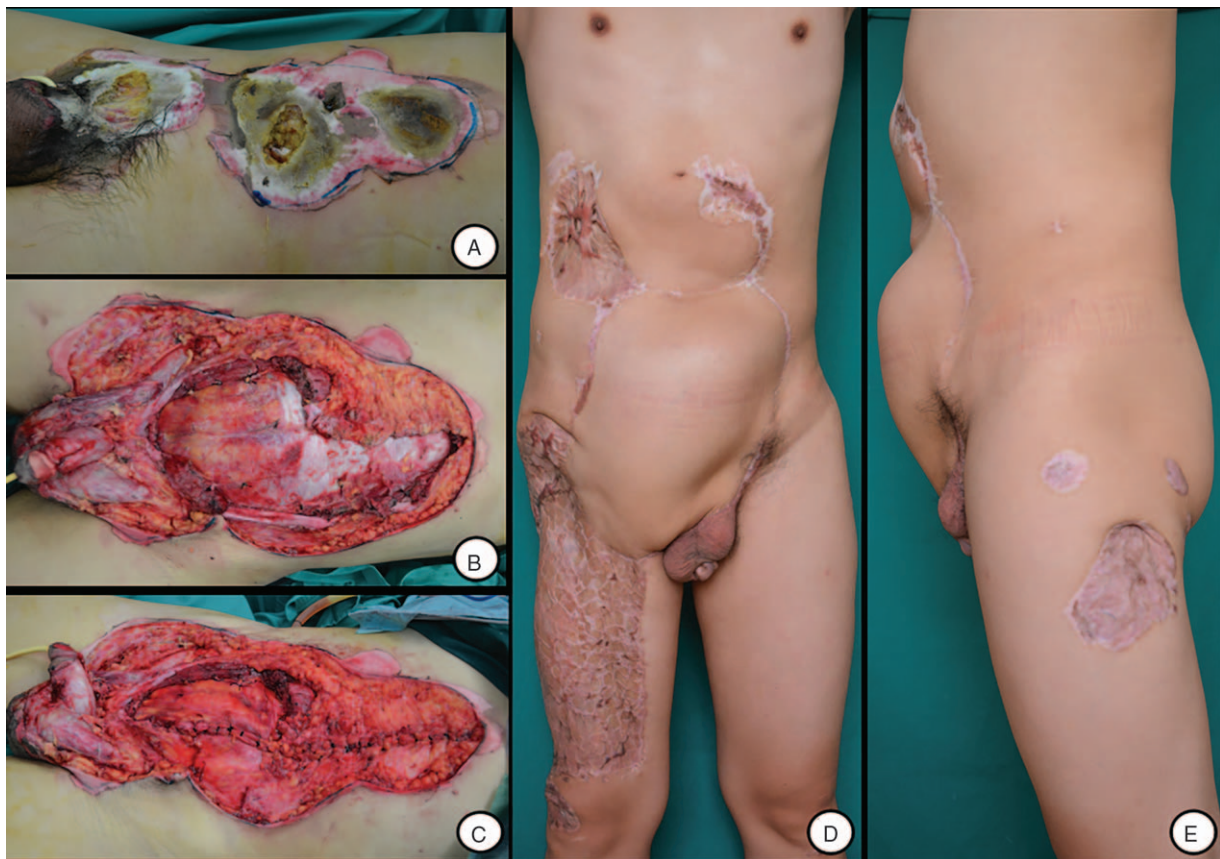
High-voltage electrical injury of the abdomen usually causes devitalization of the whole layers of the abdominal wall, even results in injuries of the internal organs. As acute peritonitis may increase the chances of wound infection and sepsis, and thus death rate, furthermore, it may also bring disadvantages to the following surgical and nursing care; reduce the patients' quality of life. Exploratory laparotomy can find some visceral organ lesion, and flap coverage is of benefit to controlling the wound infection effectively. These 2 procedures need to be carried out before the situation of abdominal lesion being exacerbated. Therefore, early diagnosis of abdominal organ injuries, early exploratory laparotomy, and timely coverage of the abdominal wall defects are the keys to enhance the patients' prognosis.

The indications for laparotomy after electrical injury on the abdominal wall still remain ambiguous, which is related with larvaceous visceral damage and delayed necrosis after electrical burns. To improve these patients' prognosis, decision regarding laparotomy was based on their clinical manifestation and debridement findings of abdominal wall by us. Fortunately, significant visceral lesion was found through laparotomy in 3 cases. No obvious internal organ injury was found in case 4 and 5 even if doubtful manifestations of acute peritonitis or gut exposure existed after injury, and these phenomena pointed out

the extent of internal organ injury was not proportional to the depth of wound after electrical injury. The segmental and jumping injury are the characteristic of electrical burns. We surmised the multiple intestinal segments necrosis may have been because of the flow of current through peritoneum into these roundabout bowels close to the anterior abdominal wall. In brief, we believed that laparotomy was important precautions after achieving on the correct assessment of clinical manifestation and debridement findings, to avoid delayed gastrointestinal perforation and peritonitis with potential visceral injury after electrical injury on abdominal wall.

In the light of conventional methods, a temporary abdominal closure can be accomplished with omentum or a variety of synthetic coverings, followed by skin grafting directly onto visceral granulation tissue, and pedicle or free myocutaneous flap should be repaired secondarily.<sup>[20–23]</sup> However, such multiple stage reconstructions are time- and cost-consuming, and the results are usually not satisfying.<sup>[24–25]</sup> Therefore, one-stage reconstruction with vascularized fascia has been proposed to overcome such disadvantages.<sup>[16,20,26]</sup> Five patients in our report underwent early flap transplantation with all flap survival, wound primary healing, no recent complications, and short hospitalization period.

Abdominal wall reconstruction includes the reestablishment of the skin and fascia, and muscles and their aponeuroses to prevent hernia formation, and the main methods include the use of prosthetic (mesh) or autologous material (tissue flaps).<sup>[27–30]</sup> To large defect of abdominal wall resulting from electrical injury, the former should be used with caution owing to the poor wound



**Figure 5.** A, Abdominal wound after injury; (B) defect after debridement; (C) defect after laparotomy; (D–E) 15 months after reconstruction using island composite ALT with innervated rectus femoris muscle, distinct abdominal wall bulging in the left wound which repaired without innervated muscles.

condition and high risk of infection.<sup>[29–33]</sup> The selection of flap is influenced by the size and location of the defect and the vascular pedicle length of the flap, the 5 cases presented above with extensive defects on the various site of abdominal wall, and island retrograde LD musculocutaneous flap, free and island composite ALT musculocutaneous flap were used respectively. By means of our clinical practice, retrograde LD musculocutaneous flap can successfully repair unilateral defects of abdomen and lumber region that reach the vicinity of the middle line, and island composite ALT musculocutaneous flap can be used to cover defects of the middle and lower abdomen that are extended 6 to 8 cm above the umbilicus. More than 3% total body surface area wound of case 4 is on the middle and upper abdomen, the pedicled ALT flap is difficult to reach and cover the wound, bilateral free composite ALT flap was employed for reconstruction of the large defect. The cautious problem of electrical injury is secondary necrosis, high-failure of free flap is mainly owing to recipient vascular erosion,<sup>[6]</sup> we use the deep inferior epigastric vessels 4 to 5 cm over the wound edge as the recipient vascular, and 3 free flaps mentioned above were successfully transplanted without vascular crisis.

Long-term follow-up showed 3 cases with abdominal bulging; however, surgical revision was not necessary because no functional discomfort occurred. The similar outcome of abdominal bulging has been reported by Bodin,<sup>[19]</sup> and the significant risk of long-term complication should be advised to patient. In addition, possible donor site morbidity should also be considered. As Kuo et al<sup>[18]</sup> reported quadriceps femoris muscle

contraction forces of donor thigh was reduced, on average, by 30% after harvest of an ALT flap combined with vascular fascia lata (without fascia lata muscle) and a cuff of vastus lateralis muscle in spite of the fact that no difficulties in daily ambulating occurred. In consideration of the long-term outcomes of cases 3, 4, and 5, the majority of abdominal bulging could be considered to be dependent on the lack of muscle and fascia structure with tensile strength, some of which is associated with the swollen wound and disability obesity after electrical burns. Therefore, we suggest that some adjacent muscle may be carried with the ALT flap used to repair the defect on the middle or lower part of abdominal wall.

Previous publications about the reconstruction of abdominal wall defect with an innervated free LD or ALT musculocutaneous flap, the thoracodorsal nerve or femoral nerve of the vastus lateralis muscle was coapted with the intercostal nerve,<sup>[3,19,34]</sup> but the recipient nerve is very difficult to find and not suit for anastomose with the nerve of flap owing to length and orientation in some cases. We used an innervated free ALT musculocutaneous flap in case 2, and pedicled innervated vastus lateralis or rectus femoris muscle in case 3 and 5, respectively, the result of follow-up is passable, especially distinct bulging appeared only in the left wound that repaired without innervated muscles in case 5, but the morbidity of donor-site is more obvious of course, and more extensive investigations with comparative studies are needed. By this token, the perfect reconstruction of abdominal wall loss after electrical injury still remains a significant clinical challenge.

## References

- [1] Leibovici D, Shemer J, Shapira SC. Electrical injuries: current concepts. *Injury* 1995;26:623–7.
- [2] Branday JM, DuQuesnay DR, Yeeseing MT, et al. Visceral complications of electrical burn injury. A report of two cases and review of the literature. *West Indian Med J* 1989;38:110–3.
- [3] Honda T, Yamamoto Y, Mizuno M, et al. Successful treatment of a case of electrical burn with visceral injury and full-thickness loss of the abdominal wall. *Burns* 2000;26:587–92.
- [4] Yang JY, Tsai YC, Noordhoff MS. Electrical burn with visceral injury. *Burns Incl Therm Inj* 1985;11:207–12.
- [5] Cancio LC, Jimenez-Reyna JF, Barillo DJ, et al. One hundred ninety-five cases of high-voltage electric injury. *J Burn Care Rehabil* 2005;26:331–40.
- [6] Koul AR, Patil RK, Philip VK. Early use of microvascular free tissue transfer in the management of electrical injuries. *Burns* 2008;34:681–7.
- [7] Rai J, Jeschke MG, Barrow RE, et al. Electrical injuries: a 30-year review. *J Trauma* 1999;46:933–6.
- [8] MacKinnon C, Klaassen M, Widdowson P. Reconstruction of a severe chest and abdominal wall electrical burn injury in a pediatric patient. *Plast Reconstr Surg* 1999;103:1775–9.
- [9] Kimata Y, Uchiyama K, Sekido M, et al. Anterolateral thigh flap for abdominal wall reconstruction. *Plast Reconstr Surg* 1999;103:1191–7.
- [10] Lv Y, Cao D, Guo F, et al. Abdominal wall reconstruction using a combination of free tensor fasciae lata and anterolateral thigh myocutaneous flap: a prospective study in 16 patients. *Am J Surg* 2015;210:365–73.
- [11] Ojuka KD, Nangole F, Ngugi M. Management of anterior abdominal wall defect using a pedicled tensor fascia lata flap: a case report. *Case Rep Med* 2012;2012:487126.
- [12] Zhou B, Zhou X, Li Z, et al. Reconstruction of the lower abdominal region using bilateral pedicled anterolateral thigh flaps combined with poly-surgical mesh: a case report. *Medicine (Baltimore)* 2015;94:e2375.
- [13] Kayano S, Sakuraba M, Miyamoto S, et al. Comparison of pedicled and free anterolateral thigh flaps for reconstruction of complex defects of the abdominal wall: review of 20 consecutive cases. *J Plast Reconstr Aesthet Surg* 2012;65:1525–9.
- [14] Jang J, Jeong SH, Han SK, et al. Reconstruction of extensive abdominal wall defect using an eccentric perforator-based pedicled anterolateral thigh flap: a case report. *Microsurgery* 2013;33:482–6.
- [15] Leppäniemi A, Tukiainen E. Reconstruction of complex abdominal wall defects. *Scand J Surg* 2013;102:14–9.
- [16] Sarabahi S, Bajaj SP, Bhatnagar A, et al. Reconstruction of abdominal wall by whole thigh flap. *J Plast Reconstr Aesthet Surg* 2006;59:1429–32.
- [17] Wong CH, Lin CH, Fu B, et al. Reconstruction of complex abdominal wall defects with free flaps: indications and clinical outcome. *Plast Reconstr Surg* 2009;124:500–9.
- [18] Kuo YR, Kuo MH, Lutz BS, et al. One-stage reconstruction of large midline abdominal wall defects using a composite free anterolateral thigh flap with vascularized fascia lata. *Ann Surg* 2004;239:352–8.
- [19] Bodin F, Dissaux C, Romain B, et al. Complex abdominal wall defect reconstruction using a latissimus dorsi free flap with mesh after malignant tumor resection. *Microsurgery* 2015;37:38–43.
- [20] Rohrich RJ, Lowe JB, Hackney FL, et al. An algorithm for abdominal wall reconstruction. *Plast Reconstr Surg* 2000;105:202–16.
- [21] Hans M, Schardey , Francesca Di Cerbo , et al. Delayed primary closure of contaminated abdominal wall defects with non-crosslinked porcine acellular dermal matrix compared with conventional staged repair: a retrospective study. *J Med Case Rep* 2014;8:251.
- [22] Manay P, Khajanchi M, Prajapati R, et al. Pedicled omental and split skin graft in the reconstruction of the anterior abdominal wall. *Int J Surg Case Rep* 2014;5:161–3.
- [23] Pieter BvH, Jan W, Marcel GWD, et al. Temporary closure of the open abdomen: a systematic review on delayed primary fascial closure in patients with an open abdomen. *World J Surg* 2009;33:199–207.
- [24] Baumann DP, Butler CE. Soft tissue coverage in abdominal wall reconstruction. *Surg Clin North Am* 2013;93:1199–209.
- [25] Stone HH, Fabian TC, Turkleson ML, et al. Management of acute full-thickness losses of the abdominal wall. *Ann Surg* 1981;193:612–8.
- [26] Hornez E, Pellet N, Roswadosky F, et al. How to reconstruct an upper full-thickness abdomen wall defect in austere environment? Interests of the pedicled myofascial latissimus dorsi flap. *Mil Med* 2014;179:e1404–8.
- [27] Mathes SJ, Steinwald PM, Foster RD, et al. Complex abdominal wall reconstruction: a comparison of flap and mesh closure. *Ann Surg* 2000;232:586–96.
- [28] Burger JW, Luijendijk RW, Hop WC, et al. Long-term follow-up of a randomized controlled trial of suture versus mesh repair of incisional hernia. *Ann Surg* 2004;240:578–83.
- [29] Hultman CS, Clayton JL, Kittinger BJ, et al. Learning curves in abdominal wall reconstruction with components separation: one step closer toward improving outcomes and reducing complications. *Ann Plast Surg* 2014;72:S126–31.
- [30] Sukkar SM, Dumanian GA, Szczerba SM, et al. Challenging abdominal wall defects. *Am J Surg* 2001;181:115–21.
- [31] Dayton MT, Buchele BA, Shirazi SS, et al. Use of an absorbable mesh to repair contaminated abdominal-wall defects. *Arch Surg* 1986;121:954–60.
- [32] Björck M, Bruhin A, Cheatham M, et al. Classification- important step to improve management of patients with an open abdomen. *World J Surg* 2009;33:1154–7.
- [33] Cavallaro A, Lo Menzo E, Di Vita M, et al. Use of biological meshes for abdominal wall reconstruction in highly contaminated fields. *World J Gastroenterol* 2010;16:1928–33.
- [34] Iida T, Mihara M, Narushima M, et al. Dynamic reconstruction of full-thickness abdominal wall defects using free innervated vastus lateralis muscle flap combined with free anterolateral thigh flap. *Ann Plast Surg* 2013;70:331–4.