



# The Clinical Outcomes of Surgical Treatment of Noncontiguous Spinal Tuberculosis: A Retrospective Study in 23 Cases

Jia Huang, Hongqi Zhang\*, Kefeng Zeng, Qile Gao

From the Department of Spine Surgery, Xiangya Hospital of Central South University, Changsha, China

## Abstract

**Study design:** A retrospective clinical study.

**Objective:** To evaluate the clinical efficacy of the surgical treatment of noncontiguous spinal tuberculosis (NSTB), and to discuss its therapeutic strategies.

**Methods:** We performed a retrospective review of clinical and radiographic data that were prospectively collected on 550 consecutive spinal tubercular patients including 27 patients who were diagnosed and treated as NSTB in our institution from June 2005 to June 2011. Apart from 4 patients being treated conservatively, the remainder received surgery by posterior transforaminal debridement, interbody fusion with instrumentation, posterior instrumentation and anterior debridement with fusion in a single or two-stage operation. The clinical outcomes were evaluated before and after treatment in terms of hematologic and radiographic examinations, bone fusion and neurologic status. The Oswestry Disability Index score was determined before treatment and at the last follow-up visit.

**Results:** 23 patients (15 M/8F), averaged  $44.6 \pm 14.2$  years old (range, 19 to 70 yd), who received surgical treatment, were followed up after surgery for a mean of  $52.5 \pm 19.5$  months (range, 24 to 72 months). The kyphotic angle was changed significantly between pre- and postoperation ( $P < 0.05$ ). The mean amount of correction was  $12.6 \pm 7.2$  degrees, with a small loss of correction at last follow-up. All patients achieved solid bone fusion. No patients with neurological deficit deteriorated postoperatively. Neither mortalities nor any major complications were found. There was a significant difference of Oswestry Disability Index scores between preoperation and the final follow-up.

**Conclusion:** The outcomes of follow-up showed that posterior and posterior-anterior surgical treatment methods were both viable surgical options for NSTB. Posterior transforaminal debridement, interbody fusion and posterior instrumentation, as a less invasive technique, was feasible and effective to treat specific tubercular foci.

**Citation:** Huang J, Zhang H, Zeng K, Gao Q (2014) The Clinical Outcomes of Surgical Treatment of Noncontiguous Spinal Tuberculosis: A Retrospective Study in 23 Cases. PLoS ONE 9(4): e93648. doi:10.1371/journal.pone.0093648

**Editor:** Robert J. Wilkinson, Institute of Infectious Diseases and Molecular Medicine, South Africa

**Received:** September 27, 2013; **Accepted:** March 8, 2014; **Published:** April 3, 2014

**Copyright:** © 2014 Huang et al. Except for Figure 3, this is an open-access article distributed under the terms of the Creative Commons Attribution License, which permits unrestricted use, distribution, and reproduction in any medium, provided the original author and source are credited.

**Funding:** The authors have no support or funding to report.

**Competing Interests:** The authors have declared that no competing interests exist.

\* E-mail: zhq9996@qq.com

## Introduction

Tuberculosis has made a dramatic comeback, in part because of the appearance of anti-tuberculosis drug resistance and the acquired immune deficiency syndrome (AIDS) pandemic. As a destructive pattern of tuberculosis, spinal tuberculosis (STB) accounts for 50% of all cases of musculoskeletal tuberculosis [1]. It is characterized by formation of cold abscess, destruction of the intervertebral disc and the adjacent vertebral bodies, collapse of the spinal elements, and anterior wedging leading to kyphosis. Multilevel noncontiguous spinal tuberculosis (NSTB) is an atypical form of STB, which leaves not less than two adjacent vertebrae intact between the two foci. The incidence of NSTB is reported as 1.1% to 16.3% [2,3]. Recently, with whole spine magnetic resonance image (MRI) being applied to aid detection of NSTB, its incidence is higher than previously quoted [4]. The treatment regimes regarding NSTB vary from purely medicine to a

combination of chemotherapy and surgery. The pendulum of therapeutic strategies to NSTB has periodically vacillated between non-operative management and radical surgery. In the present study, we seek to discuss the role of surgical treatment method.

## Materials and Methods

### Patients

This study was approved by the Ethic Committee of the Xiangya Hospital of Central South University. We performed a retrospective review of clinical and radiographic data that were prospectively collected on 550 consecutive spinal tubercular patients including 27 patients who were diagnosed and treated as NSTB in our institution from June 2005 to June 2011. Plain radiology, computed tomography and MRI of the spine were performed on all patients admitted with suspected spinal tuberculosis. Whole spine MRI was performed on patients

presenting with multi-level symptomatic vertebral infection. A diagnosis of NSTB was defined as vertebral disease additional to the main lesion identified on MRI separated by at least 2 normal spinal segment (vertebral body/neural arch and/or intervertebral disc). Written informed consent was acquired from each of the patients to authorize treatment, imageology findings, and photographic documentation.

The cohort comprised 17 males and 10 females, averaged  $44.7 \pm 13.2$  years old (range, 19–70), with a minimum 2-year follow up. Apart from 4 cases treated conservatively, the remainder 23 patients (15 M/8F), averaged  $44.6 \pm 14.2$  years old, received surgical treatment (Table 1). The location of infection varied from cervical spine down to lumbar spine (Table 1). The clinical outcomes were measured preoperatively, immediately after surgery and at ultimate follow-up visit in term of hematologic and radiographic examinations and neurologic status. Hematologic examination included erythrocyte sedimentation rate (ESR), C-reactive protein (CRP), liver function test and blood count. The neurologic status was graded according to Frankel classification [5,6]. Kyphotic angel was measured by drawing two lines—one was along the top surface of the immediate upper normal vertebral body, and the other was away from the diseased segment. The bone fusion was assessed by the Moon standard [7]. Bone fusion was characterized by reappearance of bone trabeculae between the graft bed and graft, along with substantial graft thickness in X-ray radiography.

### Treatment Strategies

The diagnosis was established by the presence of typical clinical and radiographic presentations, suggestive of STB in a resident from an endemic area who had an elevated ESR, CRP and a therapeutic response to anti-tubercular therapy. All patients were prescribed isoniazid (INH) (5 mg/kg), rifampicin (10 mg/kg), ethambutol (15 mg/kg) and pyrazinamide (25 mg/kg) for 4 months duration, followed by rifampicin/INH/pyrazinamide for at least a further nine months, until regression of symptoms, and resolution of laboratory and radiological abnormalities. Patients with progressive neurologic deficit received additional intravenous isoniazid (0.4g/day) for 3 days preoperatively [8]. The basic principles of treatment for spinal tuberculosis that we referred to were as follows: the lesion which was limited vertebral body destruction, small amount of abscess, with neither progressive spinal cord and nerve root compromise, nor drug-resistant TB, could be treated conservatively; and the indications for surgery included the evolving neurological deficit, spinal instability, severe kyphotic deformity, refractory disease, large paravertebral abscesses and epidural abscess compressing the dural sac [8,9]. If the surgical lesion was confined to less than two adjacent segments, mono-stage posterior transforaminal debridement, interbody fusion and posterior instrumentation could be utilized; if the lesion involved more than 2 adjacent segments or had large paraspinal abscess, anterior debridement and autogenous iliac bone graft or allograft bone could be added after posterior instrumentation. However, regarding the surgical treatment priority of each skipping lesion, the more serious lesion i.e. the one that resulted in more significant neurological compromise was treated first. If two lesions both caused neurological compromise, the upper lesion was treated first.

### Operative Procedure

The surgery was performed under general anaesthesia. During the first stage, posterior instrumentation was applied. As described previously, if the involvement was confined to mono-segment without mass paravertebral abscess, transforaminal debridement

and interbody fusion could be performed (Fig. 1) [8,10,11]. Mild kyphosis could be corrected by postural reduction and the application of compressive, or translation correction forces during posterior instrumentation. The instrumentation was always extended 2 levels above and below the focus. Autogenous bone or allograft was selected for posterior fusion at designated segments that underwent decompression and focal debridement.

If the focus involved more than 2 adjacent segments or had large paravertebral abscess, anterior focal debridement and bone grafting could be performed, via thoracic, thoracolumbar, or peritoneal approaches for different lesions in a single stage or in two stages depending on patients' conditions. Additionally, the leaping lesion without mass abscess and severe vertebral body destruction nor neurological compression could be left conservatively (Fig. 2c, white arrow).

### Postoperative Procedure and Follow-up

The drainage tube was removed when the drainage flow was less than 50 mL/24 h. The patients were allowed to start walking 2 weeks after surgery but the spine was immobilized with an orthosis for 3 months until bony fusion was achieved. Imageological examinations (X-ray) and hematologic parameters (ESR, CRP, liver function test) were performed at one month intervals in the first three months, three month intervals in the next nine months, at six month intervals in the second year and then once a year, along with the assessment of neurologic status, correction of deformity, and success of bone graft fusion. Clinical outcome was assessed preoperatively and at the last follow-up visit using the Oswestry disability index (ODI) questionnaire [12].

### Statistics Analysis

The statistical analysis was performed using GraphPad Prism (Version 5.0 GraphPad software Inc, California, USA). Paired Sample *t* test was used to compare the pre and postoperative clinical and radiographic data with a significance level of 0.05 (*P* value). The results are reported as mean  $\pm$  standard deviation (SD).

### Results

4 patients (2 M/2F), with an average of  $45.0 \pm 6.2$  years old, were successfully treated conservatively, and none of these had any residual instability, radiculopathy or neurological compromise. The duration of anti-TB treatment ranged from 12 months to 18 months, until regression of symptoms and resolution of hematologic and radiological abnormalities.

### Operative Results

Of the remainder, 16 patients were treated by posterior debridement, transforaminal interbody fusion with instrumentation; 6 patients underwent posterior fusion with instrumentation and anterior debridement plus autogenous iliac bone graft, or titanium mesh cage packed with morsellised rib, autoiliac bone grafting; 1 patient was treated with the two hybrid techniques mentioned above (Table 1). The duration of surgery was  $405 \pm 110$  minutes. Blood loss during surgery was  $1250 \pm 500$  mL and 1 or 2 units of packed red blood cells was transfused intra-operatively. No wound infection and sinus formation occurred.

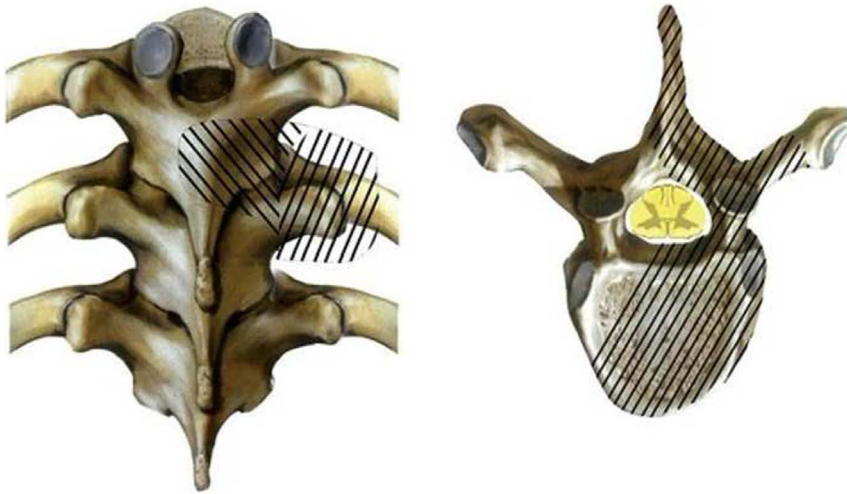
### Radiographic and Hematologic Results

Radiological fusion was achieved in all patients at the final follow-up (Fig. 2e, 3g). Evidence of bridging trabeculae and absence of motion on dynamic films were regarded as conclusive evidence of fusion [13]. The serum level of ESR and CRP

**Table 1.** Clinical details of surgical group.

Patient no.	Age (years)	Follow-up (months)	Sex	Frankel grade		Site of tuberculosis disease	Treatment	Kyphosis (°)		LV
				Pre	LV			Pre	Post	
1	19	24	M	C	D	T+T	TTIF (lower)	25	6	6
2	21	48	M	B	D	T+TL	TTIF (upper)	24	4	4
3	25	24	M	D	E	T+T	TTIF+TTIF	31	24	29
4	48	68	M	D	E	T+T	TTIF (upper)	15	8	8
5	60	72	M	D	E	T+TL	TTIF+TLIF	22	7	8
6	38	52	F	B	D	CT+T	TTIF (lower)	42	25	26
7	60	72	M	D	E	T+T	TTIF (upper)	35	18	20
8	57	24	F	C	C	CT+T	TTIF (lower)	19	10	12
9	34	68	F	C	E	T+T	TTIF+TTIF	10	3	3
10	46	72	F	E	E	T+T	TTIF (lower)	13	3	3
11	58	72	M	D	E	T+T	TTIF (lower)	8	4	4
12	65	64	M	C	D	T+TL	TTIF+TLIF	10	3	4
13	70	64	M	D	E	T+T	TTIF (upper)	18	12	12
14	63	32	F	D	E	CT+T	AP (lower)	38	16	17
15	46	66	F	C	E	T+L	AP (upper)	42	30	33
16	38	32	M	E	E	T+L	TTIF+TLIF	24	15	17
17	44	66	M	E	E	T+TL	AP (lower)	55	34	35
18	26	36	M	E	E	CT+T	AP (upper)	13	13	9
19	43	66	F	E	E	T+L	TLIF	18	-7	-9
20	43	26	M	E	E	T+TL	AP (lower)	29	9	11
21	42	68	M	E	E	T+L	TLIF	4	-6	-8
22	43	24	M	E	E	T+T+L	AP(lower) +TLIF	30	8	11
23	37	68	F	E	E	T+L	AP (upper)	35	32	33
Mean values	44.6±14.2	52.5±19.5						24.4±12.8	11.8±11.2 <sup>#</sup>	12.5±12.2*

M male; F female; LV last visit; Pre preoperative; Post postoperative; T thoracic; L lumbar; CT cervicothoracic; TL thoracolumbar; TTIF transforaminal thoracic debridement, interbody fusion; TLIF transforaminal lumbar debridement, interbody fusion; AP anterior debridement and posterior instrumentation. # indicates a statistically significant difference between preoperation and postoperation (t = 8.410, P < 0.05); \* indicates that there is no significant difference comparing postoperative and at final visit values (t = 1.902, P = 0.07).  
doi:10.1371/journal.pone.0093648.t001



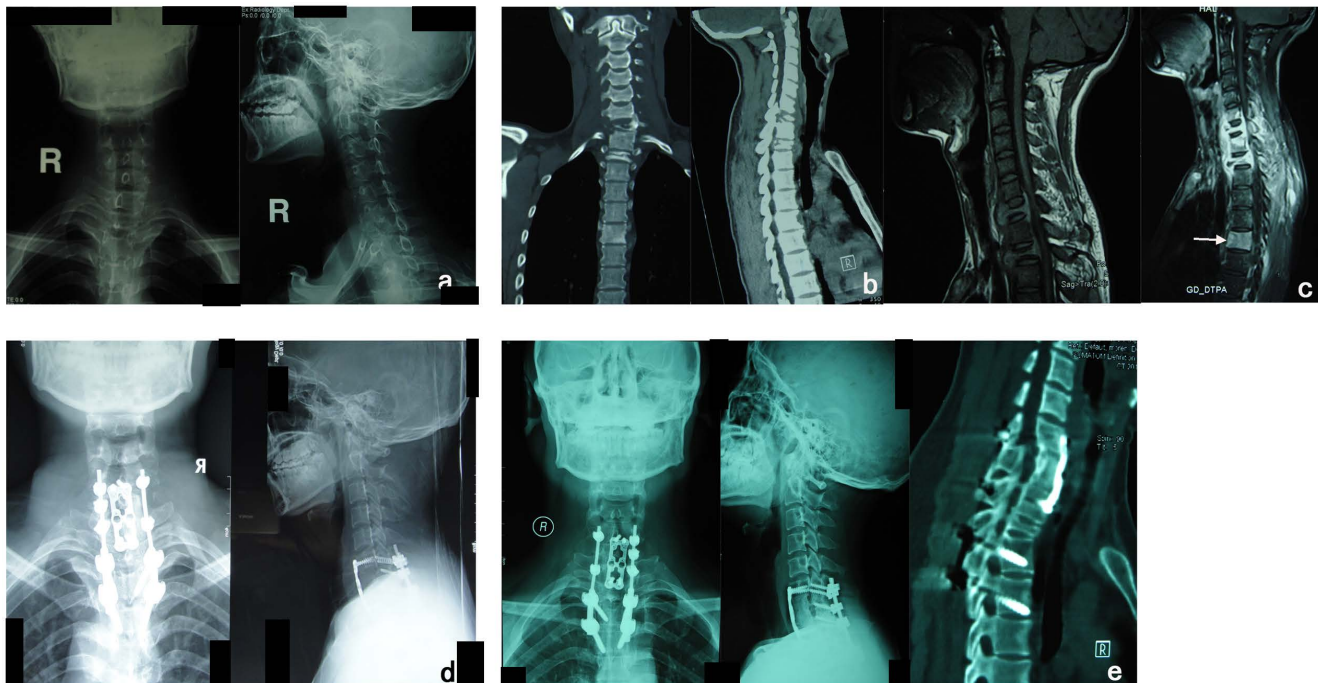
**Figure 1. Illustration of surgical management for tuberculous spondylitis through transforaminal thoracic (lumbar), interbody fusion and debridement.** The pictures were reproduced with the permission of the Hunan Publishing House.  
doi:10.1371/journal.pone.0093648.g001

returned from  $55.8 \pm 15.8$  mm/h,  $19.8 \pm 8.9$  mg/ml, respectively, preoperatively to normal with 12–16 weeks. Given the isoniazid and rifamycins-associated hepatotoxicity, liver function test were monitored at every visit for adherence to therapy. In this series, blood count and liver-function monitoring indicated no abnormality during medical therapy. The kyphotic angle improved from  $24.4 \pm 12.8^\circ$  preoperatively to  $11.8 \pm 11.2^\circ$ , with a mean correction

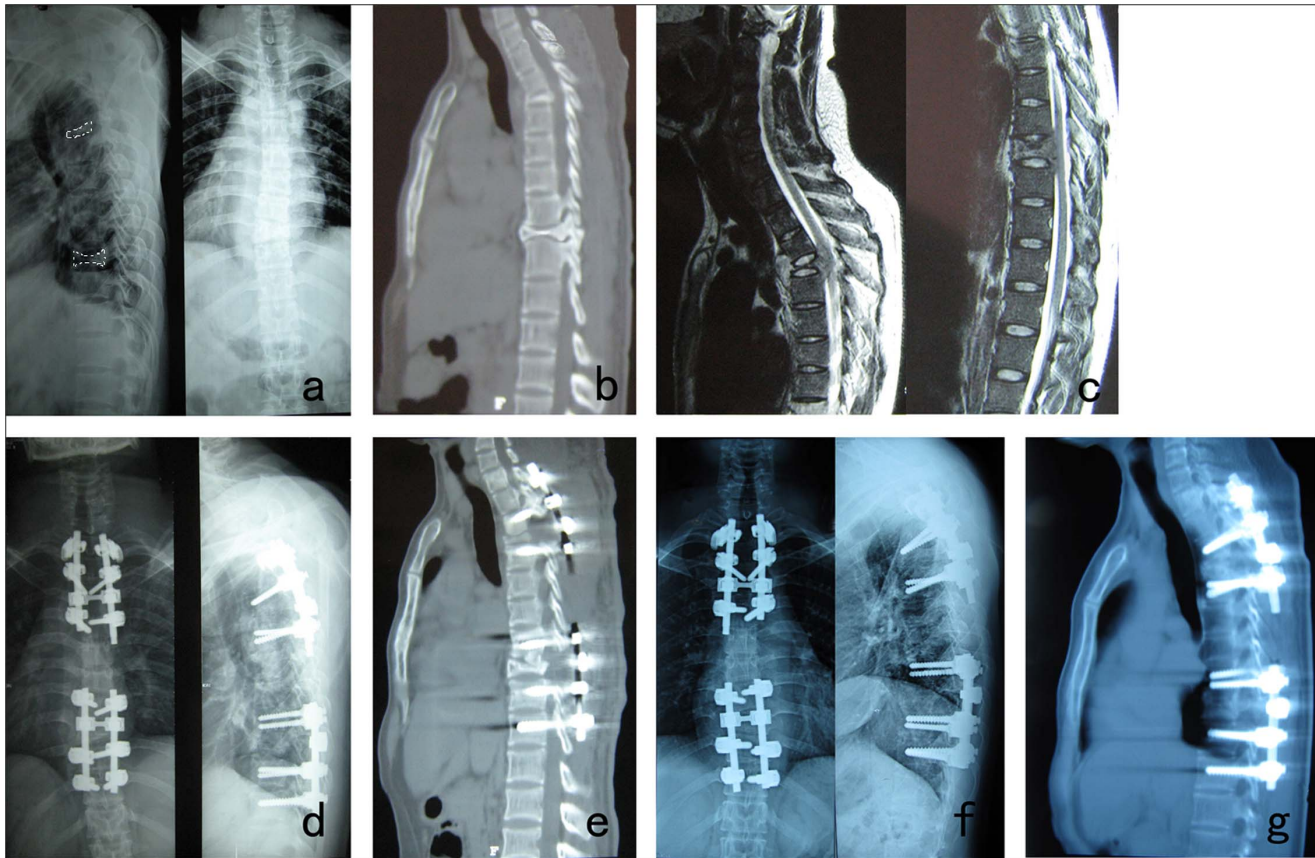
of  $12.6 \pm 7.2^\circ$ , and there was a mean correction loss of  $0.74 \pm 1.9^\circ$  at final visit (Table 1).

#### Neurologic Status

No neurological deterioration was noted in any patients postoperatively. There were 17 cases who suffered neurologic insults before surgery, most recovered after surgery. At the latest



**Figure 2. A 26-year-old woman with multilevel noncontiguous cervicothoracic tuberculous spondylitis underwent posterior instrumentation and anterior debridement, graft fusion plus anterior instrumentation.** Note the marked improvement of spinal stability and solid bone fusion when comparing her preoperative and latest films. (a) Preoperative X-ray films of cervical spine show bone destruction of the C7 and T1 vertebral bodies. (b) Preoperative CT shows tuberculosis cavities and paravertebral abscess at C7-T1 and T2 and limited involvement at T6. (c) Preoperative sagittal T1W MRI (left) showing involvement of C7-T2 with collapse of the C7 and T2 vertebrae and paravertebral abscess, Gd-DTPA-enhanced T1W sagittal MRI (right) showing enhancements of the inflammatory vertebral bodies and tissue. (d) Standing anteroposterior and lateral radiographs immediately after operation. (e) X-ray films and sagittal CT of cervical spine show grafts union at the final follow-up of 36 months.  
doi:10.1371/journal.pone.0093648.g002



**Figure 3. Images in a 25-year-old man with T4 and T9 tuberculous spondylitis.** (a) Preoperative X-ray films demonstrate collapse of the T4 and T9 vertebrae. Note the abnormal vertebral bodies outlined in white dotted lines on the lateral image. (b, c) Preoperative sagittal CT and T2W MRIs demonstrate bone destruction and formation of epidural abscess at T4 and T9. (d,e) Immediate postoperative X-ray and sagittal CT show that the patient received posterior transforaminal thoracic debridement, limited decompression plus instrumentation at the upper lesion, and posterior transforaminal thoracic debridement, interbody fusion and instrumentation at the caudal lesion. (f,g) X-ray and CT reveal graft union and internal fixation in good position at 2-year follow-up. Figure 3 is excluded from this article's CC-BY license. See accompanying retraction notice for more information.

doi:10.1371/journal.pone.0093648.g003

follow-up examination, Frank C and D were observed in one and four cases respectively, the remainder demonstrated normal neurologic functions (Table 1).

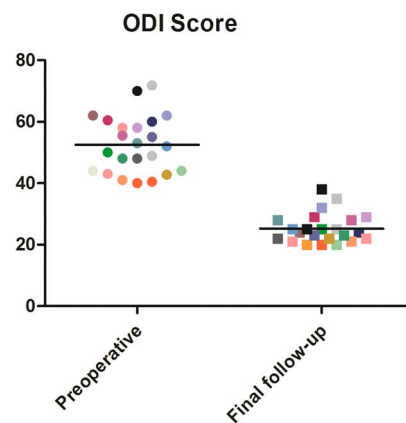
### Clinical Outcome

The mean ODI improved from  $52.5 \pm 9.2$  before surgery to  $25.3 \pm 4.8$  at the last visit (Fig. 4).

### Discussion

As a result of AIDS and new drug-resistant strains, the resurgence of STB has sparked a flurry of activity toward the prevention and treatment of this condition [14]. Nowadays, management strategies of STB include conservative therapy and various advanced surgical techniques [8,10,15–17]. STB often involves adjacent vertebrae and the intervening disc, while leaping and remote lesion is not common and does not characterize the disease. Reviewing the literature, NSTB are mostly reported as episodic case reports in the mainstream academic journals [3,16,18]. The incidence of NSTB is reported as 1.1% to 71.4% [2–4,16], and it is 4.3% in our study.

There is a minority of papers referring to the surgical treatment of NSTB. In 2012, Shi et al. [19] reported the results of 29 cases with NSTB treated with intervertebral focal surgery. These investigators obtained a mean correction rate of 59.5% with good



**Figure 4. Scatter plot shows the ODI scores of every patient preoperatively and at the last follow-up, with significant difference ( $t=22.79$ ,  $P < 0.0001$ ).** The same color of the dot represents the same patient.

doi:10.1371/journal.pone.0093648.g004

bone fusion at the final follow-up. In the same year, Zhang et al. [8] reported the clinical outcomes of posterior transforaminal thoracic debridement, limited decompression, interbody fusion

and posterior instrumentation for treatment of noncontiguous thoracic tuberculosis, which also achieved good clinical efficacy. So far, however, there is a paucity of information describing the comprehensive therapeutic strategies of NSTB. In this paper, we aim to evaluate the clinical efficacy of the surgical managements (posterior surgery and a combination of posterior and anterior surgery) for NSTB, and to discuss the relevant therapeutic strategies.

The treatment principles of NSTB are basically derived from the experience in treating contiguous spinal tuberculosis. Surgery is indicated for patients with severe or evolving neurologic deficit despite antituberculous chemotherapy, persistence of symptoms despite adequate antitubercular therapy, spinal instability, and severe spinal deformity [8,9]. Compare to single focus treatment, there are several noteworthy details in the treatment of NSTB. Multilevel surgical interventions of NSTB result in more surgical trauma and complications than that of single focus disease. Therefore, surgical indications should be controlled more strictly for each lesion of patients. Severe surgical trauma and complications caused by multilevel surgical interventions should be reduced as much as possible, by application of minimized invasive surgical techniques and the preference of debridement to radical surgery. In addition, during multilevel surgery, the upper lesion or the one with neurologic compression should be dealt with in priority. What's more, staged procedures could be performed for patients with physical deterioration.

Diverse surgical techniques, which can be divided into anterior, posterior and combined types, performed either in one or two stages, have been applied in spinal tuberculosis. Radical Hong Kong technique is the standard for anterior radical debridement with strut graft fusion. Sufficient experience has demonstrated this procedure could gain good clinical efficacy in STB treatment. Nonetheless, after radical and extended Hong Kong procedure, the incidence of spinal instability is very high. Therefore, a combination with a posterior instrumentation for full stabilisation appears crucial. Likewise, in cases with posterior instrumentation, when an anterior approach is needed for extended focus debridement, anterior instrumentation can be accomplished at the same time.

Previously, the posterior approach was primarily indicated in cases with destruction of posterior structures of spine accompanied by an epidural abscess, or the involvement of neural arch, causing posterior spinal cord compression. However, in recent years, as transforaminal thoracic or lumbar interbody fusion (TTIF or TLIF) has become widely applied as minimally invasive surgical intervention in various etiologies [20,21], these techniques have been modified to treat spinal tuberculosis [8,11,17], which were performed by a single-stage posterior transforaminal debridement, interbody fusion plus posterior instrumentation. They have the advantages of minor surgical invasion and minimal hazard of focal neurological injury due to easy access to the spinal canal, obviating the need for anterior exposure and its associated complications. In 2009, Gautam et al [11] employed TLIF to treat lumbar tuberculosis which was associated with disease resolution, and no recurrence at final follow-up, in all patients. In this study, 17 patients were treated with transforaminal debridement, interbody

fusion and posterior instrumentation, and achieved bone fusion without recurrence at last follow-up.

Many studies have shown a direct correlation between sagittal spine imbalance and severity of back pain [22,23]. Hirakawa et al. [24] showed that good restoration and maintenance of spinal alignment was obtained by 2-staged posterior (first) and anterior fusion for spinal tuberculosis. They also pointed out that pain level decreased significantly after posterior instrumentation. It is well known that posterior transpedicular instrumentation could provide sufficient spinal stability and obviate the evolution of late angular deformity [24,25]. The early correction of spinal instability, which is facilitated to suppress the infection and afford a relatively stable internal environment to decrease recurrence, plays an important role in treating STB. Furthermore, rigid stabilization of spine has been demonstrated experimentally to promote neurological recovery [24,26]. In present study, most patients achieved pronounced improvement in daily activities and neurologic deficits at the latest follow-up.

It is well known that anti-tubercular chemotherapy is the mainstay of treatment of uncomplicated spinal tuberculosis and helps to improve the outcomes of surgery by ameliorating healing and reducing recurrence. The necessity for surgical radical debridement of the disease lesions ceases to exist, which is especially important in treating NSTB. Surgery becomes less frequent, less invasive, safer and more successful. Moreover, the incidence of spinal instability created after extended and radical surgery is high. In consideration of two aspects above, we maintained the integrity of pathological vertebrae as far as possible; only paravertebral abscess, sclerotic bone, dead osteons and focal tissues of lesions were debride.

Even today there is still lack of consensus regarding the ideal duration of treatment of STB. The regimen that includes 2 months of Isoniazid/Rifampicin/Pyrazinamide/Ethambutol and followed by 4 months of Isoniazid/Rifampicin (2HRZE+4HR) has been recommended by WHO [27]. Nevertheless, in this series, anti-TB chemotherapy were prescribed for no less than 12 months as most patients came from medically underserved area, with high morbidity rates. Furthermore, uncertainty about the permeation of the focus by the drug therapy and concern about disease recurrence compelled us to choose a prolonged duration of chemotherapy. In the end, these patients achieved good cure rates without the emergence of acquired drug resistance or the occurrence of treatment failure, benefiting from their perfect obedience to anti-TB chemotherapy.

## Conclusion

The results of this study indicate that posterior and posterior-anterior surgical treatment methods for NSTB are both viable surgical options. Posterior transforaminal debridement, interbody fusion and posterior instrumentation as a less invasive technique, is feasible and effective to treat specific tubercular foci.

## Author Contributions

Conceived and designed the experiments: HZ. Performed the experiments: JH. Analyzed the data: KZ. Contributed reagents/materials/analysis tools: QG. Wrote the paper: JH.

## References

1. Tuli S (2004) Tuberculosis of the skeletal system: bones, joints, spine and bursal sheaths. Jaypee Brothers Medical Pub.
2. Polley P and Dunn R (2009) Noncontiguous spinal tuberculosis: incidence and management. *Eur Spine J* 18: 1096–1101.
3. Turgut M (2001) Spinal tuberculosis (Pott's disease): its clinical presentation, surgical management, and outcome. A survey study on 694 patients. *Neurosurgical review* 24: 8–13.
4. Kaila R, Malhi AM, Mahmood B and Saifuddin A (2007) The incidence of multiple level noncontiguous vertebral tuberculosis detected using whole spine MRI. *J Spinal Disord Tech* 20: 78–81.

5. Davis L, Warren S, Reid D, Oberle K, Saboe L, et al. (1993) Incomplete Neural Deficits in Thoracolumbar and Lumbar Spine Fractures | Reliability of Frankel and Sunnybrook Scales. *Spine* 18: 257–263.
6. Frankel H (1969) The value of postural reduction in the initial management of closed injuries of the spine with paraplegia and tetraplegia. *Paraplegia* 7: 179–192.
7. Moon MS, Woo YK, Lee KS, Ha KY, Kim SS, et al. (1995) Posterior instrumentation and anterior interbody fusion for tuberculous kyphosis of dorsal and lumbar spines. *Spine (Phila Pa 1976)* 20: 1910–1916.
8. Zhang HQ, Lin MZ, Shen KY, Ge L, Li JS, et al. (2012) Surgical management for multilevel noncontiguous thoracic spinal tuberculosis by single-stage posterior transforaminal thoracic debridement, limited decompression, interbody fusion, and posterior instrumentation (modified TTIF). *Archives of orthopaedic and trauma surgery* 132: 751–757.
9. Garg RK and Somvanshi DS (2011) Spinal tuberculosis: a review. *The journal of spinal cord medicine* 34: 440–454.
10. Zhang H, Sheng B, Tang M, Guo C, Liu S, et al. (2013) One-stage surgical treatment for upper thoracic spinal tuberculosis by internal fixation, debridement, and combined interbody and posterior fusion via posterior-only approach. *Eur Spine J* 22: 616–623.
11. Zaveri GR and Mehta SS (2009) Surgical treatment of lumbar tuberculous spondylodiscitis by transforaminal lumbar interbody fusion (TLIF) and posterior instrumentation. *J Spinal Disord Tech* 22: 257–262.
12. Fairbank J, Couper J, Davies J and O'Brien J (1980) The Oswestry low back pain disability questionnaire. *Physiotherapy* 66: 271–273.
13. Zhang HQ, Huang J, Guo CF, Liu SH and Tang MX (2013) Two-level pedicle subtraction osteotomy for severe thoracolumbar kyphotic deformity in ankylosing spondylitis. *Eur Spine J*.
14. Buckner CB, Leithiser RE, Walker CW and Allison JW (1991) The changing epidemiology of tuberculosis and other mycobacterial infections in the United States: implications for the radiologist. *AJR American journal of roentgenology* 156: 255–264.
15. Nene A and Bhojraj S (2005) Results of nonsurgical treatment of thoracic spinal tuberculosis in adults. *The spine journal : official journal of the North American Spine Society* 5: 79–84.
16. Abdul-Jabbar A, Takemoto S, Weber MH, Hu SS, Mummaneni PV, et al. (2012) Surgical site infection in spinal surgery: description of surgical and patient-based risk factors for postoperative infection using administrative claims data. *Spine (Phila Pa 1976)* 37: 1340–1345.
17. Zhang HQ, Lin MZ, Li JS, Tang MX, Guo CF, et al. (2013) One-stage posterior debridement, transforaminal lumbar interbody fusion and instrumentation in treatment of lumbar spinal tuberculosis: a retrospective case series. *Archives of orthopaedic and trauma surgery* 133: 333–341.
18. Emel E, Guzey FK, Guzey D, Bas NS, Sel B, et al. (2006) Non-contiguous multifocal spinal tuberculosis involving cervical, thoracic, lumbar and sacral segments: a case report. *European spine journal : official publication of the European Spine Society, the European Spinal Deformity Society, and the European Section of the Cervical Spine Research Society* 15: 1019–1024.
19. Shi JD, Wang ZL, Geng GQ and Niu NK (2012) Intervertebral focal surgery for the treatment of non-contiguous multifocal spinal tuberculosis. *Int Orthop* 36: 1423–1427.
20. Yamasaki R, Okuda S, Maeno T, Haku T, Iwasaki M, et al. (2013) Surgical outcomes of posterior thoracic interbody fusion for thoracic disc herniations. *Eur Spine J*.
21. Machino M, Yukawa Y, Ito K, Nakashima H and Kato F (2010) A new thoracic reconstruction technique “transforaminal thoracic interbody fusion”: a preliminary report of clinical outcomes. *Spine* 35: E1000–1005.
22. Glassman SD, Bridwell K, Dimar JR, Horton W, Berven S, et al. (2005) The impact of positive sagittal balance in adult spinal deformity. *Spine* 30: 2024–2029.
23. Roussouly P and Nnadi C (2010) Sagittal plane deformity: an overview of interpretation and management. *European spine journal* 19: 1824–1836.
24. Hirakawa A, Miyamoto K, Masuda T, Fukuta S, Hosoe H, et al. (2010) Surgical outcome of 2-stage (posterior and anterior) surgical treatment using spinal instrumentation for tuberculous spondylitis. *Journal of spinal disorders & techniques* 23: 133–138.
25. Lee TC, Lu K, Yang LC, Huang HY and Liang CL (1999) Transpedicular instrumentation as an adjunct in the treatment of thoracolumbar and lumbar spine tuberculosis with early stage bone destruction. *Journal of neurosurgery* 91: 163–169.
26. Al-Sebai MW, Al-Khawashki H, Al-Arabi K and Khan F (2001) Operative treatment of progressive deformity in spinal tuberculosis. *International orthopaedics* 25: 322–325.
27. Toman K (2004) Toman's tuberculosis: Case detection, treatment, and monitoring: questions and answers. World Health Organization.