

Other clinical applications of videolaryngoscopy besides intubation

Sir,

Videolaryngoscope (VL) is the latest frontiers in airway management. It serves as a valuable adjunct to facilitate intubation in a patient with known or suspected difficult airway. The standard VL has a digital camera, incorporated into the blade^[1] and without the need of three-axis alignment and minimal swings in hemodynamics, the video laryngoscope provides an optimal glottic view, which is projected onto a screen where it can be visualized by both the anesthesia and surgical teams [Figure 1].

Video-augmented periglottic visualization allows the adaptation of VL for airway procedures well-beyond intubation and a variety of ingenious applications and uses.^[2] According to the current scientific literature, VL has been used for examination and biopsies of the tongue base, removal of foreign bodies, and radiofrequency treatment of obstructive sleep apnea.^[3] It is sometimes happened for the ear-nose-throat (ENT) specialist to experience technical issues due to the misplacement of the direct laryngoscope because of some particular anatomical or pathological features (i.e., traumatic injuries, cervical spine immobilization, etc.).^[3] The use of VL can help in managing these issues and facilitate the execution of several procedures in addition to simple endotracheal tube placement.^[4] We are sharing our experience of one such case where VL helped in achieving an optimal view and obtaining biopsy, thus providing greater ease for surgical team.

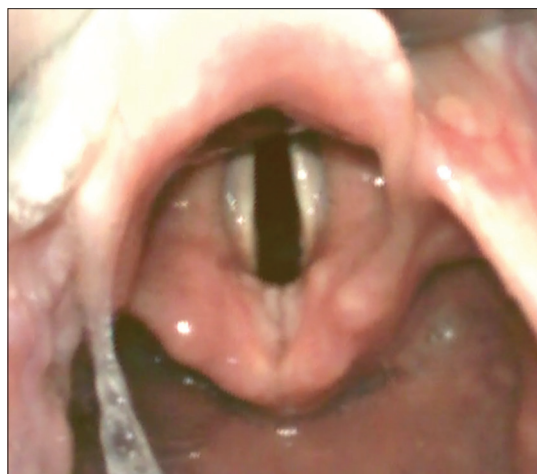

Figure 1: Normal videolaryngoscopic view of glottis with other surrounding structures

A 52-year-old male patient was presented to ENT clinic for complaints of hoarseness. He has a history of smoking for 10 years. The surgeon performed fiberoptic direct laryngoscopy in clinic that revealed vocal cord lesion. His general physical and systemic examination was unremarkable. In airway assessment, Mallampatti class II and slightly restricted neck movement. Laboratory investigations were also within normal limits. He was scheduled for direct laryngoscopy, biopsy, and LASER excision.

After application of standard American Society of Anesthesiologists monitoring (electrocardiogram, NIBP, SPO₂, ETCO₂), we did induction of anesthesia with fentanyl 2 µg/kg, propofol 2 mg/kg, and sevoflurane 4%–6% in 100% oxygen. Atracurium 30 mg was given, and then, we performed laryngoscopy with Karl Storz C-MAC VL (Karl Storz, Tuttlingen, Germany) which found Grade II view and patient intubated using double cuffed Mallinckrodt™ laser flex tube size 5.0 mm endotracheal tube with slight manipulation and external pressure. For anesthetic maintenance, sevoflurane reduced to 4% with oxygen 30% and air is added to this mixture. The other precautions for LASER airway surgery were taken into account (eye protection/goggles, 50 ml syringes filled with water, wet swabs on the patient face, etc.).

The surgeon using the Dedo Pilling laryngoscope attempted the rigid laryngoscopy. During surgical laryngoscopy, it was difficult to obtain a view even of glottic opening, and the high-risk neck extension was noted. External pressure was applied but could not improve the view. At this stage, we discussed different options for improving the view, and surgical laryngoscopy was abandoned, and then same Karl Storz C-MAC VL with an extra-curved blade was inserted demonstrating a Cormack and Lehane Grade II and viewing of whitish lesion at the upper part of vocal cords [Figure 2]. The surgeon obtains adequate biopsy samples, and LASER part of the procedure was deferred.

This case highlights the necessity and importance of close communication and cooperation between the surgeons and anesthesiologists during shared airway cases. We believe that direct suspension microlaryngoscopy should remain the gold standard for the treatment of laryngeal lesions; VLs can be considered as an alternative tool to perform selected diagnostic laryngeal

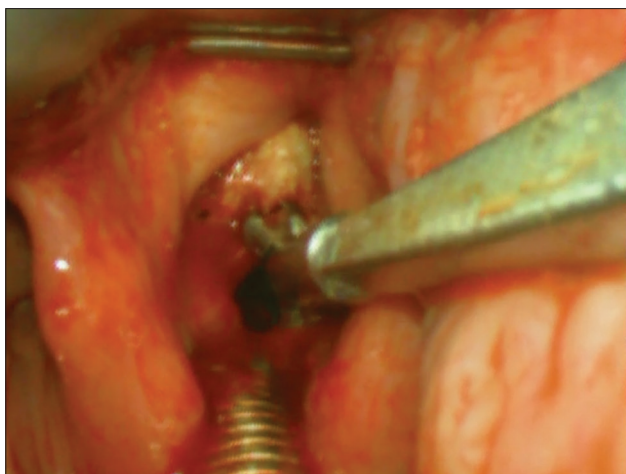

Figure 2: Biopsy of laryngeal lesion was taken with videolaryngoscope while LASER endotracheal tube in place

procedures in the presence of unfavorable anatomy and high-risk neck extension or damage to oral structures.

Declaration of patient consent

The authors certify that they have obtained all appropriate patient consent forms. In the form the patient(s) has/have given his/her/their consent for his/her/their images and other clinical information to be reported in the journal. The patients understand that their names and initials will not be published and due efforts will be made to conceal their identity, but anonymity cannot be guaranteed.

Financial support and sponsorship

Nil.

Conflicts of interest

There are no conflicts of interest.

FAISAL SHAMIM, MARIUM NAFIS, MUBASHER IKRAM¹

Departments of Anaesthesiology and ¹Surgery, Aga Khan University Hospital, Karachi, Pakistan


Address for correspondence:

Dr. Faisal Shamim,
Department of Anaesthesiology, Aga Khan University,
Stadium Road, Karachi 74800, Pakistan.
E-mail: faisal.shamim@aku.edu

References

1. Rai MR, Dering A, Verghese C. The glidescope system: A clinical assessment of performance. *Anaesthesia* 2005;60:60-4.
2. Pott LM, Murray WB. Review of video laryngoscopy and rigid fiberoptic laryngoscopy. *Curr Opin Anaesthesiol* 2008;21:750-8.
3. Shenoy PK, Aldea M. The use of GlideScope for biopsies of the tongue base. *J Laryngol Otol* 2013;127:215-6.
4. Bruno E, Dauri M, Mauramati S, Viziano A, Micarelli A, Ottaviani F, *et al.* Utility of Glidescope(®) videolaryngoscopy in surgical procedures involving the larynx. *Acta Otorhinolaryngol Ital* 2015;35:45-8.

This is an open access journal, and articles are distributed under the terms of the Creative Commons Attribution-NonCommercial-ShareAlike 4.0 License, which allows others to remix, tweak, and build upon the work non-commercially, as long as appropriate credit is given and the new creations are licensed under the identical terms.

Access this article online	
<p>Website: www.saudija.org</p>	<p>Quick Response Code</p> 
<p>DOI: 10.4103/sja.SJA_697_17</p>	

How to cite this article: Shamim F, Nafis M, Ikram M. Other clinical applications of videolaryngoscopy besides intubation. *Saudi J Anaesth* 2018;12:491-2.
© 2017 Saudi Journal of Anesthesia | Published by Wolters Kluwer - Medknow