

# Diagnostic performance of anterior segment optical coherence tomography in detecting plateau iris

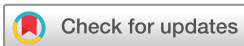Boonsong Wanichwecharungruang,<sup>1,2</sup> Warisara Pattanapongpaiboon,<sup>1</sup> Kittipong Kongsomboon,<sup>3</sup> Nucharee Parivisutt,<sup>1</sup> Kornkamol Annopawong,<sup>1</sup> Kasem Seresirikachorn <sup>1,2</sup>

## To cite:

Wanichwecharungruang B, Pattanapongpaiboon W, Kongsomboon K, *et al*. Diagnostic performance of anterior segment optical coherence tomography in detecting plateau iris. *BMJ Open Ophthalmology* 2022;**7**:e000931. doi:10.1136/bmjophth-2021-000931

► Additional supplemental material is published online only. To view, please visit the journal online (<http://dx.doi.org/10.1136/bmjophth-2021-000931>).

Received 6 November 2021  
Accepted 10 March 2022



© Author(s) (or their employer(s)) 2022. Re-use permitted under CC BY-NC. No commercial re-use. See rights and permissions. Published by BMJ.

<sup>1</sup>Ophthalmology, Rajavithi Hospital, Bangkok, Thailand

<sup>2</sup>Ophthalmology, Rangsit University College of Medicine, Mueang Pathum Thani, Thailand  
<sup>3</sup>Preventive and Social Medicine, Srinakharinwirot University, Nakhon Nayok, Thailand

## Correspondence to

Dr Kasem Seresirikachorn;  
Kasemseresirikachorn@gmail.com

## ABSTRACT

**Objective** To evaluate the diagnostic performance of manual grading of anterior segment optical coherence tomography (AS-OCT) in detection of plateau iris configuration (PIC) based on the presence of standardised ultrasound biomicroscopy (UBM) criteria in at least two quadrants; namely, clinical diagnosis of PIC (DxPIC).

**Methods and analysis** In this cross-sectional study, paired AS-OCT and UBM images were evaluated by three glaucoma specialists. AS-OCT was classified into two mechanisms, PIC versus non-PIC, of primary angle closure disease (PACD) and AS-OCT-PIC diagnostic performance was tested with DxPIC.

**Results** One hundred and seventy-nine eyes of 142 patients were enrolled for analysis, and DxPIC was found in 85 eyes (47.49%). Intraobserver agreement rates of AS-OCT classification by the graders were 0.77, 0.701 and 0.742 (all  $p < 0.001$ ), and interobserver agreement rates, between a senior glaucoma specialist and the other two glaucoma specialists, were 0.68 and 0.702 (all  $p < 0.001$ ). Plateau iris was classified in AS-OCT images by the three graders, rated 32.96%–39.1% and 24.58%–34.08% in the horizontal and vertical axes, respectively. Diagnostic performance was analysed, yielding sensitivity ranging from 56.47% to 77.78%, and specificity of 48.94% to 64.29%. We applied disease prevalence of 30%, revealing positive predictive values varying from 32.16% to 44.44%, and negative predictive values of 72.4% to 85.71%. Accuracy ranged from 51.2% to 65%. Agreement between the two devices was fair, kappa range 0.31–0.351.

**Conclusion** Performance of manual grading of AS-OCT in detection of DxPIC was relatively poor; therefore, unadjusted AS-OCT does not appear to be good for manual PIC screening in PACD patients and cannot serve as a substitute for UBM in PIC detection.

Primary angle-closure disease (PACD) is multifactorial,<sup>1</sup> and anatomical disorders of a relatively small eye play roles in its pathophysiology.<sup>2</sup> Gonioscopy is an essential tool for diagnosis and monitoring of disease progression. Iris convexity indicates pupillary block (PB) mechanism, where the posterior chamber pressure is higher than that of the anterior chamber. Double hump sign on indentation gonioscopy indicates plateau iris configuration

## Key messages

### What is already known on this topic?

► Anterior segment optical coherence tomography (AS-OCT) has been qualitatively applied for classification of plateau iris; however, its diagnostic performance has never been validated with ultrasound biomicroscopy (UBM) criteria.

### What this study adds?

► Under three glaucoma specialist graders, the accuracy of AS-OCT in detection of plateau iris (UBM criteria) was found to range from 51.2% to 65%. Agreement between the two devices was fair, with kappa range of 0.31–0.351.

### How this study might affect research, practice or policy?

► Manual grading of AS-OCT plateau iris appears to be a misnomer and cannot substitute for UBM in detection of plateau iris in clinical practice.

(PIC),<sup>3</sup> where the lens and ciliary body support the central and peripheral iris. Volcano crater appearance indicates anteriorly positioned lens while totally flat anterior chamber may indicate malignant glaucoma or a posterior to the lens pushing mechanism. One limitation of the gonioscopy technique is that it requires an experienced operator because it entails contact with the eye, resulting in discomfort during examination. Interpretation is relatively subjective, and quantitative evaluation is also limited with this tool.

Imaging technology has been developed and enhanced, and it is employed for PACD evaluation in qualitative and quantitative measurement. Ultrasound biomicroscopy (UBM) and anterior segment optical coherence tomography (AS-OCT) are the two systems which are commonly used in glaucoma for assessment of anterior chamber angle (ACA),<sup>4–8</sup> and classification of the disease mechanism can be based on the findings of either technique. Ritch *et al* used UBM

to classify PACD based on anatomic levels; namely, iris, ciliary body, lens and posterior to lens levels,<sup>9</sup> which are related to PB mechanism, PIC,<sup>10 11</sup> and phacomorphic and malignant glaucoma,<sup>12</sup> respectively. Shabana *et al* used AS-OCT to classify PACD as a PB mechanism, PIC, thick peripheral iris roll (TPIR), or exaggerated lens vault (ELV).<sup>13</sup> The two imaging systems display similar mechanisms of PB and PIC, but the consistency between the devices has been sparsely evaluated. Zhang *et al* employed AS-OCT reference images of the four mechanisms and tested the agreement of AS-OCT with UBM for PIC in 40 patients, reporting kappa of 0.87.<sup>14</sup> We speculated that AS-OCT-classified PIC (AS-OCT-PIC) could possibly be employed to screen for standard UBM-classified PIC (UBM-PIC) in clinical practice, and we tested the diagnostic performance of AS-OCT-PIC classification with our PACD pair images from UBM and AS-OCT.

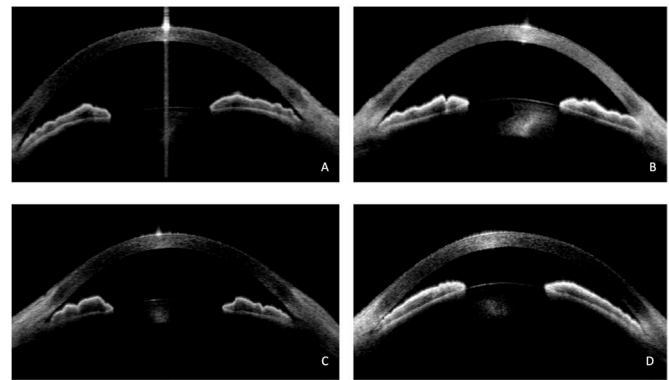
## METHODS

The present research was an associated study of the imaging in PIC described elsewhere.<sup>15</sup> In brief, it was a cross-sectional study of the performance of AS-OCT in detection of PIC based on standardised UBM criteria, undertaken at a tertiary eye care centre in Rajavithi Hospital. All investigations were carried out in accordance with the Declaration of Helsinki, and neither patients nor the public were involved in the design, conduct, reporting or dissemination plans of our research.

We enrolled phakic patients with PACD for UBM and AS-OCT investigation. PACD, including primary angle-closure suspect (PACS), PAC, and PAC glaucoma (PACG), were defined in accordance with the International Society of Geographical and Epidemiological Ophthalmology (ISGEO) classification by Foster *et al*.<sup>16</sup> Exclusion criteria were individuals who could not be evaluated with both devices, such as patients with corneal opacity. Subjects with pseudophakia, secondary angle-closure, postglaucoma surgery and post argon laser peripheral iridoplasty (ALPI) were excluded.

Complete ocular examinations including visual acuity, slit lamp evaluation of anterior eye segment, Goldmann applanation tonometry, dynamic gonioscopy and fundus ophthalmoscopy were performed by glaucoma specialists and clinical fellows, and diagnosis was made by a senior glaucoma specialist. Since our objective was focused on PIC detection, we performed laser peripheral iridotomy (LPI) to break PB in all patients at least 1 month before scanning with the two imaging systems. PACD patients who had residual angle closure in which the trabecular meshwork could not be seen by gonioscopy for at least 180° were included for UBM and AS-OCT examination.

AS-OCT (Visante, V.3.0.1.8, Carl Zeiss Meditec, Dublin, California, USA) was first performed by an experienced operator in the sitting position for horizontal and vertical axes in a standard room light (230lux). During vertical scanning, upper and lower lids were held gently, avoiding inadvertent ocular compression. The patient was placed in the supine position and UBM, Paradigm 60 or VuMAX HD (Sonomed



**Figure 1** (A) Pupillary block-like: convex iris with appositional angle with rather deep anterior chamber. (B) Plateau iris configuration: peripheral iris rising up from iris root with flat iris centrally and normal anterior chamber depth. (C) Thick peripheral iris roll: multiple rolls of anterior iris stroma with appositional angle. (D) Exaggerated lens vault: anteriorly positioned lens with marked shallow anterior chamber.

Escalon, Lake Success, NY) scanning was performed by a trained research fellow (WP) who had 2 years' experience of using this device. Immersion with water eyecup was gently performed to avoid unintentional ocular compression, followed by scanning in the superior, inferior, nasal and temporal quadrants. All images were deidentified and transferred to a personal computer.

UBM-PIC was defined as anteriorly-positioned ciliary process, absence of ciliary sulcus and peripheral iris root angulation with flat iris centrally, whereas non-PIC was assumed when these criteria were not fulfilled. UBM quadrant-wise images were classified by a senior glaucoma specialist (BW) as either PIC or non-PIC. Intraobserver agreement was assessed for reproducibility of the classification on 30 images, kappa=0.79. Interobserver agreements were tested by two glaucoma specialists (KS and NP), with kappa=0.71 and 0.73, respectively.<sup>15</sup> At eye level, UBM-PIC in at least two quadrants was defined as diagnosis of PIC (DxPIC).

AS-OCT images were separately classified by three glaucoma specialists, graders 1–3 (BW, KS and NP, respectively). Four mechanisms of PACD are shown in figure 1: PB-like (figure 1A), PIC (figure 1B), TPIC (figure 1C) and ELV (figure 1D). AS-OCT-PIC was defined as peripheral iris root angulation with flat iris centrally and normal ACD. If the two quadrants of axis images did not show the same mechanism, forced classification of the dominant mechanism was performed.

## Statistics

We tested sensitivity, specificity and accuracy of AS-OCT for prediction of DxPIC. Positive predictive values (PPV) and negative predictive values (NPV) were also tested, with an estimated disease prevalence of PIC of 30%.<sup>17 18</sup> Statistical analysis was performed with SPSS V.20 (SPSS) and Medcalc ([https://www.medcalc.org/calc/diagnostic\\_test.php](https://www.medcalc.org/calc/diagnostic_test.php), accessed 22 March 2021).

**Table 1** Axis-wise AS-OCT classification of plateau iris mechanism

AS-OCT classifications	Grader 1, N (%)	Grader 2, N (%)	Grader 3, N (%)	Total PACD, N (%)
PIC (horizontal)	70 (39.1)	59 (32.96)	68 (37.99)	179 (100)
PIC (vertical)	51 (28.49)	44 (24.58)	61 (34.08)	179 (100)

AS-OCT, anterior segment optical coherence tomography; PACD, primary angle closure disease; PIC, plateau iris configuration.

Kappa ( $\kappa$ ) represents agreement between the classifications of the two devices, defined as: 0–0.2 slight agreement; 0.21–0.4, fair agreement; 0.41–0.6, moderate agreement; 0.61–0.8, substantial agreement; greater than 0.81, highest agreement.<sup>19</sup>

## RESULTS

One hundred and seventy-nine eyes from 142 patients were enrolled for analysis. Mean age (SD) was 62.45 (8.5) years, females accounted for 76.80% of participants, and half of the eyes were diagnosed as PACG. Demographic data are shown in online supplemental table 1.

Seven hundred and sixteen quadrants from 179 eyes were scanned by UBM. UBM-PIC was most commonly found in the temporal quadrant at 50.84%, and the least common locations were the inferior and nasal quadrants at 32.40% each. The numbers of cases of UBM-PIC by quadrant are shown in online supplemental table 2. DxPIC was observed in 85 eyes (47.49%).

Intraobserver agreement of PACD mechanism classification in 40 images of AS-OCT tested by graders 1, 2 and 3 revealed kappa of 0.77, 0.701 and 0.742 (all  $p < 0.001$ ), respectively. Interobserver agreement was tested between graders 2 (KS) and 1 (BW), with kappa of 0.68 ( $p < 0.001$ ), and between graders 3 (NP) and 1 (BW), with kappa of 0.702 ( $p < 0.001$ ).

Plateau iris was classified in AS-OCT images by the three graders and rated at 32.96%–39.1% in the horizontal axis and 24.58%–34.08% in the vertical axis (table 1).

Diagnostic performance of AS-OCT in detection of DxPIC by the three graders is shown in table 2. Sensitivity ranged from 56.47% to 77.78%, and specificity from 48.94% to 64.29%. Applying disease prevalence of 30%,<sup>18</sup> PPV varied from 32.16% to 44.44%, and NPV from 72.4%

to 85.71%. Accuracy ranged from 51.2% to 65%. Agreement between AS-OCT and DxPIC of the graders was fair, with kappa ranging from 0.31 to 0.351.

We demonstrated examples of pair images of PIC detection, as correct, false positive or false negative in online supplemental figures.

## DISCUSSION

AS-OCT classification is a qualitative evaluation which uses iris configuration, ACD, and lens position to test the mechanisms of PACD, PIC versus non-PIC, in patients who have not had previous iridotomy/iridectomy. Different investigators have revealed varying proportions of these mechanisms; for instance, Zhang *et al*<sup>14</sup> reported that AS-OCT-PIC was the most common mechanism of PACD at 36.1%, whereas others have reported it at 15.5%, 23% and 3.4%.<sup>8 13 20</sup>

In this study, AS-OCT-PIC was classified by the 3 graders at 32%–39% and 24%–32% in the horizontal and vertical axes, respectively. The rate of AS-OCT-PIC appeared similar to that of standardised UBM criteria (DxPIC) in previous studies. Kumar *et al* reported the prevalence of plateau iris at 30% in PACS and PACG in South-East Asian patients,<sup>17 18</sup> while in a study in Japan, it was found in 20% of cases of PAC and PACG.<sup>21</sup> In Indian patients, plateau iris was found in 31.7% of PACG,<sup>22</sup> whereas in our previous report, it was found in 47.5% of PACD cases.<sup>15</sup> The accuracy of manual grading of AS-OCT was relatively low, however, at 51%–65%, indicating a discrepancy between AS-OCT and UBM, the latter being the reference standard for PIC classification in the literature. Anteriorly positioned ciliary body with an absence of ciliary sulcus, pushing the peripheral iris forward as a plateau, is a hallmark sign of PIC. Since AS-OCT displays only anterior iris configuration as a plateau, without any sign of the ciliary body, it could lead to incorrect PIC classification.

**Table 2** Performance of AS-OCT in prediction of clinical diagnosis of plateau iris

Statistic	Grader 1		Grader 2		Grader 3	
	Value	95% CI	Value	95% CI	Value	95% CI
Sensitivity	66.67%	51.05% to 80.00%	77.78%	62.91% to 88.80%	56.47%	45.28% to 67.20%
Specificity	64.29%	48.03% to 78.45%	57.14%	40.96% to 72.28%	48.94%	38.48% to 59.46%
Positive likelihood ratio	1.87	1.18 to 2.94	1.81	1.24 to 2.66	1.11	0.84 to 1.45
Negative likelihood ratio	0.52	0.32 to 0.83	0.39	0.21 to 0.71	0.89	0.65 to 1.22
Disease prevalence	30.00%		30.00%		30.00%	26.53% to 38.35%
Positive predictive value	44.44%	33.66% to 55.78%	43.75%	34.66% to 53.28%	32.16%	65.61% to 78.29%
Negative predictive value	81.82%	73.76% to 87.81%	85.71%	76.60% to 91.67%	72.40%	43.63% to 58.72%
Accuracy	65.00%	54.03% to 74.92%	63.33%	52.32% to 73.41%	51.20%	45.28% to 67.20%
Kappa	0.310, $p < 0.004$		0.351, $p < 0.001$		0.334, $p < 0.002$	

AS-OCT, anterior segment optical coherence tomography.



There are some possible explanations for the discrepancies between the detection of PIC with the two devices. First, AS-OCT classification is a subjective evaluation. Posterior pushing of the ciliary body might have a slight effect on the peripheral iris configuration; for example, indentation gonioscopy is needed to demonstrate the double hump sign of PIC. Neither gonioscopy nor AS-OCT can visualise the ciliary process directly. Appositional ACA (PB-like, TPIR and ELV), without peripheral corneal indentation, cannot rule out PIC mechanism. By contrast, UBM-PIC classification directly focuses on the ciliary body position and is thereby able to disclose PIC in other mechanisms hidden in AS-OCT images.

Second, some AS-OCT images showed mixed mechanisms in one axis, and forced classification of the dominant mechanism could have led to incorrect predictions; furthermore, the existing mechanisms of PACD might not include others which have yet to be identified. Third, AS-OCT iris configuration represents the iris stroma, which is a dynamic structure and can be affected by pupillary movement; furthermore, iris crypt and furrow resemble peripheral iris in appearance, and they can mimic the angulation of PIC. Fourth, patient position is different for the devices, and the supine position could have induced ocular cyclotorsion, so that the UBM scanning area might not have exactly matched the AS-OCT scanning one. In addition, the supine position in UBM scanning could have altered the ACA of these aged patients,<sup>23</sup> and different scanning positions could have resulted in a different classification of PACD mechanisms.

Shabana *et al* addressed the hypothesis that AS-OCT-PIC did not identify plateau iris syndrome caused by anteriorly positioned ciliary body.<sup>13</sup> AS-OCT classification was applied for evaluation of iris changes from mydriasis,<sup>14</sup> acute angle closure,<sup>8</sup> and long-term monitoring of ACA,<sup>20</sup> but these studies did not check the findings of PIC with the use of UBM. AS-OCT is a non-contact imaging system for rapid scanning and achieves a high image resolution, but although it has potential as a screening method for PACD, it achieved weak agreement with gonioscopy in evaluation of angle closure, at kappa 0.4.<sup>24</sup> Its diagnostic performance for angle closure detection compared with that of gold standard gonioscopy in 200 patients revealed sensitivity of 98% and specificity of 55.4%,<sup>25</sup> so that in terms of specificity, AS-OCT did not appear to be a good screening tool for PACD.

In this study, we simplified AS-OCT-PIC criteria for detection of clinical diagnosis UBM criteria, and axis to axis matching of the two devices was not necessary for determination of PIC. As its sensitivity and specificity were below 80%, it appeared not to be a good tool for screening PIC either. Negative predictive value was relatively high, however, at 72.40%–85%, which indicates that it might be useful in ruling out DxPIC.

PIC screening is crucial, as this mechanism is the most common cause of angle closure in younger patients in the USA.<sup>26</sup> The presence of PIC in Asian eyes is not uncommon, with a prevalence varying from 20% to 48%. Proper diagnosis, monitoring and management can help prevent the consequences of PIC, such as peripheral anterior synechia

(PAS) formation and IOP elevation, which can lead to visual field loss and optic nerve damage. ALPI has proven its efficacy and safety in treatment of PIC.<sup>27,28</sup> Glaucoma surgery in PIC carries a higher risk of malignant glaucoma<sup>29</sup>; therefore, patients should be informed about this risk, and surgeons should be aware of this potentially devastating complication.

Computer-aided technology of deep learning (DL) may be helpful in screening for this subtype of PACD. We previously reported the good performance of DL of AS-OCT in detecting PIC in the same dataset.<sup>15</sup> The AUC-ROC was 0.95 (95% CI=0.91 to 0.99), sensitivity was 87.9%, and specificity was 97.6%. A heatmap of DL highlighted an area behind the peripheral iris which resembled anteriorly positioned ciliary process in PIC. The Blackbox of DL, as shown in heatmap figures, might have detected anterior indentation by the ciliary process at that area, and image augmentation might have enhanced visibility of that indentation. Moreover, transfer learning of UBM and AS-OCT could enhance the visibility of the ciliary body, resulting in good prediction of PIC by AS-OCT. However, external validation of our DL algorithm should be tested prior to deployment to real-world application.

This study had both strengths and limitations, with its strengths including the fact that all eyes were evaluated with both imaging systems to test for the PIC mechanism, and that all participants underwent LPI before scanning. DxPIC was based on the standardised UBM criteria generally used in PIC studies; in fact, PIC should be diagnosed after PB is relieved. AS-OCT was performed in both axes in order to match the 4 quadrants of the UBM scans.

The study's limitations included its relatively small sample size. We performed UBM scanning using the immersion technique in supine position, as in the reference standard studies,<sup>17,18</sup> whereas AS-OCT was scanned with patients in the sitting position. Even though UBM scanning can be performed with a water-filled bag (condom type) in a sitting position, we notice that the quality of image was not as good as the immersion one. PAS affects the irido-corneal angle appearance, and this could have obscured the peripheral iris angulation of PIC, leading to another mechanism classification. AS-OCT classification in our study might not fit the original one of Shabana<sup>13</sup>; in fact, the term 'AS-OCT-PIC' appears to be a misnomer, and we suggest instead 'steep peripheral iris' for AS-OCT. We did not perform quantitative evaluation of these images, which might have shown additional information for prediction. As this study was clinic-based, the proportional rates reported do not represent the general population, and further research is needed to evaluate manual grading of AS-OCT in PIC screening.

In conclusion, based on standardised UBM criteria, the performance of manual grading of AS-OCT for prediction of plateau iris was relatively poor; therefore, unadjusted AS-OCT images do not appear suitable for manual PIC screening. As the AS-OCT system has been growing in popularity in glaucoma evaluation, the term 'AS-OCT-PIC' might mislead clinicians regarding the real mechanism of PACD, and we recommend that it be renamed 'steep peripheral

iris' in order to differentiate it from standard UBM-PIC classification. The different imaging systems were related to these discrepancies; thus, manual grading AS-OCT cannot serve as a substitute for UBM in detection of plateau iris.

**Acknowledgements** We would like to thank John Flanagan for English proofreading of this manuscript.

**Contributors** BW: substantial contributions to the conception or design of the work; acquisition, analysis, or interpretation of data for the work; drafting the work or revising it critically for important intellectual content; final approval of the version to be published; agreement to be accountable for all aspects of the work in ensuring that questions related to the accuracy or integrity of any part of the work are appropriately investigated and resolved. WP: substantial contributions to the conception or design of the work; acquisition, analysis or interpretation of data for the work; agreement to be accountable for all aspects of the work in ensuring that questions related to the accuracy or integrity of any part of the work are appropriately investigated and resolved. KK: substantial contributions to the conception or design of the work; Acquisition, analysis, or interpretation of data for the work. NP: substantial contributions to the conception or design of the work; acquisition, analysis or interpretation of data for the work. KA: substantial contributions to the conception or design of the work; acquisition, analysis or interpretation of data for the work. KS: substantial contributions to the conception or design of the work; acquisition, analysis, or interpretation of data for the work; drafting the work or revising it critically for important intellectual content; final approval of the version to be published; agreement to be accountable for all aspects of the work in ensuring that questions related to the accuracy or integrity of any part of the work are appropriately investigated and resolved.

**Funding** This study was supported by Rajavithi Research Fund No. 64172/2564.

**Competing interests** None declared.

**Patient and public involvement** Patients and/or the public were not involved in the design, or conduct, or reporting, or dissemination plans of this research.

**Patient consent for publication** Not applicable.

**Ethics approval** The protocol was approved by the Ethics Committee of Rajavithi Hospital (Document No. 64172/2564). Informed consent was waived, and data were analysed anonymously.

**Provenance and peer review** Not commissioned; externally peer reviewed.

**Data availability statement** Data are available on reasonable request. Not applicable.

**Supplemental material** This content has been supplied by the author(s). It has not been vetted by BMJ Publishing Group Limited (BMJ) and may not have been peer-reviewed. Any opinions or recommendations discussed are solely those of the author(s) and are not endorsed by BMJ. BMJ disclaims all liability and responsibility arising from any reliance placed on the content. Where the content includes any translated material, BMJ does not warrant the accuracy and reliability of the translations (including but not limited to local regulations, clinical guidelines, terminology, drug names and drug dosages), and is not responsible for any error and/or omissions arising from translation and adaptation or otherwise.

**Open access** This is an open access article distributed in accordance with the Creative Commons Attribution Non Commercial (CC BY-NC 4.0) license, which permits others to distribute, remix, adapt, build upon this work non-commercially, and license their derivative works on different terms, provided the original work is properly cited, appropriate credit is given, any changes made indicated, and the use is non-commercial. See: <http://creativecommons.org/licenses/by-nc/4.0/>.

#### ORCID iD

Kasem Seresirikachorn <http://orcid.org/0000-0001-7963-5591>

#### REFERENCES

- Ritch R, Lowe RF. Angle-closure glaucoma: mechanisms and epidemiology. In: Ritch R, Shields MB, Krupin T, eds. *The glaucomas*. v. 2nd. St Louis: Mosby, 1996.
- Lowe RF. Primary angle-closure glaucoma. inheritance and environment. *Br J Ophthalmol* 1972;56:13–20.
- Forbes MAX. Gonioscopy with corneal indentation. *Arch Ophthalmol* 1966;76:488–92.
- Pavlin CJ, Harasiewicz K, Sherar MD, et al. Clinical use of ultrasound biomicroscopy. *Ophthalmology* 1991;98:287–95.
- Pavlin CJ, Foster FS. Ultrasound biomicroscopy in glaucoma. *Acta Ophthalmol Suppl* 1992;204:7–9.
- Radhakrishnan S, Rollins AM, Roth JE, et al. Real-Time optical coherence tomography of the anterior segment at 1310 nm. *Arch Ophthalmol* 2001;119:1179–85.
- Dorairaj S, Tsai JC, Grippo TM. Changing trends of imaging in angle closure evaluation. *ISRN Ophthalmol* 2012;2012:1–7.
- Moghimi S, Zandvakil N, Vahedian Z, et al. Acute angle closure: qualitative and quantitative evaluation of the anterior segment using anterior segment optical coherence tomography. *Clin Exp Ophthalmol* 2014;42:615–22.
- Ritch R, Liebmann J, Tello C. A construct for understanding angle of closure glaucoma: the role of ultrasound biomicroscopy. *Ophthalmology Clinics of North America* 1995;8:281–93.
- Pavlin CJ, Ritch R, Foster FS. Ultrasound biomicroscopy in plateau iris syndrome. *Am J Ophthalmol* 1992;113:390–5.
- Ritch R. Plateau iris is caused by abnormally positioned ciliary processes. *J Glaucoma* 1992;1:23–6.
- Trope GE, Pavlin CJ, Bau A, et al. Malignant glaucoma. Clinical and ultrasound biomicroscopic features. *Ophthalmology* 1994;101:1030–5.
- Shabana N, Aquino MCD, See J, et al. Quantitative evaluation of anterior chamber parameters using anterior segment optical coherence tomography in primary angle closure mechanisms. *Clin Exp Ophthalmol* 2012;40:792–801.
- Zhang Y, Li SZ, Li L, et al. Quantitative analysis of iris changes following mydriasis in subjects with different mechanisms of angle closure. *Invest Ophthalmol Vis Sci* 2015;56:563–70.
- Wanichwecharungruang B, Kaothanthong N, Pattanapongpaiboon W, et al. Deep learning for anterior segment optical coherence tomography to predict the presence of plateau iris. *Transl Vis Sci Technol* 2021;10:7.
- Foster PJ, Buhmann R, Quigley HA, et al. The definition and classification of glaucoma in prevalence surveys. *Br J Ophthalmol* 2002;86:238–42.
- Kumar RS, Baskaran M, Chew PTK, et al. Prevalence of plateau iris in primary angle closure suspects an ultrasound biomicroscopy study. *Ophthalmology* 2008;115:430–4.
- Kumar RS, Tantisevi V, Wong MH, et al. Plateau iris in Asian subjects with primary angle closure glaucoma. *Arch Ophthalmol* 2009;127:1269–72.
- Fleiss JL. *Statistical methods for rates and proportions*. 2nd ed. New York: John Wiley, 1981.
- Kwon J, Sung KR, Han S. Long-Term changes in anterior segment characteristics of eyes with different primary angle-closure mechanisms. *Am J Ophthalmol* 2018;191:54–63.
- Mizoguchi T, Ozaki M, Wakiyama H, et al. Plateau iris in Japanese patients with primary angle closure and primary angle closure glaucoma. *Clin Ophthalmol* 2015;9:1159–63.
- Mansoori T, Sarvepally VK, Balakrishna N. Plateau iris in primary angle closure glaucoma: an ultrasound biomicroscopy study. *J Glaucoma* 2016;25:e82–6.
- Bell NP, Nagi KS, Cumba RJ, et al. Age and positional effect on the anterior chamber angle: assessment by ultrasound biomicroscopy. *ISRN Ophthalmol* 2013;2013:1–5.
- Sakata LM, Lavanya R, Friedman DS, et al. Comparison of gonioscopy and anterior segment ocular coherence tomography in detecting angle closure in different quadrants of the anterior chamber angle. *Ophthalmology* 2008;115:769–74.
- Nolan WP, See JL, Chew PTK, et al. Detection of primary angle closure using anterior segment optical coherence tomography in Asian eyes. *Ophthalmology* 2007;114:33–9.
- Ritch R, Chang BM, Liebmann JM. Angle closure in younger patients. *Ophthalmology* 2003;110:1880–9.
- Ritch R, Tham CCY, Lam DSC. Long-Term success of argon laser peripheral iridoplasty in the management of plateau iris syndrome. *Ophthalmology* 2004;111:7802443:104–8.
- Ritch R, Tham CCY, Lam DSC. Argon laser peripheral iridoplasty (ALPI): an update. *Surv Ophthalmol* 2007;52:279–88.
- Prata TS, Dorairaj S, De Moraes CGV, et al. Is preoperative ciliary body and iris anatomical configuration a predictor of malignant glaucoma development? *Clin Exp Ophthalmol* 2013;41:541–5.