

This is an Open Access article licensed under the terms of the Creative Commons Attribution-NonCommercial-NoDerivs 3.0 License (www.karger.com/OA-license), applicable to the online version of the article only. Distribution for non-commercial purposes only.

Invasive Recurrence of an Intestinal-Type Mucinous Epithelial Neoplasm of Low Malignant Potential: Case Report and Review of the Literature

S. Cosyns^a M. Leyder^b C. Bourgain^c P. De Sutter^a

Departments of ^aGynecology-Oncology, ^bGynecology, and ^cPathology, University Hospital Brussels, Brussels, Belgium

Key Words

Borderline ovarian tumor, low malignant potential · Borderline ovarian tumor, mucinous · Borderline ovarian tumor, intestinal-type · Invasive recurrence

Abstract

Pseudomyxoma peritonei is only rarely seen in conjunction with primary ovarian tumors. It has been suggested that only ruptured mucinous tumors arising in ovarian mature cystic teratomas can result in this clinical picture. We describe a case of a late invasive recurrence of a mucinous intestinal-type borderline ovarian tumor arising from a mature teratoma after complete surgical debulking. Borderline ovarian tumors behave indolently in the overwhelming majority of cases, and the prognosis is therefore usually outstanding.

Introduction

Pseudomyxoma peritonei (PMP) is a rare entity characterized by mucinous ascites, peritoneal implants of mucin and abdominal neoplasms. PMP diagnosed pathologically as disseminated peritoneal adenomucinosis (DPAM) is only rarely seen in conjunction with primary ovarian tumors [1]. Some authors claim that only ruptured mucinous tumors arising in ovarian mature cystic teratomas, which likely arise from endoderm-derived elements of the teratoma, can result in a clinical picture of PMP [1, 2]. The recurrence risk of mucinous tumors arising in ovarian teratomas, particularly those with associated PMP, is not known [3].

We encountered a late invasive recurrence of a mucinous intestinal-type ovarian borderline tumor arising from a mature teratoma after complete surgical debulking.

Case Report

We describe a case of a 59-year-old woman with an uneventful medical history, apart from morbid obesity (body mass index of 48). She presented with abdominal fullness, umbilical herniation and dyspnea. CT scan revealed an ovarian mass and ascites. Cancer antigen 125 (CA125) tumor marker analysis was below detection threshold. Surgical exploration by median laparotomy showed widespread gelatinous mucinous ascites (PMP) and a huge ruptured right ovarian tumor of 30 cm in diameter. The patient underwent a subtotal abdominal hysterectomy, bilateral salpingo-oophorectomy, appendectomy, omentectomy, umbilical herniorrhaphy and resection of all visible mucinous deposits. Anatomopathological examination revealed a ruptured right ovary with a mucinous borderline cystadenocarcinoma arising within a mature teratoma and a DPAM in accordance with Ronnett [1]. It contained a multiloculated mucinous cystic tumor within which a 12-cm mature cystic teratoma was embedded. Microscopically, multiple cysts were seen covered with mucinous epithelium. Goblet cells were seen as well as pseudo-multiple layered epithelium. Focally the stroma had a myxoid aspect. In some sections the ectodermal component was present. Coexpression of CK 7 and CK20 was noticed by immunohistochemistry (fig. 1, fig. 2).

The left ovary was uninvolved. The ascites and peritoneal implants were composed of abundant mucin devoid of mucinous epithelium. The appendix was examined histologically and was found to be entirely normal. Omentum, umbilical hernia sac and mesoappendix were found to contain mucin pools.

The postoperative recovery was uneventful. No adjuvant therapy was given subsequently. Radiological imaging three months after surgery indicated neither the presence of ascites nor tumoral relapse. The patient moved abroad and was lost for follow-up. Fifty-four months postoperatively she was again seen at the outpatient clinic with complaints of an umbilical hernia increasing in size over the past year. Clinically the patient presented with a hard spherical mass in the umbilical hernia sac measuring 14 cm. CA125 tumor marker testing was still negative. An abdominal CT scan showed a diffuse intra-abdominal collection also spreading through the umbilical herniation forming a spherical subcutaneous mass. A relapse of pseudomyxoma, with peritoneal carcinomatosis and a bulging umbilical hernia containing mucinous pools, was suspected (fig. 3, fig. 4).

Surgical exploration revealed a massive umbilical herniation filled by a solid mucinous tumor, attached to the abdominal fascia. After surgical resection, approximately 10 liters of gelatinous mucinous ascites was drained. Inspection of the peritoneal cavity demonstrated disseminated peritoneal carcinomatosis with invasive implants widespread on the peritoneum, small intestine, colon, diaphragm, liver and stomach. One further solitary nodule of 10 cm on the colon ascendens was resected. The umbilical hernia sac was resected and the abdominal fascia was closed classically.

After a partial resection of the rectal fascia to liberate the hard spherical mass, a complete surgical debulking was judged to be technically impossible. The abdominal wall was sutured by using two Ventrofil® (B. Braun, Melsungen, Germany) sutures for prevention of abdominal wound dehiscence in this obese patient.

Anatomopathological examination showed multiple metastases of a mucinous cystadenocarcinoma. At microscopic examination the metastases showed large pools filled with mucin enveloped by smooth connective tissue while the hard spherical mass consisted of small mucinous pools incorporated within dense fibrous tissue partitions.

Postoperatively no major wound complication occurred and 6 weeks later the first cycle of Carboplatinum-Taxol chemotherapy was started. She completed 6 cycles of chemotherapy, but passed away only one month later.

Discussion

10% of ovarian epithelial tumors consist of mucinous tumors. The vast majority of mucinous tumors are benign (75%), 10% borderline and 15% invasive carcinomas [4]. Mucinous tumors histologically resemble endocervical epithelium. They tend to remain confined to the ovaries for a longer period of time than serous carcinomas and are the largest epithelial ovarian neoplasms, with a median diameter of up to 20 cm. CA125 levels may not be markedly elevated, but tend to reflect the course of the disease. Three histopathological groups of mucinous tumors have been described: mucinous cystadenoma, mucinous tumor of uncertain malignant potential (borderline) and invasive mucinous carcinoma [5].

Mucinous borderline tumors produce large multicystic masses with smooth outer surfaces that may resemble benign mucinous cystadenomas. The majority of these tumors are unilateral, which is an important key to the histological diagnosis, because bilaterality of a mucinous tumor generally indicates the possibility of a metastatic tumor to the ovaries, derived from the appendix or other gastrointestinal sites, the pancreas or the endocervix, rather than a primary ovarian neoplasm. Furthermore, among unilateral tumors, size is an important diagnostic parameter. More than 80% of tumors larger than 10 cm are ovarian primary tumors, whereas 88% of those smaller than 10 cm are metastases [4–7].

Pseudomyxoma peritonei is defined clinically on the basis of intraoperative findings as a grossly visible, localized, or generalized accumulation of mucus in the pelvis or abdomen, either lying on and attached to the peritoneal surfaces or incorporated within dense fibrous tissue [4, 6]. Ruptured mucinous tumors arising in ovarian mature cystic teratomas can produce voluminous ascites and a clinical picture of PMP. These teratomatous ovarian mucinous tumors probably represent the only cases of PMP originating from a primary ovarian tumor [1, 4, 6].

Typically borderline mucinous tumors are heterogeneous. They often contain areas of cystadenoma and noninvasive carcinoma, and occult areas of invasive carcinoma may also coexist. Therefore adequate sampling of mucinous tumors in the histology lab is especially important for the diagnosis. Tumors with a high-grade epithelial component or an unclear level of invasion may require even more thorough sampling. Because of the large size of most borderline mucinous tumors, even extensive sampling may fail to detect a component of invasive carcinoma. Therefore histological samples at one block per centimeter are considered as a minimum [4, 8].

Immunohistochemistry may assist in determining the primary site of a mucinous carcinoma. Primary ovarian mucinous carcinomas are almost always immunoreactive for cytokeratin 7 (CK7) and cytokeratin 20 (CK20) with a predominance of CK7 expression. In contrast, colorectal carcinomas are strongly reactive for CK20 [2, 8]. K-RAS oncogene mutations are seen more frequently in mucinous ovarian carcinomas, whereas BRCA1 and BRCA2 mutations are not. Mutations in the tumor suppressor gene p53, prominently involved in carcinogenesis of serous ovarian tumors, are rarely seen in mucinous tumors of the ovary. The carcinoembryonic antigen (CEA) serum tumor marker, typically associated with gastrointestinal carcinomas, is often elevated in mucinous ovarian tumors, whereas CA125 often remains low [4–8].

Borderline ovarian tumors behave indolently in the overwhelming majority of cases, and the prognosis is therefore usually outstanding. One of the least known aspects of the natural history of borderline tumors is the development of an invasive carcinoma in patients with previous diagnosis of an ovarian borderline tumor. Zanetta et al. described a low risk of progression to invasive carcinoma of approximately 2%, both in mucinous and serous tumors [9]. Conservative management of a low malignant potential ovarian tumor significantly increases the risk of recurrence but does not affect overall survival [10–12].

There is increasing evidence that the pathogenesis of low-grade serous carcinomas and of serous tumors of low malignant potential (i.e., noninvasive borderline tumors) involves similar genes and pathways, and is distinct from that of high-grade serous carcinomas [13]. Clinical observations have been consistent with molecular and genomic investigations. Both tumor types are characterized by a young age at diagnosis and a prolonged natural history [14], and the clinical behavior of borderline tumors that recur as a low-grade invasive serous carcinoma appears similar to that of newly diagnosed low-grade serous carcinomas [15]. These findings have led some authors to believe that low-grade serous ovarian carcinomas are derived from undetected serous ovarian tumors of low malignant potential, although this hypothesis has not been proven.

In the case described here, the clinical and immunohistochemical findings are consistent with a mucinous primary ovarian tumor associated with PMP. Generally recurrences of borderline tumors are treated successfully by surgical debulking [9–12]. In the current case secondary debulking was technically not achievable, hence our decision to start chemotherapy. It is remarkable that an invasive recurrence occurred after ‘optimal’ surgical treatment of a borderline mucinous ovarian tumor. We therefore reiterated our initial histological analysis, but were unable to detect any invasive components in the original borderline tumor specimens. As hypothesized for low-grade serous carcinomas, we assume that mucinous borderline tumors may progress to invasive mucinous neoplasms.

Conclusion

We suggest a careful pathological sampling in case of a mucinous tumor. The use of clinical, pathological and immunohistochemical analyses together with tumor marker assays should help to correctly diagnose primary mucinous ovarian neoplasms. In case of borderline tumors we advocate careful follow-up, especially when a conservative surgical approach is selected. Recurrences can occur even 15 years later. A prolonged clinical follow-up supplemented with transvaginal ultrasound and tumor marker testing is advisable [9]. Even though the recurrence risk of mucinous borderline ovarian tumors is low, awareness of invasive recurrences of mucinous neoplasms is needed.

Acknowledgement

We would like to thank Dr. Devos Michel for his careful revision of the manuscript.

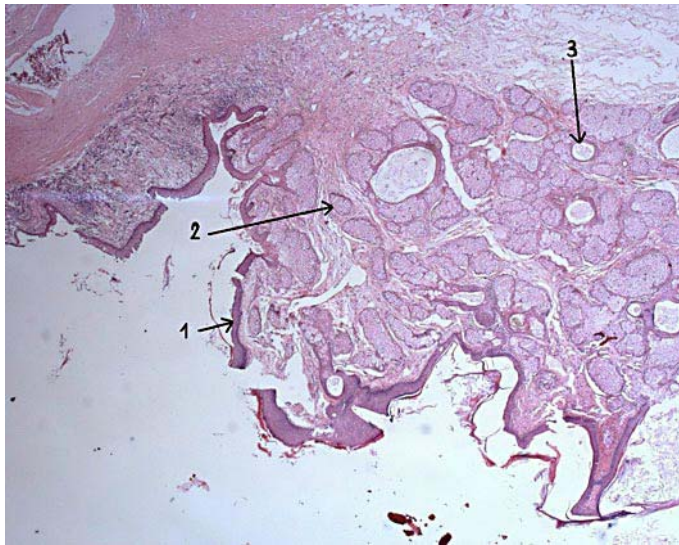


Fig. 1. Dermoid cyst. HES staining ($\times 100$) original magnification. 1: squamous epithelium, keratinized; 2: sebum gland; 3: hair follicle.

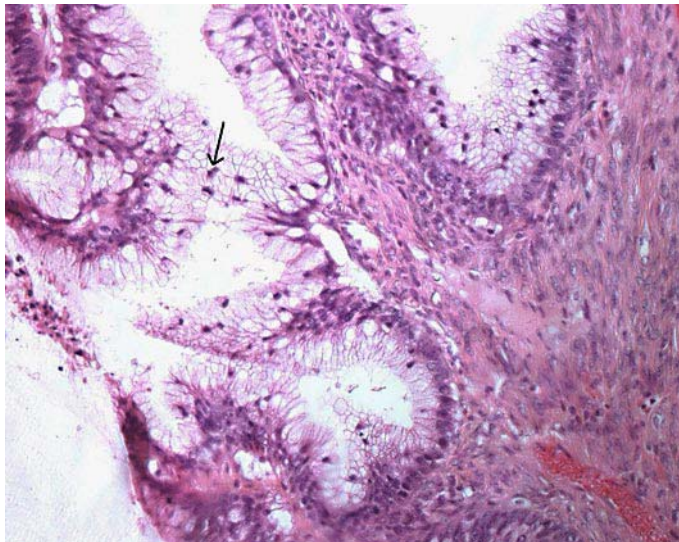


Fig. 2. HES staining ($\times 250$). Gland with atypical mucinous epithelium with crowding pseudostratification and occasional mitotic figures (arrow). No invasion was found.

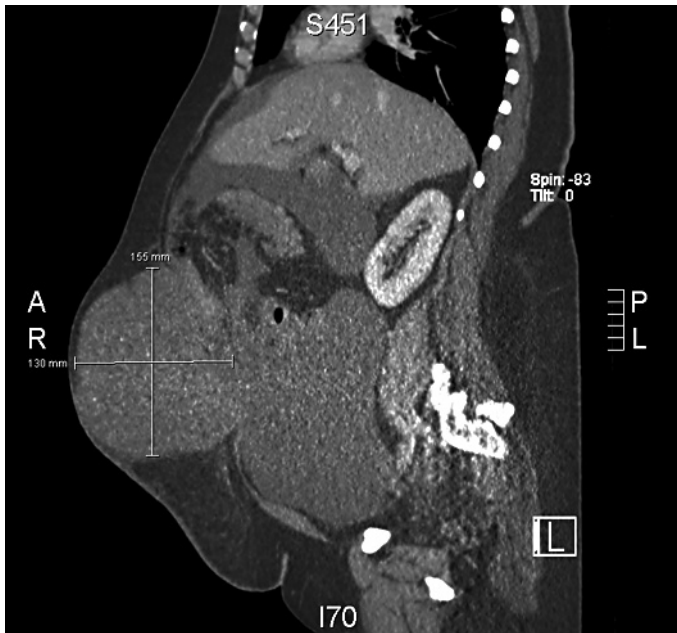

Fig. 3. CT scan: Sagittal view shows a lot of ascites presenting in the lower abdomen and in the huge umbilical herniation.

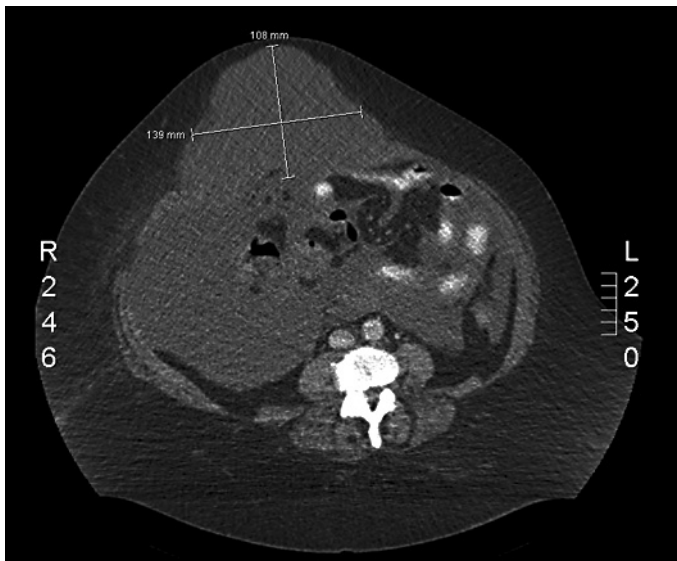


Fig. 4. CT scan: Axial view demonstrating the distribution of ascites and the filling of the umbilical herniation measuring 139 × 108 mm.

References

- 1 Ronnett BM, Seidman JD: Mucinous tumors arising in ovarian mature cystic teratomas: relationship to the clinical syndrome of pseudomyxoma peritonei. *Am J Surg Pathol* 2003;27:650–657.
- 2 Stewart CJ, Tsukamoto T, Cooke B, et al: Ovarian mucinous tumour arising in mature cystic teratoma and associated with pseudomyxoma peritonei: report of two cases and comparison with ovarian involvement by low-grade appendiceal mucinous tumour. *Pathology* 2006;38:534–538.
- 3 McKenney JK, Soslow RA, Longacre TA: Ovarian mature teratomas with mucinous epithelial neoplasms: morphologic heterogeneity and association with pseudomyxoma peritonei. *Am J Surg Pathol* 2008;32:645–655.
- 4 Hart WR: Borderline epithelial tumors of the ovary. *Modern Pathology* 2005;18:33–50.
- 5 Hart WR: Mucinous tumors of the ovary: a review. *Int J Gynecol Pathol* 2005;24:4–25.
- 6 Lee KR, Scully RE: Mucinous tumors of the ovary. *Am J Surg Pathol* 2000;24:1447–1464.
- 7 Seidman JD, Kurman RJ, Ronnett BM: Primary and metastatic mucinous adenocarcinomas in the ovaries: incidence in routine practice with a new approach to improve intraoperative diagnosis. *Am J Surg Pathol* 2003;27:985–993.
- 8 Gilks CB, Prat J: Ovarian carcinoma pathology and genetics: recent advances. *Human Pathology* 2009;40:1213–1223.
- 9 Zanetta G, Rota S, Chiari S, et al: Behavior of borderline tumors with particular interest to persistence, recurrence and progression to invasive carcinoma: a prospective study. *J Clin Oncol* 2001;19:2658–2664.
- 10 Morice P, Camatte S, El Hassan J, et al: Clinical outcomes and fertility after conservative treatment of ovarian borderline tumors. *Fertil Steril* 2001;75:92–96.
- 11 Morice P: Borderline tumours of the ovary and fertility. *Eur J Cancer* 2006;42:149–158.
- 12 Boran N, Pelin A, Tulunay G, et al: Fertility and recurrence results of conservative surgery for borderline ovarian tumors. *Gynecol Oncol* 2005;97:845–851.
- 13 Yasunaga M, Ohishi Y, Oda Y, et al: Immunohistochemical characterization of mullerian mucinous borderline tumors: possible histogenetic link with serous borderline tumors and low-grade endometrioid tumors. *Human Pathology* 2009;40:965–974.
- 14 Dubernard G, Morice P, Rey A, et al: Lymph node spread in stage III or IV primary peritoneal serous papillary carcinoma. *Gynecol Oncol* 2005;97:136–141.
- 15 Dalrymple JC, Bannatyne P, Russell P, et al: Extraovarian peritoneal serous papillary carcinoma. A clinicopathologic study of 31 cases. *Cancer* 1989;64:110–115.