

Medial Patellar Instability

Treatment and Outcomes

Gilbert Moatshe,^{*†‡} MD, Tyler R. Cram,[§] MA, ATC, Jorge Chahla,^{*} MD, PhD, Mark E. Cinque,^{*} MS, Jonathan A. Godin,^{*} MD, MBA, and Robert F. LaPrade,^{*§||} MD, PhD

Investigation performed at the Steadman Clinic and the Steadman Philippon Research Institute, Vail, Colorado, USA

Background: Historically, a lateral retinacular release was one of the primary surgical interventions used to treat lateral patellar instability. However, disruption of the lateral structures during this procedure has been associated with medial instability of the patella.

Hypothesis: We hypothesize that good to excellent outcomes can be achieved at midterm follow-up after lateral patellofemoral ligament reconstruction.

Study Design: Case series; Level of evidence, 4.

Methods: Thirteen patients were treated for medial patellar instability with a lateral patellofemoral ligament reconstruction between May 2011 and December 2013 by a single surgeon. All patients had previously undergone a lateral release procedure and had symptomatic medial patellar instability. Patients were evaluated using patient-reported outcome scores at a minimum of 2 years postsurgery.

Results: The mean Lysholm score improved from 45.6 (range, 11-76) to 71.9 (range, 30-91). The median preoperative Tegner activity scale score was 3 (range, 1-7), while the median postoperative score was 4 (range, 1-9). The median Western Ontario and McMaster Universities Arthritis Index (WOMAC) total score improved from 38 (range, 1-57) preoperatively to 6 postoperatively (range, 0-52). The mean patient satisfaction postoperatively was 8.2 (range, 5-10).

Conclusion: Significantly improved outcomes can be achieved at midterm follow-up with a low rate of complications when reconstructing the lateral patellofemoral ligament in the setting of iatrogenic medial patellar instability.

Keywords: medial patellar instability; lateral release; patella; knee outcomes; lateral patellofemoral ligament

Historically, a lateral retinacular release was a popular mode of treatment for a variety of knee conditions, including lateral patellar instability,^{2,14,19} anterior knee pain,^{5,10} and patellar chondromalacia.⁶ This procedure

was often preferred because of the reported low complication rates. In 1988, Hughston and Deese⁷ described medial patellar instability as a complication of a lateral retinacular release procedure. The static and dynamic lateral stabilizers of the patella, including the lateral patellofemoral ligament and the lateral epicondylapatellar ligament, can be compromised during a lateral retinacular release.⁴ Most cases of medial patellar instability reported in the literature are iatrogenic, but traumatic and spontaneous cases have also been reported.¹⁵

Medial patellar instability can be a disabling condition. Some patients with prior lateral retinacular release report pain and other symptoms that are worse than prior to their surgery. Sanchis-Alfonso et al¹⁶ reported that patients with iatrogenic medial patellar instability had higher rates of disabling psychologic symptoms such as anxiety and depression compared with patients with more typical anterior knee pain. The optimal treatment of this condition is debatable. Several techniques have been described, including direct lateral ligament repair,⁹ arthroscopic medial retinacular release,²⁰ lateral retinacular reconstruction with soft tissue augmentation,¹⁶ lateral patellofemoral ligament

||Address correspondence to Robert F. LaPrade, MD, PhD, Steadman Philippon Research Institute, The Steadman Clinic, 181 West Meadow Drive, Suite 400, Vail, CO 81657, USA (email: drlaprade@sprivail.org).

*Steadman Philippon Research Institute, Vail, Colorado, USA.

†Orthopedic Department, Oslo University Hospital, Oslo, Norway.

‡OSTC, The Norwegian School of Sports Sciences, Oslo, Norway.

§The Steadman Clinic, Vail, Colorado, USA.

One or more of the authors has declared the following potential conflict of interest or source of funding: G.M. receives research support from Arthrex and Health South East, Norway. R.F.L. receives royalties from Arthrex and Smith & Nephew; is a paid consultant for Arthrex, Ossur, and Smith & Nephew; and receives research support from Arthrex, Smith & Nephew, and Linvatec.

Ethical approval for this study was obtained from the Vail Valley Medical Center Institutional Review Board.

The Orthopaedic Journal of Sports Medicine, 5(4), 2325967117699816

DOI: 10.1177/2325967117699816

© The Author(s) 2017

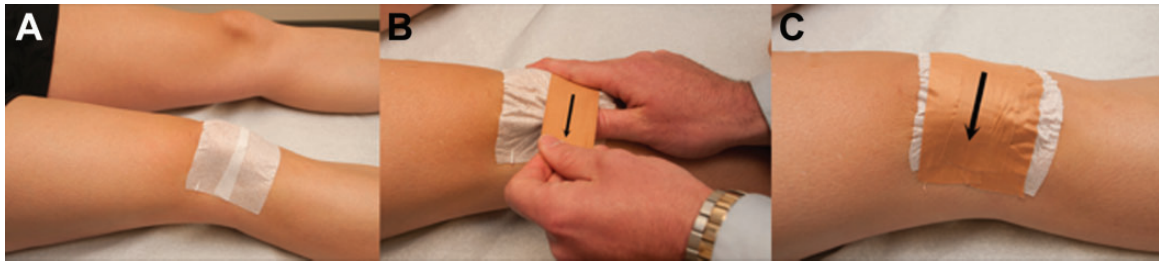


Figure 1. Schematic showing application of reverse McConnell taping. (A) Stretch tape is placed over the patellofemoral joint to protect the skin. (B) With the medial aspect of the tape in place, the patella is stabilized in the trochlear groove and the tape is pulled laterally. (C) The tape is then secured laterally, providing medial stability to the patella. It is important not to apply too much lateral tension in the tape, which will cause the patella to grind in the lateral facet of the trochlea.

reconstruction,^{25,26} and lateral patellotibial ligament reconstruction.^{8,18} The purpose of this study was to review the outcomes in patients after treatment for medial patellar instability with a lateral patellotibial ligament reconstruction^{8,18} at a minimum of 2 years' follow-up. We hypothesized that patients who had a prior lateral release would have good outcomes after lateral patellotibial ligament reconstruction at a minimum of 2 years after surgery.

METHODS

Patients

All patients who underwent a lateral patellotibial ligament reconstruction between May 2011 and December 2013 by a single surgeon were included in this study. Patients who were not a minimum of 2 years post-index surgery were not included in this study. This query yielded 15 patients, 13 (87%) of whom had complete follow-up data. Patients' ages ranged from 15 to 46 years (mean, 31 years). All 13 patients had undergone a prior lateral release procedure for lateral patellar subluxation. Detailed surgical findings were documented at the time of surgery. All patients completed preoperative and postoperative subjective questionnaires, which included the Lysholm score¹¹ and the Tegner Activity Scale²⁴ to document function and activity level. Patient satisfaction was also evaluated using a 10-point scale on which patients rated their outcome from 1 (very unsatisfied) to 10 (very satisfied). All data were collected prospectively and stored in a data registry. All patients had full range of motion during both their preoperative visit and the examination under anesthesia. Preoperatively, 9 of the 13 patients presented with medial patellar instability, while the remaining 4 patients presented with medial instability and pain.

Diagnosis

All patients presented with complaints of anterior knee pain and subjective patellar instability near extension. There were no cases of frank medial patellar dislocation. Medial patellar instability was documented subjectively by dynamically subluxing the patella medially near extension and then flexing the knee. The medially subluxated patella

would fall back into the trochlear groove at approximately 40° of knee flexion. A positive response was assumed to be elicited when patients reported that this maneuver reproduced their instability symptoms. This was then objectively verified by having the patients undergo reverse McConnell taping for 6 weeks in supervised physiotherapy. If taping provided relief of symptoms, then it was anticipated that patients could expect improvement of symptoms with surgery (Figure 1).¹⁸ Other physical examination tests included measuring the degree of patellar translation in quadrants medially and laterally, the lateral patellar apprehension test, and complete tibiofemoral stability tests (Lachman, posterior drawer, varus and valgus stress tests). On magnetic resonance imaging, a medially subluxated patella can be appreciated, particularly in severe cases.^{13,21}

Surgical Technique of Lateral Patellotibial Ligament Reconstruction

This surgical technique was originally described by Hughston et al⁸ in 1996 and further defined by Sawyer et al.¹⁸ After standard preparation, draping, and prophylactic antibiotics, a skin incision was made 3 cm lateral and proximal to the patella and carried out 3 cm distal to the Gerdy tubercle. A sharp dissection to the iliotibial band and anteriorly to the lateral aspect of the patellar tendon was performed. Proximal dissection must be performed from posterior to anterior to avoid injuring the previously released superficial layer of the iliotibial band. The lateral 8 mm of the patellar tendon was harvested, leaving the attachment to the patella intact. Then, a central 8-mm-wide iliotibial band graft was harvested leaving its attachment to the Gerdy tubercle intact. The iliotibial band graft should be the same length as the patellar tendon graft. Tag sutures were then placed at the free ends of the grafts. A soft tissue tunnel on the anterolateral aspect of the knee along the course of the lateral patellotibial ligament and within the scar tissue created by the lateral release was created for graft passage. Both grafts were then passed through the soft tissue tunnels, and the graft harvest defect in the iliotibial band was closed in an interrupted horizontal mattress fashion. Diagnostic arthroscopy was then performed using the standard anterolateral and anteromedial portals. Graft harvesting and

preparation was performed prior to arthroscopy to avoid fluid extravasation that might impair visualization and identification of the structures. The cartilage status of the patellofemoral joint was assessed. In addition, a dynamic patellofemoral examination was performed, noting and documenting the medial patellar subluxation and documenting where the patella sits centrally in the trochlear groove. Any chondral lesions found at the time of surgery were treated with chondroplasty.

After the arthroscopy was complete, the arthroscopic fluid was evacuated from the joint prior to ligament reconstruction. The 2 grafts (patellar tendon graft and iliotibial band graft) were sutured together using No. 2 nonabsorbable suture with the knee in full extension. It is important that the patella is held centered in the trochlea and the length of the patellar tendon is maintained. If the patellar tendon is short (slack) when suturing, this could imply patellar baja. Fluoroscopy can also be utilized to control patella height during surgery. The grafts were sutured to each other proximally and distally first, and the knee tested for restoration of patellar stability before placing additional sutures. The skin was closed using No. 2-0 absorbable sutures, and portals were closed using subcuticular No. 4-0 absorbable sutures.

Postoperative Rehabilitation

The rehabilitation protocol has been previously reported.¹⁸ Postoperatively, patients were allowed touch-down weight-bearing for 6 weeks, and a knee immobilizer was used during this period. The knee immobilizer was removed for passive range of motion exercises of 0° to 90° for the first 2 weeks, which were initiated on postoperative day 1. Patellar mobilization in proximal to distal directions was performed while avoiding medial to lateral patellar mobilization for the first 6 weeks to protect the reconstruction grafts. After 2 weeks, full motion was allowed as tolerated. Aspirin was recommended for deep vein thrombosis prophylaxis. Crutches and the knee immobilizer could be weaned after 6 weeks, and patients initiated the use of a stationary bike and closed kinetic chain strengthening exercises. Progression to full activities was expected at 4.5 to 6 months.

RESULTS

This consecutive cohort consisted of 13 patients, 2 males and 11 females, with a mean age of 31.3 years (range, 15-46 years). All 13 patients were available for final follow-up at a mean of 3.8 years (range, 2-5 years) after surgery. The mean time from the lateral release to reconstruction surgery was 4.4 months (range, 0.5-12 months). The mean body mass index of the cohort was 24.8 kg/m² (range, 19-40 kg/m²). Eight patients had concomitant chondral injuries at the time of surgery. The location and grade of these injuries are displayed in Table 1. Chondral lesions were graded using the Outerbridge classification system^{3,27} and defined in accordance with previous literature regarding chondral defects.^{3,27} Descriptive information and statistics for all patients are shown in Table 2.

TABLE 1

Location and Grade of Chondral Lesions Seen in 8 Patients

Patient No.	Chondral Defect
1	Trochlear groove, grade 4
2	Patella, grade 4
3	Patella, grade 3
4	Patella, grade 1
5	Patella, grade 2
6	Trochlear groove, grade 1; patella, grade 3
7	Trochlear groove, grade 4; patella, grade 4
8	Medial femoral condyle, grade 4; trochlear groove, grade 4; patella, grade 4

Concomitant Knee Pathology

One patient had prior anterior cruciate ligament reconstruction with medial meniscectomy; none of the other patients had any prior or concomitant meniscal or ligament pathology at the time of surgery.

Complications

There were no complications during surgery or during the postoperative period for any of the patients included in this study.

Patient Outcomes

The mean preoperative Lysholm score was 45.6 (range, 11-76), and the mean postoperative Lysholm score was 71.9 (range, 30-91). The median preoperative Tegner Activity Scale score was 3 (range, 1-7) while the median postoperative score was 4 (range, 1-9). The median preoperative Western Ontario and McMaster Universities Arthritis Index (WOMAC) total score was 38 (range, 1-57); the median postoperative WOMAC score was 6 (range, 0-52). Mean patient satisfaction postoperatively was 8.2 (range, 5-10). The median preoperative International Knee Documentation Committee (IKDC) score was 66.5 (range, 29.9-79.3), and the median postoperative IKDC score was 66.6 (range, 51.7-71.2). Mean patient outcome scores are reported in Table 3.

DISCUSSION

The most important finding in this study was that significantly improved outcomes can be achieved at midterm follow-up with a low rate of complications when reconstructing the lateral patellotibial ligament in the setting of iatrogenic medial patellar instability. Of note, the majority of patients (57%) presented with cartilage defects in the patellofemoral joint at the time of surgery, and most of the patients were females, which may be attributable to increased tissue laxity in females.²² Moreover, the presence of associated lesions such as chondral lesions could have acted as a confounding factor.

TABLE 2
Demographic and Outcome Data for All Patients in the Study^a

No.	Sex	Age at Surgery, y	BMI, kg/m ²	Age at FU, y	Previous Procedure	Preoperative Ligament Injury	Preoperative Chondral Lesion	Preoperative Meniscal Pathology	Tegner Score		Lysholm Score		SF-12 PCS		Postoperative Satisfaction
									Preoperative	Postoperative	Preoperative	Postoperative	Preoperative	Postoperative	
1	F	23	22.8	27	LR	ACL tear	None	S/P medial meniscectomy	3	4	46	64	42.3	39.7	6
2	M	39	26.6	44	LR	ACL tear	Trochlear groove, grade 4	None	2	9	26	91	38.9	57.6	10
3	F	15	20.0	20	LR		None	None	7	N/A	N/A	39	38.4	36.5	8
4	F	33	23.4	36	LR		Patella, grade 4	None	4	4	60	86	36.3	48.3	8
5	F	34	23.4	38	LR		Patella, grade 3	None	4	6	39	86	36.1	55.1	10
6	F	26	19.2	30	LR		Patella, grade 1	None	3	7	52	86	37.1	56.5	10
7	F	26	25.8	28	LR		Patella, grade 2	None	3	3	76	90	42.2	54.8	9
8	F	35	20.6	37	LR		None	None	2	4	47	89	26	55.3	9
9	F	35	19.7	37	LR		None	None	1	5	57	81	27.7	58.4	8
10	M	26	24.4	29	LR		None	None	5	2	66	53	45.1	30.1	6
11	F	33	24.4	35	LR		Patella, tendon, grade 3; trochlear groove, grade 1	None	2	2	46	94	27.7	52.8	9
12	F	36	40.2	39	LR		MFC, grade 4; trochlear groove, grade 4	None	1	2	21	30	27.3	23.8	5
13	F	46	31.4	48	LR		Patella, grade 4	None	1	1	11	46	24.1	25.4	8

^aACL, anterior cruciate ligament; BMI, body mass index; F, female; FU, follow-up; LR, lateral release; M, male; MFC, medial femoral condyle; N/A, not applicable; S/P, status post; SF-12 PCS, Short Form Health Survey–Physical Component Summary.

TABLE 3
Mean Preoperative and Postoperative Patient Outcome Scores With Standard Deviations^a

	Preoperative	SD	Postoperative	SD	P Value
Lysholm	45.6	19	71.9	22.5	.001
Tegner Activity Scale	2.9	1.8	4.1	2.4	.17
WOMAC total	36.1	15.2	17.8	21.9	.02
IKDC	61	6.4	66	5.1	.57
Patient satisfaction	N/A	N/A	8.2	1.7	N/A

^aIKDC, International Knee Documentation Committee; N/A, not applicable; WOMAC, Western Ontario and McMaster Universities Arthritis Index

Medial patellar instability is a disabling condition, as demonstrated by the low preoperative Tegner activity and Lysholm scores. The preoperative Tegner activity score was 2.9, and the preoperative Lysholm score was 45.6, which is defined as poor.²⁴ Higher rates of psychological symptoms such as depression and anxiety have also been reported in patients with iatrogenic medial patellar instability.¹⁶ Surgical management is usually recommended for patients who do not respond to nonoperative treatment. Similar to other studies, there was a significant improvement in symptoms after the surgical treatment in this study. The mean postoperative Lysholm score was 71.9, and the median postoperative Tegner activity score was 4.1. The

median WOMAC scores improved from 38 preoperatively to 6 postoperatively. Hughston et al⁸ reported an improvement in functional levels in 68% of patients and subjective improvement reported by 75% of patients at 54-month follow-up. These authors reported better subjective patient outcomes in the second half of the study period because of their learning curve. Sanchis-Alfonso et al¹⁶ reported outcomes in 17 patients (mean age, 34 years) with persistent pain and prior failed lateral release who underwent lateral retinaculum reconstruction using a strip of the iliotibial band for iatrogenic medial patellar instability in patients with persistent pain with prior failed lateral release. The authors reported an improvement in Lysholm score from

36.4 to 86.1, and the visual analog scale pain score improved from 7.6 to 1.9 at minimum 2-year follow-up.

The majority of the cases of medial patellar instability are iatrogenic. In our series, all patients had a prior lateral release. Hughston and Deese⁷ reported that in their series of 54 patients (60 knees), all had prior arthroscopic lateral retinacular release. Hughston et al⁸ later reported on outcomes after surgery in a series of 63 patients (65 knees), and 89% had previously undergone lateral retinacular release. Sanchis-Alfonso et al¹⁶ reported that 91% of the patients with medial patellar instability reported in the literature had a previous lateral retinacular release. Iatrogenic medial patellar instability is more common in patients who underwent an aggressive lateral retinacular release.²³ Several case series of noniatrogenic medial patellar instability have also been reported in the literature, but they are few in number.^{1,13,17}

In cases where iatrogenic medial patellar instability is suspected, it has been recommended that patients should undergo a 6-week trial of a supervised reverse McConnell taping so that the diagnosis can be confirmed and also as a prognostic factor of symptom relief by potential surgery.¹⁸

Several techniques have been described to repair or reconstruct the lateral retinacular structures. Hughston et al⁸ reported on 63 patients (65 knees) using direct lateral retinacular repair (60%) or lateral patellofemoral reconstruction using a strip of patellar tendon or iliotibial band or a combination of both. At 54-month follow-up, 75% of the patients reported subjective improvement. Nonweiler and DeLee¹² described a lateral plication procedure in 5 patients: 4 had no instability symptoms and had normal medial patellar mobility at 3.3-year follow-up. In a recent technique article, Teitge and Torga Spak²⁵ described using a quadriceps tendon autograft with the bone block fixed on the femur and a tunnel in the patella. They reported “excellent” results in 60 patients from a stability standpoint but no patient outcomes scores were reported.²⁵ In addition, 3 patients had an intraoperative patellar fracture. The preferred technique by the senior author (R.F.L.) is the lateral patellofemoral ligament reconstruction using iliotibial band and patellar tendon autografts tied over each other, as has been previously described by both Hughston et al⁸ and Sawyer et al.¹⁸

We acknowledge some limitations to the present study. First, the inherent restraints associated with the retrospective nature of the study design; however, all the data were collected prospectively, which minimized data collection errors. In addition, the relatively small sample of patients and the lack of long-term follow-up can underestimate the real effect of this procedure. Regarding outcomes scores, we acknowledge that scores such the Kujala score may be better suited for patella surgery outcomes. Unfortunately, this score was not recorded during our study’s enrollment period. The use of a single technique performed by the same experienced surgeon diminishes variables considerably; however, generalizability for practices with multiple surgeons or with less experience may be diminished. Further studies are necessary to determine the long-term outcomes of lateral retinacular reconstruction procedures.

CONCLUSION

Significantly improved outcomes can be achieved at mid-term follow-up with a low rate of complications when reconstructing the lateral patellofemoral ligament in the setting of iatrogenic medial patellar instability.

REFERENCES

1. Aksahin E, Yumrukcal F, Yuksel HY, Dogruyol D, Celebi L. Role of pathophysiology of patellofemoral instability in the treatment of spontaneous medial patellofemoral subluxation: a case report. *J Med Case Rep.* 2010;4:148.
2. Arshi A, Cohen JR, Wang JC, Hame SL, McAllister DR, Jones KJ. Operative management of patellar instability in the United States: an evaluation of national practice patterns, surgical trends, and complications. *Orthop J Sports Med.* 2016;4:2325967116662873.
3. Cameron ML, Briggs KK, Steadman JR. Reproducibility and reliability of the Outerbridge classification for grading chondral lesions of the knee arthroscopically. *Am J Sports Med.* 2003;31:83-86.
4. Fu FH, Maday MG. Arthroscopic lateral release and the lateral patellar compression syndrome. *Orthop Clin North Am.* 1992;23:601-612.
5. Fulkerson JP. The etiology of patellofemoral pain in young, active patients: a prospective study. *Clin Orthop Relat Res.* 1983;179:129-133.
6. Harwin SF, Stern RE. Subcutaneous lateral retinacular release for chondromalacia patellae: a preliminary report. *Clin Orthop Relat Res.* 1981;156:207-210.
7. Hughston JC, Deese M. Medial subluxation of the patella as a complication of lateral retinacular release. *Am J Sports Med.* 1988;16:383-388.
8. Hughston JC, Flandry F, Brinker MR, Terry GC, Mills JC 3rd. Surgical correction of medial subluxation of the patella. *Am J Sports Med.* 1996;24:486-491.
9. Johnson DP, Wakeley C. Reconstruction of the lateral patellar retinaculum following lateral release: a case report. *Knee Surg Sports Traumatol Arthrosc.* 2002;10:361-363.
10. Larson RL, Cabaud HE, Slocum DB, James SL, Keenan T, Hutchinson T. The patellar compression syndrome: surgical treatment by lateral retinacular release. *Clin Orthop Relat Res.* 1978;134:158-167.
11. Lysholm J, Gillquist J. Evaluation of knee ligament surgery results with special emphasis on use of a scoring scale. *Am J Sports Med.* 1982;10:150-154.
12. Nonweiler DE, DeLee JC. The diagnosis and treatment of medial subluxation of the patella after lateral retinacular release. *Am J Sports Med.* 1994;22:680-686.
13. Richman NM, Scheller AD Jr. Medial subluxation of the patella without previous lateral retinacular release. *Orthopedics.* 1998;21:810-813.
14. Roth S, Madarevic T, Vukelic L, Roth A, Gudac Madarevic D, Cicvaric T. Influence of arthroscopic lateral release on functional recovery in adolescents with recurrent patellar dislocation. *Arch Orthop Trauma Surg.* 2013;133:1441-1445.
15. Sanchis-Alfonso V, Merchant AC. Iatrogenic medial patellar instability: an avoidable injury. *Arthroscopy.* 2015;31:1628-1632.
16. Sanchis-Alfonso V, Montesinos-Berry E, Monllau JC, Merchant AC. Results of isolated lateral retinacular reconstruction for iatrogenic medial patellar instability. *Arthroscopy.* 2015;31:422-427.
17. Saper MG, Shneider DA. Medial patellar subluxation without previous lateral release: a case report. *J Pediatr Orthop B.* 2014;23:350-353.
18. Sawyer GA, Cram T, LaPrade RF. Lateral patellofemoral ligament reconstruction for medial patellar instability. *Arthrosc Tech.* 2014;3:e547-e550.
19. Schonholtz GJ, Zahn MG, Magee CM. Lateral retinacular release of the patella. *Arthroscopy.* 1987;3:269-272.
20. Shannon BD, Keene JS. Results of arthroscopic medial retinacular release for treatment of medial subluxation of the patella. *Am J Sports Med.* 2007;35:1180-1187.

21. Shellock FG, Mink JH, Deutsch A, Fox JM, Ferkel RD. Evaluation of patients with persistent symptoms after lateral retinacular release by kinematic magnetic resonance imaging of the patellofemoral joint. *Arthroscopy*. 1990;6:226-234.
22. Shultz SJ, Sander TC, Kirk SE, Perrin DH. Sex differences in knee joint laxity change across the female menstrual cycle. *J Sports Med Phys Fitness*. 2005;45:594-603.
23. Song GY, Hong L, Zhang H, Zhang J, Li Y, Feng H. Iatrogenic medial patellar instability following lateral retinacular release of the knee joint. *Knee Surg Sports Traumatol Arthrosc*. 2016;24:2825-2830.
24. Tegner Y, Lysholm J. Rating systems in the evaluation of knee ligament injuries. *Clin Orthop Relat Res*. 1985;198:43-49.
25. Teitge RA, Torga Spak R. Lateral patellofemoral ligament reconstruction. *Arthroscopy*. 2004;20:998-1002.
26. Udagawa K, Niki Y, Matsumoto H, et al. Lateral patellar retinaculum reconstruction for medial patellar instability following lateral retinacular release: a case report. *Knee*. 2014;21:336-339.
27. Widuchowski W, Widuchowski J, Trzaska T. Articular cartilage defects: study of 25,124 knee arthroscopies. *Knee*. 2007;14:177-182.