JACC: CASE REPORTS VOL. 29, 2024

STRUCTURAL HEART DISEASE

IMAGING VIGNETTE: CLINICAL VIGNETTE

Multimodality Imaging in a Patient With Double Aortic Arch Undergoing Transcatheter Aortic Valve Implantation

Eirini Beneki, MD, MSc, PhD, Kyriakos Dimitriadis, MD, PhD, Yannis Dimitroglou, MD, MSc, PhD, Konstantinos Tsioufis, MD, PhD, Constantina Aggeli, MD, PhD

ABSTRACT

Double aortic arch is a rare congenital malformation often identified as an incidental finding during routine imaging. In our case, we describe aortic hemodynamics of double aortic arch in a patient with severe aortic stenosis and the procedural process of transcatheter aortic valve implantation. (J Am Coll Cardiol Case Rep 2024;29:102224) © 2024 The Authors. Published by Elsevier on behalf of the American College of Cardiology Foundation. This is an open access article under the CC BY-NC-ND license (http://creativecommons.org/licenses/by-nc-nd/4.0/).

An 84-year-old man was admitted to the echocardiography outpatient department experiencing progressive shortness of breath on exertion. He was hemodynamically stable and a harsh, systolic ejection murmur was heard at the second left intercostal space on cardiac auscultation. Transthoracic echocardiography demonstrated severe aortic stenosis with preserved left ventricular ejection fraction and normal aorta diameter.

Assessing the suprasternal view, accelerated turbulent blood flow anterogradely from the ascending aorta to the transverse aortic arch was observed with color Doppler flow imaging during systole (**Figure 1A**). Following the aortic flow velocity pattern along the aortic arch we noticed unexpectedly 2 different parallel and simultaneous blood flow patterns separated by an anatomic structure resembling a membrane. This finding was suggestive of abnormal anatomy and the possible diagnosis of a double aortic arch was made. The right aortic arch (RAA) was higher and relatively small compared with the left aortic arch (LAA) as revealed with the index marker of the probe pointing to 11 o'clock (**Figure 1B**). Laminar blood flow pattern was observed through the LAA due to the straight trajectory and the larger diameter of the vessel, whereas blood flow was more turbulent through the RAA (**Figure 1C**). Both arches were joined and formed the proximal descending aorta (**Figures 1D and 1E**). Also, with the index marker of the probe pointing to 1 o'clock, left subclavian and common carotid artery depicted to arise from the left aortic arch only after reducing the Nyquist limit to 23.1 cm/s. Blood flow through both arches was detected only after reducing the Nyquist limit to 23.1cm/s. This interesting echocardiographic technical manipulation was needed because the collision of blood on the bifurcation of the 2 arches caused energy loss and consequent lower blood flow velocities through both aortic arch lumens.

The consequent computed tomography depicted a dominant LAA and a hypoplastic RAA encircling the trachea and the esophagus resulting in the formation of a complete vascular ring terminated into the proximal descending aorta (**Figures 1E and 1F**). The classic "4-vessel sign" was formatted as each subclavian and carotid

From the First Cardiology Department, School of Medicine, Hippokration General Hospital, National and Kapodistrian University of Athens, Athens, Greece.
The authors attest they are in compliance with human studies committees and animal welfare regulations of the authors' institutions and Food and Drug Administration guidelines, including patient consent where appropriate. For more information, visit the Author Center.

Manuscript received November 27, 2023; revised manuscript received December 28, 2023, accepted January 4, 2024.

ISSN 2666-0849 https://doi.org/10.1016/j.jaccas.2024.102224

ABBREVIATIONS AND ACRONYMS

LAA = left aortic arch

RAA = right aortic arch

TAVI = transcatheter aortic valve implantation

artery emerged from the relative arch. The brachiocephalic artery was absent. The vascular ring did not compress the trachea and esophagus and no other congenital malformations were detected.

The estimated Euroscore of 8% for our patient led to the decision of transcatheter aortic valve implantation (TAVI) for severe aortic stenosis. The straight trajectory of the LAA was the interventional route for a more straightforward and safer delivery of the valve, whereas the RAA was used for contrast injections during the procedure from the pigtail. Afterward, the usual sequence of interventional steps was done for TAVI (Videos 1 to 4) and the mean pressure gradient across the valve measured 10 mm Hg using transthoracic echocardiography.

To our knowledge, this is the first case report in the medical literature describing aortic hemodynamics and successful TAVI in an octogenarian with severe aortic stenosis and double aortic arch.

FUNDING SUPPORT AND AUTHOR DISCLOSURES

The authors have reported that they have no relationships relevant to the contents of this paper to disclose.

FIGURE 1 Multimodality Imaging of Double Aortic Arch

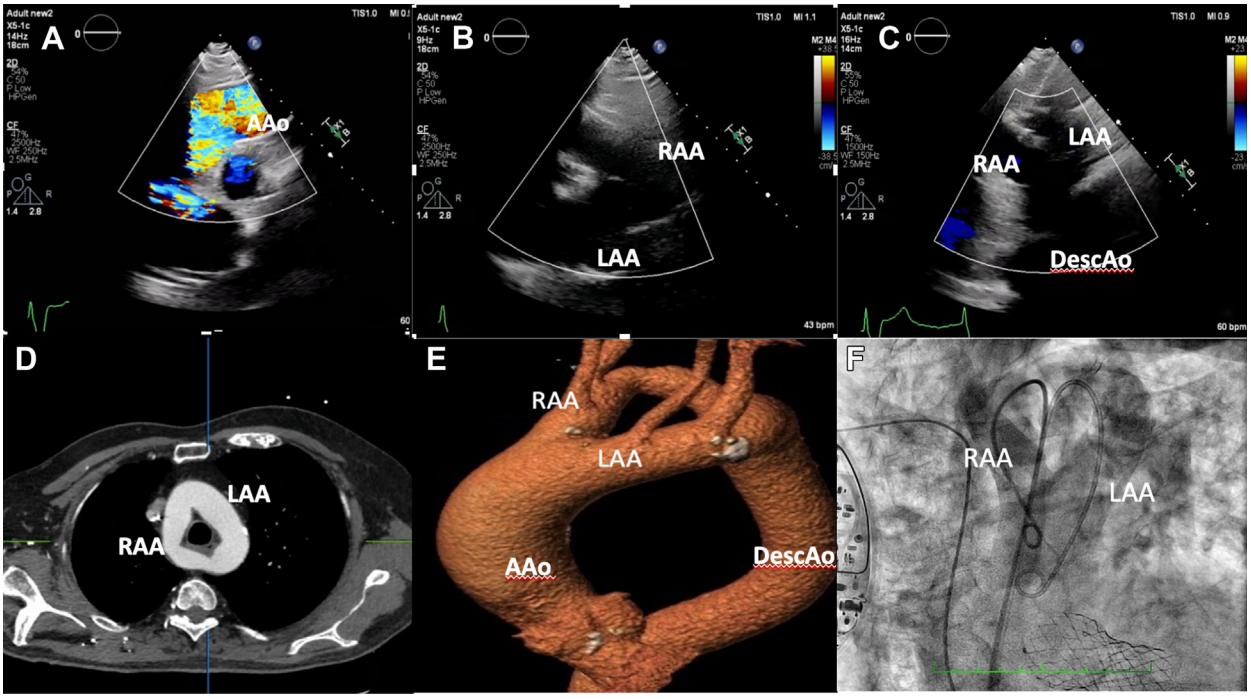

(A) Transthoracic color Doppler suprasternal views showing accelerated turbulent blood flow from the AAo to the transverse aortic arch. (B) The hypoplastic RAA joining the larger LAA to form the proximal DescAo with the index marker of the probe pointing to 11 o'clock. (C) A dominant LAA and a hypoplastic RAA terminating into the proximal DescAo. (D and E) Computed tomography depicting the double-lumen aortic arch arising from the AAo and forming a vascular ring. (F) Final aortography after TAVI. AAo = ascending aorta; DescAo = descending aorta; LAA = left aortic arch; RAA = right aortic arch; TAVI = transcatheter aortic valve implantation.

ADDRESS FOR CORRESPONDENCE: Dr Eirini Beneki, First Cardiology Department, School of Medicine, Hippokration General Hospital, National and Kapodistrian University of Athens, Vasilissis Sofias 114, Athens 11528, Greece. E-mail: e.beneki@yahoo.com.

KEY WORDS aortic valve, computed tomography, Doppler ultrasound, echocardiography, hemodynamics, imaging

APPENDIX For supplemental videos, please see the online version of this paper.