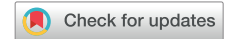

Noise caused by involuntary muscle response may inhibit detection of ventricular fibrillation during defibrillation testing



Sarah W.E. Baalman, MD,* Kirsten M. Kooiman, PA,* Anne-Floor B.E. Quast, MD,* Pieter G. Postema, MD, PhD,* Steven Donnelley, MSS,† Reinoud E. Knops, MD, PhD*

From the *Amsterdam UMC, University of Amsterdam, Amsterdam, The Netherlands, and †Boston Scientific, Minneapolis, Minnesota.

Introduction

The subcutaneous implantable cardioverter-defibrillator (S-ICD) has been shown to be a safe and efficacious alternative to the transvenous ICD for the prevention of sudden cardiac death.¹ The S-ICD avoids the intracardiac space and therefore senses subcutaneous electrocardiographic signals instead of near-field signals. This different methodology causes a benign delay of sensing of ventricular arrhythmias and prolonged time to therapy.² A recently published multicenter study described inhibition of shock therapy during defibrillation testing (DFT) in 5 de novo S-ICD implantations owing to noise sensing.³ Hypothetically, muscle spasm intrinsic to the 200 mA burst by the S-ICD during induction of ventricular fibrillation (VF) may have caused noise with subsequent absence of VF detection and withholding of therapy. However, to our knowledge there is no evidence that supports this concept to date.

Case report

A 66-year-old man with a history of inferior posterior lateral myocardial infarction, coronary artery bypass grafting, and subsequent diagnosis of ischemic cardiomyopathy with a reduced left ventricular ejection fraction of 30% on transthoracic echocardiography underwent successful S-ICD implantation in 2012 as primary prevention for sudden cardiac death. During implant 2 consecutive successful

KEYWORDS Case report; Defibrillation testing; Muscle spasm; Noise; Subcutaneous implantable cardioverter-defibrillator; Undersensing (Heart Rhythm Case Reports 2020;6:126–130)

Conflict of interest: Baalman, Quast, and Postema have nothing to declare. Kooiman reports compensation for services from Boston Scientific. Donnelley is an employee at Boston Scientific. Knops reports consulting fees, research grants, and honoraria for Boston Scientific, and consulting fees and research grants with Medtronic and Abbott. Funding: This research did not receive any specific grant from funding agencies in the public, commercial, or not-for-profit sectors. **Address reprint requests and correspondence:** Dr Sarah W.E. Baalman, Amsterdam UMC, University of Amsterdam, Department of Cardiology, Room C0-333, PO Box 22700, Meibergdreef 9, 1105 AZ Amsterdam, The Netherlands. E-mail address: s.w.baalman@amsterdamumc.nl.

KEY TEACHING POINTS

- Muscle spasm caused by induction of ventricular fibrillation (VF) by the subcutaneous ICD (S-ICD) can cause a delay in or absence of VF detection during defibrillation testing (DFT).
- Changing the sensing vector or using muscle relaxants during DFT are solutions to overcome this phenomenon.
- This case report demonstrates that induction of VF by the S-ICD is the cause of this specific noise and most likely will not occur during spontaneous episodes of VF.
- Highlighting the mechanisms of noise during DFT is important, as future studies may show noninferiority of DFT during S-ICD implantation.

DFTs were performed with a 65 J shock in standard polarity. VF was induced by a 200 mA shock from the S-ICD. The patient did not experience any arrhythmia episode or inappropriate or appropriate shocks during follow-up. In April 2018, the patient underwent an elective S-ICD generator replacement followed by a routine DFT. VF was successfully induced by the S-ICD with a 200 mA burst at 50 Hz for 3 seconds. However, because of the presence of noise the S-ICD did not reach initial detection and shock therapy was withheld (Figure 1). Twenty-three seconds after VF induction a manual 200 J shock was delivered by an external defibrillator with successful conversion to sinus rhythm. A second DFT again resulted in inhibition of therapy owing to the sensing of noise and the ventricular arrhythmia was terminated by a second external 200 J shock. In the absence of noise in the secondary vector, the sensing vector was manually programmed from the primary to the secondary sensing vector and a third DFT was performed with adequate sensing and successful termination of VF by a 65 J shock in standard

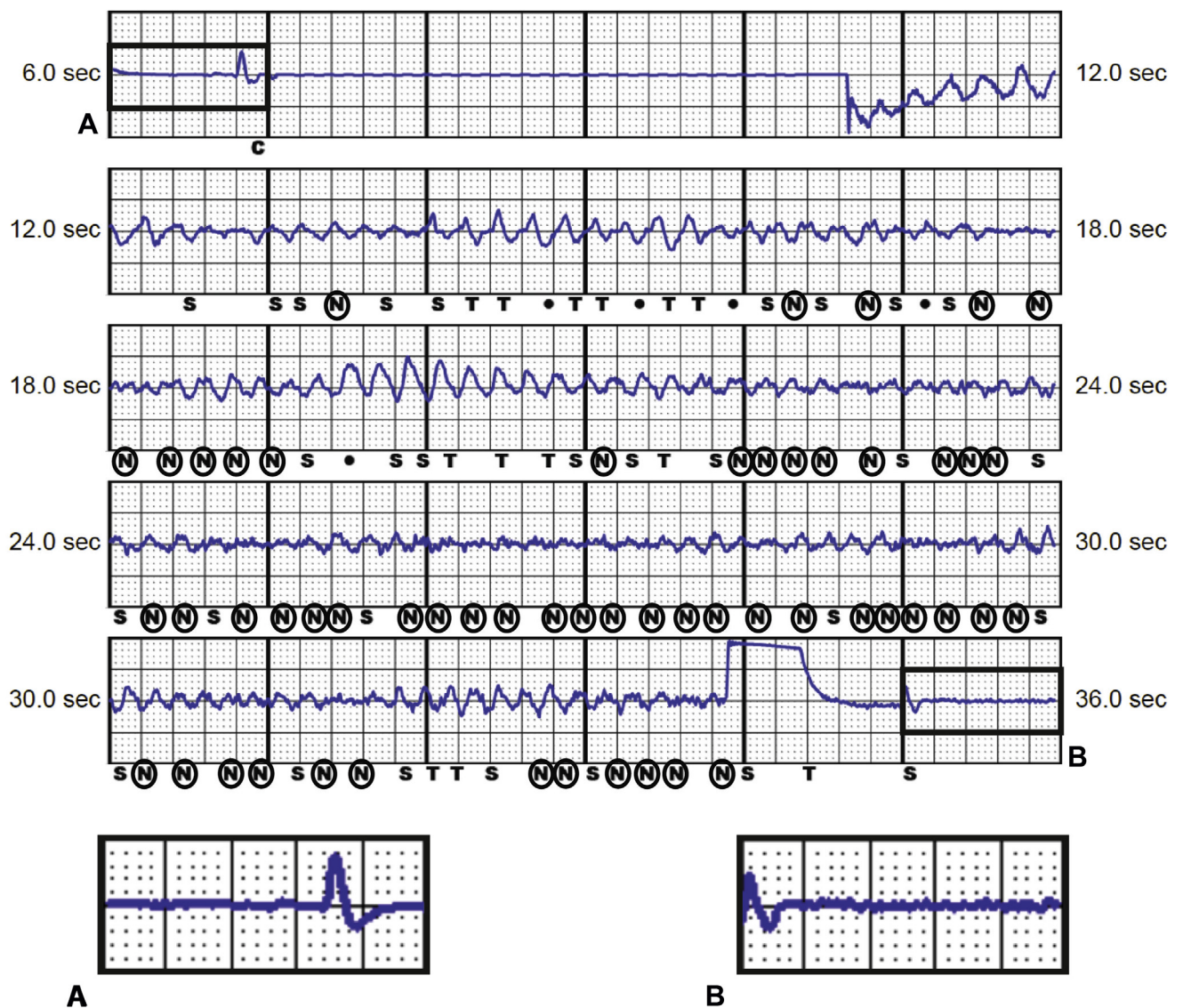


Figure 1 Subcutaneous electrocardiogram of defibrillation testing after elective subcutaneous implantable cardioverter-defibrillator (S-ICD) generator replacement. After ventricular fibrillation (VF) induction by the S-ICD, shock therapy was inhibited because of noise sensing. An external shock was manually given 23 seconds after VF induction. **A:** Beat before induction without visible noise. **B:** Beat after induction with visible noise. C = start induction; N = noise; S = sense; T = tachy detection.

polarity. The sensing vector remained programmed in the secondary vector at discharge.

To test the hypothesis that muscle spasm caused noise sensing with subsequent withholding of shock therapy and

to achieve optimal safety, we planned 5 additional consecutive DFTs following a prespecified protocol (Table 1) 2 months after the elective S-ICD replacement. The DFTs were performed under conscious sedation with and without

Table 1 Overview of the different induction methods, and noise pre-shock during the additional defibrillation tests 2 months after subcutaneous implantable cardioverter-defibrillator replacement

Test #	Method of VF induction	Duration of induction (s)	Noise marker count (60 s pre-shock)	Shock specifics
1	EP catheter	3.0	0	80 J STD 88 Ω
2	EP catheter	5.0	0	80 J STD 79 Ω
3	50 Hz burst S-ICD	3.0	5	65 J STD 77 Ω
4	50 Hz burst S-ICD	5.0	13	65 J STD 85 Ω
5	50 Hz burst S-ICD, with muscle relaxant medication	5.0	1	65 J STD 83 Ω

Noise marker counts were provided by the manufacturer. Noise only occurred after VF induction by the S-ICD without the use of muscle relaxant (test # 3 and 4). With muscle relaxant the marked noise decreased to only 1 noise marker within 60 seconds after appropriate induction of VF by the S-ICD (test #5).

EP = electrophysiology; S-ICD = subcutaneous implantable cardioverter-defibrillator; STD = standard polarity; VF = ventricular fibrillation.

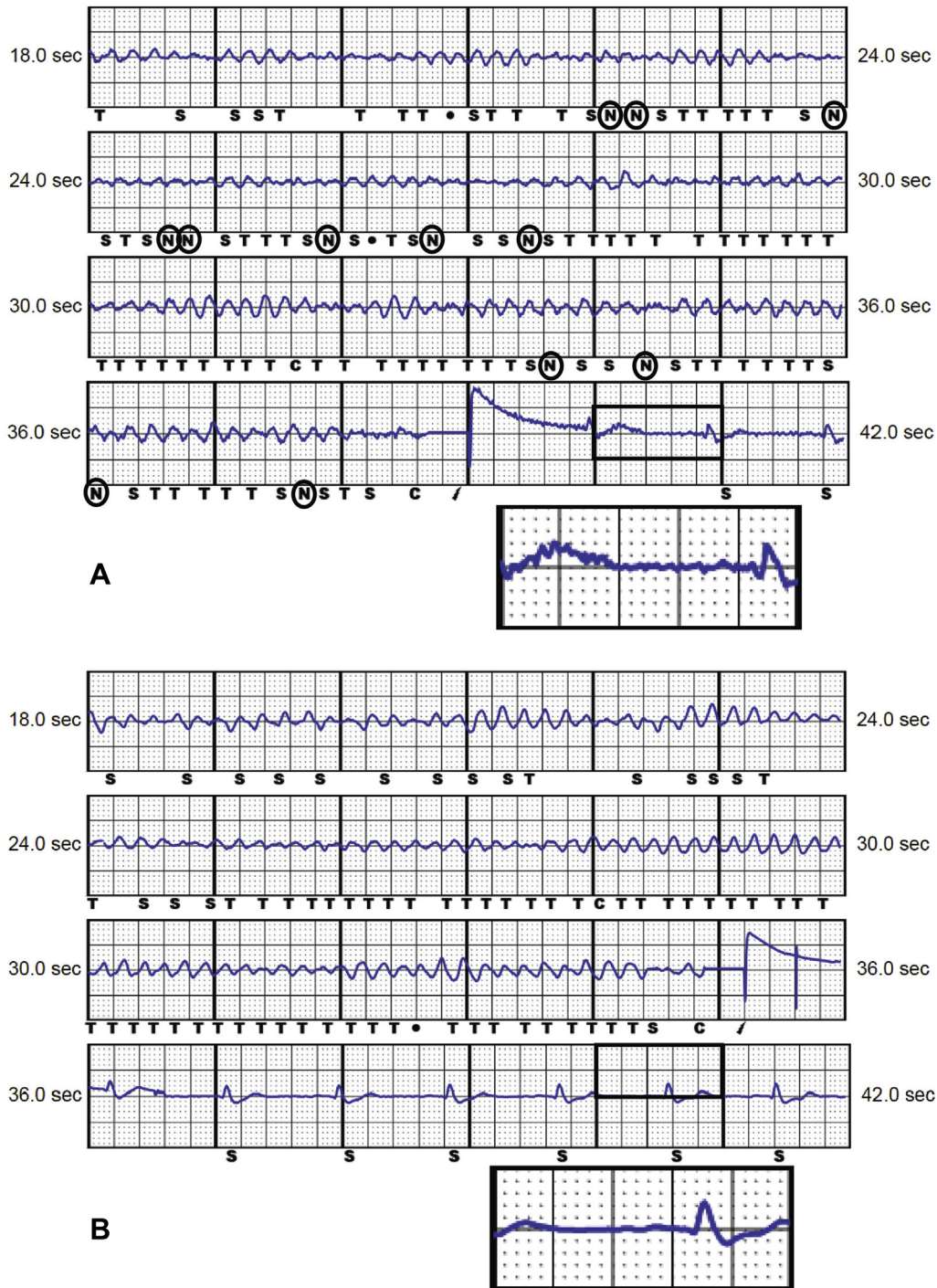


Figure 2 Subcutaneous electrocardiogram of defibrillation testing (DFT) without muscle relaxant (A) and DFT with additional quick-acting intravenous muscle relaxant (B). Ventricular fibrillation was induced by the subcutaneous implantable cardioverter-defibrillator (S-ICD) with a 50 Hz burst and successfully terminated by the S-ICD with a 65 J shock. Noise sensing only occurred during DFT without muscle relaxant (A). C = start induction; N = noise; S = sense; T = tachy detection.

additional muscle-relaxing medication. VF was induced twice by an electrophysiology (EP) catheter and 3 times by the S-ICD. We confirmed the presence or absence of noise by evaluating the subcutaneous electrocardiogram (S-ECG), the intracardiac electrogram (EGM) from the EP catheter, the surface ECG, and the noise-sensing data that was reported by the device. Time to therapy (TTT) was defined as the interval between successful induction, with a

post blanking period of 2000 ms, and onset of the shock as reported previously.⁴ During the DFTs, the configuration settings were temporarily reprogrammed to the sensing vector in which the noise occurred during S-ICD replacement, ie, the primary vector. Prior to induction the S-ECG showed normal electrical signals without visible or marked noise.

First, we performed 2 consecutive DFTs with induction of a ventricular arrhythmia by pacing the right ventricle (RV)

apex with the EP catheter during 3 seconds (5–20 V output, 150–230 ms cycle length). After successful induction of VF, the S-ICD detected the ventricular arrhythmia without any observed noise on the S-ECG, intracardiac EGM, or surface ECG. A successful 80 J shock was delivered by the device with a TTT of 12 seconds. In accordance, the S-ECG did not show any sensed or visible noise after repeating the same procedure (Table 1).

Second, we performed 2 consecutive DFTs following standard S-ICD DFT protocol, with the EP catheter still in place. VF was induced with a 200 mA burst at 50 Hz by the S-ICD for 3 seconds and 5 seconds. Noise was observed and sensed during both DFTs after induction of VF, leading to a TTT of 14 seconds and 22 seconds, respectively (Table 1, Figure 2A). Despite the sensed noise, both DFTs led to successful defibrillation to sinus rhythm.

Third, we performed a single DFT following routine DFT protocol with additional use of a short-acting intravenous muscle relaxant (suxamethonium chloride, 100 mg). Again a 200 mA burst at 50 Hz was given by the S-ICD for 5 seconds with successful induction of VF. Successful termination by the S-ICD followed with a 65 J shock in standard polarity (Figure 2B) without any visible noise on the S-ECG and a TTT of 20 seconds. The difference in noise detection between the different S-ICD testing procedures was confirmed by the engineers of the S-ICD manufacturer.

Discussion

This case report confirms the hypothesis that VF induction performed by the S-ICD can induce involuntary muscle spasm leading to noise sensing with a subsequent withholding of shock therapy. As VF induction by the EP catheter did not result in observable noise or noise sensing, the risk of noise during spontaneous events may be negligible.

A recent published study showed a prolonged TTT in several patients and erroneous absence of VF detection during induced arrhythmias at the time of DFT testing due to noise in 5 patients. All 5 patients were programmed in the primary sensing vector. Data on the position of the S-ICD system were inconclusive.³ In consonance with this previous article, in this case we describe a similar sensing issue leading to inhibition of shock therapy during DFT following elective S-ICD replacement. Within our tertiary center with 10 years of S-ICD experience, 375 de novo S-ICD implants and 140 S-ICD box changes, this was the first and only observed case of noise during DFT with subsequent inhibition of shock therapy. We argue that this sensing issue during DFT only occurs in rare cases.

The S-ICD uses standard detection, certification, and therapy decision algorithms to detect and confirm ventricular arrhythmias.⁵ During the certification phase the S-ICD marks a pattern as noise when the pattern or timing may indicate the signal is caused by noise (eg, muscle spasm or external artefacts). This may cause an event to be labeled as a suspected noise event instead of a cardiac event, leading to an increased

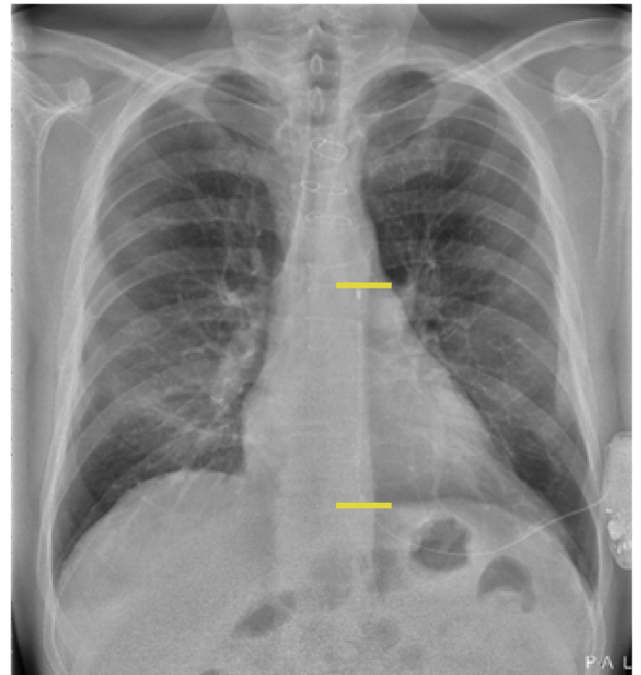


Figure 3 Anteroposterior view of the postimplant chest radiograph. The inferior position of the proximal lead causes a higher risk of stimulating the diaphragm or abdominal musculature, instead of the critical mass of the heart.

TTT or even the inability to reach detection of the arrhythmia and, thereby, withholding of shock therapy.

It is not likely that the noise observed in this case report during elective S-ICD replacement was caused by external artefacts, as the noise did not occur in the secondary sensing vector. The sensing of noise during DFT may be an inherent effect of the induction of VF by the S-ICD, as induction of a ventricular arrhythmia by the S-ICD can also induce thoracic muscle spasm. This VF induced by the S-ICD differs from spontaneous VF that will not lead to any induced thoracic muscle spasm. The difference in noise observation after induction of VF by the S-ICD with and without the use of muscle relaxants supports the hypothesis that the noise was caused by involuntary muscle response. Coil positioning of the S-ICD may have contributed to the muscle spasm and consequent noise, as the lead of the S-ICD was positioned relatively inferior (Figure 3). Since the VF induction burst goes from coil to can, an inferior coil position causes a higher risk of stimulating the diaphragm or abdominal musculature, instead of the critical mass of the heart.

During DFT, the S-ICD initiates the ventricular arrhythmia subcutaneously by a 50 Hz burst for a maximum of 10 seconds. During spontaneous events of ventricular arrhythmias, VF will be initiated within the heart. By pacing the RV to induce VF without any observable noise post induction, we demonstrated that this specific noise most likely will not occur during spontaneous VF episodes. However, as sustained noise during spontaneous events may prevent recording of an episode by the S-ICD, it is not possible to entirely rule out if this problem can occur during spontaneous

episodes of VF. In addition, owing to design limitations of the S-ICD, episodes of VF by pacing the RV were not stored while in telemetered session. Therefore, no S-ECGs were available after EP catheter VF induction for retrospective analysis or publication. Instead we used surface and intracardiac EGM recorded in our catheterization laboratory and data on marked noise from the manufacturer to reconfirm our observations.

Conclusion

This case report confirms that involuntary muscle spasm caused by induction of VF by the S-ICD can in rare cases cause a delay in or absence of VF detection during DFT. Noise sensing only occurred after extracardiac VF induction by the S-ICD without the use of muscle relaxant in the primary sensing vector. Intracardiac induction of VF by an EP catheter did not lead to visible noise on the EGM or sensing of noise by the S-ICD. Changing the sensing vector or using muscle relaxants are solutions to overcome the problem of

delayed or withholding of shock therapy caused by noise sensing during DFT.

Acknowledgments

Sarah W.E. Baalman and Kirsten M. Kooiman contributed equally.

References

1. Burke MC, Gold MR, Knight BP, et al. Safety and efficacy of the totally subcutaneous implantable defibrillator: 2-year results from a pooled analysis of the IDE Study and EFFORTLESS Registry. *J Am Coll Cardiol* 2015;65:1605–1615.
2. Moss AJ, Schuger C, Beck CA, et al. Reduction in inappropriate therapy and mortality through ICD programming. *N Engl J Med* 2012;367:2275–2283.
3. le Polain de Waroux JB, Ploux S, Mondoly P, et al. Defibrillation testing is mandatory in patients with subcutaneous implantable cardioverter-defibrillator to confirm appropriate ventricular fibrillation detection. *Heart Rhythm* 2018;15:642–650.
4. Weiss R, Knight BP, Gold MR, et al. Safety and efficacy of a totally subcutaneous implantable-cardioverter defibrillator. *Circulation* 2013;128:944–953.
5. Sanghera R, Sanders R, Husby M, Bentsen JG. Development of the subcutaneous implantable cardioverter-defibrillator for reducing sudden cardiac death. *Ann N Y Acad Sci* 2014;1329:1–17.