

# Clinical significance of performing Sonazoid-based contrast-enhanced ultrasonography before ablation of uterine fibroids by high-intensity focused ultrasound

## A preliminary cohort study

Lu Zhang, MD<sup>a</sup>, Tae Hee Kim, MD<sup>b</sup>, Kun Zhou, MD<sup>a,\*</sup>, Lifeng Ran, MD<sup>a</sup>, Wei Yang, MD<sup>a</sup>, Hui Zhu, MD<sup>a</sup>

### Abstract

High-intensity focused ultrasound (HIFU) is effective for the ablation of uterine fibroids. However, no research has indicated whether HIFU ablation of uterine fibroids might be improved by application of contrast-enhanced ultrasonography (CEUS) with Sonazoid as a contrast agent. This study aimed to assess the clinical significance of Sonazoid-based CEUS 30 minute before HIFU ablation of uterine fibroids.

This retrospective cohort study included Asian patients with solitary uterine fibroids who were treated with HIFU at Seoul HICARE Clinic (South Korea; n=34) and the Second Affiliated Hospital of Chongqing Medical University (China; n=30) between August 1, 2017, and October 31, 2017. The patients in Seoul underwent Sonazoid-based CEUS 30 minute before HIFU. All the patients received contrast-enhanced magnetic resonance imaging to diagnose uterine fibroids. The ablation results were evaluated 1 day after HIFU by contrast-enhanced magnetic resonance imaging or Sonazoid-based CEUS.

All the patients were successfully treated with HIFU. The CEUS+HIFU group had lower values for sonication power, treatment time, sonication time, total energy applied, and energy efficiency factor compared with HIFU alone group ( $P < .001$ ). There were no major adverse events after ablation therapy in either group. The incidence of post-procedure sacrococcygeal pain was lower in the CEUS +HIFU group than that in the HIFU alone group ( $P = .045$ ), while the incidences of all other intraoperative and postoperative adverse events were similar between the 2 groups.

Our findings suggest that Sonazoid-based CEUS before HIFU may enhance the ablation of uterine fibroids.

**Abbreviations:** CEUS = contrast-enhanced ultrasonography, EEF = energy efficiency factor, FA = fractional ablation, HIFU = high-intensity focused ultrasound, MGSCs = massive grayscale changes, MRI = magnetic resonance imaging, NPV = non-perfused volume.

**Keywords:** clinical significance, contrast-enhanced ultrasonography, high-intensity focused ultrasound, sonazoid, uterine fibroids

Editor: Farzad Taghizadeh-Hesary.

LZ and THK contributed equally to this work.

This study was financially supported by the Chongqing Science and Technology Program for Public Wellbeing (Approval No. cstc2015jcsf10002-14).

The authors have no conflicts of interest to disclose.

The datasets generated during and/or analyzed during the current study are available from the corresponding author on reasonable request.

<sup>a</sup> Clinical Center for Tumor Therapy, the Second Affiliated Hospital, Chongqing Medical University, Chongqing, China, <sup>b</sup> Seoul HICARE Clinic, Seoul, Korea.

\* Correspondence: Kun Zhou, Clinical Center for Tumor Therapy, the Second Affiliated Hospital, Chongqing Medical University, Chongqing, China (e-mail: zhoukun@hospital.cqmu.edu.cn).

Copyright © 2021 the Author(s). Published by Wolters Kluwer Health, Inc. This is an open access article distributed under the terms of the Creative Commons Attribution-Non Commercial License 4.0 (CCBY-NC), where it is permissible to download, share, remix, transform, and buildup the work provided it is properly cited. The work cannot be used commercially without permission from the journal.

How to cite this article: Zhang L, Kim TH, Zhou K, Ran L, Yang W, Zhu H. Clinical significance of performing Sonazoid-based contrast-enhanced ultrasonography before ablation of uterine fibroids by high-intensity focused ultrasound: a preliminary cohort study. *Medicine* 2021;100:2(e24064).

Received: 20 February 2020 / Received in final form: 1 December 2020 / Accepted: 5 December 2020

<http://dx.doi.org/10.1097/MD.00000000000024064>

## 1. Introduction

Uterine fibroids are benign smooth muscle tumors of the uterus.<sup>[1]</sup> Symptomatic uterine fibroids can seriously affect the physical and mental health, as well as quality of life of women at child-bearing age. Common treatments for uterine fibroids include hysterectomy,<sup>[2]</sup> endocrine drugs,<sup>[3]</sup> myomectomy,<sup>[4]</sup> uterine artery embolization,<sup>[5]</sup> and thermal ablation.<sup>[6,7]</sup> High-intensity focused ultrasound (HIFU) is a thermal ablation technique that has been used successfully in the management of patients with uterine fibroids.<sup>[8,9]</sup> Previous studies have revealed that HIFU is an effective and safe treatment for uterine fibroids, causing substantially less morbidity than surgery while achieving a comparable long-term quality of life.<sup>[10,11]</sup> Other investigations have shown that the use of ultrasound contrast agents during the HIFU can assist to localize the lesion, evaluate the blood supply, and assess the ablation area.<sup>[12–14]</sup> Moreover, a recent series of clinical studies indicated that a microbubble contrast agent could enhance HIFU-mediated ablation through cavitation and heating effects.<sup>[15–19]</sup>

Sonazoid consists of microbubbles of perfluorobutane gas with phospholipid monolayer shells. Sonazoid is a microbubble contrast agent used for contrast-enhanced ultrasonography (CEUS) and has been widely used in CEUS examinations of

the liver,<sup>[20,21]</sup> breast,<sup>[22,23]</sup> pancreas,<sup>[24]</sup> brain,<sup>[25,26]</sup> prostate,<sup>[27]</sup> uterus,<sup>[28]</sup> gallbladder,<sup>[29,30]</sup> spleen,<sup>[31]</sup> blood vessels,<sup>[32]</sup> kidney,<sup>[33]</sup> lymph nodes,<sup>[34,35]</sup> and gastrointestinal tract.<sup>[36]</sup> Sonazoid-based CEUS is speculated to be more sensitive to detect the arterial vascularity of target nodules than dynamic computed tomography or magnetic resonance imaging (MRI).<sup>[28]</sup> CEUS with Sonazoid is a straightforward and safe procedure that can be used for repeated examinations, and is currently taken as a valuable diagnostic tool into account for management of patients.<sup>[37]</sup> CEUS with Sonazoid has shown a high sensitivity to the detection of intranodular blood flow. However, correct targeting and guiding steps may benefit from the use of CEUS with Sonazoid.<sup>[20,38]</sup> These characteristics have enabled Sonazoid-based CEUS to be performed before and at various time points after HIFU to assess the response of hepatocellular carcinoma to ablation therapy.<sup>[39,40]</sup>

To the best of our knowledge, no study has evaluated the use of CEUS with Sonazoid during the treatment of benign uterine diseases with HIFU. Therefore, the present research aimed to assess the feasibility and possible clinical significance of Sonazoid-based CEUS 30 minute before the ablation of uterine fibroids by HIFU. For this purpose, a preliminary cohort study was carried out, in which HIFU-associated parameters and adverse events were compared between a series of cases who underwent Sonazoid-based CEUS 30 minute before HIFU therapy and those who only received HIFU therapy. In order to maximize the number of participants in each group, patients who underwent Sonazoid-based CEUS followed by HIFU ablation were enrolled from a clinic in South Korea (where Sonazoid was approved for use as a microbubble contrast agent), while patients who underwent HIFU therapy without CEUS were enrolled from a hospital in China (where Sonazoid has not been approved yet).

## 2. Methods

### 2.1. Study subjects

This retrospective cohort study included Asian patients with uterine fibroids who were treated with HIFU at Seoul HICARE Clinic (Seoul, South Korea) and the Second Affiliated Hospital of Chongqing Medical University (Chongqing, China) between August 1, 2017, and October 31, 2017. The study was approved by the Ethics Committee of Chongqing Medical University. All the patients signed the written informed consent form prior to commencing the study.

### 2.2. Inclusion and exclusion criteria

The inclusion criteria were as follows:

- 1) <sup>[15–17]</sup> patients who aged  $\geq 18$  years old;
- 2) patients with symptomatic uterine fibroids who were confirmed by clinical examination, ultrasonography, and enhanced-MRI;
- 3) fibroid was  $> 5$  cm in diameter;
- 4) patients with premenopausal symptoms; and
- 5) patients who were able to communicate with clinical staff during treatment.

1) The exclusion criteria were as follows:

- 2) pregnancy;
- 3) uterine or cervical malignancy or pre-malignancy;

- 4) multiple fibroids; and
- 5) adenomyosis.

### 2.3. Pre-HIFU MRI

All the patients underwent pre-HIFU MRI according to a standardized protocol. The targeted fibroids were measured in 3 dimensions: longitudinal (D1), anteroposterior (D2), and transverse (D3). The fibroid volume (V) was calculated using the following equation:<sup>[41,42]</sup>  $V = 0.5233 \times D1 \times D2 \times D3$ .

Preparation of the gastrointestinal tract involved 2 days of liquid food only, a 12-hour fasting, and finally, an enema before undergoing HIFU, as described previously.<sup>[15,16]</sup> Preparation of the skin included shaving, degassing, and degreasing of the skin of the anterior abdominal wall from the level of the umbilicus to the level of the pubic symphysis. A urinary catheter was placed to control bladder volume by the injection of normal saline or collection of urine. A balloon filled with degassed water was used to displace the bowel away from the acoustic pathway in order to prevent intestinal toxicity and minimize interference to the ultrasound images.

### 2.4. CEUS examination

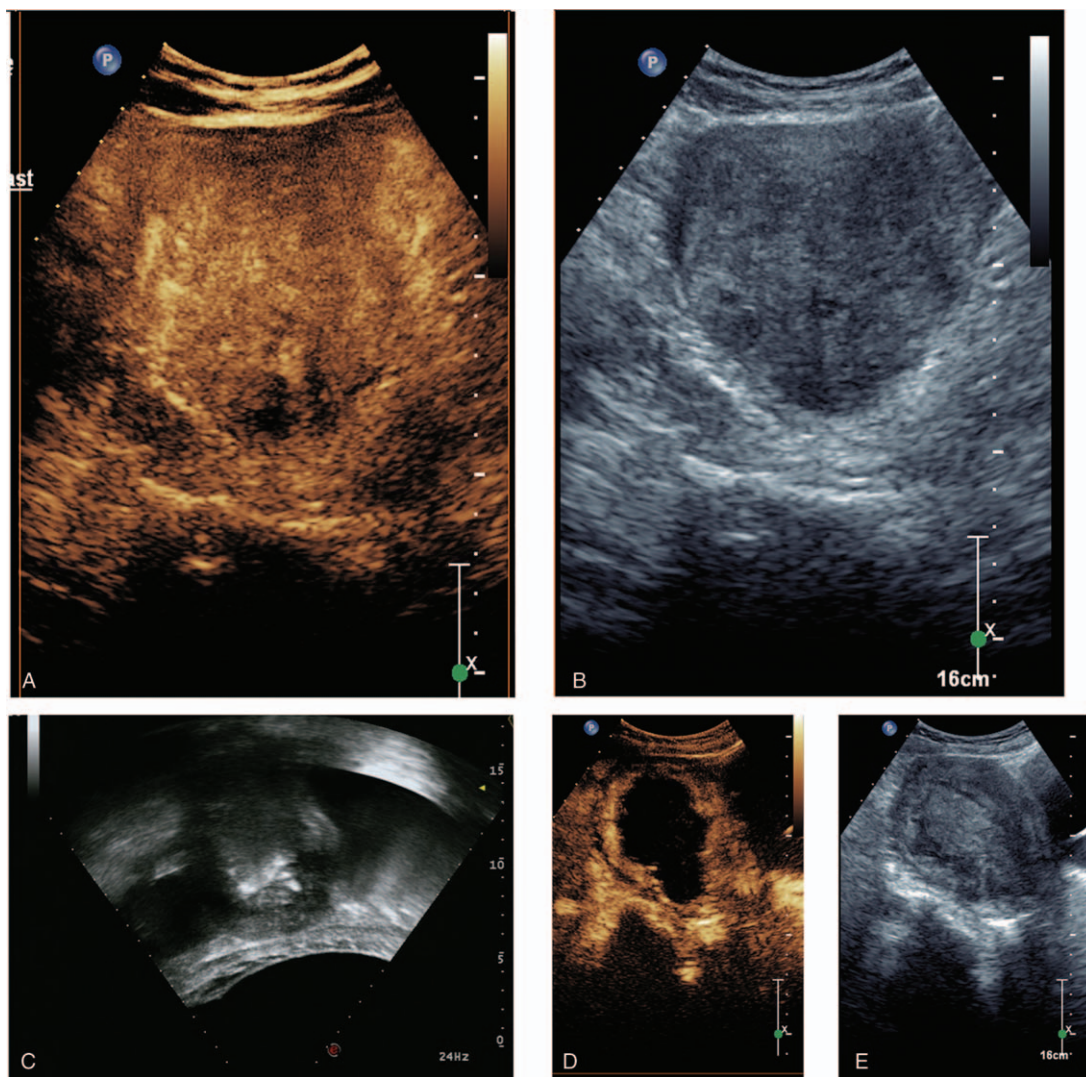
All the patients who were admitted to Seoul HICARE Clinic underwent Sonazoid-based CEUS examination 30 minute before HIFU therapy (EPIQ 7 Ultrasound System, Philips, Amsterdam, Netherlands). Before the CEUS examination, 1 vial (16  $\mu$ L) of Sonazoid (GE Healthcare, Oslo, Norway) was solubilized in 2 mL of water for injection. The 2-mL Sonazoid-water suspension was injected intravenously into each patient, and this was followed by the intravenous injection of 2 mL of a 5% glucose solution and subsequent infusion of 5% glucose solution at a rate of 10 mL/min.<sup>[39,40]</sup>

At the time of the study, Sonazoid had not been approved for clinical application in China. Therefore, patients who were admitted to the Second Affiliated Hospital of Chongqing Medical University did not undergo Sonazoid-based CEUS, while they received intravenous infusion of a 5% glucose solution (at a rate of 10 mL/min) 30 minute before treatment with HIFU.<sup>[39,40]</sup>

### 2.5. HIFU therapy

HIFU ablation was performed using an ultrasound-guided JC HIFU System (Chongqing Haifu Medical Technology Co., Ltd., Chongqing, China). Therapeutic ultrasound with a frequency of 0.8 MHz was produced from a transducer with a diameter of 20 cm and a focal length of 15 cm. Real-time imaging was performed using an ultrasound imaging device (MyLab 70, Esaote, Genoa, Italy) with a 1.0 to 8.0 MHz imaging probe coupled to a transducer.

The patient was placed in a prone position, and the anterior abdominal wall was placed in contact with the degassed water. A balloon filled with degassed water was placed between the transducer and patient's abdominal wall when bowel appeared in the acoustic pathway. HIFU therapy was carried out under intravenous conscious sedation<sup>[15,16,18]</sup> with fentanyl (50–400  $\mu$ g) and midazolam hydrochloride (1–4 mg). Vital signs, including heart and respiration rates, blood pressure, and oxygen saturation level, were monitored continuously during HIFU ablation, and the patient was requested to report any discomfort during the procedure.



**Figure 1.** Imaging data obtained from a 48-year-old patient with uterine fibroid who successfully underwent Sonazoid-based contrast-enhanced ultrasonography (CEUS) followed by high-intensity focused ultrasound (HIFU) ablation. A: Pre-treatment CEUS image showing perfusion of a fibroid. B: Pre-treatment US image of a fibroid (5.6 cm 4.9 cm 5.1 cm). C: HIFU sonication at 30 minute after administration of Sonazoid. Massive grayscale changes occurred at 35 second of sonication. The total sonication time for this fibroid was 677 second. D: CEUS image obtained 1-day after the completion of HIFU ablation showing no perfusion of the treated fibroid. E: US image obtained 1-day after the completion of HIFU ablation displaying the B-mode ultrasonographic image of the treated fibroid.

HIFU ablation was conducted using a focal point exposure of 1 to 2 second and an initial power of 100 W that was increased to 400 W in steps of 50 W. The power was not further increased if massive grayscale changes (MGSCs) could be achieved. The HIFU treatment was considered to be completed when the hyperechoic grayscale area (MGSC or total increased grayscale) encompassed the margin of the fibroid. The patient was discharged from the HIFU unit 24 hour after the therapy. Vital signs were monitored during hospitalization.

## 2.6. Evaluation of the treatment effects

Contrast-enhanced Sonazoid-based CEUS (Fig. 1) or MRI (Fig. 2) was performed 1 day after HIFU therapy, and the images were used to measure the non-perfused volume (NPV), which was defined as the tumor coagulation volume. The NPV was calculated using the same equation as that for fibroid volume

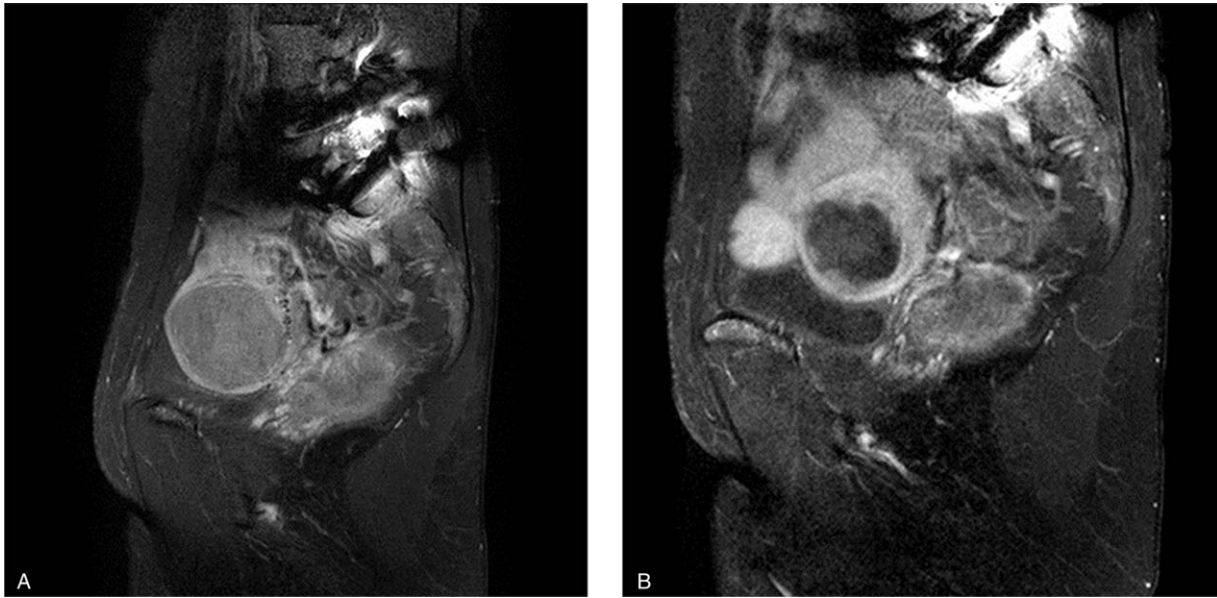
before treatment (i.e.,  $V = 0.5233 \times D1 \times D2 \times D3$ ). The fractional ablation (FA) was defined as the NPV divided by the fibroid volume before HIFU therapy. All the images were evaluated by an experienced radiologist, who measured the size of the targeted fibroid and the non-enhanced regions.

The HIFU-associated parameters included average sonication power (an average power during the HIFU treatment), duration of HIFU sonication defined as the total time of HIFU treatment (ultrasonic irradiation time), treatment time, duration of general anesthesia, total energy, energy efficiency factor (EEF), and occurrence rate of MGSCs describing changes in mass grayscale before and after HIFU treatment.

## 2.7. Statistical analysis

Statistical analysis was performed using SPSS 22.0 software (IBM Corp., Armonk, NY). Data were presented as the mean  $\pm$





**Figure 2.** Successful treatment of a patient with uterine fibroid using Sonazoid to enhance high-intensity focused ultrasound treatment effects. A. Pre-treatment T1-weighted contrast-enhanced MR image illustrating perfusion of the fibroid. B. Post-treatment T1-weighted contrast-enhanced MR image showing that the fibroid was mostly ablated.

standard deviation or  $n/N$  (%). The Student  $t$  test was used for comparing patients' age, tumor size, fibroid volume, NPV, FA, total sonication time, average power, treatment time, average total energy, and EEF between the CEUS+HIFU group and HIFU alone group. The Chi-squared test was employed to compare lesion site, MRI T2 signals, MGSC rate, and incidence of adverse events/complications between the 2 groups. A  $P$ -value  $< .05$  indicated a significant difference.

### 3. Results

#### 3.1. The patients' baseline clinical characteristics

Among 64 patients who were included in this study, 34 were admitted to the Seoul HICARE Clinic and underwent Sonazoid-based CEUS examination followed by HIFU, while 30 were admitted to the Second Affiliated Hospital of Chongqing Medical University and underwent HIFU without CEUS. The patients' baseline clinical characteristics of the in the 2 groups are shown in Table 1. The patients' mean age was  $42.52 \pm 7.63$  (range, 27–57) years old in the CEUS+HIFU group and  $39.17 \pm 6.34$  (range, 23–48) years old in the HIFU alone group. There were no significant differences between the 2 groups in patients' age, fibroid diameter or fibroid volume (Table 1). However, the CEUS+HIFU group

had a significantly higher proportion of fibroids located in the lateral wall of the uterus ( $P < .001$ ), in addition to a significantly higher proportion of fibroids with a low MRI T2 signal intensity ( $P < .001$ ).

#### 3.2. Sonazoid-based CEUS 30 min before HIFU

The 34 patients in the CEUS+HIFU group were examined using Sonazoid-based CEUS 30 minute before HIFU. Sonazoid-based CEUS detected only 1 lesion in each patient, and all the fibroids exhibited microbubble enhancement during CEUS. Furthermore, all the fibroids identified by CEUS were in the same locations as those observed by MRI.

#### 3.3. HIFU-associated parameters and the response to ablation therapy

All the HIFU procedures were completed successfully in both groups. Hyperechogenic grayscale changes were observed in all the patients during HIFU therapy. In the CEUS group, MGSCs in the fibroids were found in 34/34 patients (100%) in the CEUS+HIFU group and 25/30 patients (83.3%) in the HIFU alone group; the fibroids in the remaining 5 patients in the HIFU alone group exhibited an increase in the total grayscale value (Table 2).

**Table 1**  
Baseline clinical characteristics of the study participants.

Characteristic	HIFU alone (n=30)	CEUS+HIFU (n=34)	P
Age (yr), mean $\pm$ SD	$39.17 \pm 6.34$	$42.52 \pm 7.63$	.083
Uterine fibroid location (anterior/posterior/lateral wall)	8/14/8	3/1/30	$< .001$
Long diameter of uterine fibroid (cm), mean $\pm$ SD	$7.32 \pm 1.67$	$7.03 \pm 1.66$	.443
Volume of uterine fibroid ( $\text{cm}^3$ ), mean $\pm$ SD	$198.13 \pm 112.90$	$246.17 \pm 226.96$	.904
MRI T2 signal intensity of fibroid (high/intermediate/low)	15/6/9	4/0/30	$< .001$

CEUS = contrast-enhanced ultrasonography, HIFU = high-intensity focused ultrasound, SD = standard deviation.

**Table 2****Characteristics of the high-intensity focused ultrasound ablation therapy.**

Parameter	HIFU alone (n=30)	CEUS+HIFU (n=34)	P
Sonication power (W)	399.4±1.9	204.3±37.6	<.001 <sup>a</sup>
Treatment time (min)	181.3±36.3	44.2±15.4	<.001 <sup>a</sup>
Sonication time (s)	2824.1±419.8	358.4±271.3	<.001 <sup>a</sup>
Total energy used (kJ)	1127.8±165.4	76.2±58.8	<.001 <sup>a</sup>
Energy efficiency factor (J/mm <sup>3</sup> )	10.9±6.3	1.6±0.3	<.001 <sup>a</sup>
Non-perfused volume (cm <sup>3</sup> )	136.0±73.8	161.6±129.1	.872 <sup>a</sup>
Fractional ablation (%)	70.0±7.6	70.9±13.5	.788 <sup>a</sup>
Massive grayscale changes n, (%)	25/30 (83.3%)	34/34 (100%)	.190 <sup>b</sup>

Data are presented as the mean ± standard deviation or n/N (%). CEUS = contrast-enhanced ultrasonography, HIFU = high-intensity focused ultrasound, MGSC = massive grey scale change.

<sup>a</sup> t test.

<sup>b</sup> Chi-squared test.

The average values for sonication power, treatment time, sonication time, total energy applied, and EEF were all significantly lower in the CEUS+HIFU group compared with those in the HIFU alone group ( $P < .001$ ; Table 2). However, there were no significant differences between the 2 groups in the NPV or FA after treatment (Table 2).

### 3.4. Adverse events

Adverse events reported during the HIFU procedure included sacrococcygeal pain, pain in the treatment zone, rectal pain, tenesmus, and leg pain (Table 3). However, there were no significant differences between the 2 groups in the incidences of adverse events during HIFU therapy.

Immediate postoperative adverse events included sacrococcygeal pain, lower abdominal pain, fever, vaginal discharge, lower limb paresthesia, and anal distension (Table 4). The incidence of sacrococcygeal pain was significantly lower in the CEUS+HIFU group than in the HIFU alone group ( $P = .045$ ), while the incidences of the other adverse events were similar between the 2 groups (Table 4). All the patients were discharged 1 day after the HIFU treatment. No patients reported noteworthy clinical symptoms during the first 3 days post-HIFU.

## 4. Discussion

To date, utilization of Sonazoid-based CEUS during treatment of benign uterine diseases with HIFU has never been reported. Therefore, the current retrospective study included Asian patients

**Table 3****Incidence of adverse events during treatment.**

Adverse event	HIFU alone (n=30)	CEUS+HIFU (n=34)	P
Sacrococcygeal pain	5/30 (16.7%)	4/34 (11.8%)	.573
Skin burn	0/30 (0%)	0/34 (0%)	–
Pain in treatment zone	6/30 (20.0%)	8/34 (23.5%)	.733
Groin pain	1/30 (3.3%)	0/34 (0%)	.469
Sensation of rectal tenesmus	2/30 (6.7%)	1/34 (2.9%)	.482
Leg pain	1/30 (3.3%)	0/34 (0%)	.469

Data are presented as n/N (%). The following pain rating scale was used: 0 = painless; 1 to 2 = mild pain; 3 to 4 = moderate pain; 5 to 6 = severe pain; 7 to 8 = very severe pain; and 9 to 10 = unbearable pain. The pain score was <4 points in all patients.

**Table 4****Immediate postoperative adverse effects.**

Adverse event	HIFU alone (n=30)	CEUS+HIFU (n=34)	P
Fever	3/30 (10.0%)	3/34 (8.8%)	.872
Lower abdominal pain	4/30 (13.3%)	2/34 (5.9%)	.307
Sacrococcygeal pain	7/30 (23.3%)	2/34 (5.9%)	.045
Paresthesia of lower limb	1/30 (3.3%)	0/34 (0%)	.469
Vaginal discharge	3/30 (10.0%)	2/34 (5.9%)	.540
Skin injury	0/30 (0%)	0/34 (0%)	–
Anal distention	1/30 (3.3%)	1/34 (2.9%)	.928

Data are presented as n/N (%). The following pain rating scale was used: 0 = painless; 1 to 2 = mild pain; 3 to 4 = moderate pain; 5 to 6 = severe pain; 7 to 8 = very severe pain; and 9 to 10 = unbearable pain. The pain score was <4 points in all patients.

with uterine fibroids who were treated with HIFU, and HIFU-associated parameters and side effects were compared between a series of cases who were only treated with HIFU and those who underwent Sonazoid-based CEUS 30 minute before HIFU. A notable finding of the present study was that the CEUS+HIFU group had lower values for sonication power, treatment time, sonication time, total energy applied, and EFF than the HIFU alone group. Furthermore, there were no major adverse events after HIFU therapy in either group, and the incidences of intraoperative and postoperative adverse events were similar between the 2 groups (with the exception of sacrococcygeal pain, which was less frequent in the CEUS+HIFU group than in the HIFU alone group). Taken together, our findings suggest that Sonazoid-based CEUS 30 minute before HIFU may enhance the ablation of uterine fibroids. However, the interpretation of the results should be performed with a degree of caution due to the limitations in the study design, particularly enrollment of the patients from different hospitals in different countries.

The objective of HIFU is to deliver mechanical energy in form of a penetrating ultrasound wave and to create coagulation necrosis in a focal region. CEUS with a microbubble contrast agent is a diagnostic tool that can be performed easily in a preoperative or intraoperative/intraprocedural setting to diagnose benign and malignant diseases and to evaluate post-ablation outcome in several organs.<sup>[20,39,40,43,44]</sup> Intraoperative CEUS is safe and facilitates the early detection of residual fibroid tissue after ablation, thereby reducing the risk associated with further treatments.<sup>[19]</sup> Previous studies have demonstrated that CEUS can be performed whenever during HIFU. Numata et al<sup>[40]</sup> utilized CEUS to evaluate malignant liver tumors before, immediately after, 1 week after, and 1 month after HIFU, and they concluded that CEUS was a significant method for evaluating the therapeutic efficacy of HIFU in the ablation of hepatocellular carcinoma. Moreover, Wang et al,<sup>[45]</sup> Liu et al,<sup>[3]</sup> Orsi et al,<sup>[19]</sup> Peng et al<sup>[15]</sup> and Zhou et al<sup>[14]</sup> successfully used CEUS to examine benign uterine diseases (uterine fibroids and adenomyosis) before, during, and after HIFU treatment. CEUS has been shown to enhance ultrasound guidance during HIFU ablation of uterine fibroids<sup>[19]</sup> and has a diagnostic accuracy of 100%.<sup>[14]</sup> The patients were evaluated with CEUS during the HIFU session and further sonication was performed in the same setting, if needed, according to the enhanced US imaging. In the current study, CEUS performed during HIFU treatment facilitated early detection of residual (i.e., non-enhanced) tumors in 8 fibroids that were then completely treated within the same session. The use of CEUS during HIFU provides a more consistent ablative effect, and in case of treatment of uterine fibroids, it is

manifested with a faster volume shrinkage. In good agreement with the results of other studies,<sup>[15,17]</sup> we found that the imaging data obtained with CEUS were correlated with those achieved by MRI, and CEUS could confirm the extent of fibroid ablation. Therefore, our observations corroborate previous researches, indicating that intraprocedural CEUS is a reliable method for enhancing ultrasound guidance and assessing the efficacy of HIFU therapy. To the best of our knowledge, no previous research has concentrated on the use of Sonazoid-based CEUS during HIFU ablation of uterine fibroids. Thus, our novel findings may provide evidence supporting the clinical significance of Sonazoid-based CEUS during HIFU therapy for uterine fibroids.

In the current study, Sonazoid-based CEUS prior to HIFU ablation was conducted on all the 34 patients in the CEUS group. Furthermore, the 34 uterine fibroids detected by Sonazoid-based CEUS were observed at a similar location to that determined by MRI. HIFU therapy was performed successfully on all the patients, and there were no significant differences between the groups in the proportion of fibroids showing hyperechogenic grayscale changes (MGSCs and increases in total grayscale) after HIFU therapy. The extent of fibroid ablation (i.e., FA) ranged from 40.8% to 99.1% (median, 70.5%), and it was similar between the 2 groups. These results demonstrate the feasibility of performing Sonazoid-based CEUS during HIFU.

Notably, significant differences between the 2 groups were quantified for some HIFU-associated parameters. Compared with the HIFU alone group, the CEUS+HIFU group achieved a similar FA with a shorter sonication time, a lower average power, a lower total energy, and a smaller EEF. The above-mentioned findings indicated that Sonazoid-based CEUS could enhance the ablation of uterine fibroids by HIFU, and are consistent with the results of previous studies.<sup>[15–17,19,21]</sup> However, the enhancement of HIFU ablation by SonoVue-based CEUS occurred at a short interval (<10 minute) between CEUS and HIFU therapy, whereas we observed a beneficial effect of Sonazoid-based CEUS when it was used 30 minute before HIFU. This phenomenon may be attributed to the rate of Sonazoid metabolism after injection. For instance, the amount of Sonazoid in the portal vein blood of healthy volunteers was  $60.1 \pm 12.9\%$ ,  $41.4 \pm 11.4\%$ ,  $32.0 \pm 10.3\%$ , and  $7.8 \pm 4.5\%$  at 10, 20, 30, and 60 minute after injection.<sup>[46]</sup> Thus, up to 32% of the injected Sonazoid microbubbles could remain in the circulation 30 minute after Sonazoid-based CEUS. The retained microbubbles might serve as cavitation nuclei to cause mechanical injury to the target tissue and enhance the thermal effect during exposure to HIFU. These effects of residual Sonazoid may enable HIFU to achieve the same level of ablation with a lower amount of energy.<sup>[18,19,47]</sup>

Adverse reactions to Sonazoid are uncommon, and a study on 193 patients reported albuminuria in 1.6% of cases and diarrhea in 1.6%.<sup>[21]</sup> Moreover, no side effects were found in other studies that utilized Sonazoid-based CEUS to evaluate hepatocellular carcinoma and its response to thermal ablation.<sup>[39,40]</sup> In agreement with a previous research, no major complications were observed in the current study, and the incidence of adverse events was similar between the CEUS+HIFU group and HIFU alone group. Our results indicated that Sonazoid-based CEUS did not increase the risk of injury during HIFU therapy, although the presence of residual Sonazoid microbubbles 30 minute after CEUS could pose a theoretical risk. Although residual Sonazoid microbubbles would distribute uniformly to the various tissues of the body (including uterine fibroids), it is likely that the

inhomogeneity of the energy in the HIFU acoustic field could result in significant Sonazoid-induced cavitation and occurrence of heating only in the focal region targeted by HIFU, since the energy at the focal region would be significantly higher than that at other parts of the acoustic field. Thus, minimal injury would be expected to occur in tissues outside the focal region of ablation. Furthermore, if Sonazoid-based CEUS could decrease the amount of HIFU energy required for ablation, it could reduce the potential risk of HIFU-induced complications.<sup>[19]</sup> It is noteworthy that in the present study, the incidence of sacrococcygeal pain was lower in the CEUS+HIFU group than that in the HIFU alone group. As sacrococcygeal pain could be related to tissue injury due to the penetration of HIFU beyond the target region to the sacrococcygeal region, it can be concluded that the use of a lower total energy in the CEUS+HIFU group may reduce HIFU-induced tissue injury in the sacrococcygeal region. In agreement with results of the present study, Jiang et al<sup>[16]</sup> and Cheng et al<sup>[18]</sup> reported a significantly smaller EEF and a lower incidence of sacrococcygeal pain in SonoVue-based CEUS group compared with control group.

An important limitation of the present study is that the 2 groups of patients were recruited from different hospitals in different countries, and this may cause several confounding factors, potentially influencing the results. Possible confounding factors include patient ethnicity, operator's work experience, MRI T2 signal intensity of the fibroid, and uterine fibroid location. The HIFU alone group contained a remarkably higher proportion of fibroids with a high or intermediate MRI T2 signal intensity, which are generally considered more difficult to ablate. Furthermore, the HIFU alone group also contained a higher proportion of fibroids on the posterior uterine wall, and it is well-known that deep-seated fibroids are more challenging to ablate. As these factors may cause bias in the results in the CEUS+HIFU group, we urge caution in the interpretation of our data. Nevertheless, our findings are in a satisfactory agreement with results of previous studies that investigated SonoVue-based CEUS. Furthermore, a similar method of patient enrollment has been used in a previously published research.<sup>[15]</sup> Therefore, despite the limitations of our preliminary study, our novel findings may lay a foundation for a future prospective, randomized controlled trial.

Another limitation of the current study was related to the inclusion of only patients with large (> 5 cm) solitary fibroids. Our decision to concentrate on patients with large uterine fibroids was based on a previous observation that the enhancing effects of SonoVue microbubbles were greater on fibroids < 4 cm than those on > 4 cm.<sup>[15]</sup> Another limitation of the current study was the small sample size. Hence, further large scale, multicenter, randomized controlled trials are warranted to confirm and extend the findings of the present research.

## 5. Conclusions

The results of this preliminary clinical study suggested that Sonazoid-based CEUS performed 30 minute before HIFU might enhance the ablation of uterine fibroids. Sonazoid-based CEUS could decrease the sonication power, treatment time, sonication time, total energy applied, and energy efficiency factor of the HIFU procedure, without additional adverse events. However, our data should be interpreted with a degree of caution due to the limitations in the study design, which may involve confounding factors. Further prospective, randomized controlled trials need to



be carried out to validate our findings, and to indicate whether the use of Sonazoid-based CEUS before HIFU ablation is clinically significant.

### Author contributions

**Conceptualization:** Lu Zhang, Tae Hee Kim, Kun Zhou, Hui Zhu.

**Investigation:** Lu Zhang, Tae Hee Kim, Lifeng Ran, Wei Yang, Hui Zhu.

**Methodology:** Lu Zhang, Tae Hee Kim, Lifeng Ran, Wei Yang, Hui Zhu.

**Writing – original draft:** Lu Zhang.

**Writing – review & editing:** Kun Zhou.

### References

- Okolo S. Incidence, aetiology and epidemiology of uterine fibroids. *Best Pract Res Clin Obstet Gynaecol* 2008;22:571–88.
- Nakayama K, Tsukao M, Ishikawa M, et al. Total laparoscopic hysterectomy for large uterine cervical myoma. *Mol Clin Oncol* 2017;6:655–60.
- Liu C, Lu Q, Qu H, et al. Different dosages of mifepristone versus enantone to treat uterine fibroids: a multicenter randomized controlled trial. *Medicine (Madr)* 2017;96:e6124–1.
- Agdi M, Tulandi T. Minimally invasive approach for myomectomy. *Semin Reprod Med* 2010;28:228–34.
- Fonseca MCM, Castro R, Machado M, et al. Uterine artery embolization and surgical methods for the treatment of symptomatic uterine leiomyomas: a systemic review and meta-analysis followed by indirect treatment comparison. *Clin Ther* 2017;39:1438–55.
- Iversen H, Dueholm M. Radiofrequency thermal ablation for uterine myomas: long-term clinical outcomes and reinterventions. *J Minim Invasive Gynecol* 2017;24:1020–8.
- Toub DB. A new paradigm for uterine fibroid treatment: transcervical, intrauterine sonography-guided radiofrequency ablation of uterine fibroids with the sonata system. *Curr Obstet Gynecol Rep* 2017;6:67–73.
- Pessarrodona A, Isern J, Rodriguez J, et al. Treatment of uterine fibroids using high-intensity ultrasound. *Med Clin (Barc)* 2013;141(Suppl 1):22–9.
- Chen J, Li Y, Wang Z, et al. Evaluation of high-intensity focused ultrasound ablation for uterine fibroids: an IDEAL prospective exploration study. *BJOG* 2018;125:354–64.
- Quinn SD, Vedelago J, Gedroyc W, et al. Safety and five-year re-intervention following magnetic resonance-guided focused ultrasound (MRgFUS) for uterine fibroids. *Eur J Obstet Gynecol Reprod Biol* 2014;182:247–51.
- Chen J, Chen W, Zhang L, et al. Safety of ultrasound-guided ultrasound ablation for uterine fibroids and adenomyosis: a review of 9988 cases. *Ultrason Sonochem* 2015;27:671–6.
- Solbiati L, Tonolini M, Cova L, et al. The role of contrast-enhanced ultrasound in the detection of focal liver lesions. *Eur Radiol* 2001;11(Suppl 3):E15–26.
- Kennedy JE, ter Haar GR, Wu F, et al. Contrast-enhanced ultrasound assessment of tissue response to high-intensity focused ultrasound. *Ultrasound Med Biol* 2004;30:851–4.
- Zhou XD, Ren XL, Zhang J, et al. Therapeutic response assessment of high intensity focused ultrasound therapy for uterine fibroid: utility of contrast-enhanced ultrasonography. *Eur J Radiol* 2007;62:289–94.
- Peng S, Xiong Y, Li K, et al. Clinical utility of a microbubble-enhancing contrast (“SonoVue”) in treatment of uterine fibroids with high intensity focused ultrasound: a retrospective study. *Eur J Radiol* 2012;81:3832–8.
- Jiang N, Xie B, Zhang X, et al. Enhancing ablation effects of a microbubble-enhancing contrast agent (“SonoVue”) in the treatment of uterine fibroids with high-intensity focused ultrasound: a randomized controlled trial. *Cardiovasc Intervent Radiol* 2014;37:1321–8.
- Isern J, Pessarrodona A, Rodriguez J, et al. Using microbubble sonographic contrast agent to enhance the effect of high intensity focused ultrasound for the treatment of uterine fibroids. *Ultrason Sonochem* 2015;27:688–93.
- Cheng C, Xiao Z, Huang G, et al. Enhancing ablation effects of a microbubble contrast agent on high-intensity focused ultrasound: an experimental and clinical study. *BJOG* 2017;124(Suppl 3):78–86.
- Orsi F, Monfardini L, Bonomo G, et al. Ultrasound guided high intensity focused ultrasound (USgHIFU) ablation for uterine fibroids: do we need the microbubbles? *Int J Hyperthermia* 2015;31:233–9.
- Park HS, Kim YJ, Yu MH, et al. Real-time contrast-enhanced sonographically guided biopsy or radiofrequency ablation of focal liver lesions using perflurobutane microbubbles (sonazoid): value of Kupffer-phase imaging. *J Ultrasound Med* 2015;34:411–21.
- Jiang H, Luo S, He M. A retrospective study: high intensity focused ultrasound (HIFU) associated a microbubble-enhancing contrast (“SonoVue”) therapy for uterine fibroids with pelvic operation history. *J Kunming Med Univ* 2013;9:33.
- Omoto K, Matsunaga H, Take N, et al. Sentinel node detection method using contrast-enhanced ultrasonography with Sonazoid in breast cancer: preliminary clinical study. *Ultrasound Med Biol* 2009;35:1249–56.
- Miyamoto Y, Ito T, Takada E, et al. Efficacy of Sonazoid (perflubutane) for contrast-enhanced ultrasound in the differentiation of focal breast lesions: phase 3 multicenter clinical trial. *AJR Am J Roentgenol* 2014;202:W400–7.
- Imazu H, Uchiyama Y, Matsunaga K, et al. Contrast-enhanced harmonic EUS with novel ultrasonographic contrast (Sonazoid) in the preoperative T-staging for pancreaticobiliary malignancies. *Scand J Gastroenterol* 2010;45:732–8.
- Saito K, Hirai T, Ueno S. Transcranial contrast-enhanced ultrasonography with Sonazoid in semiquantitative evaluation of brain perfusion. *J Med Ultrason* (2001) 2013;40:133–9.
- Saito K, Hirai T, Ohishi H, et al. Initial experience of transcranial contrast-enhanced ultrasonography with Sonazoid in the evaluation of microvascular brain anatomy. *J Med Ultrason* (2001) 2009;36:137–43.
- Uemura H, Sano F, Nomiya A, et al. Usefulness of perflubutane microbubble-enhanced ultrasound in imaging and detection of prostate cancer: phase II multicenter clinical trial. *World J Urol* 2013;31:1123–8.
- Makino S, Hirai C, Itakura A, et al. Evaluation of uterine blood flow: a new method using contrast-enhanced ultrasound. *Eur J Obstet Gynecol Reprod Biol* 2015;191:143–4.
- Kawai R, Hata J, Manabe N, et al. Contrast-enhanced ultrasonography with Sonazoid for diagnosis of gangrenous cholecystitis. *J Med Ultrason* (2001) 2016;43:193–9.
- Sugihara T, Koda M, Kato J, et al. Contrast-enhanced sonography with Sonazoid as a new diagnostic tool for splenic hamartoma: a single case report. *J Med Ultrason* (2001) 2016;43:113–8.
- Saito K, Hirai T, Ohishi H. Contrast-enhanced carotid ultrasonography with Sonazoid in evaluation of neovascularization in carotid artery plaques. *Neurosonology* 2008;21:176–82.
- Okayama S, Hirai T, Yamashita N, et al. Contrast-enhanced ultrasonography with Sonazoid for evaluation of renal microcirculation. *J Med Ultrason* (2001) 2008;35:183–9.
- Kawai Y, Ajima K, Nagai T, et al. Real-time imaging of the lymphatic channels and sentinel lymph nodes of the stomach using contrast-enhanced ultrasonography with Sonazoid in a porcine model. *Cancer Sci* 2011;102:2073–81.
- Manabe N, Hata J, Haruma K, et al. Active gastrointestinal bleeding: evaluation with contrast-enhanced ultrasonography. *Abdom Imaging* 2010;35:637–42.
- Matsuzawa F, Einama T, Abe H, et al. Accurate diagnosis of axillary lymph node metastasis using contrast-enhanced ultrasonography with Sonazoid. *Mol Clin Oncol* 2015;3:299–302.
- Moriyasu F, Itoh K. Efficacy of perflubutane microbubble-enhanced ultrasound in the characterization and detection of focal liver lesions: phase 3 multicenter clinical trial. *AJR Am J Roentgenol* 2009;193:86–95.
- Minami Y, Kudo M. Contrast-enhanced ultrasonography with Sonazoid in hepatocellular carcinoma diagnosis. *Hepatoma Res* 2020;6:46–57.
- Eso Y, Takai A, Takeda H, et al. Sonazoid-enhanced ultrasonography guidance improves the quality of pathological diagnosis in the biopsy of focal hepatic lesions. *Eur J Gastroenterol Hepatol* 2016;28:1462–7.
- Fukuda H, Ito R, Ohto M, et al. Treatment of small hepatocellular carcinomas with US-guided high-intensity focused ultrasound. *Ultrasound Med Biol* 2011;37:1222–9.
- Numata K, Fukuda H, Ohto M, et al. Evaluation of the therapeutic efficacy of high-intensity focused ultrasound ablation of hepatocellular carcinoma by three-dimensional sonography with a perflubutane-based contrast agent. *Eur J Radiol* 2010;75:e67–75.
- Jingqi W, Lu Z, Jun Z, et al. Clinical Usefulness of the microbubble contrast agent sonovue in enhancing the effects of high-intensity focused

- ultrasound for the treatment of adenomyosis. *J Ultrasound Med* 2018;37:2811–9.
- [42] Hangarga US, Rita D. Low dose mifepristone in the treatment of uterine leiomyoma. *Int J Reprod Contracept Obstet Gynecol* 2017;6:44–8.
- [43] Hui-Xiong Xu. Contrast-enhanced ultrasound: the evolving applications. *World J Radiol* 2009;1:15–24.
- [44] Gallotti A, D’Onofrio M, Ruzzenente A, et al. Contrast-enhanced ultrasonography (CEUS) immediately after percutaneous ablation of hepatocellular carcinoma. *Radiol Med* 2009;114:1094–105.
- [45] Wang W, Wang Y, Wang T, et al. Safety and efficacy of US-guided high-intensity focused ultrasound for treatment of submucosal fibroids. *Eur Radiol* 2012;22:2553–8.
- [46] Kogita S, Imai Y, Seki Y. Time intensity curves of Sonazoid in portal vein in the patients with chronic liver disease and in healthy volunteers. *Kanzo* 2009;50:593–4.
- [47] Farny CH, Glynn Holt R, Roy RA. The correlation between bubble-enhanced HIFU heating and cavitation power. *IEEE Trans Biomed Eng* 2010;57:175–84.