

Chronic Ankle Pain After An Initial 'Twisting' Injury To The Ankle

Faruk AYKANAT,¹ Ozkan KOSE²

¹Department of Orthopaedics and Traumatology, Islahiye State Hospital, Gaziantep;

²Department of Orthopaedics and Traumatology, Antalya Education and Research Hospital, Antalya

A 42-year-old woman was admitted to our outpatient clinic with chronic left ankle pain that began after having a twisting ankle injury fifteen days prior. Immediately after the injury, she was admitted to the nearest emergency department and foot radiographs were taken. Lateral and oblique foot radiographs revealed no abnormal findings, and the patient was diagnosed as simple ankle sprain and was treated with anti-inflammatory medications, elastic bandage, rest, and ice. Although the soft

tissue swelling subsided gradually, the patient suffered from chronic ankle pain and persistent antalgic gait. On physical examination, there was tenderness over the foot distal and inferior to the anterior talofibular ligament (ATFL). The range of ankle movements was slightly painful and inversion of the ankle produced considerable pain. Neurovascular examination was normal. The initial foot radiographs were available and re-evaluated (Figure 1). **[see page 83 for diagnosis]**

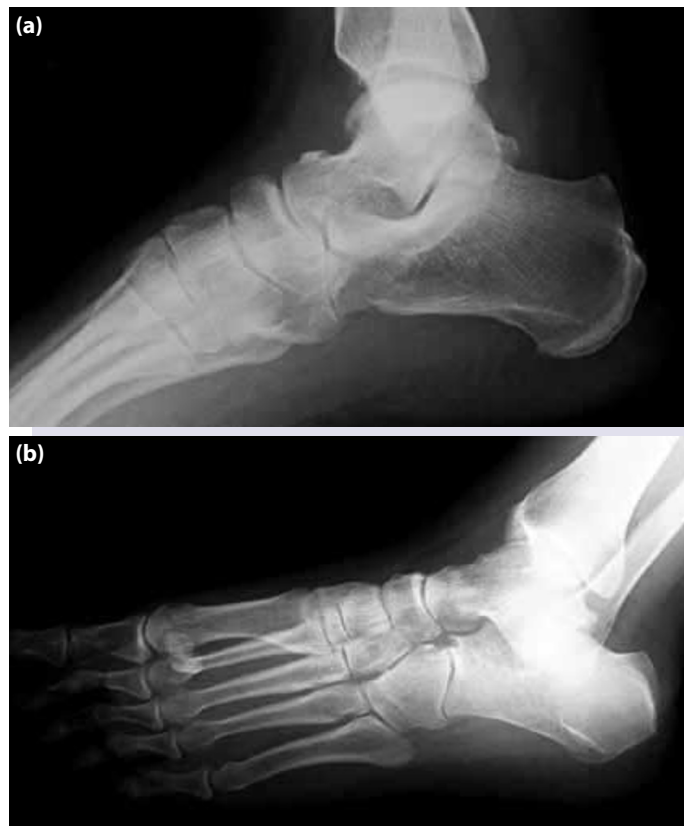

Figure 1. (a) Lateral and (b) oblique foot radiographs of the patient.

Submitted: July 26, 2013 **Accepted:** September 04, 2013 **Published online:** September 13, 2013

Correspondence: Dr. Faruk Aykanat. Çamlıca Mahallesi, Garnizon Caddesi, No: 1, İslahiye Merkez, 27800 Gaziantep, Turkey.

e-mail: farukaykanat@gmail.com



DIAGNOSIS: Fracture of Anterior Superior Process of Calcaneus: A Commonly Missed Fracture

A careful examination of the initial lateral foot radiograph raised the suspicion of fracture of the anterior superior process of calcaneus (ASPC) (Figure 2a). Further imaging with computerized tomography (CT) and multiplanar reconstruction confirmed our preliminary diagnosis (Figure 2b, c). Below-knee plaster cast was applied and continued for four weeks, after which a gradual return to full activities was allowed. At the final follow-up six months after the initial injury, the patient was free of pain and was able to return to his previous level of activity.

Fracture of ASPC is a rare fracture that constitutes 3% of all calcaneal fractures.^[1,2] The mechanism of the injury is often an inversion injury with the foot in plantar flexion, similar to simple ankle sprain.^[1-3] Because of its infrequency, the similarity between typical history and clinical presentation of an ankle sprain and difficulties in direct radiographic evaluation of the fractures of the ASPC is usually misdiagnosed as ankle sprain at initial emergency visits. On the other hand, early identification and prompt treatment of these moderately seeming fractures may prevent chronic ankle problems as observed in our patient. Therefore, emergency physicians should be aware of this fracture.

In order to prevent misdiagnosis, a high level of suspicion and investigation is necessary. Furthermore, the physical examination the tenderest point on palpation should be correctly identified. In the fracture of the ASPC, the tender point is 3-4 cm distal to the lateral malleolar tip over the bifurcate ligament.^[2,3] Whereas in ankle sprain of the ATFL is usually tender.^[4] In addition to a careful physical examination, a careful examination of the foot radiographs is important. Anteroposterior and lateral foot radiographs should be obtained as the first line imaging work-up. However, complex anatomic structure of the foot and superimposition on direct radiography makes the evaluation difficult causing these fractures may easily be missed. In case of suspicion, computed tomogra-

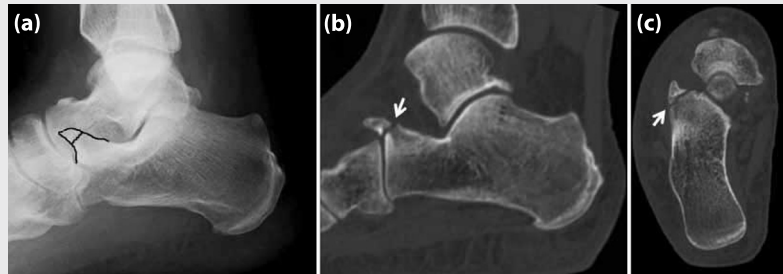


Figure 2. (a) Lateral foot radiograph validated a suspected fracture line at the anterior superior process of calcaneus (black drawing). (b) Sagittal and (c) axial CT demonstrated the fracture (white arrows).

phy (CT) is the most useful imaging method to detect and define the extent of the fracture.^[4] Sagittal reconstruction best demonstrates the fracture.^[3]

The os calcaneus secundarius is an uncommon accessory ossicle of the midfoot which is present in the 5% of the normal population.^[3-5] However, in the context of foot trauma, this normal anatomic variant may be misdiagnosed as a fracture of the ASPC. Thus, os calcaneus secundarius should be considered in the differential diagnosis of acute fractures of the ASPC. The most important radiographic clue to differentiate an os calcaneus secundarius from an acute fracture is the oval configuration and well-corticated margins.^[3,4] Conservative treatment in the form of plaster cast immobilization that last 4 weeks is sufficient for the treatment.^[1,4]

References

1. Trnka HJ, Zettl R, Ritschl P. Fracture of the anterior superior process of the calcaneus: an often misdiagnosed fracture. *Arch Orthop Trauma Surg* 1998;117:300-2.
2. Petrover D, Schweitzer ME, Laredo JD. Anterior process calcaneal fractures: a systematic evaluation of associated conditions. *Skeletal Radiol* 2007;36:627-32.
3. Ouellette H, Salamipour H, Thomas BJ, Kassarian A, Torriani M. Incidence and MR imaging features of fractures of the anterior process of calcaneus in a consecutive patient population with ankle and foot symptoms. *Skeletal Radiol* 2006;35:833-7. [CrossRef](#)
4. Hodge JC. Anterior process fracture or calcaneus secundarius: a case report. *J Emerg Med* 1999;17:305-9.
5. Golder WA. Anterior process of the calcaneus: a clinical-radiological contribution to anatomical vocabulary. *Surg Radiol Anat* 2004;26:163-6. [CrossRef](#)