

Perfluorocarbon liquid migration into the subarachnoid space in a patient with morning glory syndrome

Masood Naseripour, Adel Ghasempour, Khalil Ghasemi Falavarjani*, Mostafa Sultan Sanjari, Maryam Yousefi

Eye Research Center, Rassoul Akram Hospital, Iran University of Medical Sciences, Tehran, Iran

Available online 28 October 2015

Abstract

Purpose: To report a case of perfluorocarbon liquid (PFCL) migration into the subarachnoid space at the time of vitreoretinal surgery in a patient with morning glory syndrome associated retinal detachment.

Case report: A 9-year-old girl underwent pars plana vitrectomy and silicone oil injection for retinal detachment associated with morning glory syndrome. PFCL was used for retinal stabilization before endolaser photocoagulation. The retina detached, and repeated vitrectomy and silicone oil injection was performed. Postoperative magnetic resonance imaging revealed PFCL in the subarachnoid space.

Conclusion: The migration of perfluorocarbon into the subarachnoid space is a rare complication of vitrectomy in patients with morning glory syndrome.

© 2015 Iranian Society of Ophthalmology. Production and hosting by Elsevier B.V. This is an open access article under the CC BY-NC-ND license (<http://creativecommons.org/licenses/by-nc-nd/4.0/>).

Keywords: Perfluorocarbon liquid; Morning glory syndrome; Subarachnoid space

Introduction

Perfluorocarbon liquid (PFCL) and silicone oil are routinely used in vitreoretinal surgery to displace subretinal fluid and blood and to stabilize and flatten the retina. Introduction of these agents has led to significant improvement in vitreoretinal surgery results, especially in complicated retinal detachment. However, they may result in infrequent but serious complications including subretinal retention of the tamponade substances as well as unusual cases of migration of silicon oil and PFCL along the optic nerve into the subarachnoid space.^{1–5} Here, we report a case of subarachnoid migration of PFCL in morning glory syndrome.

Case report

A 9-year-old girl with a history of morning glory syndrome was referred to our clinic with significant decreased vision of her right eye from one month earlier. Visual acuity in her right eye was hand movements close to face. Slit-lamp examination was not contributory. However, fundus examination revealed bullous retinal detachment (Fig. 1) with a peripheral break. The left eye was normal.

The patient underwent 20 gauge three-port pars plana vitrectomy. PFCL was used for retinal reattachment and endolaser endophotocoagulation of the break. Fluid–air exchange and air–silicone exchange were performed. The first day after surgery, the retina was attached; however, on the second postoperative day, the retina was detached at the posterior pole. Intraocular pressure (IOP) was normal during the postoperative period.

Two days later, repeated vitreoretinal surgery was performed. At the time of surgery, a focal extramacular retinotomy was made to drain the subretinal fluid under air injection.

*Corresponding author. Eye research Center, Rassoul Akram Hospital, Sattarkhan-Niaiesh St., Tehran, Iran. Tel.: +98 9121725850; fax: +98 2166509162.

E-mail address: drghasemi@yahoo.com (K.G. Falavarjani).

Peer review under responsibility of the Iranian Society of Ophthalmology.

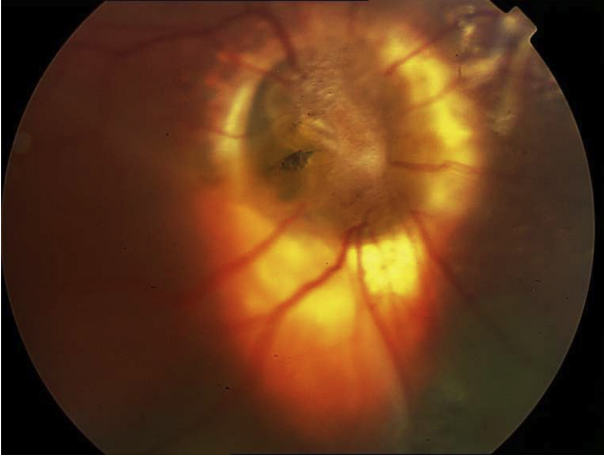


Fig. 1. Fundus photography of the right eye showing retinal detachment associated with morning glory disc.

The consistency of subretinal fluid was compatible with PFCL. Following the fluid–air exchange, PFCL was injected to extrude remaining submacular fluid and keep the retina attached, and endolaser photocoagulation was performed around the retinotomy site. Finally, PFCL was directly exchanged with silicone oil. Before closing the sclerotomies, an expanding PFCL bubble was observed coming out of optic disc and morning glory cavity. The fluid was completely removed using a backflush cannula. At the end of the surgery, the retina was rechecked to be sure that there was no fluid under or over the retina, and the vitreous cavity was filled with silicone oil. The IOP was adjusted, and the sclerotomy sites were closed with 7-0 Vicryl sutures.

The first day after the second operation, the retina was attached, but a few small PFCL bubbles were seen over the optic nerve head. Orbital magnetic resonance imaging (MRI) was performed, and a localized area of signal void compatible with PFCL bubble was observed in subarachnoid space (Fig. 2). On the third postoperative day, the retina was detached at macula by lobulated fluid, indicating the presence of PFCL under the retina. The patient was free of any neurological symptom, and the neurological examination was normal. Though the need for repeated surgery was explained to the patient's parents, they refused any further attempt. At the last visit, there was a unified large subretinal bubble at the posterior pole, and peripheral retina was attached.

Discussion

Migration of the intraocular tamponade agents into the central nervous system is very rare.^{1–5} The exact mechanism of this migration is unclear. Shield and Eagle⁶ proposed different mechanisms including chronic rise of IOP, and cavernous degeneration of optic nerve and macrophage migration. Kuhn et al³ suggested that in patients with optic pit, a separate path from an anatomic abnormality facilitates silicone migration.³ Recently, optical coherence tomography (OCT) studies have shown that abnormal connections exist between the vitreous cavity, subretinal space and retobulbar

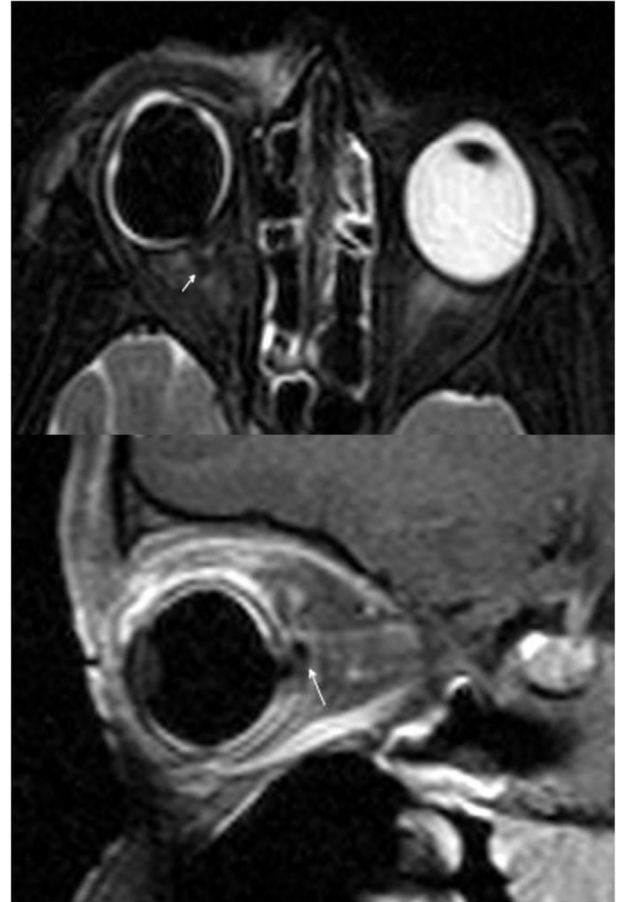


Fig. 2. Axial T2 (upper section) and sagittal contrast enhanced fat suppressed T1 (lower section) magnetic resonance imaging demonstrates right optic nerve head excavation and suppression of the signal within the right globe and subarachnoid space in the retrobulbar area suggestive of perfluorocarbon liquid or silicone oil bubble (arrow).

subarachnoid space in excavated optic discs anomalies.^{7,8} Interestingly, Cennamo et al⁸ reported an abnormal communication between the subarachnoid space and the subretinal space in 5 patients with morning glory syndrome.

The clinical importance of silicone oil and PFCL within the subarachnoid space is undetermined. No reports have identified an obvious association of silicone migration with focal neurologic deficits.¹

The appearance of intraocular silicone oil has been described to be hyper-intense relative to the contralateral normal vitreous on T1-weighted and hyper-, hypo-, or iso-intense on T2-weighted MRI.⁹ Since T1 and T2 weighting depends on the physical properties of the oil and imaging techniques, different intensities may be observed.⁹ The PFCL appears dark (hypo-intense) on all MR images and may be indistinguishable from the silicone oil on a fat- or silicone-saturation sequence.⁹ In our patient, the liquid in the subarachnoid space and the globe was hypo-intense in both T1 and T2 images (Fig. 2). We observed intraoperative exit of the PFCL from optic nerve head and postoperative accumulation of subretinal PFCL, so the fluid in the subarachnoid space was presumed to be PFCL.

To the best of our knowledge, this is the first case of PFCL migration into the subarachnoid space in a patient with morning glory syndrome. We assumed that in our case, the anatomical abnormality in optic nerve head (morning glory disc) allowed PFCL to gain access to the subarachnoid space during the surgery, and it has been displaced anteriorly following the postoperative prone position. The retinal surgeons may consider OCT examination before surgery in patients with morning glory syndrome.^{7,8} If an abnormal communication between the vitreous cavity and subarachnoid space was found, the surgeon should be cautious for using PFCL.

Financial interest

None of the authors have any financial interest in the subject matter of this paper.

References

1. Chen JX, Nidecker AE, Aygun N, Gujara SK, Gandhi D. Intravitreal silicone oil migration into the subarachnoid space and ventricles: a case report and review of literature. *Eur J Radiol Extra* 2011;**78**:e81–e83.
2. Malin DR, Aulino JM, Recchia FM. Intracranial hyperdense subarachnoid perfluorocarbon droplets after attempted retinal detachment treatment. *Emerg Radiol* 2007;**14**:261–263.
3. Kuhn F, Kover F, Szabo I, Mester V. Intracranial migration of silicone oil from an eye with optic pit. *Graefes Arch Clin Exp Ophthalmol* 2006;**244**:1360–1362.
4. Chang CC, Chang HS, Toh CH. Intraventricular silicone oil. *J Neurosurg* 2013;**118**:1127–1129.
5. Eller AW, Friberg TR, Mah F. Migration of silicone oil into the brain: a complication of intraocular silicone oil for retinal tamponade. *Am J Ophthalmol* 2000;**129**:685–688.
6. Shields CL, Eagle Jr. RC. Pseudo-Schnabel's cavernous degeneration of the optic nerve secondary to intraocular silicone oil. *Arch Ophthalmol* 1989;**107**:714–717.
7. Katome T, Mitamura Y, Hotta F, Mino A, Naito T. Swept-source optical coherence tomography identifies connection between vitreous cavity and retrobulbar subarachnoid space in patient with optic disc pit. *Eye (Lond)* 2013;**27**:1325–1326.
8. Cennamo G, de Crecchio G, Iaccarino G, Forte R, Cennamo G. Evaluation of morning glory syndrome with spectral optical coherence tomography and echography. *Ophthalmology* 2010;**117**:1269–1273.
9. Herrick RC, Hayman LA, Maturi RK, Diaz-Marchan PJ, Tang RA, Lambert HM. Optimal imaging protocol after intraocular silicone oil tamponade. *AJNR Am J Neuroradiol* 1998;**19**:101–108.