

CASE REPORT

Open Access



Anticoagulation may contribute to antimicrobial treatment of Lemierre syndrome: a case report

Jie Ge, Peipei Zhou, Yifei Yang, Tianshu Xu and Xu Yang*

Abstract

Background: Lemierre syndrome (LS) is characterized by multisystemic infection beginning in the oropharynx, local thrombophlebitis (typically, of the internal jugular vein) and peripheral embolism. No evidence-based guidelines exist for the management of this disease, and the use of anticoagulation therapy remains particularly controversial.

Case presentation: A 61-year-old man presenting with left neck swelling, odynophagia, and dyspnea underwent emergency surgery and received intravenous antibiotics. The primary infection was controlled on hospital day 5, but on day 6 sudden leukocytosis and hypoxemia were observed. CT angiography revealed an intraluminal filling defect in the pulmonary artery on day 8. LS was diagnosed and anticoagulation therapy was initiated. The WBC count, which had maintained its peak values in the previous 2 days, decreased instantly after initiation, and follow-up controls showed thrombus resolution.

Conclusions: Our case supports the notion that anticoagulation therapy may be a valid supplement to antimicrobial therapy in LS, especially in the presence of a possibly young thrombus as suggested by clinical worsening.

Keywords: Anticoagulation, Infectious disease, Thromboembolism, Lemierre syndrome, Case report

Background

Despite its nonnegligible annual incidence of >1/100000, Lemierre syndrome (LS) often goes undiagnosed due to its non-specific symptoms [1, 2]. The most accurate definition of LS should include 1) infection that originates in the oropharynx, mastoiditis, oral cavity and sinusitis, 2) isolation of *Fusobacterium necrophorum* and 3) local thrombophlebitis, typically of the internal jugular vein, producing disseminated emboli to the periphery (often septic pulmonary emboli) [2–4]. However, as an obligate anaerobic bacterium, *Fusobacterium necrophorum* is often difficult to isolate in blood cultures. It requires a longer incubation period than other bacteria,

and cultures can be false negative if antibiotics are administered before sample collection. In addition, other bacteria may cause the same clinical syndrome. Therefore, a clinical diagnosis of LS is considered to be still valid even when *Fusobacterium necrophorum* is undetected or other bacteria are detected [5–7]. Delayed treatment of LS can lead to multisystemic organ dysfunction, potential end-stage organ damage or death. Systemic emboli and septic pulmonary emboli can also be life threatening. Therefore, early diagnosis and treatment of LS are vital. The key tools of physicians are antibiotic therapy, anticoagulation therapy and drainage of abscesses [2]. The use of anticoagulation therapy remains controversial, and it is unclear whether anticoagulation treatment improves patient outcomes. Here, we report a case in which anticoagulation initiated after clinical worsening was followed by prompt clinical and

* Correspondence: Nova_gejie@163.com

Department of stomatology, Changzhou First People's Hospital, Juqian Street, Changzhou 185, Jiangsu, China



© The Author(s). 2021 **Open Access** This article is licensed under a Creative Commons Attribution 4.0 International License, which permits use, sharing, adaptation, distribution and reproduction in any medium or format, as long as you give appropriate credit to the original author(s) and the source, provide a link to the Creative Commons licence, and indicate if changes were made. The images or other third party material in this article are included in the article's Creative Commons licence, unless indicated otherwise in a credit line to the material. If material is not included in the article's Creative Commons licence and your intended use is not permitted by statutory regulation or exceeds the permitted use, you will need to obtain permission directly from the copyright holder. To view a copy of this licence, visit <http://creativecommons.org/licenses/by/4.0/>. The Creative Commons Public Domain Dedication waiver (<http://creativecommons.org/publicdomain/zero/1.0/>) applies to the data made available in this article, unless otherwise stated in a credit line to the data.

laboratory improvement, supporting a role of anticoagulation in the treatment of LS.

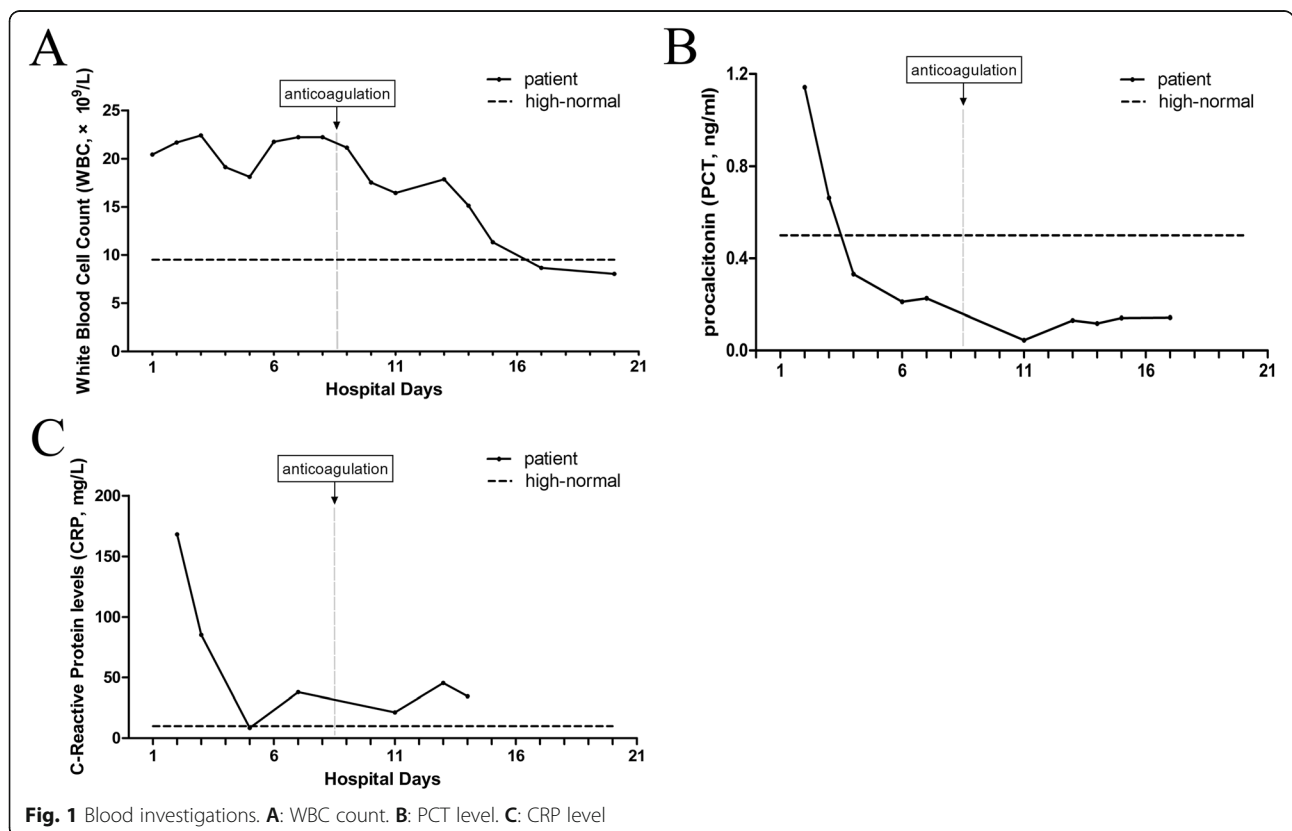
Case presentation

A 61-year-old man presented to the oral and maxillo-facial surgery service with a 5-day history of left neck swelling, odynophagia, and dyspnea without chest pain or cough. He reported a history of 7-day odontalgia and 3-day intravenous cefotiam (1 g every 12 h) and metronidazole (500 mg every 8 h) treatment. He was otherwise healthy, with no known allergies. His weight was 65 kg. At the time of admission, the patient had an oxygen saturation (SpO) of 98% while breathing ambient air. Laboratory data revealed a white blood cell count (WBC) of 20.45×10^9 /L (Fig. 1 A), procalcitonin (PCT) of 1.142 ng/mL (Fig. 1 B), C-reactive protein (CRP) of 168.23 mg/L (Fig. 1 C), random blood glucose of 16.02 mmol/L and glycosylated hemoglobin of 8.7%. Computed tomography (CT) of the neck revealed diffusive swelling combined with pneumatosis (Fig. 2 A). The patient was then diagnosed with cervical necrotizing fasciitis.

He underwent emergency incision and drainage surgery and received empirical treatment with intravenous imipenem-cilastatin sodium (1 g every 8 h) and metronidazole (500 mg every 8 h). His blood glucose was controlled by insulin. Anaerobic cultures of pyogenic fluids

and blood were obtained on admission and were sterile 5 days later, which may have been due to the antimicrobial treatment before admission. After five days of antimicrobial treatment (hospital day 5), the patient’s WBC count had gradually decreased to 18.12×10^9 /L (Fig. 1 A; hospital day 5) and CRP to 8.51 mg/L (Fig. 1 C; hospital day 5). However, he had an SpO of 80% in room air and 96% with oxygen inhalation (5 L/min) on the sixth hospital day. Laboratory data showed that his WBC count increased to 21.77×10^9 /L (Fig. 1 A; hospital day 6), while his PCT level decreased to 0.211 ng/mL (Fig. 1 B; hospital day 6). A repeat CT scan revealed that the neck infection had regressed (Fig. 2 A) and that the pulmonary infection was stable (Fig. 2 B). Chest CT angiography revealed an intraluminal filling defect in the lower branch of left pulmonary artery on the eighth hospital day (Fig. 2 C). This manifestation was considered consistent with septic pulmonary embolism derived from the internal jugular vein, which was very close to the infection focus (Fig. 2 D). LS was diagnosed.

Anticoagulation therapy was performed with low molecular weight heparin (4250 U every 12 h) for the following 4 days. His WBC gradually decreased to 17.87×10^9 /L (Fig. 1 A; hospital day 13). Low molecular weight heparin was replaced with warfarin (3 mg every day) on hospital day 12. The international normalized ratio (INR) was monitored constantly and controlled between



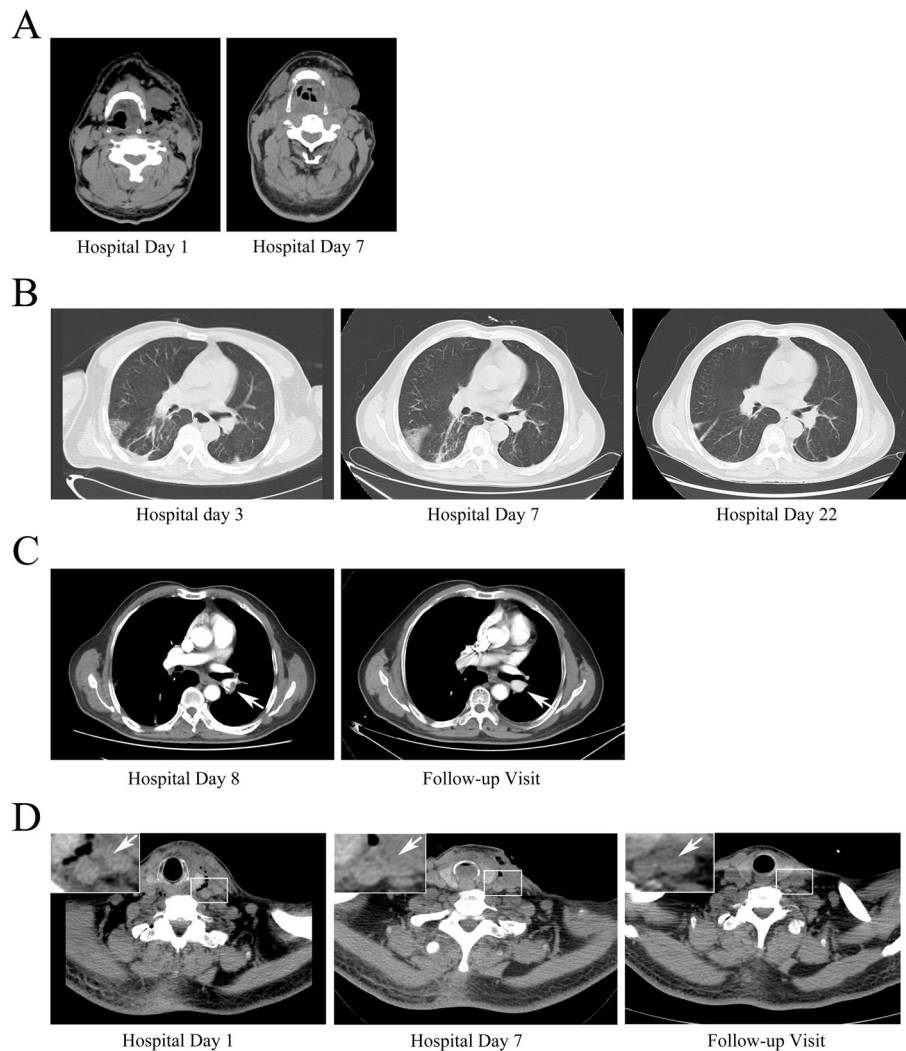


Fig. 2 Imaging. **A:** Neck CT. **B:** Chest CT. **C:** Pulmonary artery CT. White arrow: pulmonary emboli in the “Hospital Day 8” image; pulmonary emboli disappeared in the “Follow-up Visit” image. **D:** Internal jugular vein CT. White arrow: signs of inflammation next to the internal jugular vein in “Hospital Day 1” and “Hospital Day 7” images; the signs of inflammation disappeared in the “Follow-up Visit” image

2 and 2.5. The patient’s WBC count decreased to 8.67×10^9 /L on hospital day 17 and remained normal on the following days (Fig. 1 A). Repeat chest CT showed that the pulmonary infection was cured on hospital day 22 (Fig. 2 B). He was discharged from the hospital on hospital day 24 and continued anticoagulation therapy. When he returned for a follow-up visit at the twentieth week, the embolus had dissolved (Fig. 2 C), and anticoagulation therapy was discontinued. No haemorrhage occurred during anticoagulation therapy.

Discussion and conclusions

In this case, the primary infection was controlled on hospital day 5, as proven by CT evaluation and decreased WBC and PCT levels. The sudden increase in WBC count and decrease in SpO₂ on hospital day 6 were

considered to be caused by newly formed septic pulmonary emboli. Pulmonary emboli above the subsegmental level are a possible, but rare complication of LS, and 3 days were required for diagnosis of LS. As a result, anticoagulation therapy was not initiated until hospital day 8. The WBC count maintained its peak value on hospital days 6–8 before anticoagulation therapy was initiated, but rapidly decreased after initiation. This quick response suggests that anticoagulation therapy may have contributed to the infection resolution achieved by antimicrobials.

In a review of 137 cases of LS, the authors found that 4–6 weeks of carbapenem or piperacillin/tazobactam combined with metronidazole were effective in terms of infection control, but the reason for the choice of such a duration was not explained in any of

the included papers [6]. Our antimicrobial treatment was maintained until the WBC counts remained normal for 1 week and clinical symptoms improved. The duration was 24 days in total and 16 days after anticoagulation therapy proceeded, which is much shorter than the average. However, it is still unknown whether anticoagulation therapy is essential, which is an important issue especially in cases, such as the one we described, that are complicated by large intraluminal emboli.

In the past few decades, evidence remained poor regarding the management of LS, particularly regarding its potentially life-threatening thromboembolic complications. Consequently, physicians must make their decisions based on small case series or anecdotal cases when facing uncommon thromboembolic conditions, such as LS. Physicians who are opposed to anticoagulant treatment confirm that the thrombus is caused by an infection process and will be resolved at the same time when the infection is resolved. In contrast, some authors confirm that anticoagulant therapy may reduce the morbidity and mortality of serious complications, such as cavernous sinus thrombosis or pulmonary embolism. Theoretically, a septic thrombus sequesters bacteria and creates a barrier to antibiotic penetration. When the thrombus is dissolved by anticoagulants, the bacteria are exposed to a higher concentration of antibiotics, increasing accessibility [8]. Our case supports this hypothesis precisely. Unfortunately, randomized controlled trials are impractical to investigate the use of anticoagulation therapy in the treatment of LS due to the rarity of this illness. Based on small case series, the proposal has been advanced to reserve this approach to bilateral disease only; a single-center retrospective series has found no association with thrombus recanalization, although it is unclear whether recanalization is clinically relevant [9]. The improvement seen in our case despite the absence of bilateral disease and the finding of recanalization following anticoagulation could be explained by the likelihood that the thrombus had developed recently, as suggested by the sudden increase in infection parameters, and may have been more vulnerable to anticoagulation than an older, organized thrombus. This possibility is consistent with the known biology of venous thrombi [10] and should be explored by future research.

A recent European collaborative study performed an individual patient-level analysis of 712 cases published globally from 2000 to 2017 [1]. The authors could not find disease-specific elements against the safety of anticoagulation and drew the conclusion that therapeutic anticoagulation is indicated for LS if there are no contraindications. Nevertheless, the authors did not provide definitive guidelines for the duration of anticoagulation. According to the American College of Chest Physicians

guidelines for provoked thrombotic events, anticoagulation therapy is recommended for a duration of at least 3 months [11], which may be available for reference to Lemierre syndrome presented pulmonary embolism. Our patient received a treatment duration of 20 weeks because his follow-up visit was delayed by the outbreak of COVID-19. A limitation of our case is the lack of microbial isolation. However, the diagnosis of LS is currently accepted even without microbial isolation in the presence of a clinical diagnosis of sepsis from an oropharyngeal focus and thrombi or emboli consistent with the primary infection location [5]. This case satisfies the broad criteria of Lemierre syndrome, that are currently accepted, but not the restrictive or classic criteria that require evidence of jugular vein thrombosis and *Fusobacterium necrophorum*, and that future management studies should report results for both subpopulations.

In conclusion, therapeutic anticoagulation may be considered in the management of LS, while further research is needed to evaluate whether the use of anticoagulant and antibiotics leads to better clinical outcomes than the use of antibiotics alone.

Patient perspective

I'm the daughter of the patient. We are grateful to the doctors' help in Changzhou First People's Hospital and happy to share the treatment experience of my father.

Abbreviations

LS: Lemierre syndrome; SpO₂: Oxygen saturation; WBC: White blood cell count; CRP: C-Reactive protein; PCT: Procalcitonin; CT: Computed tomography; INR: International normalized ratio

Acknowledgements

Not applicable.

Authors' contributions

JG and XY performed the literature review and drafted the manuscript. PPZ and YFY obtained the image data. TSX reviewed the report and provided important revisions. All authors read and approved the final manuscript.

Funding

This work was supported by Changzhou Science and Technology Bureau (CN) (grant number CJ20180060).

Availability of data and materials

The datasets generated and/or analysed during the current study are not publicly available due to patient privacy protection but are available from the corresponding author on reasonable request.

Declarations

Ethics approval and consent to participate

Institutional review board approval was not required for this case report. Informed consent was obtained from the patient.

Consent for publication

Consent for publication was obtained from the patient.

Competing interests

The authors declare that they have no competing interests.

Received: 18 August 2021 Accepted: 21 October 2021

Published online: 04 November 2021

References

1. Valerio L, Zane F, Sacco C, Granziera S, Nicoletti T, Russo M, et al. Patients with Lemierre syndrome have a high risk of new thromboembolic complications, clinical sequelae and death: an analysis of 712 cases. *J Intern Med.* 2021 Mar;289(3):325–39. <https://doi.org/10.1111/joim.13114>.
2. Osowicki J, Kapur S, Phuong LK, Dobson S. The long shadow of Lemierre's syndrome. *J Infect.* 2017;74 Suppl 1:S47–53. [https://doi.org/10.1016/S0163-4453\(17\)30191-3](https://doi.org/10.1016/S0163-4453(17)30191-3).
3. Schulman S. Lemierre syndrome - treat with antibiotics, anticoagulants or both? *J Intern Med.* 2021 Mar;289(3):437–8. <https://doi.org/10.1111/joim.13100>.
4. Walkty A, Embil J. Lemierre's Syndrome. *N Engl J Med.* 2019 Mar 21;380(12):e16. <https://doi.org/10.1056/NEJMicm1808378>.
5. Valerio L, Corsi G, Sebastian T, Barco S. Lemierre syndrome: current evidence and rationale of the Bacteria-associated thrombosis, thrombophlebitis and Lemierre syndrome (BATTLE) registry. *Thromb Res.* 2020 Dec;196:494–9. <https://doi.org/10.1016/j.thromres.2020.10.002>.
6. Johannesen KM, Bodtger U. Lemierre's syndrome: current perspectives on diagnosis and management. *Infect Drug Resist.* 2016;9:221–7. <https://doi.org/10.2147/IDR.S95050>.
7. Hill UG, Vallis MP, Cotter T, Hegarty MA. Has Lemierre's syndrome become a bacteriological diagnosis? *Br J Hosp Med (Lond).* 2010;71(3):169. <https://doi.org/10.12968/hmed.2010.71.3.46983>.
8. Campo F, Fusconi M, Ciotti M, Diso D, Greco A, Cattaneo CG, et al. Antibiotic and anticoagulation therapy in Lemierre's syndrome: case report and review. *J Chemother.* 2019 Feb;31(1):42–8. <https://doi.org/10.1080/1120009X.2018.1554992>.
9. Valerio L, Pleming W, Pecci A, Barco S. Management of Lemierre syndrome. *Minerva Med.* 2021. <https://doi.org/10.23736/S0026-4806.21.07497-8>.
10. Saha P, Humphries J, Modarai B, Mattock K, Waltham M, Evans CE, et al. Leukocytes and the natural history of deep vein thrombosis: current concepts and future directions. *Arterioscler Thromb Vasc Biol.* 2011 Mar; 31(3):506–12. <https://doi.org/10.1161/ATVBAHA.110.213405>.
11. Kearon C, Akl EA, Ornelas J, Blaivas A, Jimenez D, Bounameaux H, et al. Antithrombotic therapy for VTE disease: CHEST guideline and expert panel report. *Chest.* 2016 Feb;149(2):315–52. <https://doi.org/10.1016/j.chest.2015.11.026>.

Publisher's Note

Springer Nature remains neutral with regard to jurisdictional claims in published maps and institutional affiliations.

Ready to submit your research? Choose BMC and benefit from:

- fast, convenient online submission
- thorough peer review by experienced researchers in your field
- rapid publication on acceptance
- support for research data, including large and complex data types
- gold Open Access which fosters wider collaboration and increased citations
- maximum visibility for your research: over 100M website views per year

At BMC, research is always in progress.

Learn more biomedcentral.com/submissions

