

# Management of Renal Cysts

Okan Bas, MD, Ismail Nalbant, MD, Nevzat Can Sener, MD, Hacer Firat, MD, Süleyman Yeşil, MD, Kürşad Zengin, MD, Fatih Yalcinkaya, MD, Abdurrahim Imamoglu, MD

## ABSTRACT

**Background and Objectives:** Renal cysts have a high prevalence in the general population, and their estimated incidence increases with age. Renal cyst aspiration (usually with sclerotherapy) or open/laparoscopic decortication is a generally effective and safe method in the treatment of symptomatic simple renal cysts. The success rates of laparoscopic decortication and percutaneous aspiration-sclerotherapy were compared to assist in the decision making for the procedure.

**Methods:** A total of 184 patients with symptomatic simple renal cysts were treated with either laparoscopic decortication in 149 cases or percutaneous aspiration-sclerotherapy in 35 cases. The follow-up period was approximately 35 months, and the symptomatic and radiologic success rates of the 2 techniques were compared retrospectively.

**Results:** Laparoscopic decortication was found to have high success rates, a low recurrence rate, and minimal morbidity. Percutaneous aspiration-sclerotherapy is an outpatient procedure with a minimally higher recurrence rate.

**Conclusion:** When a symptomatic cyst is encountered and treatment of the cyst is indicated, laparoscopic decortication is a more efficient method that offers better results than percutaneous aspiration-sclerotherapy.

**Key Words:** Renal cyst, Laparoscopy, Sclerotherapy.

## INTRODUCTION

The kidney is one of the most common sites of cysts in the body, with a prevalence of 20% to 50% in the general population,<sup>1,2</sup> and it is estimated that the incidence increases with age.<sup>3</sup> Although most renal cysts (RCs) are found incidentally and are peripheral in location without any symptoms, they occasionally become large enough to cause pain, hematuria, hypertension, and pelvicalyceal obstruction.<sup>4,5</sup> Cyst rupture is less common.<sup>4</sup> When an RC is very large, it may show the mechanical effects of a space-occupying lesion or compression of the collecting system (or both). Thus, when required, RC aspiration (usually with sclerotherapy) or open/laparoscopic decortication is generally effective and safe.<sup>6</sup>

Despite surgeons' familiarity with laparoscopic decortication (LD) and percutaneous aspiration-sclerotherapy (PAS) for simple RCs, there are a limited number of studies including long-term symptomatic and radiologic outcomes with high numbers of patients. Thus the aim of this study was to retrospectively evaluate and compare the success rates of LD and PAS in 184 patients with symptomatic simple RCs to provide insights into the surgical procedure and outcomes over a 35-month follow-up period.

## METHODS

### Patients

The study comprised 184 consecutive patients with symptomatic simple RCs. Data were collected from a retrospective review of the hospitals' and physicians' office records and by interviews with the patients. Each procedure was explained to the patients, including a discussion of success rates, possible complications, invasiveness, and the need for anesthetics and hospitalization, and patients were actively involved in the decision-making process.

Department of Urology, Abdurrahman Yurtaslan Oncology Education and Research Hospital, Ministry of Health, Ankara, Turkey (Dr. Bas).

Department of Urology, Yenimahalle State Hospital, Ministry of Health, Ankara, Turkey (Dr. Nalbant).

Department of Urology, Numune Education and Research Hospital, Ministry of Health, Adana, Turkey (Dr. Can Sener).

Department of Radiology, Diskapi Yildirim Beyazid Education and Research Hospital, Ministry of Health, Ankara, Turkey (Dr. Firat).

Department of Urology, Gazi University School of Medicine, Ankara, Turkey (Dr. Yeşil).

Department of Urology, Bozok University School of Medicine, Yozgat, Turkey (Dr. Zengin).

Department of Urology, Diskapi Yildirim Beyazid Education and Research Hospital, Ministry of Health, Ankara, Turkey (Drs. Yalcinkaya, Imamoglu).

Address correspondence to: Okan Bas, MD, Department of Urology, Abdurrahman Yurtaslan Oncology Education and Research Hospital, Ankara, Turkey. Telephone: +90 312 336 09 09, Fax: +90 312 345 49 79, E-mail: drokanbas@hotmail.com

DOI: 10.4293/JSLS.2014.00097

© 2015 by JSLS, Journal of the Society of Laparoendoscopic Surgeons. Published by the Society of Laparoendoscopic Surgeons, Inc.

Thereafter the procedure was chosen according to patient preference. The LD group comprised 149 patients, and the PAS group comprised 35 patients. All patients were evaluated in our urology clinic between January 2007 and April 2013, and the cysts were localized and characterized by ultrasonography and computed tomography. Patients with autosomal dominant polycystic kidneys or complicated cysts, those who had undergone open or laparoscopic surgery on the same kidney, those with cysts with a radiologic diagnosis other than Bosniak classes I and II, and those with cysts relating to the collecting system were excluded from the study. All patients were symptomatic (renal pain, renal lump, hypertension, or hematuria) at

presentation. The characteristics of the patients, including their age, sex, clinical presentation, kidney side, cyst location and position, maximum diameter of the cyst, number of cysts, Bosniak classification of the cyst, and history of surgery, are given in **Table 1**.

### Procedure

**Decortication technique.** The laparoscopic approach that provides the most direct access to the cyst was preferred. In this study the transperitoneal approach was performed in 19 patients (12.7%) at a 45° flank position for anteriorly located RCs, and the retroperitoneal approach

**Table 1.**  
Patient Characteristics and Preoperative Parameters

	Laparoscopic Decortication	Aspiration-Sclerotherapy
No. of patients	149	35
Male/female (n)	83 (56.8%)/66 (43.2%)	22 (62.8%)/13 (37.2%)
Mean age (range) (y)	57.7 (20–80)	59 (18–79)
Kidney side: right/left (n)	84 (56.4%)/65 (43.6%)	16 (45.7%)/19 (54.3%)
Cyst location (n)		
Upper	43 (28.8%)	13 (37.2)
Middle	43 (28.8%)	4 (11.4%)
Lower	49 (32.8%)	11 (31.4%)
Peripelvic	14 (9.6%)	7 (20%)
Cyst position (n)		
Anterior	19 (12.7%)	3 (8.5%)
Posterior	82 (55%)	23 (65.7%)
Lateral	48 (32.3%)	9 (25.8%)
Clinical presentation (n)		
Renal lump	16 (10.7%)	7 (20%)
Renal pain	119 (79.9%)	21 (60%)
Hypertension	5 (3.4%)	3 (8.6%)
Hematuria	9 (6.0%)	4 (11.4%)
Maximum diameter of cyst (range) (mm)	78.8 (48–160)	71.5 (30–120)
No. of cysts (n)		
1	130 (87.2%)	35 (100%)
2	12 (8%)	0
>2	7 (4.8%)	0
Bosniak classification (n)		
I	140 (93.9%)	33 (100%)
II	9 (6.1%)	0
Previous operation (n)	5 (3.3%)	0 (0%)

was preferred for 130 patients (87.3%) in a flank position for posteriorly and laterally located RCs. Three ports were used for both techniques, in which the cyst was cleared of overlying fat and tissue, and fluid was carefully aspirated from the cyst without spillage and submitted for later cytologic analysis. The cystic wall was circumferentially excised by electrocautery and submitted for later pathologic analysis; the specimens were found to be benign in character in all cases. Hemostasis at the edge of the cyst was provided by electrocautery. The interior wall of the cyst was visualized to exclude additional cysts or any suspicious-looking areas to rule out malignancy. Fulguration of the base was avoided to reduce the risk of fistulization with the major renal vessels or collecting system. Perirenal fat was packed into the base of the cyst to prevent cyst recurrence. A Jackson-Pratt drain was routinely placed and removed 24 hours after the procedure.

**Aspiration technique.** The patient was sedated, and local anesthesia was administered. The cyst was then ablated in the radiology department as an outpatient procedure. It was punctured with an 18-gauge needle, followed by aspiration of 10 to 20 mL of fluid, under the guidance of ultrasonography with the patient in a prone position. The cyst fluid was submitted for cytologic examination in all cases. If the fluid was clear, an equivalent volume of water-soluble contrast medium was injected to delineate the cyst wall. If the wall was smooth and there was no connection with the pelvicalyceal system and no extravasation outside the cyst wall, a 5F pigtail polyethylene catheter was inserted in one step under ultrasonographic guidance. Ethanol with a concentration of 95% in a volume equal to 25% of the total cyst volume was injected if the cyst volume was <150 mL. A catheter was then clamped for 20 minutes while the patient was asked to move into different positions to help distribute the ethanol over the cyst wall; the catheter was then opened and drained completely by aspiration, confirmed by ultrasonography, and the catheter was removed. After complete drainage of the injected ethanol, another similar injection was given, followed by clamping of the catheter for another 20 minutes and then drainage and catheter removal, if the cyst volume was 150 to 500 mL. Finally, if the cyst volume was >500 mL, the catheter was left in place for continuous drainage for 24 hours and then ethanol was injected, followed by catheter clamping and drainage after 20 minutes, and the procedure was repeated every 24 hours for a total of 2 to 3 injections. The ethanol volume was not allowed to exceed 150 mL per injection.

## Follow-Up

Each patient was reassessed with clinical and ultrasonographic examinations at 1 month and 6 months and then annually after the procedure to determine success rates. All patients were available for follow-up during a mean period of 35.26 months in the LD group and 34.91 months in the PAS group. Radiologic success was defined as no visible evidence of a cyst on ultrasonography. For symptomatic success, we assessed whether the patient was symptomatic or not based on the subjective report of the patient. Information about postoperative symptoms was gathered by telephone conversations. Failure was considered a recurrence of the cyst with or without symptoms. A symptomatic patient after the procedure was considered a failure.

## Statistical Analysis

Statistical analysis was performed with a commercially available statistical program (SPSS, version 14.0; SPSS, Chicago, Illinois) with the Pearson  $\chi^2$  and Student *t* tests for independent variables.  $P < .05$  was considered statistically significant.

## RESULTS

The characteristics and preoperative parameters of the 149 patients in the laparoscopic cyst decortication group (83 men and 66 women) and 35 patients in the PAS group (22 men and 13 women)—with mean ages of 57.7 years and 59 years, respectively—are listed in **Table 1**. The laterality of cysts was as follows: right kidney in 56.4% and left kidney in 43.6% in the LD group and right kidney in 45.7% and left kidney in 54.3% in the PAS group. Most of the cysts in the LD group were located in the lower (32.8%) and posterior (55%) position, whereas in the PAS group, they were mostly located in the upper (37.2%) and posterior (65.7%) position. The most common clinical symptom for both groups was renal pain (79.9% in LD group and 60% in PAS group), followed by renal lump (10.7% in LD group and 20% in PAS group), hematuria (6.0% in LD group and 11.4% in PAS group), and hypertension (3.4% in LD group and 8.6% in PAS group). All the patients in the PAS group had only 1 cyst; in contrast, in the LD group, 87.2% of patients had only 1 cyst, 8% had 2 cysts, and 4.8% had >2 cysts. The Bosniak classification was first described in 1986; then underwent several modifications and upgrades, on the basis of computed tomography imaging studies; and is used uniformly by urologists and radiologists as a way of diagnosing and categorizing cystic renal masses for management. When classified with the Bosniak

classification, all the patients in the PAS group were class I but in the LD group 93.9% of patients were class I and 6.1% were class II. None of the patients in the PAS group had undergone any previous operation, whereas 3.3% of the LD patients (n = 5) had at least 1 previous unsuccessful cyst aspiration. There was no significant difference in baseline demographic data between the LD and PAS groups (**Table 1**).

The procedures used in the LD group were the transperitoneal (12.7%) and retroperitoneal (87.3%) approach. In 3 patients (2%) in this group who underwent the retroperitoneal approach, conversion to open surgery was needed because of excessive bleeding (n = 1) and excessive adhesions (n = 2). The mean follow-up time for the LD group was 35.26 months. The mean diameter of cysts was 10.54 mm after 1 month and 6.62 mm after 6 months. Of the 149 patients, 138 (92.6%) were symptom free whereas 11 (7.4%) reported persistent pain (n = 7) or persistent hypertension (n = 4) at follow-up in the LD group. In 5 of these patients, recurrences of new cysts were detected with ultrasonography of the treated kidney. Symptomatic success was achieved in 92.6% of patients and radiographic success was achieved in 96.6% because of new cyst development on follow-up ultrasonography. None of the patients with radiologic failure had symptomatic failure (**Table 2**).

All the patients in the PAS group underwent sclerotherapy. The mean follow-up period of the PAS group was 34.91 months. The mean diameter of the cysts was 31.2 mm after 1 month and 24.8 mm after 6 months. During the follow-up period, 21 RCs (60%) were successfully removed and 14 patients (40%) had reduction of the cyst volume to one half of the initial size. Symptoms com-

pletely resolved in 19 patients (54.2%). Of the 35 patients in the PAS group, 13 (37.1%) had recurrent pain and 3 (8.6%) had recurrent hypertension. Their initial symptoms resolved with PAS but recurred after cyst recurrence. In 2 patients there was persistent pain despite radiologically apparent cyst regression. The cyst recurrence rate was 22.8% (n = 8) in the PAS group. The mean aspirated cyst volume was 172.14 mL (**Table 3**).

There was a significant difference between both symptomatic and radiologic success rates in the LD and PAS groups (**Figure 1**). The success rate for patients with hypertension was 20% (only 1 of 5 patients) in the LD group and 0% (0 of 3 patients) in the PAS group.

In 3 patients (2%) in the LD group, conversion to open surgery was required because of either bleeding or adhesions. No patients in the PAS group had complications.

**Table 2.**  
Intraoperative and Postoperative Results for Laparoscopic Decortication Group

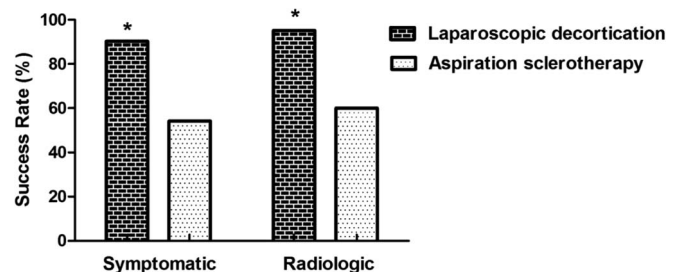
Procedure	Data
Transperitoneal (n)	19 (12.7%)
Retroperitoneal (n)	130 (87.3%)
Transition to open surgery (n)	3 (2%)
Mean diameter of cyst after 1 mo (range) (mm)	10.54 (0–15)
Mean diameter of cyst after 6 mo (range) (mm)	6.62 (0–8)
Mean length of follow-up (mo)	35.26
Symptomatic success (%)	92.6 <sup>a</sup>
Radiologic success (%)	96.6 <sup>a</sup>

<sup>a</sup>Significant at .05 level.

**Table 3.**  
Intraoperative and Postoperative Results for Percutaneous Aspiration-Sclerotherapy Group

	Data
Sclerotherapy (n)	35 (100%)
Mean diameter of cyst after 1 mo (mm)	31.2
Mean diameter of cyst after 6 mo (mm)	24.8
Mean aspirated cyst volume (mL)	172.14
Mean length of follow-up (mo)	34.91
Symptomatic success (%)	54.2 <sup>a</sup>
Radiologic success (%)	60 <sup>a</sup>
Recurrence (%)	22.8

<sup>a</sup>Significant at .05 level.



**Figure 1.** Comparison of symptomatic and radiologic success rates of laparoscopic decortication and percutaneous aspiration-sclerotherapy. Asterisk indicates statistically different from the percutaneous aspiration-sclerotherapy group ( $P < .05$ ).

## DISCUSSION

Peripheral simple RCs are common in the general population and are usually asymptomatic. Generally, management is limited to the control of symptoms. Pain, infection, and obstructive uropathy are the major indications for surgical intervention.<sup>3,7</sup> When cysts are symptomatic, the first-line procedure is often percutaneous aspiration with or without a sclerosing agent.<sup>6,8</sup> Open cyst decortication is thought to have a potentially higher morbidity rate and require longer convalescence, so LD and even nephrectomy can be an option.<sup>9</sup>

LD of RCs has been shown to be an extremely safe and effective therapy.<sup>10,11</sup> Atug et al<sup>12</sup> showed that laparoscopic cyst decortication is an effective and durable treatment option for symptomatic simple RCs during long-term follow-up. They also concluded that the greater and durable success rates of this minimally invasive technique may render this treatment option superior to other treatment modalities.<sup>12</sup> In addition, laparoscopic management of symptomatic RCs has been shown to be effective and is associated with minimal complications, reduced operative time, minimal blood loss, reduced hospital stay, and rapid convalescence.<sup>1,13</sup> On the other hand, in other studies it has been shown that the initial first-line therapy for symptomatic simple RCs was often percutaneous aspiration with or without the instillation of a sclerosing agent, which is associated with a low morbidity rate (1.3%–20%) and high success rate (75%–97%).<sup>6,10,14</sup>

Researchers have shown that the success rate of LD is 60% to 100%, regardless of the approach used, and the radiologic success rate has ranged between 88.2% and 93.9% for peripherally located cysts whereas it has been reported to be 55% for peripelvic cysts.<sup>15</sup> Although several other studies have reported on the safety and high success rate of single-session aspiration and sclerotherapy,<sup>16–18</sup> there was a significant difference between both the symptomatic and radiologic success rates in the LD and PAS groups in our study.

In a study comparing aspiration and sclerotherapy with laparoscopic unroofing in the management of symptomatic simple RCs, Okeke et al<sup>4</sup> showed pain recurrence in all patients treated with sclerotherapy after a mean follow-up period of 17 months. In contrast, all patients in the laparoscopic treatment group were pain free after a mean follow-up period of 17.7 months. Okeke et al concluded that laparoscopic treatment of symptomatic cysts is more effective than sclerotherapy. They also recommended diagnostic simple aspiration of the cyst as a test of pain relief

before sclerotherapy, but the improvement of pain is not necessarily associated with complete resolution of the cyst. In our study, there was persistent pain despite radiologically apparent cyst regression, which means that the pain was unlikely to originate from the RC. The previously reported results were very similar to those of our study, but our follow-up time was twice that of the previous study and our success rate with sclerotherapy was higher than that previously reported. Similarly, Shiraishi et al<sup>19</sup> showed that LD for simple RCs offers not only distinct benefits during surgery but also long-term effectiveness.

In our study, the radiologic success rate was 96.6% and the rate of improvement of symptoms was 92.6% after a mean follow-up period of 35.26 months in the LD group. In the PAS group, the radiologic success rate was 60% and the rate of improvement of symptoms was 54.2% after a mean follow-up period of 34.91 months. The rate of cyst recurrence was 22.8% (n = 8) in the PAS group. Although the success rate was similar to other reported success rates, which is not a new message, no superiority of either of the 2 procedures was found in patients with hypertension. The potential reasons for the treatment failures might be associated with the origin unlikely to be the RC, idiopathic hypertension, or misdiagnosis. Hematuria was completely resolved after the intervention in both groups. A rigorous clinical evaluation is recommended before attributing flank pain or hypertension to a simple RC.

When the methods used in our study were compared, LD was found to have high success rates, a low recurrence rate, and minimal morbidity; PAS was performed as an outpatient procedure and had a minimally higher recurrence rate. Even though LD is a minimally invasive method, PAS is an outpatient procedure with minimal invasiveness compared with LD. Although hospital stay was not assessed in our study, patients undergoing LD should be hospitalized, in contrast to those undergoing PAS. However, this study had some limitations, such as the retrospective method; the fact that the groups were not statistically equal and therefore were not comparable; the relatively low patient number; the lack of randomized controlled studies concerning the same patient group; the fact that the assessment of symptomatic success was based on the subjective reports of the patients; the lack of objective questionnaires to measure the symptoms of the patients; and the lack of comparison of intervention times, hospitalization times, and cost-effectiveness. To our knowledge, there have been limited studies that have specifically examined and compared the clinical outcomes of treatment approaches in this cohort of patients, and selecting the optimal treatment for these patients can

be challenging because each treatment modality has unique advantages and disadvantages.

In the Bosniak classification, classes I and II are considered benign. A small proportion of Bosniak class IIF cysts are malignant.<sup>20</sup> Classes III and IV are at least 50% malignant.<sup>20</sup> In this study, because we did not perform partial or radical nephrectomy, we did not include potentially malignant lesions. Furthermore, even though a small proportion of Bosniak class IIF cysts are malignant, we do not treat these cysts; rather, we perform follow-up, only treating these cysts if they become malignant.

## CONCLUSION

Laparoscopic cyst decortication is an effective and durable treatment for symptomatic simple RCs with long-term durability compared with PAS. The higher success rates of this minimally invasive technique may indicate a preference for the use of this method over other treatment modalities. When symptomatic cysts are encountered and treatment of the cyst is indicated, LD is more efficient and offers better results than PAS. To support these findings, prospective randomized trials should be designed with larger cohorts.

## References:

1. Rane A. Laparoscopic management of symptomatic simple renal cysts. *Int Urol Nephrol*. 2004;36:5–9.
2. Skolarikos A, Laguna MP, de la Rosette JJ. Conservative and radiological management of simple renal cysts: a comprehensive review. *BJU Int*. 2012;110:170–178.
3. Hemal AK. Laparoscopic management of renal cystic disease. *Urol Clin North Am*. 2001;28:115–126.
4. Okeke AA, Mitchelmore AE, Keeley FX, Timoney AG. A comparison of aspiration and sclerotherapy with laparoscopic de-roofing in the management of symptomatic simple renal cysts. *BJU Int*. 2003;92:610–613.
5. Shao Q, Xu J, Adams T, et al. Comparison of aspiration-sclerotherapy versus laparoscopic decortication in management of symptomatic simple renal cysts. *J Xray Sci Technol*. 2013;21:419–428.
6. Camargo AH, Cooperberg MR, Ershoff BD, Rubenstein JN, Meng MV, Stoller ML. Laparoscopic management of peripelvic renal cysts: University of California, San Francisco, experience and review of literature. *Urology*. 2005;65:882–887.
7. Agarwal MM, Hemal AK. Surgical management of renal cystic disease. *Curr Urol Rep*. 2011;12:3–10.
8. Li YZ, Li MX, Wang T, et al. Efficacy and safety of alcohol sclerotherapy involving single-session multiple injections to treat simple renal cysts: a multicenter, prospective, randomized, controlled trial. *Chin Med J (Engl)*. 2013;126:803–807.
9. Kropp KA, Grayhack JT, Wendel RM, Dahl DS. Morbidity and mortality of renal exploration for cyst. *Surg Gynecol Obstet*. 1967;125:803–806.
10. Pearle MS, Traxer O, Cadeddu JA. Renal cystic disease. Laparoscopic management. *Urol Clin North Am*. 2000;27:661–673.
11. Yang D, Xue B, Zang Y, et al. A modified laparoendoscopic single-site renal cyst decortication: single-channel retroperitoneal laparoscopic decortication of simple renal cyst. *J Laparoendosc Adv Surg Tech A*. 2013;23:506–510.
12. Atug F, Burgess SV, Ruiz-Deya G, Mendes-Torres F, Castle EP, Thomas R. Long-term durability of laparoscopic decortication of symptomatic renal cysts. *Urology*. 2006;68:272–275.
13. Dunn MD, Clayman RV. Laparoscopic management of renal cystic disease. *World J Urol*. 2000;18:272–277.
14. Lang EK. Renal cyst puncture and aspiration: a survey of complications. *AJR Am J Roentgenol*. 1977;128:723–727.
15. Wolf JS Jr. Evaluation and management of solid and cystic renal masses. *J Urol*. 1998;159:1120–1133.
16. Bean WJ. Renal cysts: treatment with alcohol. *Radiology*. 1981;138:329–331.
17. El-Diasty TA, Shokeir AA, Tawfeek HA, Mahmoud NA, Nabeeh A, Ghoneim MA. Ethanol sclerotherapy for symptomatic simple renal cysts. *J Endourol*. 1995;9:273–276.
18. Paananen I, Hellstrom P, Leinonen S, et al. Treatment of renal cysts with single-session percutaneous drainage and ethanol sclerotherapy: long-term outcome. *Urology*. 2001;57:30–33.
19. Shiraishi K, Eguchi S, Mohri J, Kamiryo Y. Laparoscopic decortication of symptomatic simple renal cysts: 10-year experience from one institution. *BJU Int*. 2006;98:405–408.
20. Warren KS, McFarlane J. The Bosniak classification of renal cystic masses. *BJU Int*. 2005;95:939–942.