

[CASE REPORT]

Occurrence of Immunoglobulin G4-related Disease during Chemotherapy for Advanced Breast Cancer

Yasutoshi Fujii¹, Mihoko Doi¹, Hiroaki Yamane¹, Takehiko Morioka¹, Daisuke Komichi²,
Takashi Nishisaka³ and Katsunori Shinozaki¹

Abstract:

Immunoglobulin G4-related disease (IgG4-RD) is defined as an inflammatory lymphoproliferative disorder. The relationship between malignancies and IgG4-RD remains unclear. We herein present a case of IgG4-RD that occurred during chemotherapy for advanced breast cancer. In this case, it was challenging to determine which of these diseases was responsible for the patient's mediastinal lymphadenopathy. Lymphadenopathy with IgG4-RD was diagnosed by assessing the reactivity to corticosteroids, which were used as premedication in chemotherapy, over time. The administration of prednisolone, which was initiated to treat active IgG4-RD, led to stable systemic therapy for malignancy. It is imperative to assess the disease activity and consider each treatment.

Key words: IgG4-related disease, autoimmune pancreatitis, lymphadenopathy, breast cancer

(Intern Med 59: 1649-1654, 2020)

(DOI: 10.2169/internalmedicine.3386-19)

Introduction

Immunoglobulin G4-related disease (IgG4-RD), a novel disease concept that was first described in Japan by Hamano et al. (1), is characterized by an elevation of the serum IgG4 level and the infiltration of IgG4-positive plasma cells in tissues, as well as a chronic lymphoproliferative disorder that presents as fibrous, massive, hypertrophic lesions in several organs. In Japan, the Ministry of Health, Labour and Welfare proposed the Comprehensive Diagnostic Criteria for IgG4-RD in 2011 (2). To date, the precise steps resulting in the establishment of IgG4-RD remain unclear. Typically, lymphadenopathy is accompanied by other manifestations of IgG4-RD, and the differentiation of IgG4-RD from malignant tumors is clinically essential. Conversely, IgG4-RD is reportedly correlated with malignancies (3-6), although the relationship between malignant tumors and IgG4-RD remains under debate. We herein report a case of IgG4-RD that occurred during systemic therapy for advanced breast cancer and which the patient experienced repeated exacerbations and remissions with corticosteroids, which were used

as premedication in chemotherapy.

Case Report

A 68-year-old-female with a history of Graves' disease and who presented with pain and swelling in the right upper limb was diagnosed with right breast invasive ductal carcinoma with metastasis to the right axillary lymph nodes and lungs. An immunohistological study revealed HER2 3+, ER 3+, PgR+, and a Ki-67 labeling index of 19.1%. Accordingly, treatment with paclitaxel (PTX)+trastuzumab (Tmab) was initiated for unresectable advanced breast cancer. The regimen was switched to trastuzumab emtansine (T-DM1) due to the development of peripheral neuropathy as an adverse event. The patient showed an iodinated contrast media-related hypersensitivity reaction (generalized urticaria) during the clinical course.

After 2 years and 5 months of chemotherapy, the patient developed painless swelling of the bilateral submaxillary glands. We suspected IgG4-RD because of a high serum IgG4 value (752 mg/dL), but chose to observe the patient without corticosteroid treatment, after confirming that there

¹Division of Clinical Oncology, Hiroshima Prefectural Hospital, Japan, ²Department of Gastroenterology, Hiroshima Prefectural Hospital, Japan and ³Department of Pathology, Hiroshima Prefectural Hospital, Japan

Received: May 23, 2019; Accepted: February 18, 2020; Advance Publication by J-STAGE: April 9, 2020

Correspondence to Dr. Yasutoshi Fujii, yasup31@hotmail.com

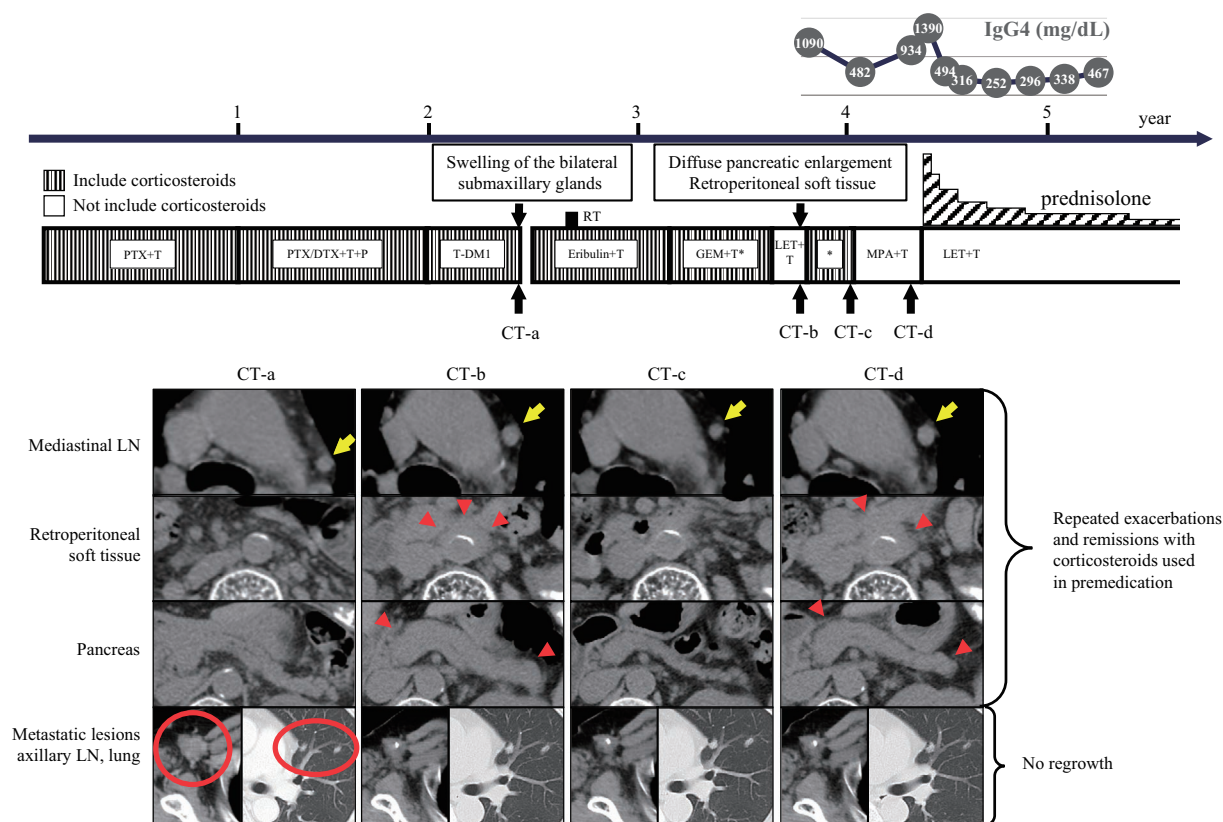


Figure 1. Clinical course. T: trastuzumab, P: pertuzumab, PTX: paclitaxel, DTX: docetaxel, T-DM1: trastuzumab emtansine, GEM: gemcitabine, LET: letrozole, MPA: medroxyprogesterone acetate

were no malignant findings in fine needle aspiration cytology, because she had no symptoms and her condition was accompanied by advanced cancer. At the same period, although her tumor lesions had been shrinking, positron emission tomography-computed tomography (PET-CT) still showed an abnormal uptake of fluorodeoxyglucose (FDG) in the right axillary lymph node. In addition, new lymphadenopathies of the mediastinal and paraaortic lymph nodes (Fig. 1 CT-a) and an abnormal uptake of FDG were detected; these lymphadenopathies were considered to represent new metastatic lesions of breast cancer; thus, we changed the regimen to eribulin+Tmab.

After that, only the right axillary lymph node was enlarged; thus, radiation therapy (39Gy/13fr) was added. The regimen was administered alternately with gemcitabine (GEM)+Tmab and letrozole (LET)+Tmab because of peripheral neuropathy. A follow-up CT scan performed 2 months after the commencement of ongoing LET+Tmab revealed enlargement of mediastinal and paraaortic lymph nodes (Fig. 1 CT-b). We assessed that the breast cancer lesions progressed because of weakness in tumor control in endocrine therapy and returned to GEM+Tmab. Although these lymphadenopathies were reduced (Fig. 1 CT-c), it became difficult to continue GEM due to peripheral neuropathy, and we changed the regimen to medroxyprogesterone acetate (MPA). As a result, these lymphadenopathies enlarged again

(Fig. 1 CT-d). At that time, we retrospectively observed that the pancreas and retroperitoneal soft tissue had enlarged and reduced along with these lymphadenopathies following the initiation of LET+Tmab treatment. Conversely, the sites at the first diagnosis that were the primary lesions—the right axillary lymph node and lungs—consistently showed no regrowth over time (Fig. 1 CT-b, c, d). Of note, the patient did not receive corticosteroids in the period in which she received endocrine therapy+Tmab regimen. In addition, salivary gland swelling, which had been pointed out previously, was subjectively reduced with the administration of corticosteroids as premedication for chemotherapy. Based on these findings, the mediastinal and paraaortic lymph nodes, which were initially considered to be new breast cancer lesions, were considered to be IgG4-RD lesions.

Endoscopic ultrasonography (EUS) revealed low echoic diffuse pancreatic enlargement and stranding echoes. Magnetic resonance cholangiopancreatography (MRCP) showed bile duct stenosis and an irregularly narrow segment of the main pancreatic duct and low apparent diffusion coefficient (ADC) of the diffusely enlarged pancreatic parenchyma. The patient's serum bilirubin and liver enzyme levels were not elevated. We performed EUS-guided fine-needle aspiration, and a histopathological examination revealed infiltration of lymphocytes and plasma cells and fibrosis. After an immunohistochemical evaluation, more than 10 IgG4-positive

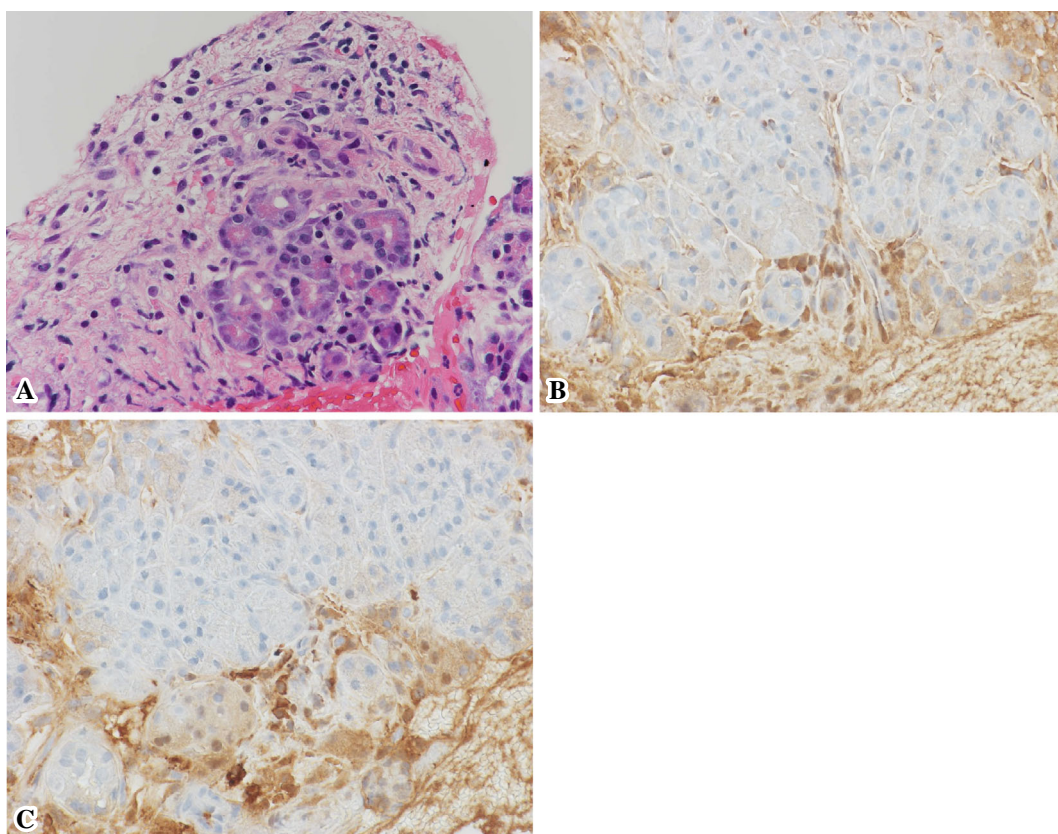


Figure 2. A: A specimen obtained by EUS-guided fine-needle aspiration. Pathologically, the lesion was found to be composed of inflammatory fibrous tissues with lymphoplasmacytic infiltration (Hematoxylin and Eosin staining, $\times 400$). B: Immunohistochemistry with IgG-positive plasma cells (IgG staining, $\times 400$). C: IgG4-immunostaining revealed more than 10 IgG4-positive cells per high-power field (IgG4 staining, $\times 400$). EUS: endoscopic ultrasonography

cells were detected in a high-power field and the IgG4/IgG ratio was $>40\%$ (Fig. 2). A diagnosis of IgG4-RD was made based on the Comprehensive Diagnostic Criteria for IgG4-RD, 2011. Based on the different clinical response to corticosteroids used as premedication in chemotherapy, the lesions of the pancreas, salivary gland, retroperitoneal soft tissue, and the mediastinal and paraaortic lymph nodes were diagnosed as IgG4-RD.

The breast cancer lesions were controlled for long period of time, and prednisolone (PSL; 30 mg) was initiated for IgG4-RD with bile duct stenosis. Thereafter, all lesions showed remission (Fig. 3). Next, we changed the systemic therapy to LET + Tmab because of the contraindication of the combination of MPA and PSL due to the risk of thrombus. Currently, at 6 years since the initiation of chemotherapy, the patient is continuing to stably receive systemic therapy for breast cancer with the administration of PSL to control IgG4-RD.

Discussion

We encountered a case of IgG4-RD that developed during several lines of systemic therapy for advanced breast cancer. The IgG4-related lymphadenopathy was noticed due to the different clinical response of plural lymphadenopathy to cor-

ticosteroids, which were used as premedication for chemotherapy.

The precise steps resulting in the establishment of IgG4-RD remain unclear. IgG4-RD is thought to be an autoimmune condition. The immunological characteristics of IgG4-RD include Th2-cell-dominant immune responses and abundant infiltration of regulatory T (Treg) cells into the involved organs. An excess immunoreaction of Th2 cells is reported to result in the recruitment of Treg cells, that secrete high levels of IL-10, inducing further class-switching to IgG 4 and TGF- β , thereby, driving severe fibrosis (7, 8). To date, several studies have reported that associations between allergic conditions and IgG4-RD may suggest a shared pathogenesis between the two conditions (9). On the other hand, studies of patients with autoimmune conditions have shown a coincidental pathogenesis between malignancy and the subsequent development of dermatomyositis, systemic sclerosis, and other conditions (10). The presented patient showed an allergic predisposition and an iodinated contrast media-related hypersensitivity reaction at 4 months before the onset of IgG4-RD. Moreover, the patient had a history of treatment for Graves' disease that had been administered for 15 years before the onset of IgG4-RD. The previous dataset of 235 consecutive IgG4-RD patients showed that 30% had a past history of allergic disease and 8.5% had a past

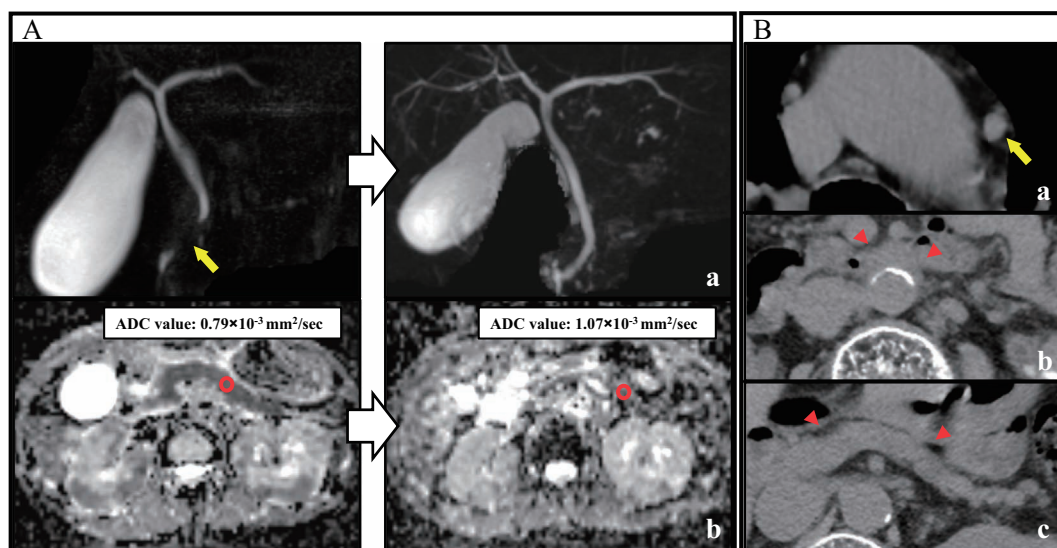


Figure 3. After starting PSL (30 mg) for IgG4-RD. A: MRCP showed improvement in bile duct stenosis (a), and an ADC map showed an increase in the ADC value (b). B: The size of the lesions of the mediastinal LNs (a), retroperitoneal soft tissue (b) and pancreas (c) were reduced. PSL: prednisolone, MRCP: magnetic resonance cholangiopancreatography, ADC: apparent diffusion coefficient, LN: lymph node

history of autoimmune disease, respectively (11). Taken together, the patient may have had an intrinsic risk of developing IgG4-RD.

The association between malignant tumors and IgG4-RD remains under debate (Table). Wallace et al. (6) reported that a history of invasive malignancy is probably correlated with the subsequent development of IgG4-RD, and proposed that malignancy may be a predisposing condition to IgG4-RD in some patients. One possible explanation is that treatment for malignancy fosters immune dysregulation, leading to IgG4-RD in patients with other risk factors for that condition. The presence of malignancy or its treatment may induce some stimulation, such as pathogen-associated molecular pattern molecules and damage-associated molecular pattern molecules, and could cause excess immunoreaction of Th2 cells. In addition, no IgG4-RD manifestations occurred at the site of a prior malignancy in these studies (6); the condition could not be accounted for by local changes in the immunological milieu associated with malignancy, its treatment, or subsequent damage. Even in the largest cohort, which covered all organ manifestations of IgG4-RD in Japan, with the exception of 2 of 38 cases, IgG4-RD and malignancy diagnosed before or at the presentation of IgG4-RD differed in terms of the organ of origin (11). On the other hand, three of six retrospective cohort studies, reporting the risk of malignancy in IgG4-related disease, reported a marked correlation between IgG4-RD and the occurrence of malignancy (Table) (3-5). Those studies proposed that IgG4-RD could feature aspects of paraneoplastic syndrome, a characteristic of which was that the risk of occurrence of malignancies was the highest within 1 year after the diagnosis of IgG4-RD, and the clinical findings of autoimmune disease enhanced with treatment of the underlying malignancy (4, 5).

Moreover, the fact that few malignancies occurred at the site of prior IgG4-RD lesions indicates that IgG4-RD may feature aspects of paraneoplastic syndrome. However, in a study reported by Wallace et al. (6) and our case, the development of IgG4-RD was not correlated with the activity of malignancy and did not match the characteristics of paraneoplastic syndrome. Conversely, the other three studies reported that IgG4-RD was not markedly correlated with the occurrence of malignancy (1-13); this discrepancy could be attributed to differences in the analytical methods. Hirano et al. and Inoue et al. excluded subjects who were concurrently diagnosed with IgG4-RD complicated with malignancy.

We initiated corticosteroid treatment (CST) for IgG4-RD that developed during chemotherapy for advanced breast cancer. The early introduction of CST is recommended, especially for patients with progressive fibrosis in the salivary glands and pancreas lesions (14-16). However, CST is associated with a risk of susceptibility to infection during chemotherapy. Observation may be appropriate for advanced cancer patients with asymptomatic lesions; however, if the disease activity of IgG4-RD is high, CST may lead to stable systemic therapy for advanced cancer. In short, it is important that the activity of each disease be precisely assessed. On the other hand, immunosuppressants can interfere with the anticancer response, although no clear evidence exists to support the correlation between malignant tumor progression and corticosteroid therapy. Previous studies have demonstrated that corticosteroids inhibit chemotherapy-induced cell apoptosis, whereas other investigations have reported that they suppress tumor progression and metastasis (17). In breast cancer, the response of breast cancer cells to glucocorticoid signaling may differ among breast cancer subtypes. Preclinical data has revealed that glucocorticoids receptor

Table. The Association between Malignant Tumors and IgG4-RD.

Reference	Number of cases	Follow up period	Number of cases that developed malignant tumor	Cancer type	Standardised incidence rate (95% CI)	Relative risk (95% CI)
3	106	average 3.1 years	11 (10.4%)	Colon(2)Lung(2)ML(2)Breast(1)Kidney(1)Prostate(1)Ovary(1)Tongue(1)	3.8	
4	108 AIP only	median 3.3 years	15 (13.9%)	Stomach(7)Lung(3)ML(2)Prostate(2)Colon(2)Bile duct(1)Thyroid(1)	• All 2.7 (1.4-3.9) • within 1 year 6.1 (2.9-9.9) • 1 year or more 1.5 (0.3-2.8)	At the time of AIP diagnosis 4.9 (1.7-14.9)
12	113	median 6.1 years	14 (12.4%)	Lung(5)Stomach(2)Pancreas(2)Bile duct(1)Kidney(1)Tongue(1)Breast(1)MM(1)AML(1)	1.04 (0.57-1.8)	
13	116 AIP only	median 3 years	11 (9.5%)	Prostate(4)ML(2)Kidney(2)Breast(1)Bile duct(1)Pancreas(1)		0.64 (0.27-1.51)
11	235	median 3 years	13 (6%)	Lung(6)Colon(3)Stomach(2)Urinary Bladder(2)Pancreas(1)Kidney(1)	1.16	
5	158	median 5.95 years	34 (21.5%)	Lung(5)Colon(5)Prostate(5)Stomach(4)Pancreas(4)Kidney(2)ML(2)Bile duct(1)Liver(1)Esophagus(1)Ovary(1)Breast(1)Thyroid(1)Tongue(1)Skin(1)MS(1)	• All 2.01 (1.34-2.69) • within 1 year 3.53 (1.23-5.83) • 1 year or more 1.48 (0.99-1.98)	
Reference	Number of cases	Number of cases with a history of invasive cancer prior to IgG4-RD diagnosis		Cancer type	Standardised prevalence rate (95% CI)	Odds ratio (95% CI)
6	125	20 (16.0%)		Prostate(7)ML(4)Colon(2)Lung(2)Testicle(2)Breast(2)Cervix(1)Leukemia(1)	2.5 (1.1-3.6)	3.1 (1.6-6.2, p=0.01)

ML: malignant lymphoma, MM: malignant melanoma, AML: acute myeloid leukemia, MS: myelodysplastic syndrome, CI: confidence interval

(GR) activation may reduce estrogen-induced cell proliferation in ER-positive breast cancer (18). On the other hand, in ER-negative breast cancer, the high tumor expression of GR is associated with a poor prognosis and GR activation suppresses chemotherapy-induced apoptosis (19). In our case of ER-positive breast cancer, the shrinkage of the malignant lesions has been maintained, with no abnormal uptake of FDG and without the appearance of new lesions, while controlling IgG4-RD with PSL. Thus, it seems that there have been no adverse effects from PSL.

Overall, this case indicates that malignancy may be a predisposing condition to IgG4-RD, and may not be a characteristic of paraneoplastic syndrome. It is imperative to assess the disease activity and consider each treatment.

The authors state that they have no Conflict of Interest (COI).

References

- Hamano H, Kawa S, Horiuchi A, et al. High serum IgG4 concentrations in patients with sclerosing pancreatitis. *N Engl J Med* **344**: 732-738, 2001.
- Okazaki K, Kawa S, Kamisawa T, et al. Comprehensive diagnostic criteria for IgG4-related disease (IgG4-RD) 2011. *J Jpn Soc Intern Med* **101**: 795-804, 2012.
- Yamamoto M, Takahashi H, Tabeya T, et al. Risk of malignancies in IgG4-related disease. *Mod Rheumatol* **22**: 414-418, 2012.
- Shiokawa M, Kodama Y, Yoshimura K, et al. Risk of cancer in patients with autoimmune pancreatitis. *Am J Gastroenterol* **108**: 610-617, 2013.
- Asano J, Watanabe T, Oguchi T, et al. Association between immunoglobulin G4-related disease and malignancy within 12 years after diagnosis: an analysis after longterm follow up. *J Rheumatol* **42**: 2135-2142, 2015.
- Wallace ZS, Wallace CJ, Lu N, Choi HK, Stone JH. Association of IgG4-related disease with history of malignancy. *Arthritis Rheumatol* **68**: 2283-2289, 2016.
- Zen Y, Fujii T, Harada K, et al. Th2 and regulatory immune reactions are increased in immunoglobulin G4-related sclerosing pancreatitis and cholangitis. *Hepatology* **45**: 1538-1546, 2007.
- Yamamoto M, Takahashi H, Shinomura Y. Mechanisms and assessment of IgG4-related disease: lessons for the rheumatologist. *Nat Rev Rheumatol* **10**: 148-159, 2014.
- Kamisawa T, Anjiki H, Egawa N, Kubota N. Allergic manifestations in autoimmune pancreatitis. *Eur J Gastroenterol Hepatol* **21**: 1136-1139, 2009.
- Joseph CG, Darrah E, Shah AA, et al. Association of the autoimmune disease scleroderma with an immunologic response to cancer. *Science* **343**: 152-157, 2014.
- Inoue D, Yoshida K, Yoneda N, et al. IgG4-related disease: dataset of 235 consecutive patients. *Medicine (Baltimore)* **94**: e680, 2015.
- Hirano K, Tada M, Sasahira N, Isayama H, Mizuno S, Takagi K, et al. Incidence of malignancies in patients with IgG4-related disease. *Intern Med* **53**: 171-176, 2014.
- Hart PA, Law RJ, Dierkhising RA, Smyrk TC, Takahashi N, Chari ST. Risk of cancer in autoimmune pancreatitis: a case-control study and review of the literature. *Pancreas* **43**: 417-421, 2014.

14. Khosroshahi A, Wallace ZS, Crowe JL, et al. International consensus guidance statement on the management and treatment of IgG4-related disease. *Arthritis Rheumatol* **67**: 1688-1699, 2015.
15. Shimizu Y, Yamamoto M, Naishiro Y, et al. Necessity of early intervention for IgG4-related disease: delayed treatment induces fibrosis progression. *Rheumatology* **52**: 679-683, 2013.
16. Hirano K, Tada M, Isayama H, et al. Long-term prognosis of autoimmune pancreatitis with and without corticosteroid treatment. *Gut* **56**: 1719-1724, 2007.
17. Lin KT, Wang LH. New dimension of glucocorticoids in cancer treatment. *Steroids* **111**: 84-88, 2016.
18. Karmakar S, Jin Y, Nagaich AK. Interaction of glucocorticoid receptor (GR) with estrogen receptor (ER) alpha and activator protein 1 (AP1) in dexamethasone-mediated interference of ERalpha activity. *J Biol Chem* **288**: 24020-24034, 2013.
19. Wu WS, Chaudhuri S, Brickley DR, Pang T, Karrison SD. Microarray analysis reveals glucocorticoid-regulated survival genes that are associated with inhibition of apoptosis in breast epithelial cells. *Cancer Res* **64**: 1757-1764, 2004.

The Internal Medicine is an Open Access journal distributed under the Creative Commons Attribution-NonCommercial-NoDerivatives 4.0 International License. To view the details of this license, please visit (<https://creativecommons.org/licenses/by-nc-nd/4.0/>).

© 2020 The Japanese Society of Internal Medicine
Intern Med 59: 1649-1654, 2020