

# Emerging options for the management of age-related macular degeneration with stem cells

Ingrid Mooney<sup>1</sup>  
James LaMotte<sup>2</sup>

<sup>1</sup>Eye Design, Santa Fe, NM, USA;

<sup>2</sup>Department of Basic and Visual Science, Southern California College of Optometry, Fullerton, CA, USA

**Abstract:** Age-related macular degeneration (AMD) is a devastating retinal disease that occurs in later life as the retinal pigment epithelium (RPE) cells die, with subsequent photoreceptor degeneration. In the past, RPE transplant surgeries gave evidence that AMD was potentially treatable, but it involved limited amounts of ocular tissue, and the complication rate was high. Then, stem cell transplants offered an unlimited supply of retinal precursors for endogenous repair and exogenous cell replacement. Debate continues as to which type of stem cell is most appropriate for treating AMD. The prospects include adult-derived progenitor stem cells (including progenitor cells from ocular tissues), hematopoietic stem cells, embryonic stem cells, and induced pluripotent stem cells. Now the therapy is expanding into phase I human trials. This review examines the collective research contributions toward a clinical model of AMD management with stem cells.

**Keywords:** age-related macular degeneration, pluripotent stem cells, stem cells, transplantation, retinal pigmented epithelium

## Age-related macular degeneration

“Difficult” is an apt word to describe age-related macular degeneration (AMD). The disease is difficult for patients because they lose central vision (only the macula is affected, and the rest of the retina is undamaged),<sup>1</sup> which is devastating. AMD is difficult for the eye care provider because few therapeutic treatments are available.<sup>2</sup> This disease is also a difficult challenge for those pursuing stem cell therapy because it involves not only the retinal pigmented epithelium (RPE), a monolayer of the retina, but also the complex photoreceptors and their myriad nervous connections.<sup>3</sup>

The RPE has many functions, but the phagocytic role of the RPE is one that is essential for the renewal of photoreceptors.<sup>3,4</sup> However, after decades of phagocytic activity, accumulation of the immense amount of damaging metabolic waste becomes an ever-increasing burden on RPE cells. As RPE cells are injured and die in the macula, AMD progresses, resulting in central vision loss. Usually, the first visible sign on the retina is a concentration of yellowish, globular deposits called drusen at the macula. Drusen are hyalinized material containing membrane-bound bodies<sup>5</sup> in Bruch’s membrane, which is situated between the RPE and the choriocapillaris (a choroidal structure that supplies blood for the outer layers of the retina).

In addition to advancing age, there are other factors that are related to AMD. One of these is genetics, which is a well-known influence in this disease.<sup>6</sup> AMD has been shown to be a polygenic disorder, and more than half a dozen chromosomes<sup>7,8</sup> and numerous proteins are associated with it.<sup>9</sup> The Y402H sequence in complement factor H

Correspondence: James LaMotte  
Department of Basic and Visual  
Science, Southern California College  
of Optometry, 2575 Yorba Linda Blvd,  
Fullerton, CA 92831, USA  
Tel +1 714 449 7486  
Email jlamotte@scco.edu

has a strong association with AMD. However, several different alleles appear to increase the risk of AMD.<sup>10</sup> Other contributors are lifestyle factors such as diet, smoking, and ultraviolet ray exposure.<sup>3</sup>

There are two forms of AMD. Dry AMD is evidenced by drusen deposition and degeneration of the outer retina, RPE, and choriocapillaris. Wet AMD is characterized by widespread atrophy and choroidal neovascularization (CNV) formation, in which blood vessels from the choriocapillaris grow into the normally avascular subretinal space. Formation of this membrane can cause hemorrhage, RPE detachment, scarring, and profound vision loss.

In a normal retina, growth factors secreted by the RPE are involved in inhibiting the abnormal growth of vessels (angiogenesis) in the choroid. These growth factors also support the RPE and choroid, whereas brain-derived neurotrophic growth factor may support differentiation of the RPE.<sup>11,12</sup> Pigment epithelium-derived growth factor may maintain angiogenic balance by prohibiting angiogenesis.<sup>12,13</sup> Proangiogenic vascular endothelial growth factor-A (VEGF-A) promotes survival of choriocapillaris endothelial cells,<sup>14</sup> and angiopoietin 1 and 2 may stabilize new blood vessels and regulate vascular permeability.<sup>15</sup> Thus, damage to the RPE causes choroidal changes such as angiogenesis and ultimately the degeneration of photoreceptors.<sup>16</sup>

The mechanism for CNV formation appears to be multifaceted. Usually, it is associated with a defect in Bruch's membrane caused by atrophy or macrophage activity.<sup>17</sup> One plausible explanation for CNV formation is that the age-related lipid drusen deposits and inflammation of Bruch's membrane cause decreased diffusion of oxygen and growth factors.<sup>18</sup> Deterioration and disorganization of Bruch's membrane contribute to the breakdown of the blood-retinal barrier between the choroid and retina.<sup>19</sup> Hypoxia and decreased permeability lead to the overexpression of growth factors and the accumulation of VEGFs, which stimulates angiogenesis.<sup>20</sup> Hypoxia also attracts macrophages and promotes choriocapillaris atrophy.<sup>14,17</sup> Bone marrow-derived endothelial precursor cells are recruited to the region and contribute to CNV formation as well.<sup>21</sup>

In a diseased eye, oxidative stress may trigger changes in cell surface molecules that functionally impair circulating hematopoietic stem cells (HSCs) derived from bone marrow. Decreased HSC function has been linked to CNV development.<sup>22</sup> Bone marrow-derived mesenchymal stem cells express matrix metalloproteinase (MMP13). Increased expression of proangiogenic MMP13 has also been linked to CNV development. In both cases, the molecular

mechanisms involved appear to be multifaceted and are not fully understood. If these responses can be therapeutically controlled, CNV formation might be subdued.<sup>23</sup>

Surgical removal of CNV is possible, but it may recur. Common surgical complications include hemorrhage and retinal detachment. The use of photodynamic therapy to treat CNV may actually trigger recurrence of CNV by promoting the hypoxic state.<sup>19,24</sup> Anti-VEGF treatments have proven useful in inhibiting neovascularization and increasing visual acuity by 25%–40%.<sup>25</sup> However, anti-VEGF injections are costly and must be given every 4–6 weeks throughout the life of the patient.<sup>26</sup>

## Retinal transplantation Macular translocation

Researchers reasoned that by relocating the fovea (the center of the macula) to a healthier area of RPE, visual function might be restored to AMD patients. This highly technical surgery requires vitrectomy, induced retinal detachment, retinotomy, excision of the neovascular complex, translocation of the fovea, retinal reattachment, and silicone tamponade. Since the original study by Machemer and Steinhorst in 1993,<sup>27</sup> the procedure has been performed on hundreds of AMD patients. Between 25% and 66% of macular translocation patients had improved visual acuity.<sup>27–29</sup> A long-term follow-up of 40 patients found that 25% retained a significant improvement in visual acuity 3 years postoperatively,<sup>30</sup> thus proving that AMD is potentially treatable. However, macular translocation patients suffered a high complication rate, including proliferative vitreoretinopathy, recurrent CNV, hemorrhage, macular hole, low intraocular pressure, macular edema, intraocular lens dislocation, and double vision resulting from image rotation.<sup>27–31</sup>

## Autologous RPE translocation

Grafts of RPE and choroid from the periphery of the retina have been proposed because this tissue source is more abundant, larger grafts can be harvested, and peripheral retinal regions are generally unaffected by AMD.<sup>31</sup> Because equatorial grafts are predominantly composed of rods, there is doubt as to how long transplanted rods can maintain foveal cones.<sup>32</sup> Hundreds of AMD patients have undergone RPE translocation. Between 25% and 57% experienced some visual improvement.<sup>32–36</sup> One study of 84 patients found a visual acuity improvement at 1–2 years, with further improvement at 3 years, indicating that, in some cases, long-term visual improvement was sustainable.<sup>33</sup>

However, RPE/choroid transplants were plagued by a similar high complication rate. Complications included hemorrhage, recurrent CNV, epiretinal membrane, intraretinal cysts, retinal detachment, macular hole, RPE damage, and proliferative vitreoretinopathy due to efflux of RPE cells into the intravitreal cavity.<sup>36</sup> There were also reports of difficulty in accurate graft placement and graft failure due to nonadhesion or nonperfusion of the transplant.<sup>32–36</sup> Concerns were also raised that autologous RPE transplants may have impaired function due to inherent disease processes.<sup>37</sup>

## Iris pigmented epithelium transplantation

The iris pigmented epithelium (IPE) has the same embryonic origin as the RPE. In rabbit studies, subretinally transplanted autologous IPE grafts formed a monolayer on the RPE and phagocytosed rod outer segments (a critical function in the renewal of photoreceptors).<sup>38</sup> In comparison with the complexity of obtaining RPE transplants, harvesting IPE required a simple procedure on the iris. In a study of 19 patients (17 with AMD), autologous IPE grafts were transplanted subretinally. Five patients showed visual improvement of three to four lines on a visual acuity chart. The complication rate was reduced to two patients who suffered retinal detachment and proliferative vitreopathy. None of the patients had a recurrence of CNV at 11 months postoperatively.<sup>39</sup>

In all of these transplantation studies, early intervention was deemed critical because damage to Bruch's membrane interferes with RPE cell adhesion, which can result in graft failure,<sup>40</sup> a glial scar barrier in a diseased retina, which interferes with graft integration,<sup>41</sup> and disruption of the blood–retinal barrier, which can compromise graft survival.<sup>42</sup> Furthermore, in late stages of AMD, secondary retinal degeneration in the inner retina and retrograde neuronal degeneration result in reorganization of synaptic connections in higher visual pathways and may ultimately limit potential functional improvement.<sup>43</sup> These studies pointed to the need for an abundant RPE source for the millions who are affected by AMD and a less complicated surgical approach with sustainable results.

## Stem cell therapy Selecting a therapy

Stem cell therapy was proposed as a means to provide a limitless source of retinal precursors for endogenous repair and exogenous cell replacement of the RPE and photoreceptors. However, selecting the most appropriate stem cell for AMD treatment has been a challenge (see Figure 1).

In general terms, a stem cell is an undifferentiated cell capable of self-renewal and giving rise to one or more differentiated cell types. Stem cells can migrate extensively and possess varying degrees of plasticity, meaning they can form cells in areas where they are not normally found. For example, when transplanted into the olfactory bulb, adult hippocampal progenitor cells generated site-specific olfactory cells with phenotypes not found in the hippocampus.<sup>44</sup>

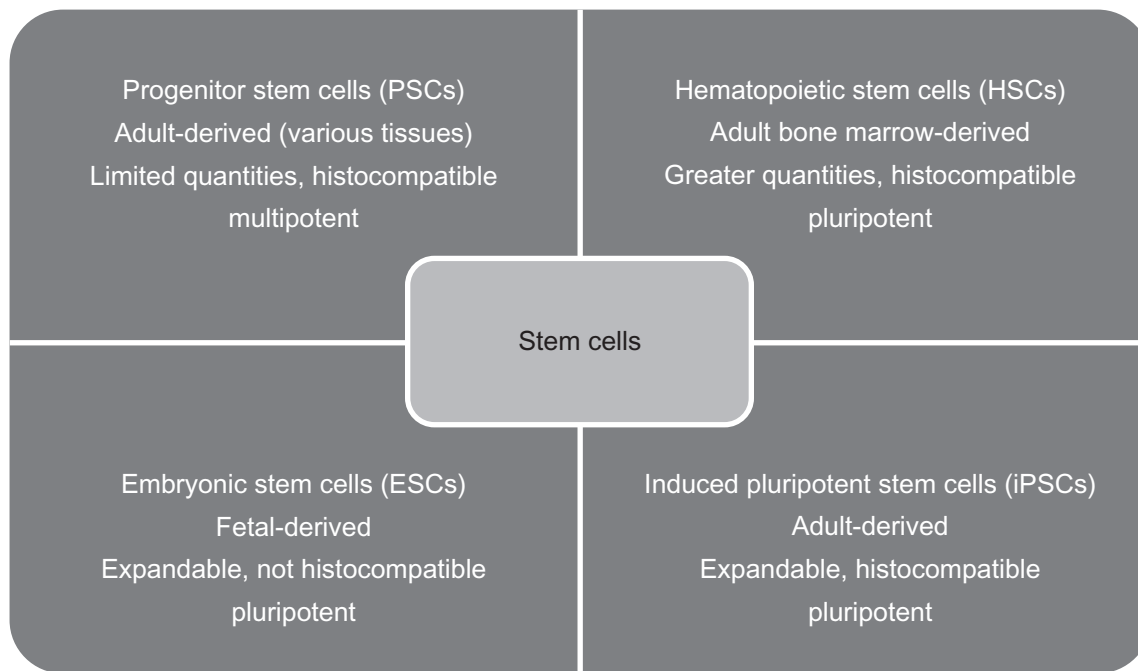
## Adult-derived progenitor stem cells

Multipotent progenitor stem cells (PSCs) are derived from adult tissue and give rise to a limited array of cell types.<sup>45</sup> Because PSC differentiation is limited, the generated cell types are more predictable. Use of autologous PSCs obviates the need for immunosuppressive therapy, and their use is not prone to ethical debate. However, PSCs have more limited self-renewal potential, and because they do not always expand well in culture,<sup>46</sup> controlling PSC differentiation is difficult.<sup>47,48</sup> Additionally, the available quantities of PSCs are more limited.<sup>49</sup>

PSCs differentiate into a wide variety of retinal cell types, including photoreceptors.<sup>50</sup> Retinal injury stimulates signaling mechanisms and the release of growth factors that guide the migration, proliferation, and differentiation of PSCs in damaged areas. PSCs implanted subretinally have been shown to rescue photoreceptors, integrate with the outer nuclear layer of the retina, and express photoreceptor-specific markers such as recoverin, rhodopsin, and cone opsin.<sup>51</sup> When progenitor or precursor cells are precommitted to a rod lineage prior to transplantation, they produce rod receptors with a mature phenotype.<sup>52</sup> In rodent studies, a bypass nerve graft from the optic nerve head to the pretectal region of the brain resulted in a restored pupillary response.<sup>53</sup> A bypass graft from the optic nerve head to the superior colliculus produced positive visual-evoked potentials and restored the ability of rodents to visually identify simple linear patterns.<sup>54–56</sup> Neural PSCs have been induced to differentiate into cortical neurons that survived many months and formed long-distance connections in the rodent brain.<sup>44,57</sup> Taken together, these studies suggest that PSCs might repair the retina and damaged brain pathways and succeed in restoring some degree of visual function.

## Limbal epithelial progenitor cells

Although available in limited quantities, epithelial cells from the limbus at the periphery of the cornea can acquire properties of neural progenitor cells and could potentially be expanded in vitro. These cells can seemingly differentiate



**Figure 1** Summary table and comparison of four promising stem cell classifications and their characteristics. The first line is the classification. The second line is the derivation of the stem cells. The third and fourth lines are general characteristics.

into rod photoreceptors, albeit with a low (20%) *in vitro* efficiency.<sup>48</sup> Activation of Shh and Wnt pathways may increase their efficiency.<sup>48</sup>

## Müller cells

Müller cells, which serve a supportive function in the retina, are also progenitor-like cells. Müller cells may be responsible for retinal regeneration in rats<sup>58</sup> and chicks.<sup>59</sup> Although the human retina does not regenerate, humans have gametes for organism regeneration, which are ostensibly inhibited to prevent uncontrolled cell division.<sup>60</sup> Human-derived Müller cells express markers for retinal neurons, which raises the possibility that if retinal regeneration could be activated in humans, it might allow for endogenous retinal repair.<sup>61</sup>

## Mesenchymal stromal stem cells

Mesenchymal stromal cells derived from human adipose tissue have been induced to differentiate into cells expressing RPE markers. The differentiated cells synthesize pigment, which may help offset the early pigmentary changes characteristic of dry AMD. Further research is needed to assess the functional capacity of these cells.<sup>62</sup>

## Bone marrow-derived stem cells

In rodent studies, bone marrow-derived stem cells differentiated into neural retinal cells. When injected into

the vitreous of eyes with damaged retinas, they incorporated mainly into the outer nuclear layer of the retina and expressed rhodopsin.<sup>63</sup> In a separate study involving mice with RPE degeneration, HSCs were aspirated from the bone marrow of mouse femurs and injected systemically into the tail vein. Within 4–6 weeks, 90% of the cells in the subretinal space were bone marrow-derived RPE cells expressing RPE65. This demonstrated the ability of these cells to migrate extensively and ‘home’ to damaged subretinal tissues.<sup>64</sup>

Encouraging results such as these prompted a phase I human trial in India in which autologous bone marrow-derived stem cells were harvested, isolated, and injected into the vitreous of 25 AMD and 25 retinitis pigmentosa patients. Visual acuity improved at 1 month and improved further at 3 months, expanding the visual range from near zero to a distance of a few meters.<sup>65,66</sup> A similar experiment on one retinitis pigmentosa patient yielded comparable results, with the patient reporting improved vision, color discrimination, and reduced photosensitivity.<sup>67</sup>

The advantages of using bone marrow-derived stem cells are their availability, ease of isolation, and the potential for autologous (histocompatible) transplants that would not require immunosuppression.<sup>68</sup> However, hematopoietic cells can migrate to other organs as well, such as the lungs, and it is unknown what complications might arise as a result.<sup>64</sup>

## Embryonic stem cells

Pluripotent embryonic stem cells (ESCs) are derived from a blastocyst inner cell mass, and they can give rise to almost all of the 220 cell types in the human body except the trophoblast.<sup>46</sup> ESCs can be grown in culture for extended periods and can differentiate into all three germ layers, but there are ethical concerns surrounding the use of fetal-derived ESCs. In addition, the mechanisms of differentiation are poorly understood and difficult to control. Researchers have encountered problems with differentiation into undesired or multiple cell types, mutations, and tumor formation.<sup>69</sup> A further problem is that in the absence of immunosuppression, an adult ESC recipient risks transplant rejection in response to ESC surface antigens.<sup>45,69,70</sup>

Phagocytosis of rod outer segments is an important function because it permits continual renewal of the disks containing rhodopsin, the visual pigment of rods. In Royal College of Surgeons (RCS) rats, phagocytosis of rod outer segments is impaired, resulting in degeneration of the photoreceptors in the first month of life and serious visual impairment within 2–3 months. ESCs from a mouse blastocyst were differentiated *in vitro* into neural precursors and were transplanted subretinally into 20-day-old RCS rats. Up to eight rows of photoreceptor cells were observed at 2 months in the eyes of the rats that received the transplants.<sup>71</sup> Researchers have wondered whether human embryonic stem cells (hESCs) would respond similarly.

## hESCs

In multiple experiments, hESCs were transplanted subretinally into mice and RCS rats. They differentiated into retinal progenitors and gave rise to photoreceptor precursors at 20% efficiency,<sup>72</sup> and the rodents showed improved responses to light, orientation patterns, and spatial frequencies.<sup>73,74</sup> hESCs have also been shown to restore electroretinogram responses, which is evidence that nervous signals are reaching the visual cortex.<sup>75</sup> However, in one study, the electroretinogram response subsequently disappeared at 19 weeks, suggesting that visual rescue was not sustainable.<sup>76</sup> Use of hESCs has shown other characteristics of usable cells as they differentiated into RPE. They formed tight junctions (which are important for maintaining the blood–brain barrier), expressed RPE markers, and survived up to 9 months long term.<sup>43,77,78</sup> The embryonic stem cell-derived pigmented epithelial cells have shown functionality by demonstrating phagocytosis of latex beads simulating the rod outer segment disks.<sup>79</sup>

Various culturing techniques have been tested to increase the efficiency of hESCs. Wnt and nodal antagonists improved hESCs efficiency,<sup>80</sup> whereas nicotinamide with

activin A increased RPE differentiation from 13% to 73% in 8 weeks.<sup>76,78</sup> Further, noggin or dkk1 with IGF 1 increased retinal progenitors expressing Crx, rhodopsin, s-opsin, and recoverin and accelerated development by 3–4 weeks.<sup>72</sup> Recently, three-dimensional constructs of RPE were generated from hESCs grown on a matrix. It is hoped that these young graft structures might integrate and adhere more readily because RPE cells are anchorage dependent.<sup>81</sup> If Bruch's membrane and the extracellular matrix are not supportive, apoptosis and graft failure can occur. Adhesion molecules like integrin and cadherin may aid binding, and various scaffolding matrices have been tried with varying success.<sup>82</sup>

Potentially, hESCs seem to offer an unlimited source of RPE, but there are drawbacks to using them.<sup>47</sup> One argument against expanding RPE in this way is that after 40 passages, glial cells are preferentially produced.<sup>60</sup> RPE alters as early as two to three passages. Over time, RPE cell potency can decline and RPE65 (which is needed for photoisomerization of all trans-retinaldehyde) becomes undetectable.<sup>82</sup> In addition, pluripotent ESCs are known to cause tumor formation.<sup>69</sup> Epigenetic variation in hESC passages could result in safety issues, so a stable karyotype over multiple passages is needed.<sup>83</sup> In addition, cells must exit the active cycle prior to transplantation; otherwise, recoverin-positive cells can proliferate and form tumors.<sup>84</sup>

hESCs of fetal origin have demonstrated potential because they can differentiate into specific cell types, but they have raised ethical concerns and are not widely available.<sup>85</sup> Additionally, fetal cells can be rejected in an adult recipient due to immunoincompatibility.<sup>85</sup> In rodent studies, cyclosporine has often been used as an immunosuppressant, but immunosuppressants can have serious side effects. It is unknown how much immunosuppression might be needed in correlating human studies.<sup>47</sup> In RCS rat studies, visual acuity was shown to decrease with or without immunosuppression, which may indicate the need for multiple transplants.<sup>77</sup> One proposed solution is to establish an hESC bank of pure, pathogen-free cells with minimal epigenetic variations<sup>26,86</sup> and with a human leukocyte antigen histocompatibility match.<sup>47</sup>

Amniotic fluid-derived cells also express ESC markers and behave like pluripotent cells, but, unlike ESCs, they have not proven to be tumorigenic *in vivo*. They can migrate and integrate in mouse brains and are precursors to a broad array of cells, including cells expressing Pax 6, which characterizes a retinal progenitor. They retain a normal karyotype for 260 doublings and could also be human leukocyte antigen matched. Further, research is needed to determine whether they can be used to restore retinal function.<sup>46</sup>



## Induced pluripotent stem cells

To create a stem cell with the best attributes of both an adult progenitor stem cell and an embryonic stem cell, researchers tried a new approach by reprogramming somatic (adult) cells to behave like ESCs. Although induced pluripotent stem cells (iPSCs) were first derived from mouse fibroblasts,<sup>87</sup> a year later, human iPSCs were generated by overexpressing four transcription factors that were introduced via a viral vector and randomly integrated into the genome.<sup>88,89</sup> This procedure was highly technical and time consuming. In addition, altering the genetic material raised the risk of mutations and tumor formation. There were other concerns that using patient-derived somatic cells might reintroduce the original genetic defects and contribute to the patient's disease.<sup>90</sup> It is unclear as to how long the cells have been reprogrammed and whether cells derived from and transplanted into an aged eye will respond adequately.<sup>26</sup>

Nevertheless, iPSCs appear to differentiate into a variety of retinal cells, including retinal ganglion cells, rods, and cones.<sup>85</sup> iPSCs derived from human fetal lung fibroblasts and transplanted subretinally in RCS rats differentiated into functional RPE capable of phagocytosing rod outer segments and preserving the outer nuclear layer of the retina. The rats showed improved visual acuity and light responses; however, at 13 weeks, the iPSCs were undetectable, perhaps due to macrophage activity. More research is needed to ensure long-term cell survival.<sup>91</sup>

Nonviral induction methods were next explored, including plasmids,<sup>92</sup> nonintegrating episomal vectors,<sup>93</sup> and chemicals.<sup>94</sup> More recently, protein-induced pluripotent stem cells have been produced by direct delivery of recombinant (reprogramming) proteins.<sup>95</sup> The use of recombinant proteins eliminates the risk of genetic modification. It is simpler and more efficient than genetic manipulation. Recombinant proteins are readily available and cost-effective. In addition, over 30 passages, protein-induced pluripotent stem cells produced cells identical to ESCs, and they differentiated into all three germ layers.<sup>96</sup>

The differentiation state of induced PSCs is unique, and genetic differences between stem cell-derived RPE cells and primary RPE have been noted. It is unclear how these variations may affect the function of stem cell-derived RPE cells.<sup>97</sup> Further research is needed to determine whether protein-induced PSCs or ESCs are ultimately the best cells for treating AMD.

## Higher visual pathways

All of these approaches rely on early intervention, ie, before secondary degeneration, including retrograde neuronal degeneration, has occurred. As discussed in our previous

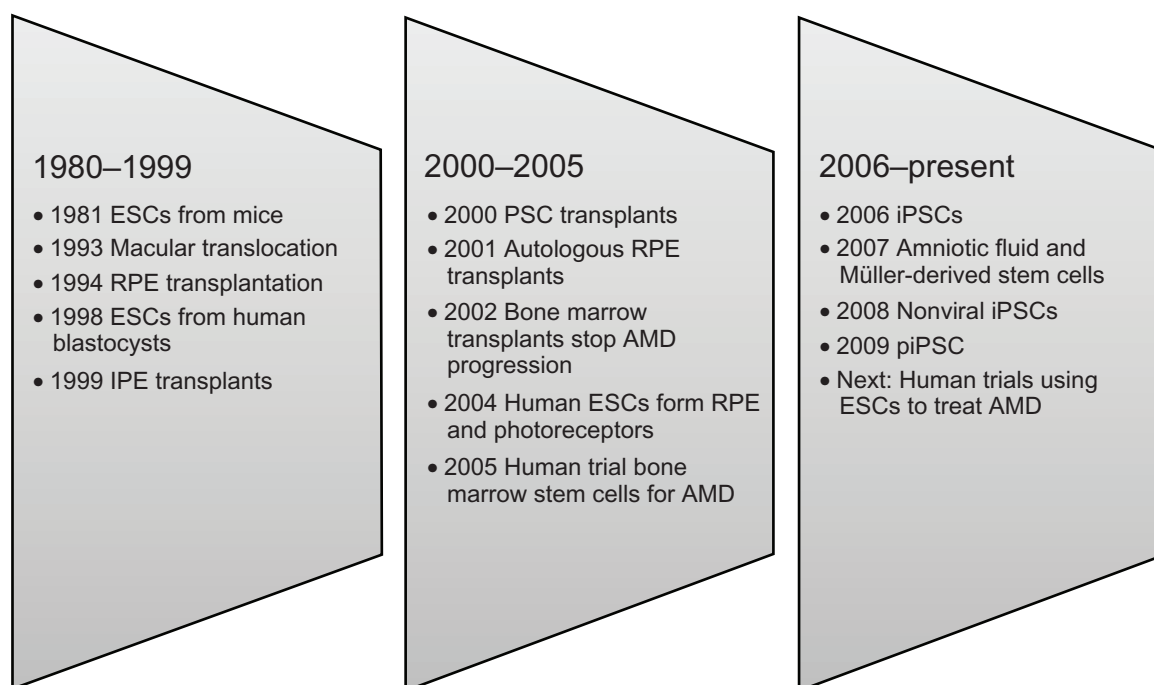
article,<sup>98</sup> retinal progenitor cells can migrate extensively throughout the retina,<sup>99</sup> and growth factors promote axonal growth of retinal ganglion cells. In response to environmental cues, axons can grow and extend into the optic nerve head of the retina,<sup>100</sup> but gliosis or scarring and inhibitory proteins in the myelin of the optic nerve sheath prevent further axonal nerve growth beyond this point.<sup>101–103</sup> In rodent studies, peripheral nerve grafts from the optic nerve head to the superior colliculus or pretectal regions of the brain were used to bypass this roadblock. The axons extended into the grafts and reached the brain, where they apparently formed functional synapses and resulted in improved responses to light and striped visual patterns, restored pupil reactivity, and increased visual evoked potentials in the visual cortex.<sup>52–55,104</sup>

In a human model, however, it might be expected that bypassing the lateral geniculate nucleus (which mediates stereoscopic vision) could disrupt correspondence to the retina and result in visual confusion. A lack of knowledge regarding the lateral geniculate nucleus leaves this question unanswered. More research is needed to determine whether such a bypass graft is feasible in a human and whether it might succeed in restoring function to the higher visual pathways. Rodent studies suggest that significant visual improvement may be achieved even if a small population (about 15%) of axons reach the brain,<sup>52,104</sup> but it is unknown whether this may hold true for humans. For stem cell therapy to succeed in AMD patients with advanced degeneration, it is critical to develop a means of restoring these higher neuronal connections and pathways. This will perhaps pose the greatest challenge to stem cell researchers in this area.

## Conclusion

Research on stem cell therapy for AMD ranges from the level of molecular mechanics to clinical trials on human subjects (see Figure 2). The treatment model seems simple and supplants the damaged or dead RPE and photoreceptor cells with viable cells. Stem cell therapy provides the potential to supply functioning cells, but it is evident that it is far from simple to accomplish this and restore vision to AMD patients.

In preliminary human pilot projects, stem cell therapy has shown promise in restoring some visual function to AMD patients. But lingering questions remain to be answered. What type of stem cell is best suited to treating AMD patients? How much visual function can be restored? Are the visual acuity improvements sustainable? Will stem cell therapy prove safe and effective? How might stem cells be used to restore function to higher visual pathways?



**Figure 2** Milestones in the development of options for the management of AMD.

**Abbreviations:** AMD, age-related macular degeneration; ESCs, embryonic stem cells; IPE, iris pigmented epithelium; iPSCs, induced pluripotent stem cells; PSC, progenitor stem cell; RPE, retinal pigment epithelium.

Several phase I human trials to treat AMD with stem cells are poised to begin in the next several years. Results from these trials should add considerably to our knowledge about the above questions and hopefully point the way to a future treatment for AMD.

## Disclosure

The authors report no conflicts of interest in this work.

## References

1. Fine SL, Berger JW, Maguire MG, Ho AC. Age-related macular degeneration. *N Engl J Med*. 2000;342(7):483–492.
2. Fletcher EL. Mechanisms of photoreceptor death during retinal degeneration. *Optom Vis Sci*. 2010;87(4):269–275.
3. de Jong PT. Age-related macular degeneration. *N Engl J Med*. 2006;355(14):1474–1485.
4. Young RW, Bok D. Participation of the retinal pigment epithelium in the rod outer segment renewal process. *J Cell Biol*. 1969;42(2):392–403.
5. Abdelsalam A, Del Priore L, Zarbin MA. Drusen in age-related macular degeneration: pathogenesis, natural course, and laser photocoagulation-induced regression. *Surv Ophthalmol*. 1999;44(1):1–29.
6. Seddon JM, Ajani UA, Mitchell BD. Familial aggregation of age-related maculopathy. *Am J Ophthalmol*. 1997;123(2):199–206.
7. Weeks DE, Conley YP, Tsai HJ, et al. Age-related maculopathy: an expanded genome-wide scan with evidence of susceptibility loci within the 1q31 and 17q25 regions. *Am J Ophthalmol*. 2001;132(5):682–692.
8. Klein ML, Schultz DW, Edwards A, et al. Age-related macular degeneration. Clinical features in a large family and linkage to chromosome 1q. *Arch Ophthalmol*. 1998;116(8):1082–1088.
9. Crabb JW, Miyagi M, Gu X, et al. Drusen proteome analysis: an approach to the etiology of age-related macular degeneration. *Proc Natl Acad Sci U S A*. 2002;99(23):14682–14687.
10. Li M, Atmaca-Sonmez P, Othman M, et al. CFH haplotypes without the Y402H coding variant show strong association with susceptibility to age-related macular degeneration. *Nat Genet*. 2006;38(9):1049–1054.
11. Hackett SF, Friedman Z, Freund J, et al. A splice variant of *trkB* and brain-derived neurotrophic factor are co-expressed in retinal pigmented epithelial cells and promote differentiated characteristics. *Brain Res*. 1998;789(2):201–212.
12. Ishida K, Yoshimura N, Yoshida M, Honda Y, Murase K, Hayashi K. Expression of neurotrophic factors in cultured human retinal pigment epithelial cells. *Curr Eye Res*. 1997;16(2):96–101.
13. Dawson DW, Volpert OV, Gillis P, et al. Pigment epithelium-derived factor: a potent inhibitor of angiogenesis. *Science*. 1999;285(5425):245–248.
14. Blaauwgeers HG, Holtkamp GM, Rutten H, et al. Polarized vascular endothelial growth factor secretion by human retinal pigment epithelium and localization of vascular endothelial growth factor receptors on the inner choriocapillaris. Evidence for a trophic paracrine relation. *Am J Pathol*. 1999;155(2):421–428.
15. Thurston G. Role of Angiopoietins and Tie receptor tyrosine kinases in angiogenesis and lymphangiogenesis. *Cell Tissue Res*. 2003;314(1):61–68.
16. Witmer AN, Vrensen GF, Van Noorden CJ, Schlingemann RO. Vascular endothelial growth factors and angiogenesis in eye disease. *Prog Retin Eye Res*. 2003;22(1):1–29.
17. Penfold PL, Madigan MC, Gillies MC, Provis JM. Immunological and aetiological aspects of macular degeneration. *Prog Retin Eye Res*. 2001;20(3):385–414.
18. Bird AC. The Bowman lecture. Towards an understanding of age-related macular disease. *Eye (Lond)*. 2003;17(4):457–466.
19. Campochiaro PA, Soloway P, Ryan SJ, Miller JW. The pathogenesis of choroidal neovascularization in patients with age-related macular degeneration. *Mol Vis*. 1999;5:34.

20. Spilsbury K, Garrett KL, Shen WY, Constable IJ, Rakoczy PE. Overexpression of vascular endothelial growth factor (VEGF) in the retinal pigment epithelium leads to the development of choroidal neovascularization. *Am J Pathol.* 2000;157(1):135–144.
21. Sengupta N, Caballero S, Mames RN, Timmers AM, Saban D, Grant MB. Preventing stem cell incorporation into choroidal neovascularization by targeting homing and attachment factors. *Invest Ophthalmol Vis Sci.* 2005;46(1):343–348.
22. Sasahara M, Otani A, Yodoi Y, Yoshimura N. Circulating hematopoietic stem cells in patients with idiopathic choroidal neovascularization. *Invest ophthalmol Vis Sci.* 2009;50(4):1575–1579.
23. Lecomte J, Louis K, Detry B, et al. Bone marrow-derived mesenchymal cells and MMP13 contribute to experimental choroidal neovascularization. *Cell Mol Life Sci.* 2010 Aug 11. [Epub ahead of print].
24. Schlingemann RO. Role of growth factors and the wound healing response in age-related macular degeneration. *Graefes Arch Clin Exp Ophthalmol.* 2004;42(1):91–101.
25. Rosenfeld PJ, Brown DM, Heier JS, et al. Ranibizumab for neovascular age-related macular degeneration. *N Engl J Med.* 2006;355(14):1419–1431.
26. Coffey P. Interview: stemming vision loss with stem cells: seeing is believing. *Regen Med.* 2009;4(4):505–507.
27. Machemer R, Steinhorst UH. Retinal separation, retinotomy, and macular relocation: II. A surgical approach for age-related macular degeneration? *Graefes Arch Clin Exp Ophthalmol.* 1993;231(11):635–641.
28. Aisenbrey S, Lafaut BA, Szurman P, et al. Macular translocation with 360 degrees retinotomy for exudative age-related macular degeneration. *Arch Ophthalmol.* 2002;120(4):451–459.
29. Pertile G, Claes C. Macular translocation with 360 degree retinotomy for management of age-related macular degeneration with subfoveal choroidal neovascularization. *Am J Ophthalmol.* 2002;134(4):560–565.
30. Chen FK, Patel PJ, Uppal GS, Tufail A, Coffey PJ, Da Cruz L. Long-term outcomes following full macular translocation surgery in neovascular age-related macular degeneration. *Br J Ophthalmol.* 2010;94(10):1337–1343.
31. MacLaren RE, Bird AC, Sathia PJ, Aylward GW. Long-term results of submacular surgery combined with macular translocation of the retinal pigment epithelium in neovascular age-related macular degeneration. *Ophthalmology.* 2005;112(12):2081–2087.
32. Chen FK, Uppal GS, MacLaren RE, et al. Long-term visual and microperimetry outcomes following autologous retinal pigment epithelium choroid graft for neovascular age-related macular degeneration. *Clin Experiment Ophthalmol.* 2009;37(3):275–285.
33. Maaijwee K, Heimann H, Missotten T, Mulder P, Jousen A, van Meurs J. Retinal pigment epithelium and choroid translocation in patients with exudative age-related macular degeneration: long-term results. *Graefes Arch Clin Exp Ophthalmol.* 2007;245(11):1681–1689.
34. Binder S, Stolba U, Krebs I, et al. Transplantation of autologous retinal pigment epithelium in eyes with foveal neovascularization resulting from age-related macular degeneration: a pilot study. *Am J Ophthalmol.* 2002;133(2):215–225.
35. Van Meurs JC, Van Den Biesen PR. Autologous retinal pigment epithelium and choroid translocation in patients with exudative age-related macular degeneration: short-term follow-up. *Am J Ophthalmol.* 2003;136(4):688–695.
36. MacLaren RE, Uppal GS, Balaggan KS, et al. Autologous transplantation of the retinal pigment epithelium and choroid in the treatment of neovascular age-related macular degeneration. *Ophthalmology.* 2007;114(3):561–570.
37. Klimanskaya I. Retinal pigment epithelium. *Methods Enzymol.* 2006;418:169–194.
38. Thumann G, Bartz-Schmidt KU, El Bakri H, et al. Transplantation of autologous iris pigment epithelium to the subretinal space in rabbits. *Transplantation.* 1999;68(2):195–201.
39. Thumann G, Aisenbrey S, Schraermeyer U, et al. Transplantation of autologous iris pigment epithelium after removal of choroidal neovascular membranes. *Arch Ophthalmol.* 2000;118(10):1350–1355.
40. Tezel TH, Del Priore LV. Repopulation of different layers of host human Bruch's membrane by retinal pigment epithelial cell grafts. *Invest Ophthalmol Vis Sci.* 1999;40(3):767–774.
41. Kinouchi R, Takeda M, Yang L, et al. Robust neural integration from retinal transplants in mice deficient in GFAP and vimentin. *Nat Neurosci.* 2003;6(8):863–868.
42. Wang S, Villegas-Perez MP, Vidal-Sunz M, Lund RD. Progressive optic axon dystrophy and vascular changes in rd mice. *Invest Ophthalmol Vis Sci.* 2000;41(2):537–545.
43. Lund RD, Ono SJ, Keegan DJ, Lawrence JM. Retinal transplantation: progress and problems in clinical application. *J Leukoc Biol.* 2003;74(2):151–160.
44. Fricker RA, Carpenter MK, Winkler C, Greco C, Gates MA, Bjorklund A. Site-specific migration and neuronal differentiation of human neural progenitor cells after transplantation in the adult rat brain. *J Neurosci.* 1999;19(14):5990–6005.
45. Gage FH. Mammalian neural stem cells. *Science.* 2000;287(5457):1433–1438.
46. De Coppi P, Bartsch G Jr, Siddiqui MM, et al. Isolation of amniotic stem cell lines with potential for therapy. *Nat Biotechnol.* 2007;25(1):100–106.
47. Haruta M. Embryonic stem cells: potential source for ocular repair. *Semin Ophthalmol.* 2005;20(1):17–23.
48. Zhao X, Das AV, Bhattacharya S, et al. Derivation of neurons with functional properties from adult limbal epithelium: implications in autologous cell therapy for photoreceptor degeneration. *Stem Cells.* 2008;26(4):939–949.
49. Zhao X, Liu J, Ahmad I. Differentiation of embryonic stem cells to retinal cells in vitro. *Methods Mol Biol.* 2006;330:401–416.
50. Tropepe V, Coles BL, Chiasson BJ, et al. Retinal stem cells in the adult mammalian eye. *Science.* 2000;287(5460):2032–2036.
51. Klassen HJ, Ng TF, Kurimoto Y, et al. Multipotent retinal progenitors express developmental markers, differentiate into retinal neurons, and preserve light-mediated behavior. *Invest Ophthalmol Vis Sci.* 2004;45(11):4167–4172.
52. MacLaren RE, Pearson RA, MacNeil A, et al. Retinal repair by transplantation of photoreceptor precursors. *Nature.* 2006;444(7116):203–207.
53. Thanos S. Adult retinofugal axons regenerating through peripheral nerve grafts can restore the light-induced pupilloconstriction reflex. *Eur J Neurosci.* 1992;4(8):691–699.
54. Carter DA, Bray GM, Aguayo AJ. Long-term growth and remodeling of regenerated retino-collicular connections in adult hamsters. *J Neurosci.* 1994;14(2):590–598.
55. Carter DA, Bray GM, Aguayo AJ. Regenerated retinal ganglion cell axons can form well-differentiated synapses in the superior colliculus of adult hamsters. *J Neurosci.* 1989;9(11):4042–4050.
56. Keirstead SA, Rasminsky M, Fukuda Y, Carter DA, Aguayo AJ, Vidal-Sanz M. Electrophysiologic responses in hamster superior colliculus evoked by regenerating retinal axons. *Science.* 1989;246(4927):255–257.
57. Englund U, Fricker-Gates RA, Lundberg C, Bjorklund A, Victorin K. Transplantation of human neural progenitor cells into neonatal rat brain: extensive migration and differentiation with long-distance axonal projections. *Exp Neurol.* 2002;173(1):1–21.
58. Ooto S, Akagi T, Kageyama R, et al. Potential for neural regeneration after neurotoxic injury in the adult mammalian retina. *Proc Natl Acad Sci U S A.* 2004;101(37):13654–13659.
59. Fischer AJ, Reh TA. Müller glia are a potential source of neural regeneration in the postnatal chicken retina. *Nat Neurosci.* 2001;4(3):247–252.



60. Klassen H, Sakaguchi DS, Young MJ. Stem cells and retinal repair. *Prog Retin Eye Res.* 2004;23(2):149–181.
61. Lawrence JM, Singhal S, Bhatia B, et al. MIO-M1 cells and similar müller glial cell lines derived from adult human retina exhibit neural stem cell characteristics. *Stem Cells.* 2007;25(8):2033–2043.
62. Vossmerbaeumer U, Ohnesorge S, Kuehl S, et al. Retinal pigment epithelial phenotype induced in human adipose tissue-derived mesenchymal stromal cells. *Cytotherapy.* 2009;11(2):177–188.
63. Tomita M, Adachi Y, Yamada H, et al. Bone marrow-derived stem cells can differentiate into retinal cells in injured rat retina. *Stem Cells.* 2002;20(4):279–283.
64. Atmaca-Sonmez P, Li Y, Yamauchi Y, et al. Systemically transferred hematopoietic stem cells home to the subretinal space and express RPE-65 in a mouse model of retinal pigment epithelium damage. *Exp Eye Res.* 2006;83(5):1295–1302.
65. Kumar A, Pahwa VK, Tandon R, Kumar L, Mohanty S. Use of autologous bone marrow derived stem cells for rehabilitation of patients with dry age related macular degeneration and retinitis pigmentosa: phase-1 clinical trial. *Indian J Med Paediatr Oncol.* 2005;26 Suppl 3:12–14.
66. *Blind World Magazine.* Stem cell promise cure for vision loss. 2006 Apr 19. Available from: <http://www.home.earthlink.net/~blindworld2/MEDICAL/6-04-19-01.htm>. Accessed May 22, 2007.
67. *Blind World Magazine.* Retinitis pigmentosa (RP) patient gets stem cell implant. 2006 May 5. Available from: <http://www.home.earthlink.net/~blindworld2/MEIDCAL/6-05-05-02.htm>. Accessed May 22, 2007.
68. Trounson A. New perspectives in human stem cell therapeutic research. *BMC Med.* 2009;7:29.
69. Arnhold S, Klein H, Semkova I, Addicks K, Schraermeyer U. Neurally selected embryonic stem cells induce tumor formation after long-term survival following engraftment into the subretinal space. *Invest Ophthalmol Vis Sci.* 2004;45(12):4251–4255.
70. Lanza R, Rosenthal N. The stem cell challenge. *Sci Am.* 2004;290(6):92–99.
71. Schraermeyer U, Thumann G, Luther T, et al. Subretinally transplanted embryonic stem cells rescue photoreceptor cells from degeneration in the RCS rats. *Cell Transplant.* 2001;10(8):673–680.
72. Lamba DA, Karl MO, Ware CB, Reh TA. Efficient generation of retinal progenitor cells from human embryonic stem cells. *Proc Natl Acad Sci U S A.* 2006;103(34):12769–12774.
73. Coffey PJ, Girman S, Wang SM, et al. Long-term preservation of cortically dependent visual function in RCS rats by transplantation. *Nat Neurosci.* 2002;5(1):53–56.
74. Girman SV, Wang S, Lund RD. Cortical visual functions can be preserved by subretinal RPE cell grafting in RCS rats. *Vision Res.* 2003;43(17):1817–1827.
75. Lamba DA, Gust J, Rey TA. Transplantation of human embryonic stem cell-derived photoreceptors restores some visual function in Crx-deficient mice. *Cell Stem Cell.* 2009;4(1):73–79.
76. Corneo B, Temple S. Sense and serendipity aid RPE generation. *Cell Stem Cell.* 2009;5(4):347–348.
77. Lu B, Malcuit C, Wang S, et al. Long-term safety and function of RPE from human embryonic stem cells in preclinical models of macular degeneration. *Stem Cells.* 2009;27(9):2126–2135.
78. Idelson M, Alper R, Obolensky A, et al. Directed differentiation of human embryonic stem cells into functional retinal pigment epithelium cells. *Cell Stem Cell.* 2009;5(4):396–408.
79. Haruta M, Sasai Y, Kawasaki H, et al. In vitro and in vivo characterization of pigment epithelial cells differentiated from primate embryonic stem cells. *Invest Ophthalmol Vis Sci.* 2004;45(3):1020–1025.
80. Osakada F, Ikeda H, Mandai M, et al. Toward the generation of rod and cone photoreceptors from mouse, monkey and human embryonic stem cells. *Nat Biotechnol.* 2008;26(2):215–224.
81. Nistor G, Seiler MJ, Yan F, Ferguson D, Keirstead HS. Three-dimensional early retinal progenitor 3D tissue constructs derived from human embryonic stem cells. *J Neurosci Methods.* 2010;190(1):63–70.
82. Vugler A, Lawrence J, Walsh J, et al. Embryonic stem cells and retinal repair. *Mech Dev.* 2007;124(11–12):807–829.
83. Alge CS, Suppmann S, Priglinger SG, et al. Comparative proteome analysis of native differentiated and cultured human RPE cells. *Invest Ophthalmol Vis Sci.* 2003;44(8):3629–3641.
84. Polans AS, Witkowska D, Haley TL, Amundson D, Baizer L, Adamus G. Recoverin, a photoreceptor-specific calcium-binding protein, is expressed by the tumor of a patient with cancer-associated retinopathy. *Proc Natl Acad Sci U S A.* 1995;92(20):9176–9180.
85. Parameswaran S, Balasubramanian S, Babai N, et al. Induced pluripotent stem cells generate both retinal ganglion cells and photoreceptors: therapeutic implications in degenerative changes in glaucoma and age-related macular degeneration. *Stem Cells.* 2010;28(4):695–703.
86. *The London Project to Cure Blindness.* London: UCL Institute of Ophthalmology; 2007. Available from: <http://thelondonproject.org/aboutus/index.aspx?id=1258>. Accessed May 14, 2010.
87. Takahashi K, Yamanaka S. Induction of pluripotent stem cells from mouse embryonic and adult fibroblast cultures by defined factors. *Cell.* 2006;126(4):663–676.
88. Takahashi K, Tanabe K, Ohnuki M, et al. Induction of pluripotent stem cells from adult human fibroblasts by defined factors. *Cell.* 2007;131(5):861–872.
89. Yu J, Vodyanik MA, Smuga-Otto K, et al. Induced pluripotent stem cell lines derived from human somatic cells. *Science.* 2007;318(5858):1917–1920.
90. Buchholz DE, Hikita ST, Rowland TJ, et al. Derivation of functional retinal pigmented epithelium from induced pluripotent stem cells. *Stem Cells.* 2009;27(10):2427–2434.
91. Carr AJ, Vugler AA, Hikita ST, et al. Protective effects of human iPS-derived retinal pigment epithelium cell transplantation in the retinal dystrophic rat. *PLoS One.* 2009;4(12):e8152.
92. Okita K, Nakagawa M, Hyenjong H, Ichisaka T, Yamanaka S. Generation of mouse induced pluripotent stem cells without viral vectors. *Science.* 2008;322(5903):949–953.
93. Yu J, Hu K, Smuga-Otto K, et al. Human induced pluripotent stem cells free of vector and transgene sequences. *Science.* 2009;324(5928):797–801.
94. Lyssiotis CA, Foreman RK, Staerk J, et al. Reprogramming of murine fibroblasts to induced pluripotent stem cells with chemical complementation of Klf4. *Proc Natl Acad Sci U S A.* 2009;106(22):8912–8917.
95. Kim D, Kim CH, Moon JI, et al. Generation of human induced pluripotent stem cells by direct delivery of reprogramming proteins. *Cell Stem Cell.* 2009;4(6):472–476.
96. Zhou H, Wu S, Joo JY, et al. Generation of induced pluripotent stem cells using recombinant proteins. *Cell Stem Cell.* 2009;4(5):381–384.
97. Liao JL, Yu J, Huang K, et al. Molecular signature of primary retinal pigment epithelium and stem-cell-derived RPE cells. *Hum Mol Genet.* 2010;19(21):4229–4238.
98. Mooney I, LaMotte J. A review of the potential to restore vision with stem cells. *Clin Exp Optom.* 2008;91(1):78–84.
99. Takahashi M, Palmer TD, Takahashi J, Gage FH. Widespread integration and survival of adult-derived neural progenitor cells in the developing optic retina. *Mol Cell Neurosci.* 1998;12(6):340–348.
100. Stuermer CA, Bastmeyer M. The retinal axon's pathfinding to the optic disk. *Prog Neurobiol.* 2000;62(2):197–214.
101. MacLaren RE. Regeneration and transplantation of the optic nerve: developing a clinical strategy. *Br J Ophthalmol.* 1998;82(5):577–583.
102. Weibel D, Cadelli D, Schwab ME. Regeneration of lesioned rat optic nerve fibers is improved after neutralization of myelin-associated neurite growth inhibitors. *Brain Res.* 1994;642(1–2):259–266.

103. Schwab ME, Caroni P. Oligodendrocytes and CNS myelin are nonpermissive substrates for neurite growth and fibroblast spreading in vitro. *J Neurosci*. 1998;8(1):2381–2393.
104. Thanos S, Naskar R, Heiduschka P. Regenerating ganglion cell axons in the adult rat establish retinofugal topography and restore visual function. *Exp Brain Res*. 1997;114(3):483–491.

### Stem Cells and Cloning: Advances and Applications

Dovepress

#### Publish your work in this journal

Stem Cells and Cloning: Advances and Applications is an international, peer-reviewed, open access journal. Areas of interest in stem cell research include: Embryonic cell stems; Adult stem cells; Blastocysts; Cordblood stem cells; Stem cell transformation and culture; Therapeutic cloning; Umbilical cord blood and bone marrow cells; Laboratory,

animal and human therapeutic studies; Philosophical and ethical issues related to stem cell research. This journal is indexed on CAS. The manuscript management system is completely online and includes a quick and fair peer-review system. Visit <http://www.dovepress.com/testimonials.php> to read real quotes from published authors.

Submit your manuscript here: <http://www.dovepress.com/stem-cells-and-cloning-advances-and-applications-journal>