

Available online at [www.sciencedirect.com](http://www.sciencedirect.com)

ScienceDirect

Biomedical Journal

journal homepage: [www.elsevier.com/locate/bj](http://www.elsevier.com/locate/bj)

## Brief Communication

# Management of intracranial vertebral artery stenosis with ipsilateral vertebral artery hypoplasia and contralateral vertebral artery occlusion via type 2 proatlantal intersegmental artery

Chuan-Min Lin<sup>a,1</sup>, Chien-Hung Chang<sup>a</sup>, Ho-Fai Wong<sup>b,c,\*</sup><sup>a</sup> Department of Neurology, Chang Gung Memorial Hospital at Linkou, Taoyuan, Taiwan<sup>b</sup> Department of Medical Imaging and Intervention, Chang Gung Memorial Hospital at Linkou, Taoyuan, Taiwan<sup>c</sup> College of Medicine, Chang Gung University, Taoyuan, Taiwan

## ARTICLE INFO

## Article history:

Received 8 August 2019

Accepted 10 February 2020

Available online 12 June 2021

## Keywords:

Proatlantal intersegmental artery  
Intracranial atherosclerotic disease  
Intracranial stent

## ABSTRACT

**Background:** Proatlantal intersegmental artery (PIA) is a rare primitive carotid-basilar anastomosis. PIA may accompany with ipsilateral or bilateral vertebral arteries (VAs) agenesis. Here, we presented the case with intracranial VA stenosis supplying via PIA and demonstrated how we evaluated and managed.

**Methods:** Dual antiplatelet therapy and adequate hydration were given for three weeks for intracranial atherosclerotic disease (ICAD). We arranged magnetic resonance (MR) vessel wall imaging to survey both intracranial VAs. Intracranial right VA stenosis supplying via PIA with ipsilateral VA hypoplasia and contralateral intracranial VA occlusion caused multiple posterior circulation infarcts. We performed angioplasty and intracranial stenting for ICAD at the right VA V4 segment via PIA.

**Results:** National Institute of Health Stroke Scale (NIHSS) and modified Rankin scale (mRS) got improved at discharge and ten months.

**Conclusions:** This case is the first report for ICAD management via PIA. A persistent type 2 PIA is essential for supplying posterior circulation.

In the early embryonic stage, four types of carotid-vertebrobasilar anastomosis were described: proatlantal intersegmental, hypoglossal, otic, and trigeminal arteries. These anastomoses may regress within a week with the

development of the vertebrobasilar system [1]. The otic artery never persists, and other arteries may rarely persist [2]. The trigeminal artery is the most common, with an incidence between 0.10% and 0.50%. The primitive hypoglossal artery is the

\* Corresponding author. Department of Medical imaging and intervention, Chang Gung Memorial Hospital at Linkou, 5, Fusing St., Gueishan, Taoyuan 333, Taiwan.

E-mail address: [hfwong@cgmh.org.tw](mailto:hfwong@cgmh.org.tw) (H.-F. Wong).

Peer review under responsibility of Chang Gung University.

<sup>1</sup> First author: Chuan-Min Lin, MD.

<https://doi.org/10.1016/j.bj.2020.02.004>

2319-4170/© 2020 Chang Gung University. Publishing services by Elsevier B.V. This is an open access article under the CC BY-NC-ND license (<http://creativecommons.org/licenses/by-nc-nd/4.0/>).

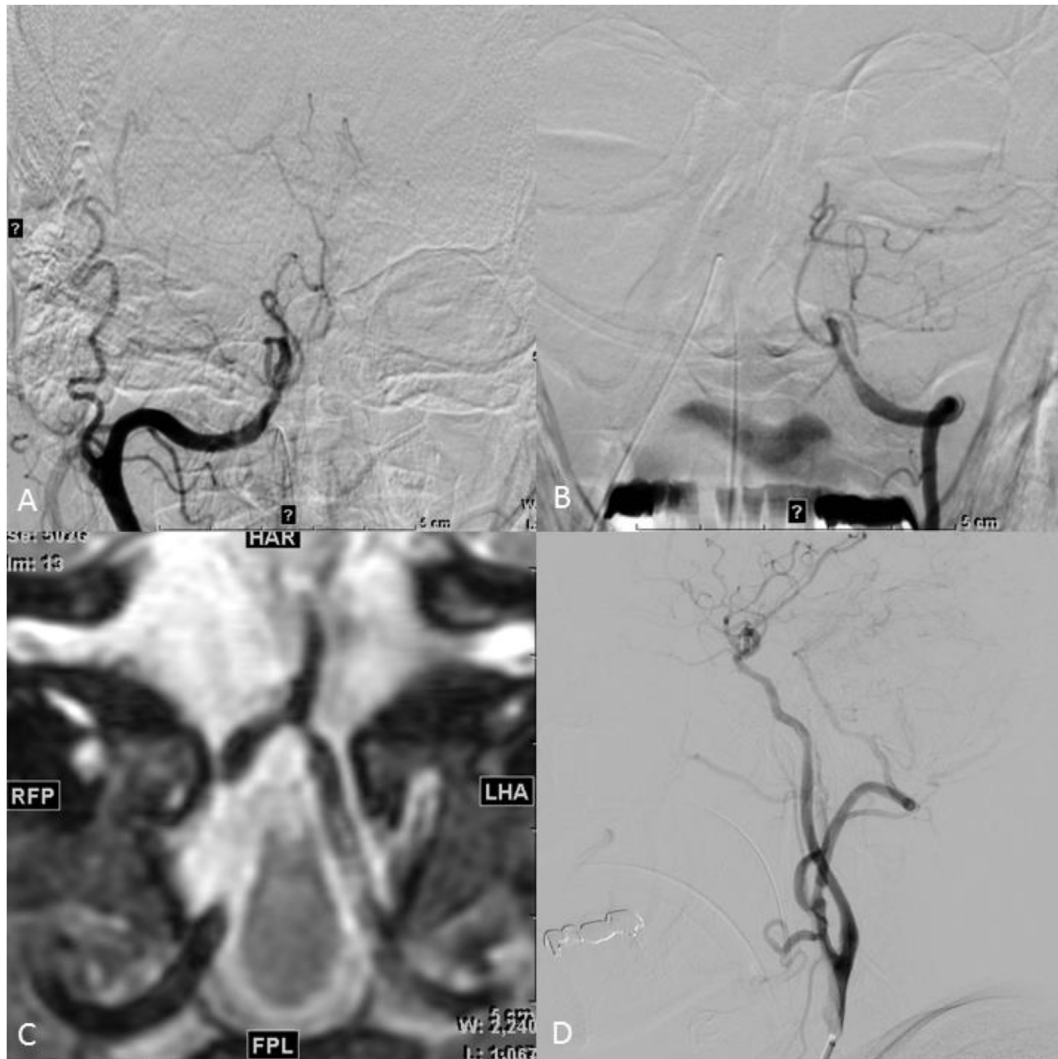


Fig. 1 (A) Anteroposterior right carotid angiogram shows Type II PIA and tight stenosis at intradural right vertebral artery. (B) Anteroposterior left vertebral angiogram shows complete occlusion of intradural left vertebral artery. (C) HRMR vessel wall image (3D T2WI COR reformation) obtained three weeks after initial stroke elucidate smaller lumen at left vertebral basilar artery junction and thrombosis within left vertebral artery resultant complete occlusion. (D) Lateral projection angiogram of right carotid artery shows recanalization of PIA after angioplasty and Wingspan system.

second most common with an incidence of about 0.10%, and the third most common is the proatlantal intersegmental artery (PIA) seen in 0.02% [3].

The PIA persists until the vertebral arteries (VAs) develop and connect with the basilar artery (BA) [4]. The persistence of PIA is often associated with hypoplasia or agenesis of VAs [5]. Two types of PIAs have been described. Type 1 PIA takes origin from the caudal internal carotid artery (ICA) and ascends to the level of the occipitoatlantal space where it is connected to the VA. Type 2 PIA rises from the external carotid artery (ECA) and joins the ipsilateral VA below the first cervical vertebra [1,3]. Both types of PIA continues to the V3 segment of the VA and enters the posterior fossa via the foramen magnum [2]. PIA can be found in cases with transient ischemic attack (TIA), vertebrobasilar insufficiency (VBI), or even cerebral hemispheric or posterior circulation infarction. Here, we presented

a case with intracranial VA stenosis with PIA supply, to demonstrate how we evaluate and manage for intracranial atherosclerotic disease (ICAD).

### Clinical report

A 61-year-old male heavy smoker had a history of uncontrolled hypertension. He presented with mild left limb weakness and slurred speech on May 8th; initially, he did not seek medical attention. He was found drowsy, four limb weakness, and speech disturbance in the morning on May 12th. Magnetic resonance imaging (MRI) revealed multiple infarctions over pons, bilateral occipital lobes, and cerebellums. MR angiography showed near-total occlusion at bilateral intradural VAs. His left limb weakness progressed to dense hemiplegia on May

**Table 1 Management for PIA with carotid artery stenosis.**

Author (publication year)	Clinical presentation	PIA	Management
Quriel et al. (1988)	Left transient retinal ischemia	Type 1	Endarterectomy
Bour et al. (1991)	Right ICA bruit	Type 1	Angioplasty
Kolbinger et al. (1993)	Right cerebellar and left dorsal thalamus infarction	Type 1	Endarterectomy
Türler A and Erasmi H. (1996)	Infarction	Type 1	Endarterectomy
Mori et al. (1998)	Minor infarction, recurrent syncope	Type 2	Angioplasty
Woodcock et al. (2001)	Left bifurcation stenosis	Type 1	Endarterectomy
Grego et al. (2004)	Transient ischemic attack, syncope, vertigo	Type 1	Endarterectomy
Morales et al. (2006)	Transient ischemic attack (Dizziness and right upper limb weakness)	Type 1	Stent
Schoof et al. (2007)	Left posterior borderzone infarction	Type 1	Endarterectomy
Berger et al. (2011)	Brainstem, right occipital, left MCA infarction	Type 2	Endarterectomy
Ohhashi and Inoya (2013)	Infarction	NA	Stent
Abla AA et al. (2014)	Right PCA infarction with left ECA dissection and left subclavian artery stenosis	Type 2	Stent
Buljan et al. (2015)	Right hemisphere infarction two times	Type 1	Endarterectomy
Liechty JM et al. (2016)	Transient ischemic attack (Right hand weak, left amaurosis fugax)	Type 2	Endarterectomy
Diab and Gan (2017)	Transient ischemic attack (Left side weakness)	Type 1	Endarterectomy
Ma et al. (2019)	Vertigo (transient ischemic attack)	Mixed PIA	Stent
This case (2019)	Pons, bilateral occipital lobes, and cerebellums infarction	Type 2	Wingspan stent

Abbreviations: PIA: Proatlantal intersegmental artery; ICA: internal carotid artery; ECA: external carotid artery.

14th despite aspirin use. Enoxaparin was given for stroke in progression after excluding hemorrhage. However, the weakness of his limbs continued to deteriorate. He was then transferred to this hospital.

The National Institute of Health Stroke Scale (NIHSS) was 22, and the modified Rankin scale (mRS) was 5. Computed tomography angiography (CTA) showed severe stenosis at right intradural VA, right intradural VA supplied by right ECA, hypoplasia of right extracranial VA (V1–V2), and hypoplasia of left posterior cerebral artery (PCA). We prescribed dual antiplatelet therapy (aspirin and clopidogrel) and adequate hydration for ICAD. Transcranial Doppler and carotid sonography performed on May 17th revealed decreased flows at bilateral extracranial VAs. His clinical condition stabilized with aggressive medical therapy. Digital subtraction angiography (DSA) on May 21st showed right type 2 PIA supplying the right VA V3–V4 segment with hypoplasia of extracranial segment, tight stenosis at right VA V4 short segment, complete occlusion of the left VA V4 segment, and bilateral small posterior communicating arteries (Fig. 1A and B). Brain MR vessel wall imaging revealed right intracranial VA tight stenosis, left VA complete occlusion with an enhanced plaque and smaller lumen at left VA (Fig. 1C).

We introduced a tri-axial guiding catheter system to the right type 2 PIA from right femoral arterial access. The diameter of the VA before the stenosis was 3.5 mm (mm). After angioplasty with Gateway balloon 3\*15 mm under 6 atm pressure, Wingspan (Stryker Neurovascular, Cork, Ireland) stent 4\*20 mm was deployed in the right V4 segment and across the stenotic segment (Fig. 1D). Right stenotic VA diameter got increased from 1.2 mm to 2.4 mm. The patient's muscle power improved after aggressive medical treatment and Wingspan (Stryker Neurovascular, Cork, Ireland) placement. His muscle power improved at discharge. At follow-up ten months later, the NIHSS improved from 22 to 13, and the mRS improved to 3.

## Discussion

Type 1 PIA with ipsilateral common carotid artery (CCA) bifurcation or ICA ulcerative plaque can lead to vertebrobasilar TIA symptoms with vertigo, diplopia, nausea/vomiting, and disequilibrium [6]. Bahsi et al. reported that PIA originated from ICA and top of basilar syndrome in 1993 [7]. Ikeda et al. reported a case of type 1 PIA with ICA stenosis presenting with paramedian pons infarction [8]. ICA occlusion with ipsilateral type 1 PIA can cause watershed infarction or posterior circulation infarction [9,10]. Tanaka et al. described a case of type 1 PIA and ipsilateral trigeminal artery presented with left MCA occlusion and infarction [11].

Liechty et al. described a case of left ICA severe stenosis with type 2 PIA presenting with transient right-hand weakness and left amaurosis fugax [12]. ICA stenosis with ipsilateral type 2 PIA can cause MCA territory infarction [13]. Ishiguro et al. suggested a steal phenomenon from anterior circulation to posterior circulation via type 2 PIA that caused left MCA infarction [14]. Berger et al. described that left ICA 80% stenosis, left type 2 PIA with tight stenosis at the origin, and both VAs agenesis leads to simultaneous hemispheric and vertebrobasilar ischemic cerebrovascular disease. She was treated by ICA endarterectomy and CCA to PIA bypass [15] [Table 1].

When performing endarterectomy, understanding the PIA anatomy would decrease the risk of ischemia. Woodcock et al. described a bilateral type 1 PIA case that received endarterectomy for left severe ICA stenosis [16]. Kolbinger et al. presented a case of occlusion of right ICA, proximal to an ipsilateral type 1 PIA, and both absent proximal VAs and posterior communicating arteries. The flow from left ICA retrograde filled right ICA via the anterior communicating artery. Type 1 PIA then supplied the flow from the right ICA to the BA. Right proximal ICA endarterectomy was then performed for posterior cerebral hypoperfusion [10].

Angioplasty in a case of asymptomatic ICA tight stenosis and ipsilateral type 1 PIA was reported by Bour et al., in 1991 [17]. Mori et al. presented a case of recurrent syncope and minor infarction who received kissing balloon angioplasty for right bifurcation stenosis with type 2 PIA [18]. Carotid stent with a filter protection device for stenosis at the origin of the PIA was reported by Ohhashi and Inoya in 2013 [19]. Abla et al. described a case of left subclavian stenosis proximal to the VA, occluded right VA, and right dissecting ECA with type 2 PIA presenting with right PCA infarction. The retrograde flow resolved after stenting at the left subclavian artery and left ECA [20].

In our case, severe stenosis at right intracranial VA, occlusion of left intracranial VA, hypoplasia of right extracranial VA, and hypoplasia of left PCA caused multiple posterior circulation infarctions. After aggressive medication management, our case did not improve clinically. MR vessel wall imaging revealed left VA complete occlusion with the enhanced plaque and smaller lumen at left VA at vertebral basilar artery junction. The information on the left VA complicated plaque and the smaller lumen is important for intracranial stent evaluation in ICAD. We used Wingspan (Stryker Neurovascular, Cork, Ireland) stent system to treat the tight stenosis at the intradural right vertebral artery. We opted to access the intracranial VA stenosis via type 2 PIA instead of penetrating through the occluded left VA. Attempt to open up the occluded left VA is a choice, but with a smaller diameter, higher probability of failure, and a higher risk of distal embolization.

## Conclusion

In summary, this is the first case report to demonstrate how to evaluate and manage before performing an intervention for ICAD via PIA. The timing of intervention could be clinical deterioration or post aggressive medical therapy. MR vessel wall imaging provided valuable information about complicated plaque and vessel lumen size of the left VA. In our case, a persistent type 2 PIA is essential for supplying posterior circulation.

## Ethical approval

This study was approved by the Chang Gung Foundation Institutional Review Board with the IRB number 201900258B0.

## Conflicts of interest

The authors declare that they have no conflict of interest.

## REFERENCES

- [1] Okahara M, Kiyosue H, Mori H, Tanoue S, Sainou M, Nagatomi H. Anatomic variations of the cerebral arteries and their embryology: a pictorial review. *Eur Radiol* 2002;12:2548–61.
- [2] Uchino A. Carotid-vertebrobasilar anastomosis: magnetic resonance and computed tomographic angiographic demonstration. *Jpn J Radiol* 2019;37:565–78.
- [3] Tubbs RS, Verma K, Riech S, Mortazavi MM, Shoja MM, Loukas M, et al. Persistent fetal intracranial arteries: a comprehensive review of anatomical and clinical significance. *J Neurosurg* 2011;114:1127–34.
- [4] Gumus T, Onal B, Ilgit ET. Bilateral persistence of type 1 proatlantal arteries: report of a case and review of the literature. *AJNR Am J Neuroradiol* 2004;25:1622–4.
- [5] Luh GY, Dean BL, Tomsick TA, Wallace RC. The persistent fetal carotid-vertebrobasilar anastomoses. *AJR Am J Roentgenol* 1999;172:1427–32.
- [6] Yu W, Feng Z, Zhao C, Fu C. Proatlantal intersegmental artery with internal carotid artery stenosis. *Neurology* 2017;89:104–5.
- [7] Bahsi YZ, Uysal H, Peker S, Yurdakul M. Persistent primitive proatlantal intersegmental artery (proatlantal artery I) results in 'top of the basilar' syndrome. *Stroke* 1993;24:2114–7.
- [8] Ikeda M, Okamoto K, Hirai S, Amari M, Takatama M. [A case of pontine infarction with persistent primitive proatlantal artery]. *Rinsho Shinkeigaku* 1993;33:976–9.
- [9] Schoof J, Skalej M, Halloul Z, Wunderlich MT. Carotid endarterectomy in a patient with persistent proatlantal artery. *Cerebrovasc Dis* 2007;23:458–9.
- [10] Kolbinger R, Heindel W, Pawlik G, Erasmi-Korber H. Right proatlantal artery type I, right internal carotid occlusion, and left internal carotid stenosis: case report and review of the literature. *J Neurol Sci* 1993;117:232–9.
- [11] Tanaka Y, Hara H, Momose G, Kobayashi S, Kobayashi S, Sugita K. Proatlantal intersegmental artery and trigeminal artery associated with an aneurysm. Case report. *J Neurosurg* 1983;59:520–3.
- [12] Liechty JM, Weddle RJ, Shutze WP, Smith BL. Occurrence of a type 2 proatlantal intersegmental artery during carotid endarterectomy for symptomatic stenosis. *J Vasc Surg* 2016;64:807–8.
- [13] Hackett ER, Wilson CB. Congenital external carotid-vertebral anastomosis. A case report. *Am J Roentgenol Radium Ther Nucl Med* 1968;104:86–9.
- [14] Ishiguro M, Sohma T, Tsuchita H, Kitami K, Hotta H, Kurokawa Y. [Persistent primitive proatlantal intersegmental artery (PPPAA) presenting with cerebral infarction]. *No Shinkei Geka* 1991;19:559–63.
- [15] Berger L, Gouicem D, Lebied el D, Felisaz A, Coffin O, Maiza D. Internal carotid and ipsilateral type II proatlantal artery stenoses causing simultaneous hemispheric and vertebrobasilar transient ischemia. *J Vasc Surg* 2011;53:475–7.
- [16] Woodcock RJ, Cloft HJ, Dion JE. Bilateral type 1 proatlantal arteries with absence of vertebral arteries. *AJNR Am J Neuroradiol* 2001;22:418–20.
- [17] Bour P, Bracard S, Frisch N, Frisch R, Fieve G. Persistent proatlantal artery associated with carotid artery stenosis treatment by percutaneous transluminal balloon angioplasty. *Ann Vasc Surg* 1991;5:38–40.
- [18] Mori T, Fukuoka M, Kazita K, Mori K. Percutaneous transluminal angioplasty using kissing balloon technique for carotid bifurcation stenoses coupled with the proatlantal intersegmental artery: a case report. *Minim Invasive Neurosurg* 1998;41:214–6.
- [19] Ohhashi G, Inoya H. [Stenting for cerebral infarction due to stenosis of a persistent primitive proatlantal artery: a case report]. *No Shinkei Geka* 2013;41:59–64.
- [20] Abla AA, Kan P, Jahshan S, Dumont TM, Levy EI, Siddiqui AH. External carotid dissection and external carotid proatlantal intersegmental artery with subclavian steal prompting external carotid and subclavian artery stenting. *J Neuroimaging* 2014;24:399–403.

[1] Okahara M, Kiyosue H, Mori H, Tanoue S, Sainou M, Nagatomi H. Anatomic variations of the cerebral arteries and