

Probable Donor-Derived Human Adenovirus Type 34 Infection in 2 Kidney Transplant Recipients From the Same Donor

Matthew A. Pettengill,^{1,2} Tara M. Babu,¹ Paritosh Prasad,¹ Sally Chuang,¹ Michael G. Drage,¹ Marilyn Menegus,^{1,†} Daryl M. Lamson,³ Xiaoyan Lu,⁴ Dean Erdman,⁴ and Nicole Pecora¹

¹University of Rochester Medical Center, Rochester, New York; ²Thomas Jefferson University, Philadelphia, Pennsylvania; ³Wadsworth Center, New York State Department of Health, Albany, New York; ⁴US Centers for Disease Control and Prevention, Atlanta, Georgia

Human adenovirus type 34 (HAdV-34) infection is a recognized cause of transplant-associated hemorrhagic cystitis and, in rare cases, tubulointerstitial nephritis. The source of such infections is often difficult to assess, that is, whether acquired as a primary infection, exposure to a pathogen in the transplanted organ, or reactivation of an endogenous latent infection. We present here 2 cases of likely transplant-acquired HAdV-34 infection from the same organ donor, manifesting as tubulointerstitial nephritis in 1.

Keywords. adenovirus; HAdV-34; kidney transplant; tubulointerstitial nephritis.

Transplant recipients and other immunocompromised patients are particularly susceptible to severe disease or death due to infection with human adenoviruses (HAdVs), which can affect almost any organ system [1–3]. In stem cell transplant patients, severe lymphopenia is associated with disseminated HAdV infection [3, 4]. Kidney transplant recipients may develop serious infections, commonly manifesting as hemorrhagic cystitis, though tubulointerstitial nephritis has rarely been reported [5–9]. Patients develop clinical disease 1 to 3 months after transplant [10]. The most common types of HAdV associated with serious renal infections are from species B (types 7, 11, 34, and 35) [1, 4, 8, 11, 12]. Although establishing an etiology of these infections is difficult, their propensity to occur not long after the time of transplant and to affect the kidneys and urinary

tract has raised the possibility of a donor-derived infection. This report describes clinical and laboratory findings from a donor and 2 kidney transplant recipients who evidenced transmission of infection with HAdV-34 after transplantation.

DONOR

The donor was a 31-year-old male with a history of a seizure disorder who presented to an outside hospital after a seizure and head trauma complicated by cardiac and respiratory arrest. No respiratory illness was noted; however, a computed tomography (CT) head scan did demonstrate mucosal thickening in the ethmoid sinuses and air fluid levels in the sphenoid sinuses, which could suggest recent viral infection. Chest x-ray (CXR) on admission noted patchy opacity in the right upper lobe; this was improved on repeat CXR on hospital day 2, and CT of the chest on hospital day 5 demonstrated only atelectasis. His kidneys were transplanted into 2 patients in 1 medical center reported on here. The heart, lungs, and liver were all available from this donor for transplant. The liver was rejected on biopsy for unknown reasons. The heart and lungs were transplanted at other medical centers and, at the date of writing, recipient patients were doing well without evidence of adenovirus infection. Note that, to the best of our knowledge, serologic tests have not been performed on these patients. In addition, the center that transplanted this donor's lungs routinely screens for adenovirus species B/E and C when they perform pre- and post-transplant bronchoscopies (3 of the latter) as part of their routine care (HAdV-34 is a serotype of adenovirus B). No specimens tested positive for adenovirus. Both centers (heart and lungs) were notified of the potential adenovirus transmission and continue to monitor those patients.

PATIENT 1

Patient 1 was a 36-year-old male with end-stage renal disease due to sclerosing glomerulonephritis, for which he underwent an uncomplicated deceased donor kidney transplant (donor CMV IgG negative, recipient CMV IgG positive). He received antithymocyte globulin induction. One month after his transplant, he presented to the hospital with 3 days of allograft tenderness, hematuria, fever, dysuria, and urinary retention. At that time, he was on valganciclovir, trimethoprim/sulfamethoxazole, and fluconazole prophylaxis. His immunosuppressive regimen consisted of tacrolimus 6 mg daily, mycophenolate mofetil 1000 mg twice daily, and prednisone 20 mg daily.

On admission, the patient had a low-grade fever and was hemodynamically stable. His physical exam demonstrated significant tenderness to palpation over his allograft. Admission laboratory values revealed a white blood cell count (WBC)

Received 18 September 2018; editorial decision 18 December 2018; accepted 21 December 2018.

[†]Deceased

Correspondence: N. Pecora, MD, PhD, University of Rochester Medical Center, 601 Elmwood Avenue, Box 626, Rochester, NY 14642 (nicole_pecora@urmc.rochester.edu).

Open Forum Infectious Diseases®

© The Author(s) 2019. Published by Oxford University Press on behalf of Infectious Diseases Society of America. This is an Open Access article distributed under the terms of the Creative Commons Attribution-NonCommercial-NoDerivs licence (<http://creativecommons.org/licenses/by-nc-nd/4.0/>), which permits non-commercial reproduction and distribution of the work, in any medium, provided the original work is not altered or transformed in any way, and that the work is properly cited. For commercial re-use, please contact permissions@oup.com DOI: 10.1093/ofid/ofy354

of 5.9 THOU/uL with lymphopenia, a hemoglobin (Hgb) of 10.7 g/dL, and a platelet count of 166 THOU/uL. His creatinine (Cr) was elevated at 1.69 mg/dL (1.15 mg/dL 1 month prior, the lowest since transplant). His liver function tests were normal. Urine studies showed 660 red blood cells (RBCs) and 61 WBCs. Computerized tomography abdominal imaging on admission showed perinephric stranding consistent with allograft pyelonephritis.

The patient was started on empiric antibiotic therapy for presumed bacterial allograft pyelonephritis while the microbiologic testing was pending. He initially improved; however, on day 3 of hospitalization, he had worsening allograft tenderness and high-grade fevers up to 40°C. Repeat CT abdominal imaging showed progressive perinephric stranding and allograft edema. Urine and blood cultures were negative. Serum was submitted for quantitative HAdV nucleic acid testing (~5 weeks post-transplantation), which was positive at a level of 6×10^6 HAdV genome copies/mL. HAdV molecular typing was performed by polymerase chain reaction (PCR) amplification and sequence analysis of a partial region of the HAdV hexon gene and was determined to be HAdV-34 (nucleotide sequence similarity score = 99% compared with reference sequence KF268196) [13].

Core biopsy of the allograft kidney revealed sharply demarcated zones of tubular necrosis in a pauci-inflammatory background. High-powered examination revealed residual tubular epithelium with textureless “smudge” chromatin and intraluminal necrotic debris. The histologic findings were characteristic of HAdV infection and were confirmed by immunohistochemistry (Figure 1A and B). The patient was treated with cidofovir (dosed at 1 mg/kg 3 times per week) and probenecid, and immunosuppression was concurrently decreased. With treatment, the adenovirus viremia cleared up in 29 days (Table 1). Cidofovir therapy was well tolerated for 5 weeks and was stopped when his viral load became undetectable. His Cr at treatment completion was 1.5 mg/dL, and no protein was isolated from his urine. The patient had rapid resolution of his symptoms and improvement in renal function.

PATIENT 2

The recipient of the donor’s other kidney was a 40-year-old male with end-stage renal disease secondary to type 1 diabetes mellitus. He received basiliximab induction (CMV IgG donor negative, CMV IgG recipient negative). His clinical course was complicated by grade 1A cellular rejection, for which he received antithymocyte globulin therapy. He presented to the hospital 3 months after transplantation with 2 days of fever, chills, and malaise. On admission, he was on acyclovir, dapsone, and fluconazole prophylaxis. His immunosuppression at that time included tacrolimus 5 mg daily, mycophenolate mofetil 750 mg twice daily, and prednisone 10 mg daily.

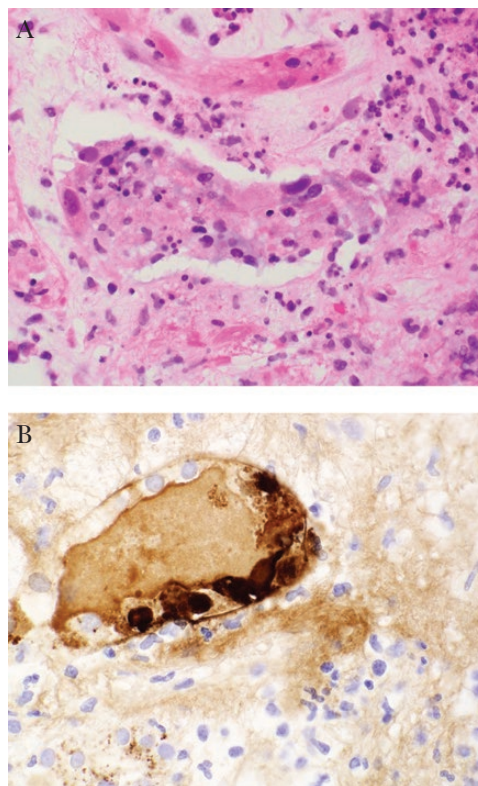


Figure 1. Patient 1 kidney biopsy sections stained with hematoxylin and eosin (A) or adenovirus immunohistochemistry (B).

On admission, the patient had fever, rigors, and tachycardia. His physical exam was unremarkable. Admission laboratory tests revealed a WBC of 11.7 THOU/uL with 22% bandemia, a Hgb of 7.1 g/dL, and a platelet count of 249 THOU/uL. His Cr was elevated from baseline to 1.99 mg/dL. His liver function tests were normal. Urine studies showed 9 WBCs and <1 RBC. Blood cultures and urine culture were positive for *Escherichia coli*. He improved with targeted antibiotic therapy for urosepsis and concurrent decrease in immunosuppression. Given the known history of Patient 1, a serum specimen from Patient 2 was submitted to a commercial laboratory for HAdV nucleic acid testing, which was negative.

HADV SERUM NEUTRALIZATION TEST RESULTS

Using pre- and post-transplant serum specimens, it was possible to evaluate the timing of Patient 1’s exposure to HAdV-34. Serum HAdV-34–neutralizing antibodies were measured against the HAdV-34 prototype strain Compton using a laboratory-developed test based on a standard serum neutralization protocol [14] that had been modified for this study to use another cell type (A549). Neutralizing antibodies were considered positive with titers of 10 or greater. Serum from Patient 1 was negative for neutralizing antibodies both 6 months and 1 day before transplant (Table 1). However, by 4 weeks after

Table 1. Human Adenovirus PCR and Serum Neutralization Test Results of Transplant Donor and Recipients

Time Frame	Donor		Recipient (Patient 1) ^a		Recipient (Patient 2)	
	HAdV PCR, GC/mL	HAdV-34 Nt, Titer	HAdV PCR, GC/mL	HAdV-34 Nt, Titer	HAdV PCR, GC/mL	HAdV-34 Nt, Titer
Pretransplant	Neg	Pos (320)	N/A	Neg (<10)	N/A	Neg (<10)
Post-transplant						
Week 1	N/A	N/A	Neg	N/A	N/A	N/A
Week 2	N/A	N/A	N/A	N/A	N/A	N/A
Week 3	N/A	N/A	Pos (4.3×10 ⁴)	N/A	N/A	N/A
Week 4	N/A	N/A	Pos (2.8×10 ⁵)	Pos (160)	N/A	N/A
Week 5	N/A	N/A	Pos (6.0×10 ⁶)	N/A	N/A	N/A
Week 6	N/A	N/A	Pos (4.6×10 ⁶)	N/A	N/A	N/A
Week 7	N/A	N/A	Pos (7.6×10 ³)	Pos (640)	N/A	N/A
Week 8	N/A	N/A	Pos (2.8×10 ³)	N/A	N/A	Pos (80)
Week 9	N/A	N/A	Pos (236)	Pos (1280)	N/A	N/A
Week 10	N/A	N/A	Neg	N/A	N/A	N/A
Week 11	N/A	N/A	Neg	N/A	N/A	N/A
Week 12	N/A	N/A	N/A	N/A	Neg	N/A

Abbreviations: GC/mL, genome copies per milliliter; N/A, not available; Neg, negative; Nt, serum neutralization titer; Pos, positive.

^aTransplant recipient 1 was symptomatic during weeks 5–7 and received cidofovir treatment during weeks 7–10.

transplant, he seroconverted to HAdV-34, consistent with the PCR findings and indicating that his HAdV-34 infection occurred at the time of transplant, either through the donated kidney or as a de novo infection.

As serum was available from both the donor and the second kidney recipient pre- and post-transplant, it was possible to differentiate between these possibilities. Donor serum collected 1 day before transplant was positive for neutralizing antibodies (titer 320) to HAdV-34, indicating prior HAdV-34 infection. Serum collected 1 day before transplant from Patient 2 was seronegative. However, a serum specimen from Patient 2 collected 8 weeks after transplant was positive, indicating seroconversion to HAdV-34 (Table 1). These findings indicate that both Patient 1 and Patient 2 were infected with HAdV-34 either at the time of transplant via a donor organ-derived infection or shortly thereafter (independently, as a de novo infection). Serum from the donor was submitted for quantitative HAdV nucleic acid testing but was negative, indicating that the donor was not HAdV viremic at the time of organ harvest, although latent infection and viremia below the limit of detection could not be ruled out. Tissue was not available to assess the presence of virus in the transplanted organs.

DISCUSSION

HAdV-34 was first isolated in 1972 from a 17-year-old male patient who developed fever after receiving a kidney transplant [15]. Multiple reports followed of systemic HAdV-34 infections among renal transplant recipients and other immunocompromised patients [8, 16, 17], as well as rare reports of acute conjunctivitis [18, 19] in immunocompetent persons. To our knowledge, there are no reports that directly document HAdV latency in the kidneys. Latency has been documented in lymphatic tissues of

the oro-gastrointestinal tract for other hAdV types, and hAdV-34 infection with persistent shedding in the urine of recipients of kidney transplants has been widely documented. Case reports of hAdV-34 infection in patients receiving donor kidneys have led to speculation that the virus was latent in donor kidneys, becoming active in the recipient as a consequence of immunological impairment. In preparation for organ transplantation, donors are tested for a variety of infectious diseases (such as hepatitis B, hepatitis C, and HIV) that could be transmitted to recipients. However, HAdV testing is not required by the Organ Procurement and Transplantation Network (OPTN) [20]. The source of an HAdV infection in a transplant patient can be difficult to determine, and de novo infection or reactivation of latent disease may be the most likely explanations. In this instance, 1 of the 2 kidney recipients (Patient 1) had disease suggestive of HAdV infection within a few weeks after transplantation, which prompted testing that confirmed HAdV tubulointerstitial nephritis and disseminated viremia. The United Network for Organ Sharing (UNOS) was contacted, and the health status of the other 2 recipients was ascertained from the respective transplant centers. In addition to the kidneys, the donor heart and lungs were also transplanted to separate patients, neither of whom developed symptomatic HAdV-related disease or required HAdV diagnostic testing. The confirmed adenovirus infection in the first patient was reported to the OPTN at the time it was diagnosed. The second kidney recipient at our institution did not have symptoms specifically suggestive of HAdV infection but was tested for HAdV due to the known positive results of Patient 1. Retrospective testing found that the deceased organ donor had serological evidence of prior exposure to HAdV-34.

As both kidney recipients were initially seronegative for HAdV-34 before transplant and then seroconverted a few

weeks later, a possible route of HAdV-34 transmission was from the donor to both organ recipients. As the absence of specimens positive for HAdV from both the donor and Patient 2 makes it impossible to strengthen the connection with sequencing data, it does remain possible that both recipients contracted HAdV-34 infection independent from the environment. Although to our knowledge there are limited data available on hAdV-34 seroprevalence, seropositivity to hAdV-35, a closely related virus that shows a similar clinical/epidemiological profile to hAdV-34, was found to be uncommon in an international study [21]. At least 1 epidemiological survey has indicated that HAdV-34 is uncommon in the general population [22], making the possibility of acquisition from the environment somewhat less likely. The kidney recipient patients did not share a room during their hospital stay, but they were seen at separate times by some common health care providers. No other cases of HAdV disease were diagnosed in other patients in the hospital wards occupied by the kidney transplant patients described here in the 6 months preceding or in the 6 months after their hospital stay. Interestingly, the clinical courses of the 2 patients were quite different, which may reflect differences in infectious doses from each kidney or differences in host resistance to infection. It is also possible that differing cross-protection from prior infections with other adenovirus serotypes could have contributed to the difference in clinical courses between recipients, but this is poorly understood for adenoviruses.

Although donor-derived HAdV infections are rare, testing for HAdV should be considered in transplant recipients with culture-negative pyelonephritis and those who demonstrate hemorrhagic cystitis or tubulointerstitial nephritis within a few months of transplant.

Acknowledgments

The authors would like to acknowledge the Wadsworth Center's Applied Genomics Technologies Core for performing the dideoxy sequencing and Eileen Schneider (Centers for Disease Control and Prevention) for helpful discussion and feedback.

Author contributions. Marilyn Menegus initiated this study, and all authors agree that she met the definition of authorship. Marilyn passed away on March 20, 2017, and to the best of our knowledge, she did not have any conflicts of interest related to this work, but due to her passing before the study completion, a conflict of interest (COI) form for Marilyn is not available. Marilyn was a remarkable and productive educator, mentor, and scientist with a special interest in clinical virology.

Disclaimer. The findings and conclusions in this report are those of the authors and do not necessarily represent the official position of the Centers for Disease Control and Prevention.

Financial support. Nicole Pecora is supported by funding through the Emerging Infections Program, sponsored by Health Research Incorporated. No other authors have funding to disclose.

Potential conflicts of interest. All authors: no reported conflicts of interest. All authors have submitted the ICMJE Form for Disclosure of Potential Conflicts of Interest. Conflicts that the editors consider relevant to the content of the manuscript have been disclosed.

References

1. Hierholzer JC. Adenoviruses in the immunocompromised host. *Clin Microbiol Rev* **1992**; 5:262–74.
2. Ison MG. Adenovirus infections in transplant recipients. *Clin Infect Dis* **2006**; 43:331–9.
3. Lion T. Adenovirus infections in immunocompetent and immunocompromised patients. *Clin Microbiol Rev* **2014**; 27:441–62.
4. Chakrabarti S, Mautner V, Osman H, et al. Adenovirus infections following allogeneic stem cell transplantation: incidence and outcome in relation to graft manipulation, immunosuppression, and immune recovery. *Blood* **2002**; 100:1619–27.
5. Barraclough K, Oliver K, Playford EG, et al. Life-threatening adenovirus infection in a kidney transplant recipient. *NDT Plus* **2009**; 2:250–3.
6. Kim SS, Hicks J, Goldstein SL. Adenovirus pyelonephritis in a pediatric renal transplant patient. *Pediatr Nephrol* **2003**; 18:457–61.
7. Tomoe H, Onitsuka S, Nishino S, et al. Adenovirus-induced kidney graft pyelonephritis following renal transplantation. *Hinyokika Kyo* **1994**; 40:1005–8.
8. Keller EW, Rubin RH, Black PH, et al. Isolation of adenovirus type 34 from a renal transplant recipient with interstitial pneumonia. *Transplantation* **1977**; 23:188–91.
9. Dawood US, Nelson A, Wu D, et al. Disseminated adenovirus infection in kidney transplant recipient. *Nephrology (Carlton)* **2014**; 19(Suppl 1):10–3.
10. Watcharananan SP, Avery R, Ingsathit A, et al. Adenovirus disease after kidney transplantation: course of infection and outcome in relation to blood viral load and immune recovery. *Am J Transplant* **2011**; 11:1308–14.
11. Florescu MC, Miles CD, Florescu DF. What do we know about adenovirus in renal transplantation? *Nephrol Dial Transplant* **2013**; 28:2003–10.
12. Rady K, Walters G, Brown M, Talaulikar G. Allograft adenovirus nephritis. *Clin Kidney J* **2014**; 7:289–92.
13. Okada M, Ogawa T, Kubonoya H, et al. Detection and sequence-based typing of human adenoviruses using sensitive universal primer sets for the hexon gene. *Arch Virol* **2007**; 152:1–9.
14. Hierholzer JC, Bingham PG. Vero microcultures for adenovirus neutralization tests. *J Clin Microbiol* **1978**; 7:499–506.
15. Hierholzer JC, Atuk NO, Gwaltney JM Jr. New human adenovirus isolated from a renal transplant recipient: description and characterization of candidate adenovirus type 34. *J Clin Microbiol* **1975**; 1:366–76.
16. Mori T, Aisa Y, Shimizu T, et al. Hemorrhagic cystitis caused by adenovirus type 34 after allogeneic bone marrow transplantation. *Transplantation* **2005**; 79:624.
17. de Jong PJ, Valderrama G, Spigland I, Horwitz MS. Adenovirus isolates from urine of patients with acquired immunodeficiency syndrome. *Lancet* **1983**; 1:1293–6.
18. Uchio E, Matsuura N, Takeuchi S, et al. Acute follicular conjunctivitis caused by adenovirus type 34. *Am J Ophthalmol* **1999**; 128:680–6.
19. Saitoh-Inagawa W, Tanaka K, Uchio E, et al. Genome typing of adenovirus type 34 isolated in two cases of conjunctivitis in Sapporo, Japan. *J Clin Microbiol* **2001**; 39:4187–9.
20. Fischer SA, Avery RK; AST Infectious Disease Community of Practice. Screening of donor and recipient prior to solid organ transplantation. *Am J Transplant* **2009**; 9(Suppl 4):S7–18.
21. Barouch DH, Kik SV, Weverling GJ, et al. International seroepidemiology of adenovirus serotypes 5, 26, 35, and 48 in pediatric and adult populations. *Vaccine* **2011**; 29:5203–9.
22. Gray GC, McCarthy T, Lebeck MG, et al. Genotype prevalence and risk factors for severe clinical adenovirus infection, United States 2004–2006. *Clin Infect Dis* **2007**; 45:1120–31.