

# Urticaria multiforme-like eruption due to a novel agent elexacaftor/tezacaftor/ivacaftor in a pediatric patient with cystic fibrosis



Rebecca H. Goldberg, BS,<sup>a</sup> Natalie H. Matthews, MD, MPhil,<sup>b</sup> Alexandra C. Hristov, MD,<sup>b,c</sup> and Frank Wang, MD<sup>b</sup>  
Ann Arbor, Michigan

**Key words:** cystic fibrosis; drug rash; elexacaftor; ivacaftor; morbilliform drug eruption; tezacaftor; urticaria; urticaria multiforme.

## INTRODUCTION

Urticaria multiforme (UM), a morphologic subtype of urticaria also known as acute urticarial hypersensitivity syndrome and acute annular urticaria, is a benign hypersensitivity reaction most frequently observed in young children.<sup>1</sup> It is characterized by acute onset of small, blanchable urticarial wheals coalescing into large annular or arcuate plaques with ecchymotic centers and polycyclic borders.<sup>1,2</sup> Individual lesions tend to regress within 24 hours, and the entire rash usually resolves within 10 days without dyspigmentation. Symptoms include fever and edema of the hands, feet, and face. Although the etiology of UM remains unknown, likely triggers include viral and bacterial infections, antibiotics, and antipyretics.<sup>3</sup> Here, we report a case of a UM-like eruption in a pediatric patient with cystic fibrosis (CF) who was taking elexacaftor/tezacaftor/ivacaftor (ELX/TEZ/IVA) (Trikafta, Vertex Pharmaceuticals).

## CASE REPORT

A 12-year-old boy with a history of CF presented with 3 days of a pruritic, nonpainful rash. He had started ELX/TEZ/IVA 7 days prior to rash onset. The rash initially appeared on his neck before spreading to his head, trunk, bilateral upper and lower extremities, palms, soles, and genitals. The patient's parents reported migration of individual lesions. Two nights before presentation, he had a fever of 38.9 °C which resolved with ibuprofen. He denied chills, night

### Abbreviations used:

CF:	cystic fibrosis
ELX/TEZ/IVA:	elexacaftor/tezacaftor/ivacaftor
EM:	erythema multiforme
UM:	urticaria multiforme

sweats, weight change, myalgias, arthralgias, or genitourinary, gastrointestinal, or pulmonary symptoms. Except for ELX/TEZ/IVA, he had not started or changed any medications, and he was not taking supplements.

On physical examination, his rash consisted of pink-to-erythematous, edematous, round papules coalescing into plaques (Fig 1, A to C). Many papules on the extremities demonstrated central duskiness, imparting a targetoid appearance. He had erythema of his cheeks. There was no edema of the face, hands, or feet, no lymphadenopathy, and no involvement of the ocular, oral, or genital mucosae. His conjunctivae were mildly injected. The patient was afebrile, with stable vital signs. The differential diagnosis included UM-like drug eruption, morbilliform drug eruption, serum sickness-like reaction, drug reaction with eosinophilia and systemic symptoms, and erythema multiforme (EM).

A 4-mm punch biopsy taken from a lesion on the left thigh demonstrated mild epidermal spongiosis, mild vacuolar alteration of basal keratinocytes, and a superficial and deep perivascular lymphocytic infiltrate with numerous eosinophils (Fig 2). Twort and

From the University of Michigan Medical School, Ann Arbor<sup>a</sup>; Department of Dermatology, University of Michigan Medical School, Ann Arbor<sup>b</sup>; and Department of Pathology, University of Michigan Medical School, Ann Arbor.<sup>c</sup>

Funding sources: None.

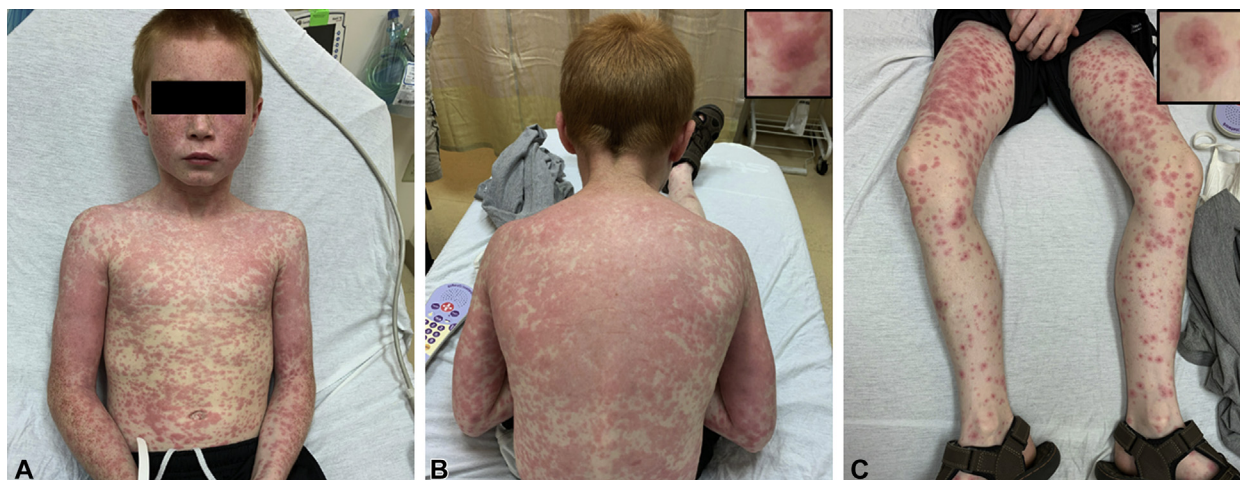IRB approval status: Not applicable.

Correspondence to: Rebecca H. Goldberg, BS, University of Michigan Medical School, 1301 Catherine St, Ann Arbor, MI 48109. E-mail: [beckgold@umich.edu](mailto:beckgold@umich.edu).

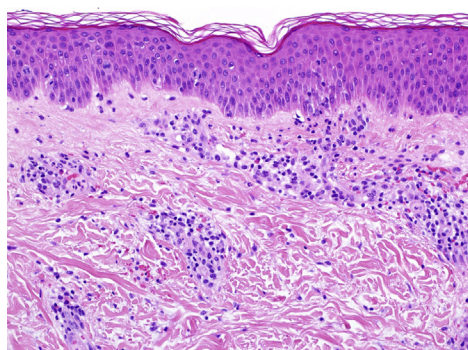
JAAD Case Reports 2021;18:71-3.  
2352-5126

© 2021 by the American Academy of Dermatology, Inc. Published by Elsevier, Inc. This is an open access article under the CC BY-NC-ND license (<http://creativecommons.org/licenses/by-nc-nd/4.0/>).

<https://doi.org/10.1016/j.jidcr.2021.10.018>



**Fig 1.** Clinical appearance of urticaria multiforme-like drug eruption in our patient, who was taking the novel cystic fibrosis agent elexacaftor/tezacaftor/ivacaftor. Numerous pink-to-erythematous, edematous papules and plaques on (A) the chest, trunk, and bilateral anterior upper extremities; (B) the back and bilateral posterior upper extremities, which displayed numerous targetoid lesions (*inset*); and (C) the bilateral anterior lower extremities, which also displayed numerous targetoid lesions (*inset*).



**Fig 2.** Histopathologic findings in our patient. A 4-mm punch biopsy from a representative lesion of the left thigh showed mild epidermal spongiosis, mild vacuolar alteration of basal keratinocytes, and a superficial and deep perivascular lymphoeosinophilic infiltrate, consistent with urticaria multiforme-like drug eruption.

periodic acid–Schiff for fungus stains were negative. Laboratory tests revealed a leukocytosis of  $16.8 \text{ K}/\mu\text{L}$  with 4.3% eosinophils. A complete metabolic panel revealed no transaminitis. Rapid COVID-19 polymerase chain reaction testing was negative.

Based on the clinical and histologic features, a diagnosis of UM-like drug eruption due to ELX/TEZ/IVA was made. The drug was discontinued. The patient was treated with oral prednisone (2 mg/kg daily, tapered over 4 weeks) and oral diphenhydramine. Laboratory abnormalities resolved within 1 day, and the rash and pruritus resolved over several days without recurrence.

## DISCUSSION

We present the case of a pediatric patient with CF who presented with a UM-like drug eruption after starting ELX/TEZ/IVA. This drug was approved by the US Food and Drug Administration in 2019 for patients with CF 12 years of age and older. It is the first triple combination therapy for patients with the F508del mutation, which is present in up to 90% of patients with CF.<sup>4</sup> As this drug becomes more widely used, it is important to recognize its cutaneous side effects to avoid misdiagnosis and to determine whether continuing the medication is essential.

Our patient's findings were most consistent with a UM-like eruption, although the differential diagnosis included morbilliform drug eruption, serum sickness-like reaction, drug reaction with eosinophilia and systemic symptoms, and EM. These dermatoses can be dangerous and often mimic UM and UM-like drug eruption, demonstrating the importance of avoiding misdiagnosis. The exact etiology of UM remains unknown, but possible triggering factors include infections (mycoplasma, adenovirus, streptococcus, herpesvirus, Epstein-Barr virus), antibiotics (amoxicillin, cephalosporins, macrolides), and antipyretics (aspirin, acetaminophen).<sup>1,3</sup> Our patient was not exposed to such factors but presented with lesions that were migratory and targetoid, particularly on the extremities. We considered that the rash was “UM-like” and less likely to be conventional UM. Given the temporal relationship, we suspected that our patient's rash was secondary to the initiation of ELX/TEZ/IVA

7 days prior to rash onset. In addition, considering the morbilliform/urticarial nature of the lesions on the trunk, the possibility of a morbilliform drug eruption with UM-like features cannot be excluded.

Because of the urticarial, polycyclic, and ecchymotic appearance of the rash, we considered serum sickness-like reaction, which classically presents with pruritic, fixed, urticarial, dusky macules, papules, and/or plaques, with edema of the extremities, malaise, arthralgia, and fever. Because many of these findings were absent in our patient, this entity was less favored. Although our patient had very mild eosinophilia, drug reaction with eosinophilia and systemic symptoms was also less likely because of the absence of facial edema, lymphadenopathy, and systemic symptoms, as well as the short interval between medication initiation and rash onset. EM classically presents with mucosal and acral involvement, and characteristic target/iris lesions with sharp margins and 3 concentric color zones. Our patient was nontoxic-appearing and did not exhibit the classic target lesions of EM or mucosal involvement. His systemic findings were limited to a brief low-grade fever, which we felt was more consistent with UM-like drug eruption.

There is limited literature regarding cutaneous adverse events of ELX/TEZ/IVA. Phase 3 clinical trials report “rash” in 9% to 11% of participants, although further details on these reactions have not been reported.<sup>5</sup> A similar UM-like eruption, which developed 2 weeks after initiation of ELX/TEZ/IVA, was reported in a 24-year-old woman with CF. She presented with thin, erythematous, annular, urticarial plaques with dusky-gray centers. Unlike our patient, she reported edema of her hands, feet, and face.<sup>6</sup> Similar to our patient, histopathologic examination showed a hypersensitivity dermatitis with urticarial features.

Management of UM is primarily symptomatic, since it is self-resolving. First-line management includes systemic H1 antihistamines, with systemic corticosteroids in refractory cases.<sup>2</sup> Management of UM-like eruption is similar, with additional consideration given to discontinuing the offending medication. Given the therapeutic benefit of ELX/TEZ/IVA and its increasing use, it is imperative to recognize adverse cutaneous reactions that may necessitate discontinuation of the drug. Future study is needed to determine the safety and tolerability of continuation of ELX/TEZ/IVA in patients with various exanthems, including UM-like reaction.

#### Conflicts of interest

None disclosed.

#### REFERENCES

1. Sempau L, Martín-Sáez E, Gutiérrez-Rodríguez C, Gutiérrez-Ortega MC. Urticaria multiforme: a report of 5 cases and a review of the literature. *Actas Dermosifiliogr*. 2016;107(1):e1-e5.
2. Emer JJ, Bernardo SG, Kovalerchik O, Ahmad M. Urticaria multiforme. *J Clin Aesthet Dermatol*. 2013;6(3):34-39.
3. Shah KN, Honig PJ, Yan AC. “Urticaria multiforme”: a case series and review of acute annular urticarial hypersensitivity syndromes in children. *Pediatrics*. 2007;119(5):e1177-e1183.
4. US Food and Drug Administration. FDA approves new breakthrough therapy for cystic fibrosis [press release]. October 21, 2019. Accessed October 25, 2021. <https://www.fda.gov/news-events/press-announcements/fda-approves-new-breakthrough-therapy-cystic-fibrosis>
5. Griese M, Costa S, Linnemann RW, et al. Safety and efficacy of elexacaftor/tezacaftor/ivacaftor for 24 weeks or longer in people with cystic fibrosis and one or more F508del alleles: interim results of an open-label phase 3 clinical trial. *Am J Respir Crit Care Med*. 2021;203(3):381-385.
6. Stashower J, Carr P, Miller V, Zlotoff B. Novel reaction to new cystic fibrosis medication Trikafta. *Clin Case Rep*. 2021;9(5):e04116.