

CO₂ vs. air insufflation in endoscopic ultrasonography: a prospective study



Authors

Marta Serrani¹, Andrea Lisotti¹, Alessia Spada², Sandro Sferrazza¹, Claudio Calvanese¹, Pietro Fusaroli¹

Institutions

- 1 Department of Medical and Surgical Science, U.O.C. of Gastroenterology, University of Bologna, Hospital of Imola, Italy
- 2 Department of Economics, University of Foggia, Foggia, Italy

submitted 24.7.2018

accepted after revision 26.10.2018

Bibliography

DOI <https://doi.org/10.1055/a-0809-4912> |

Endoscopy International Open 2019; 07: E317–E321

© Georg Thieme Verlag KG Stuttgart · New York

ISSN 2364-3722

Corresponding author

Marta Serrani, S. Orsola Hospital, University of Bologna – Department of Medical and Surgical Science, U.O.C. of Gastroenterology, University of Bologna, Hospital of Imola, via Montericco 4 Imola Bologna 40026Italy

Fax: +0542 662409

tarma80@gmail.com

ABSTRACT

Background and study aims Carbon dioxide (CO₂) is being increasingly used for insufflation during endoscopy for safety and better tolerance. The role of CO₂ during endoscopic ultrasonography (EUS) has not been studied

yet. Our main aim was to compare the effects of CO₂ vs. air insufflation on abdominal discomfort in patients undergoing EUS. Our secondary outcomes were to ascertain the effects of CO₂ insufflation on image quality/visual artifacts and on the amount of sedation.

Patients and methods This was a prospective, controlled, single-blind, observational study. Abdominal discomfort was assessed before diagnostic EUS, and 1 and 3 hours post-procedure and recorded as a visual analogue scale. Image quality was also recorded as a 4-point scale from optimal to poor at four different scanning sites (esophagus, stomach, duodenal bulb and second portion).

Results A total of 198 patients were enrolled. We observed that CO₂ resulted in less abdominal discomfort than air insufflation that was statistically significant at 3 hours ($P=0.048$) but not at 1 hour after EUS ($P=0.112$), probably due to the ongoing effects of sedation at the latter stage. On the other hand, no differences were found in the dose of sedation administered in the two groups. Image quality was significantly better in the CO₂ group compared to the air group at all four different scanning sites ($P<0.01$). Similarly, CO₂ correlated with less visual artifacts and need of suction ($P<0.01$).

Conclusions Similarly to previous findings with other endoscopic procedures, EUS was associated with improved scores for abdominal discomfort with CO₂ rather than air insufflation. Moreover, overall EUS image quality was improved using CO₂ insufflation. Future studies are warranted to ascertain whether CO₂ insufflation should be regarded as the standard of care for diagnostic EUS.

Introduction

Digestive endoscopy procedures require gas insufflation to allow the progression of the endoscope and proper examination of the mucosa.

Room air is the most common gas used in standard endoscopic settings, however, subsequent distension of the bowel often causes abdominal discomfort because of air slow re-absorption [1]. Therefore, employment of carbon dioxide (CO₂) instead of air is increasing. In fact, it is well established that CO₂ causes less abdominal discomfort because it is absorbed

faster (160 times) than air from the gut and then expired through the lungs [2]. Several studies demonstrated that CO₂ insufflation induces less abdominal discomfort than air during colonoscopy, endoscopic retrograde cholangiopancreatography (ERCP) and enteroscopy [3–6]

Endoscopic ultrasonography (EUS) matches endoscopic and ultrasound view to investigate pancreatic and biliary diseases, stage gastrointestinal tumors and diagnose submucosal lesions and lymph nodes [7–11].

Instrumentation consists of a dedicated echoendoscope with a high-frequency ultrasound transducer on its tip. Gas

pockets may persist between the probe and the target organ as a consequence of insufflation; thereby acoustic coupling is impaired, generating visual artifacts that can hamper diagnostic accuracy. As a consequence, endosonographers need to activate multiple suctions in attempt to reduce bowel gas throughout the entire procedure.

We hypothesized that CO₂ insufflation could influence not only patients' discomfort but also the quality of EUS images. To our knowledge, the outcomes of CO₂ insufflation in EUS have not been evaluated in a clinical study so far. Therefore, to date, no recommendation is available regarding the choice of gas insufflation for EUS (air or CO₂).

The main aim of this study was to compare the effects of CO₂ vs. air insufflation on abdominal discomfort in patients undergoing EUS. The secondary outcomes were to ascertain the effects of CO₂ on dose of sedation, EUS image quality and presence of visual gas artifacts.

Patients and methods

This was a prospective, controlled, single-blind, observational study. Consecutive patients who were scheduled for EUS in our center from April 2016 to January 2017 were eligible. The trial was approved by the local ethic committee and registered at www.clinicaltrials.gov (NCT02773563).

Exclusion criteria were:

- age < 18 or > 85
- pregnancy/lactation
- non-feasibility of EUS
- patient's unwillingness to participate

Patients enrolled were allocated to either of two groups:

- group A (air insufflation)
- group B (CO₂ insufflation)

Two endoscopic rooms were available for EUS during the study period, of which one was equipped with a CO₂ delivery system and another one with a standard air-insufflation system. At the time of reservation, patients were randomly allocated in one of these two rooms according to the availability of booking slots.

All the procedures were performed by one of three experienced operators (PF, AL, MS). Before starting enrollment, all endoscopists met to come to agreement related to the study standards of care and definitions. Moreover, at the end of each examination, all the images were reviewed collectively by the three endosonographers in order to share quality evaluation by consensus and not only based on the judgment of a single operator.

Procedures and data collection

All the procedures were performed either with a radial (GF-UE160, Olympus Medical Systems Corp., Tokyo, Japan) or with a curvilinear-array echoendoscope (GF-UTC180, Olympus Medical Systems Corp., Tokyo, Japan). Study data were directly collected by the endosonographers and recorded in a case report form. Abdominal discomfort intensity was assessed before the procedure, and 1 and 3 hours post-procedure and recorded as a visual analogue scale (VAS) ranging from 0 to 10 (0: no pain, 10:

maximum pain). All the patients were blinded as to which gas was used. The endosonographers showed a printed numeric scale to the patients before and after examinations (at 1 and 3 hours post-procedure). By doing so, a verbal explanation was also provided to the patients during each administration of the VAS.

Image quality assessment was performed at four standard stations (second part of the duodenum, duodenal bulb, stomach, and esophagus) and recorded as optimal, suboptimal, poor, and impossible. Optimal was defined as a clean EUS view of the target organ with adequate resolution; suboptimal was defined as a minimal loss in image resolution, but still adequate for diagnosis; poor was defined as a significant loss in image quality barely adequate for diagnosis; impossible was defined as inadequate for diagnosis. Visual artifacts were defined as white convex shadows between the probe and the target organ impairing acoustic coupling. Need for suction was considered as the frequency of gas aspiration from the lumen in order to remove the gas pockets. Dosage and type of sedation were also recorded.

CO₂ delivery system

The CO₂ regulator available in our Unit was the Olympus UCR, connected by tubing to the CO₂ central supply of our hospital. The gas flow setting was 1.5 L/min.

Statistical analysis

Continuous variables were reported as mean ± standard deviation or median (range). Categorical variables were reported as number (percentage). The Mann-Whitney test was used for comparison of continuous variables. Fisher's exact test or Chi-square test was used for the comparison of categorical variables. To compare the effects of CO₂ vs. air insufflation in patients undergoing EUS, the subjects were randomized to treatment, and the two-sided two-sample Mann Whitney test was used. To achieve 90% power of test, at significance levels of 0.01, the sample size required for each patient group was calculated to be 94 units; we hypothesized up to 10% of incomplete examinations, therefore we planned to enroll 200 patients. All the analyses were performed using STATA version 14.0 software (Stata Corporation, College Station, Texas).

Results

From April 2016 to January 2017, 200 patients were enrolled. Two patients were excluded because of the premature interruption of the procedure, one due to esophageal stenosis, one due to status post-gastric surgery that was previously unknown.

The two groups were well balanced with regard to demographic characteristics (► **Table 1**). Ninety-four patients were enrolled in the CO₂ group and 104 patients were enrolled in the air group. Indications and results of EUS are also reported in ► **Table 1**. There were no statistically significant differences between group A and B concerning the duration of exams.

► **Table 1** Baseline characteristics of the study population.

Patient characteristics	Total (no. 198)
Age (years)	64 (21–90)
Gender (male)	97 (48.9%)
EUS indication	
Biliary tree	72 (36.4%)
Pancreatic parenchyma	86 (43.4%)
Gastric cancer	30 (15.2%)
Subepithelial tumor	10 (5.1%)
Fine needle aspiration	49 (24.7%)
Echoendoscope type	
Curvilinear array	113 (57.1%)
Radial scanning	85 (42.9%)
EUS, endoscopic ultrasound; CO ₂ , carbon dioxide; SD, standard deviation.	

Abdominal discomfort

There was no statistically significant difference between the two groups concerning abdominal discomfort before EUS (1.04 ± 1.82 vs. 1.03 ± 1.83). We observed a trend to a reduced discomfort in the CO₂ group at 1 hour after the procedure compared to the air group (1.17 ± 1.68 vs. 1.54 ± 1.77 ; $P=0.112$). Interestingly, a significant reduction in abdominal discomfort in the CO₂ group compared to the air group was seen at 3 hours after EUS (0.88 ± 1.57 vs. 1.17 ± 1.54 ; $P=0.048$) (► **Table 2**).

Image quality and visual artifacts

Analysis of our data showed that the quality of EUS images was significantly superior in each single station (second part of the duodenum, duodenal bulb, stomach, esophagus) with CO₂ insufflation ($P<0.001$) compared to air insufflation (► **Fig. 1**, ► **Fig. 2**). There was also a statistically significant difference with respect to visual artifacts and need of gas suction, with CO₂ correlating with less artifacts and requiring less gas aspiration from the lumen of the gut ($P<0.001$).

► **Table 2** Comparison between CO₂ and air insufflation.

	CO ₂ Group (mean ± SD)	Air Group (mean ± SD)	P value
Abdominal discomfort – VAS 0 – 10¹			
Before EUS	1.04 ± 1.82	1.03 ± 1.83	0.956
1 hour after EUS	1.17 ± 1.68	1.54 ± 1.77	0.112
3 hours after EUS	0.88 ± 1.57	1.17 ± 1.54	0.048
Image quality assessment²			
Duodenum – second portion	1.31 ± 0.55	1.72 ± 0.68	<0.0001
Duodenum – bulb	1.30 ± 0.55	1.74 ± 0.69	<0.0001
Stomach – celiac trunk	1.42 ± 0.60	1.87 ± 0.75	<0.0001
Esophagus – mediastinum	1.53 ± 0.69	1.98 ± 0.82	0.0001
Visual artifacts³	0.54 ± 0.67	0.96 ± 0.67	<0.0001
Need of suction⁴	0.15 ± 0.36	0.48 ± 0.50	<0.0001
EUS duration (minutes)	22.56 ± 10.87	21.18 ± 10.93	0.310
Sedation			
Fentanyl dose (mcg)	107.98 ± 23.54	107.69 ± 25.85	0.868
Midazolam dose (mg)	4.26 ± 1.74	4.13 ± 1.82	0.723

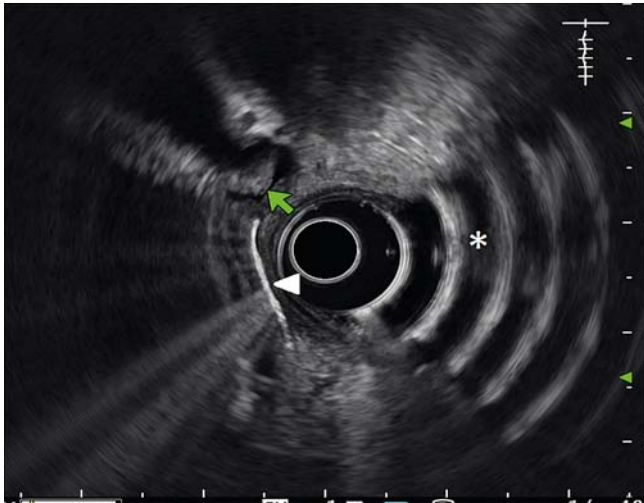P value from the comparison between CO₂ vs. air group, made with the Mann-Whitney test.

¹ Abdominal discomfort was recorded as a Visual Analogue Scale ranging from 0 (no pain) to 10 (maximum pain).

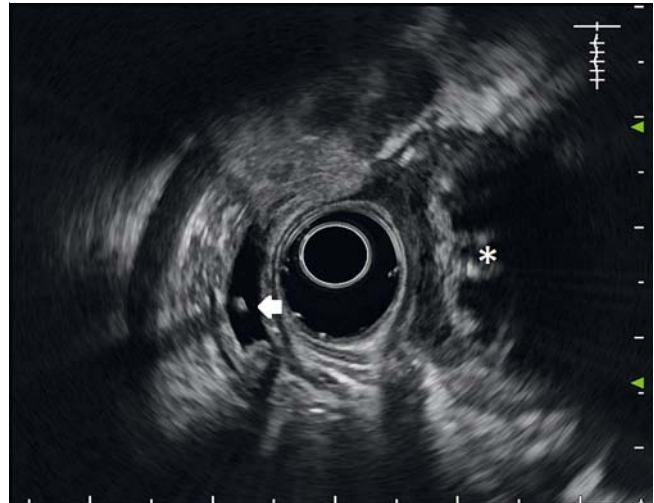
² Image quality assessment was recorded as optimal (1), suboptimal (2), poor (3) or impossible (4).

³ Visual artifacts were recorded as none (0), few (1) or several (2).

⁴ Need of suction was recorded as infrequent (0) or frequent (1).



► **Fig. 1** Typical image showing visual artifacts from the second portion of the duodenum (asterisk). The image also shows a stone (green arrow) and aerobilia (arrowhead) in the common bile duct.



► **Fig. 2** An example of optimal imaging from the second portion of the duodenum. No visual artifacts are seen. The image shows a small stone in the common bile duct (arrow) and large stones in the gallbladder (asterisk).

Sedation

There were no statistically significant differences between group A and B concerning the amount of sedation. In particular we administered on average/pro patient 107.9 mcg of fentanyl in the CO₂ group and 107.6 mcg in the air group, and 4.2 mg of midazolam in the CO₂ group and 4.1 mg in the air group (► **Table 2**).

Discussion

To the best of our knowledge, this is the first study investigating the role CO₂ insufflation on abdominal discomfort after EUS. The main finding of this study consisted in the significant association between CO₂ insufflation and lower abdominal discomfort scores at 3 hours after the procedure, compared to air insufflation. However, no statistically significant differences were found between CO₂ and air before and 1 hour after the procedure, although a trend to a reduced discomfort in the CO₂ group was seen at the latter stage. A possible explanation for the lack of benefit in the CO₂ group 1 hour after EUS can be found in the ongoing impact of sedation drugs on the perception of abdominal discomfort. On the other hand, we may assume that the effect of conscious sedation on the perception of visceral pain had completely vanished 3 hours after the procedure when the statistically significant difference between air and CO₂ was detected. Meanwhile, the amount of administered sedation was similar between the two groups and no association between CO₂ insufflation and reduced need of sedation was found.

Moreover, we showed a better quality of the EUS images obtained with CO₂ vs. air insufflation evaluated at different scanning points, including transduodenal, transgastric and transeophageal. Similarly, visual air artifacts and need of suction were lower when CO₂ was used in comparison to air. We hypothesize that use of CO₂ contributed significantly to improve-

ment in image quality, thanks to its quick reabsorption that may be 160 times faster than air [2]. In particular the beneficial effect of CO₂ might be related not only to suction of gas pockets during EUS but also to less gas distension of intervening bowel loops.

As far as the safety of CO₂ is concerned, Bretthauer et al. enrolled 103 patients in a randomized study evaluating whether CO₂ insufflation leads to CO₂ retention in both sedated and unsedated patients undergoing colonoscopy, in comparison to air insufflation. Data analysis showed a slight increase of end-tidal CO₂ in sedated patients but the type of gas insufflated was not relevant. They also administered a questionnaire to record abdominal pain at 1, 3 and 6 hours after the procedure. The results indicated a significant lower abdominal pain in the CO₂ group [12].

The role of CO₂ vs. air insufflation for colonoscopy was also the subject for a meta-analysis by Wu et al. (9 studies, 1577 patients). Despite significant heterogeneity for some major results, data showed that CO₂ insufflation was associated with a significant decrease in abdominal pain during and 1, 6 and 24 hours after the procedure [13].

A prospective, randomized, double blind study evaluated the degree of abdominal discomfort post ERCP in 116 patients insufflated with CO₂ vs. air. Mean pain scores were significantly reduced in the CO₂ group at 1, 3 and 24 hours after ERCP [14]. Another study on ERCP showed favorable results for CO₂ insufflation. The primary outcome was to compare immediate post-procedure abdominal pain where the CO₂ group showed a statistically lower VAS score than the air group. The authors also described a statistically significant reduction in abdominal distension at 3 and 24 hours post ERCP; no effect was seen with respect to nausea [15].

Intubation depth and total enteroscopy rate in single balloon enteroscopy were evaluated in a Chinese study comparing 214 patients sorted in 2 groups (air vs. CO₂). They also recorded ab-

dominal pain/distension at 1, 2, 3 and 6 hours post-enteroscopy. In the CO₂ group, a higher total enteroscopy rate was observed and the VAS score for pain and distension were milder, although not statistically significant [16].

Recently, the American Society for Gastrointestinal Endoscopy issued a review on the use of CO₂ in gastrointestinal endoscopy. CO₂ use was described in colonoscopy, ERCP, balloon-assisted enteroscopy and endoscopic submucosal dissection. As a conclusion of the review, a big amount of data indicated that CO₂ insufflation in many types of digestive endoscopy procedures is safe and associated with less abdominal pain compared with air insufflation [17].

Our study has limitations. First, no validated criteria for image quality and visual artifacts were available. As a result, the evaluation of EUS image quality may have been operator-dependent. However, we developed rigorous criteria for image analysis, which were shared by three experienced endosonographers who subsequently performed all the exams. Second, the operator was aware of the type of gas being used during the procedures, with a potential risk for an evaluation bias. However, all the endosonographers reviewed images and videos after each procedure to give an objective evaluation of the parameters of image quality and artifacts. Our study was conducted in patients who underwent EUS with conscious sedation. We acknowledge that results may change with deep sedation as far as patient satisfaction scores are concerned. On the other hand, we believe that the results concerning image quality evaluation are not related to the type of sedation used.

If our results are confirmed by future studies, it may be speculated that CO₂ insufflation should become a standard for diagnostic EUS to improve the quality of imaging, potentially leading to even more accurate diagnosis. Similarly, as the number of operative and therapeutic EUS procedures is steadily increasing, CO₂ insufflation should be the standard of care similarly to other types of therapeutic endoscopy.

Conclusion

In conclusion, we showed that CO₂ insufflation for EUS provided better scores for abdominal discomfort at 3 hours after the procedure. No differences were found in the amount of sedation administered in the CO₂ group compared to the air group. We also showed that EUS image quality, visual artifacts and need of suction were improved using CO₂ insufflation compared to air. Future studies are warranted to ascertain whether CO₂ insufflation should be regarded as standard of care for both diagnostic and therapeutic EUS.

Competing interests

None

References

- [1] Wu J, Hu B. The role of carbon dioxide insufflation in colonoscopy: a systematic review and meta-analysis. *Endoscopy* 2012; 44: 128–36
- [2] Saltzman HA, Sieker HO. Intestinal response to changing gaseous environments: normobaric and Hyperbaric observations. *Ann N Y Acad Sci* 1968; 150: 31–39
- [3] Li X, Zhao YJ, Dai J et al. Carbon dioxide insufflation improves the intubation depth and total enteroscopy rate in single-balloon enteroscopy: a randomized, controlled, double-blind trial. *Gut* 2014; 63: 1560–1565
- [4] Bretthauer M, Seip B, Aasen S et al. Carbon dioxide insufflation for more comfortable endoscopic retrograde cholangiopancreatography: a randomized, controlled, double-blind trial. *Endoscopy* 2007; 39: 58–64
- [5] Lee SJ, Lee TH, Park SH et al. Efficacy of carbon dioxide versus air insufflation according to different sedation protocols during therapeutic endoscopic retrograde cholangiopancreatography: Prospective, randomized, double-blind study. *Digestive Endoscopy* 2015; 27: 512–521
- [6] Aquino JCM, Bernardo WM, Hourneaux de Moura DT et al. Carbon dioxide versus air insufflation enteroscopy: a systematic review and meta-analysis based on randomized controlled trials. *Endosc Int Open* 2018; 06: E637–E645
- [7] Serrani M, Calvanese C, Lisotti A et al. Basics in endoscopic ultrasound part 1: diagnostic indications and tissue sampling. *Rev Recent Clin Trials* 2017: [Epub ahead of print] doi:10.2174/1574887112666171009170119
- [8] Serrani M, Calvanese C, Lisotti A et al. Basics in endoscopic ultrasound part 2: EUS-guided sampling and therapeutic applications. *Rev Recent Clin Trials* 2017: [Epub ahead of print] doi:10.2174/1574887113666171221113503
- [9] El Hajj II, Eloubeidi M. Sampling para-aortic lymph nodes in pancreatic and biliary cancers with EUS-guided FNA: diagnostic, clinical, and therapeutic implications. *Gastrointest Endosc* 2016; 84: 476–478
- [10] Dietrich CF, Burmester E. Contrast-enhanced ultrasound of small focal solid pancreatic lesions: A must! *Endosc Ultrasound* 2017; 6: S106–S110
- [11] Varadarajulu S, Wallace MB. Applications of endoscopic ultrasonography in pancreatic cancer. *Cancer Control* 2004; 11: 15–22
- [12] Bretthauer M, Lynge AB, Thiis-Evensen E et al. Carbon dioxide insufflation in colonoscopy: safe and effective in sedated patients. *Endoscopy* 2005; 37: 706–709
- [13] Wu J, Hu B. The role of carbon dioxide insufflation in colonoscopy: a systematic review and meta-analysis. *Endoscopy* 2012; 44: 128–136
- [14] Bretthauer M, Seip B, Aasen S et al. Carbon dioxide insufflation for more comfortable endoscopic retrograde cholangiopancreatography: a randomized, controlled, double-blind trial. *Endoscopy* 2007; 39: 58–64
- [15] Lee SJ, Lee TH, Park SH et al. Efficacy of carbon dioxide versus air insufflation according to different sedation protocols during therapeutic endoscopic retrograde cholangiopancreatography: Prospective, randomized, double-blind study. *Digestive Endoscopy* 2015; 27: 512–521
- [16] Xuan L, Yun-Jia Z, Jun D et al. Carbon dioxide insufflation improves the intubation depth and total enteroscopy rate in single-balloon enteroscopy: a randomized, controlled, double-blind trial. *Gut* 2014; 63: 1560–1565
- [17] Lo SK, Fujii-Lau LL, Enestvedt BK. ASGE Technology Committee. et al. The use of carbon dioxide in gastrointestinal endoscopy. *Gastrointest Endosc* 2016; 83: 857–865